Med
K8189

22500470157

PRINTED BY BIRRELL AND SONS, EDINBURGH & LONDON

Med
K8189

ATLAS OF

HUMAN ANATOMY

BY DR. JOHANNES SOBOTTA
PROFESSOR OF ANATOMY AND DIRECTOR OF THE ANATOMICAL INSTITUTE IN BONN

EDITED FROM THE EIGHTH GERMAN EDITION BY
J. PLAYFAIR McMURRICH
PROFESSOR EMERITUS OF ANATOMY IN THE UNIVERSITY OF TORONTO

VOLUME III

THE NERVOUS AND BLOOD VASCULAR SYSTEMS AND THE SENSE ORGANS OF THE HUMAN BODY WITH AN APPENDIX ON THE LYMPHATIC SYSTEM

WITH 156 COLORED AND 137 UNCOLORED FIGURES
TOGETHER WITH 68 PARTLY COLORED TEXT-FIGURES, FROM ORIGINAL DRAWINGS
BY K. HAJEK AND FRÄULEIN WOLFF-MALM

FOURTH REVISED AND ENLARGED ENGLISH EDITION

1936

G. E. STECHERT & CO., NEW YORK

UNIVERSITY
COLLEGE
LONDON

UNIVERSITY
COLLEGE
LONDON

WELLCOME INSTITUTE
LIBRARY

Coll.	WelMOmec
Coll.	
No.	QS

8615159

Printed in Germany

64919

From the Preface to the First Edition.

An experience with the work of the Anatomical Laboratory, extending over many years, has convinced the author of the advisability of presenting illustrations of the peripheral nervous system and of the blood vessels as they are seen by the student in his dissections, i. e. the nerves and arteries of any region in the same figure. Consequently in the majority of the figures representing these structures arteries and nerves, arteries, veins and nerves, or arteries and veins are shown in each figure, and only occasionally is there a departure from this plan, when, for the sake of clearness, accessory figures showing only the arteries or the nerves (for example, the cranial nerves) are added.

This method of arrangement has the advantage for the student, that he finds on a single page of the Atlas representations of all the structures he has seen at any one stage of his dissection, and is not obliged to waste time in turning from page to page of the Volume. Each figure is one of a series of topographic anatomical illustrations.

The simultaneous representation of blood vessels and nerves makes reproduction in colors necessary. The arteries are shown red, the veins blue and the nerves yellow. For the reproduction in color autotypes have been used, prepared in a most satisfactory matter by Messrs. Angerer and Göschl of Vienna and the various plates have at the same time been adapted for the coloration of the other tissues shown (muscles, bones, fat, skin etc.). In this way colored illustrations have been obtained, which do not, it is true, show an absolutely natural coloration, but nevertheless approximate it sufficiently to give an extraordinarily accurate general impression. All the figures of the Volume are from originals by K. Hajek, whose artistic talent and skill in anatomical illustrations are again fully manifested.

As was stated in the Preface to the first Volume, the endeavour has been to make of the Atlas a work that would be of use to students and practitioners, not one intended for expert Anatomists. Whoever wishes information in special fields of anatomy, will necessarily turn to special treatises on those fields, and this Atlas, even were it twice as extensive, would not be sufficient for him. On the other hand an undue expansion of the book and overloading it with illustrations of interest only to specialists, would only render it more difficult for the student or practitioner to get the information he desires. The chief object has therefore been to limit the illustrations to the necessities of the case, but to present these in a series of comprehensive figures, showing step by step the stages usually followed in dissection.

In correspondence with the arrangement followed in the first and second volumes, this one presents alternately pages of text and figures. The latter show the principal figures of the Atlas, the former, in addition to accessory and schematic figures and the explanations of the chief figures, a brief text intended for review during the use of the Atlas in the dissecting room, this being accompanied by references to other illustrations in the volume where the structures under consideration are shown.

Würzburg, May 1906.

The Author.

From the Preface to the Second German Edition.

The Second Edition of this Atlas differs from the first by an increase in the number of illustrations. For the brain, especially, and for the sense-organs a number of new figures have been added. The representation of the principal fibre tracts has been extensively altered and in this connection some of the schematic figures have been replaced by new ones. In addition a considerable number of schemata have been added, which have in many cases been adapted from the admirable figures by Villiger.

The alphabetical index at the end of the Volume refers to the figures. In the text brief references are given to pages on which further statements as to the structures under consideration are to be found, and a special page reference was therefore unnecessary.

Würzburg, Spring, 1915. The Author.

Preface to the Sixth German Edition.

In contrast to the third, fourth and fifth editions, which were essentially the same as the second, this sixth edition presents a number of new illustrations, especially of the nerves and vessels of the lower limb, of the brain, the eye and the auditory organ.

Bonn, 1927. The Author.

Preface to the Seventh German Edition.

This seventh edition, compared with the sixth, has been improved, apart from lesser modifications, by the addition of three large, full-page, colored representations of the cranial, cervical and thoracic portions of the sympathetic nervous system, taken, by kind permission, from the admirable publications of Mr. Braeucker of Hamburg.

Bonn, November 1930. The Author.

Preface to the Eighth German Edition.

The eighth edition differs but little from the seventh, but contains some new illustrations of the blood vessels (and nerves), especially those of the posterior abdominal wall; and of the lymphatic vessels. Further the structure of the medulla oblongata, the pons and the corpora quadrigemina is shown in some schemata taken from the diagrams of Müller-Spatz, published by the J. F. Lehmann's Verlag.

Bonn, March 1933. The Author.

Contents.

Angiology (Cont.) and **Neurology** p. 1—241, Fig. 1—235.
Vessels of the Heart p. 4, 5, Fig. 4, 5.
Nerves and Vessels of the Neck, Axilla, Back and Thoracic Wall p. 6—37, Fig. 6—25.
Nerves and Vessels of the Upper Extremity p. 39—59, Fig. 26—50.
Nerves and Vessels of the Head and the Viscera of the Head and Neck p. 60—85, Fig. 51—75.
Blood Vessels of the Abdominal Viscera p. 86—93, Fig. 76—79.
Blood Vessels and Nerves of the false and true Pelvis and of the Perineum p. 94—111, Fig. 80—90.
Nerves and Vessels of the Lower Extremity p. 112—133, Fig. 91—113.
The Sympathetic Nervous System p. 134—142, Fig. 114—118.
The Spinal Cord p. 143—151, Fig. 119—134.
The Meninges and Vessels of the Brain p. 152—167, Fig. 135—147.
The Brain p. 168—241, Fig. 148—235.

Sense Organs p. 242—323, Fig. 236—353.
The Eye p. 242—277, Fig. 236—284.
The Ear p. 278—315, Fig. 285—339.
The Skin p. 316—323, Fig. 340—353.

Appendix: the Lymphatic Vessels p. 324—335, Fig. 354—361.

Index p. 337.

Explanations

of the Abbreviations used in this Volume.

---

ant. or anter. = anterior, anteriores etc.
a. or art. = arteria, arteriae etc.
ext. = externus, externa etc.
gangl. = ganglion.
gland. = glandula, glandulae etc.
int. = internus, interna etc.
lat., lateral. = lateralis, laterales etc.
med., medial. = medialis, mediales etc.
n. = nervus.
nn. = nervi.
post., poster. = posterior, posteriores etc.
prof. = profundus, profunda etc.
r., ram. = ramus, rami.
superf. = superficialis, superficiales etc.
tr. = truncus, trunci etc.
v. = vena, venae etc.

The names of muscles are indicated by having a capital initial letter.

× after a name denotes that the part is cut.

A name in () indicates that the part is not directly visible, but shows through other structures.

The significance of the remaining abbreviations that are occasionally used is indicated by the context. When part of a figure has no labels, these have already been given in one or several preceding figures.

Angiology. (Cont.)

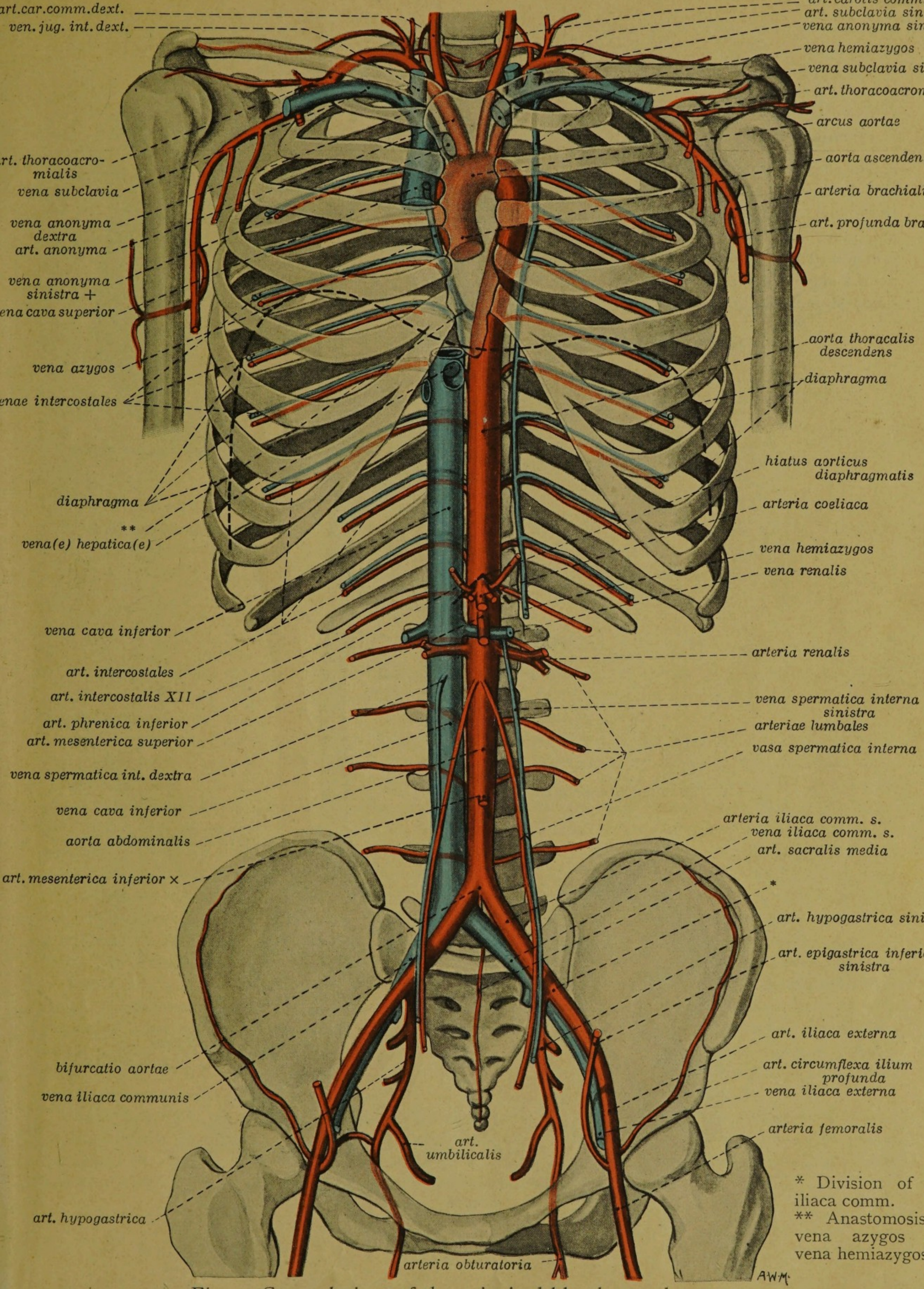

* Division of art. iliaca comm.
** Anastomosis of vena azygos and vena hemiazygos.

Fig. 1. General view of the principal blood-vascular stems.

The Fetal Circulation.

Fig. 2. Diagram of the fetal circulation.

The vessels that contain so-called arterial blood are red; those that contain venous blood are blue; and those that contain mixed blood are violet. The arrows show the direction of the blood stream.

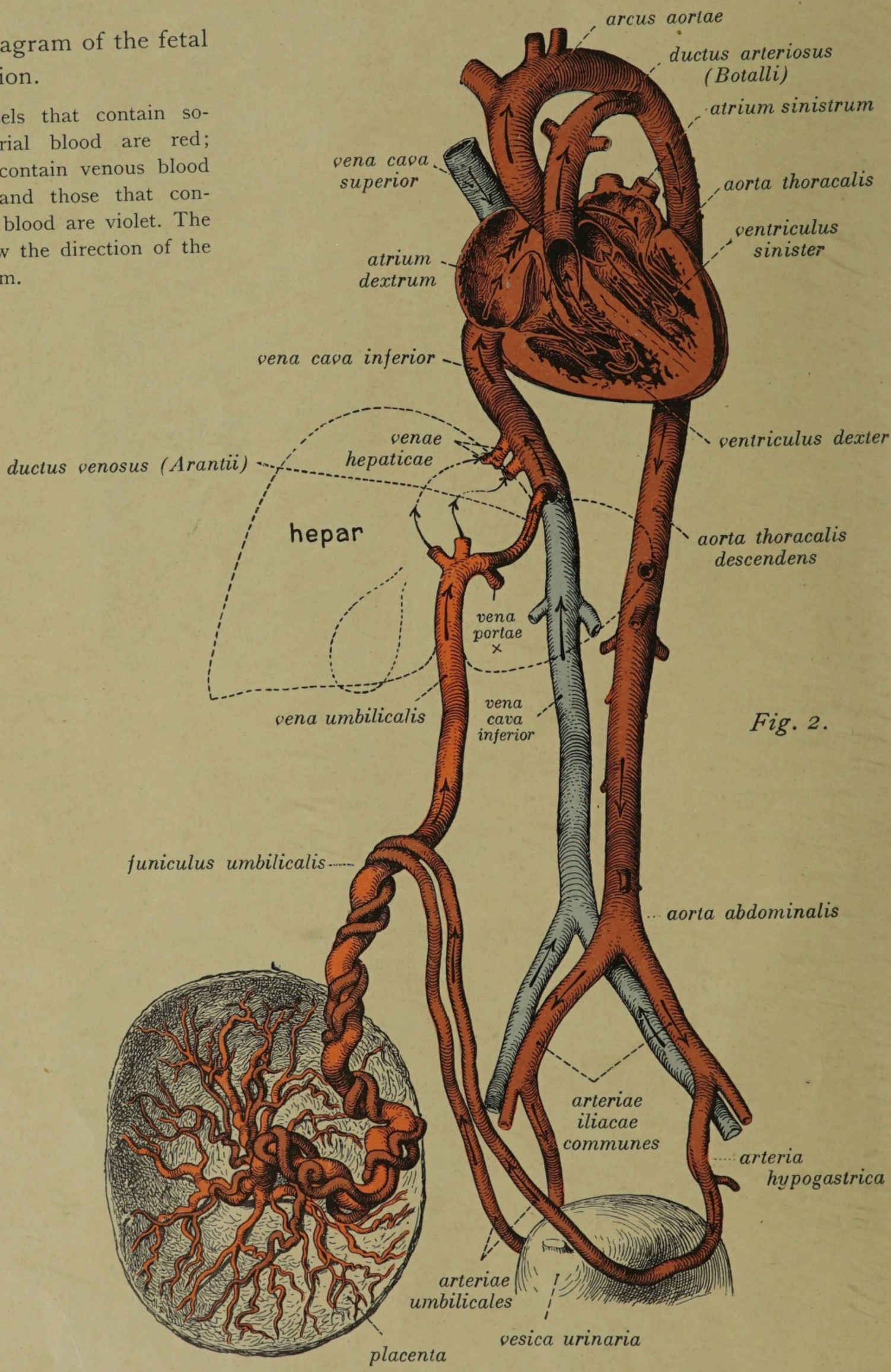

Fig. 2.

The Fetal Circulation.

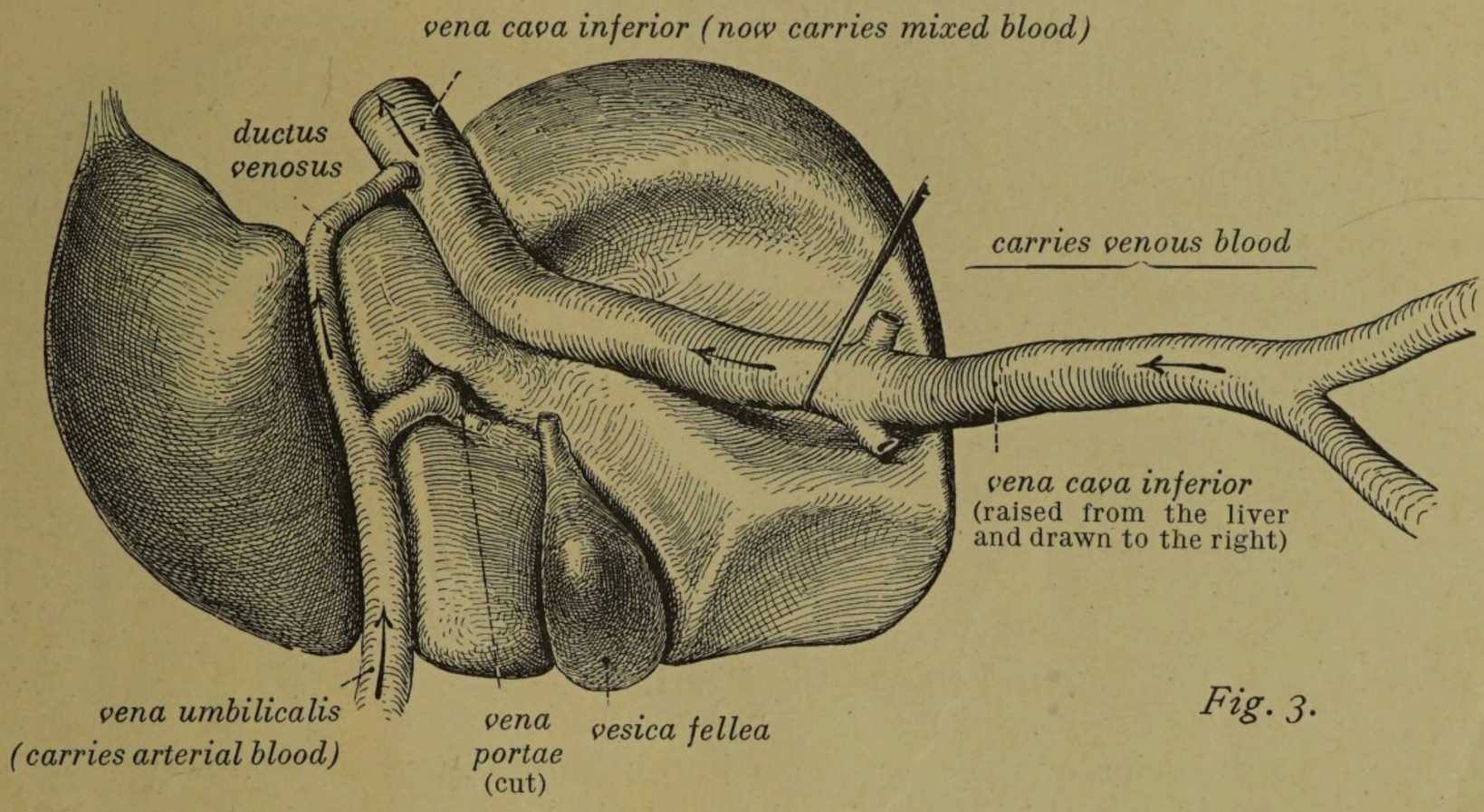

Fig. 3.

Fig. 3. The circulation in the fetal liver (schematic).

The Fetal Circulation.

The circulation in the fetus differs from that of the adult in that the lesser or pulmonary circulation is still almost entirely wanting, the placental circulation taking its place. The two halves of the heart are in communication by an opening in the atrial septum, the *foramen ovale.*

The placenta, united to the wall of the uterus, is connected with the fetus by the *umbilical cord*, which contains two *umbilical arteries* and an *umbilical vein.* The umbilical arteries are identical with those of the same name in the adult but are so large that they appear to be almost direct continuations of the fetal aorta; they contain blood relatively poor in oxygen, since the fetal arteries do not contain any really "arterial" blood, but an almost mixed blood. In the placenta this blood is arterialized and is returned by the umbilical vein to the body of the fetus; here for the most part it passes through the liver by way of the later portal vein but partly goes directly into the inferior vena cava by the *ductus venosus (Arantii)*, there becoming mixed with venous blood. Other venous blood is poured into the right atrium from the superior vena cava and the cardiac veins; the decidedly mixed blood thus produced can pass on by one of two routes. 1. It may pass directly to the left atrium through the foramen in the atrial septum *(foramen ovale)*, and so in the usual way into the systemic circulation; or 2. it may reach the systemic circulation in the ordinary manner. A valve, that gradually becomes more and more insufficient towards the close of fetal life, the *valvula venae cavae (Eustachian valve)*, incompletely prevents blood flowing from the right atrium into the right ventricle, but what does reach that cavity continues on into the pulmonary artery. This has a large communication, the *ductus arteriosus (Botalli)*, with the fetal aorta, so that all the blood in the pulmonary artery passes into the aorta, since the branches of the artery in the lungs are hardly capable of transmitting blood during the collapsed condition of the organs.

Only at birth, when the first breath draws air into the lungs and at the same time widens the branches of the pulmonary artery, does the lesser circulation become active; the foramen ovale of the atrial septum is closed by the valvula of the foramen; the communication between the two sides of the heart is thus closed; and the lumen of the ductus arteriosus becomes obliterated.

Angiology. (Cont.)

The Arteries of the Heart.

The arteries of the heart are the two *coronary arteries*, which take their origin from the right and left sinuses of the aorta.

1. The *left coronary artery* supplies principally the left ventricle. It divides into *a circumflex branch* and an *anterior descending branch*. The latter runs downward towards the apex of the heart in the anterior longitudinal sulcus; the former traverses the left half of the coronary sulcus.

2. The *right coronary artery* supplies principally the right ventricle and the right atrium. It runs at first in the right half of the coronary sulcus to the diaphragmatic surface of the heart and then descends as the *posterior descending branch* in the posterior longitudinal sulcus to the apical incisura.

The Veins of the Heart.

Almost all the veins of the heart open into a large, but short common stem, the *coronary sinus*, which occupies the posterior part of the coronary groove and opens into the right atrium. The principal affluents are:

1. The *great cardiac vein (v. cordis magna)* arises at the apex of the heart and runs at first upwards in the anterior longitudinal sulcus and then through the left half of the coronary sulcus, to unite with other veins in forming the coronary sinus.

2. The *middle cardiac vein (v. cordis media)* ascends in the posterior longitudinal sulcus and, after receiving the small cardiac vein, opens into the coronary sinus.

3. The *small cardiac vein (v. cordis parva)* is a small stem lying in the right portion of the coronary groove. It opens into the middle cardiac vein just before it enters the coronary sinus, or else directly into the sinus.

4. The *posterior cardiac veins (vv. posteriores ventriculi sinistri)* are usually several stems situated on the posterior surface of the left ventricle; they either open into the great vein or directly into the coronary sinus.

5. The *arterior cardiac veins (vv. cordis anteriores)* are on the anterior wall of the right ventricle and open, usually, directly into the right atrium.

6. The *oblique vein (v. obliqua atrii sinistri)* is a small vein on the posterior surface of the left atrium which opens either into the great vein or the coronary sinus.

7. The *venae cordis minimae* belong to the wall of the right atrium and open directly into the atrium by the foramina venarum minimarum.

Fig. 4. The arteries and veins of the heart, from in front. (1/1) A piece is cut out of the conus arteriosus and the beginning of the pulmonary artery, to show the left coronary artery.

Fig. 5. The arteries and veins of the heart, from behind and below. (1/1)

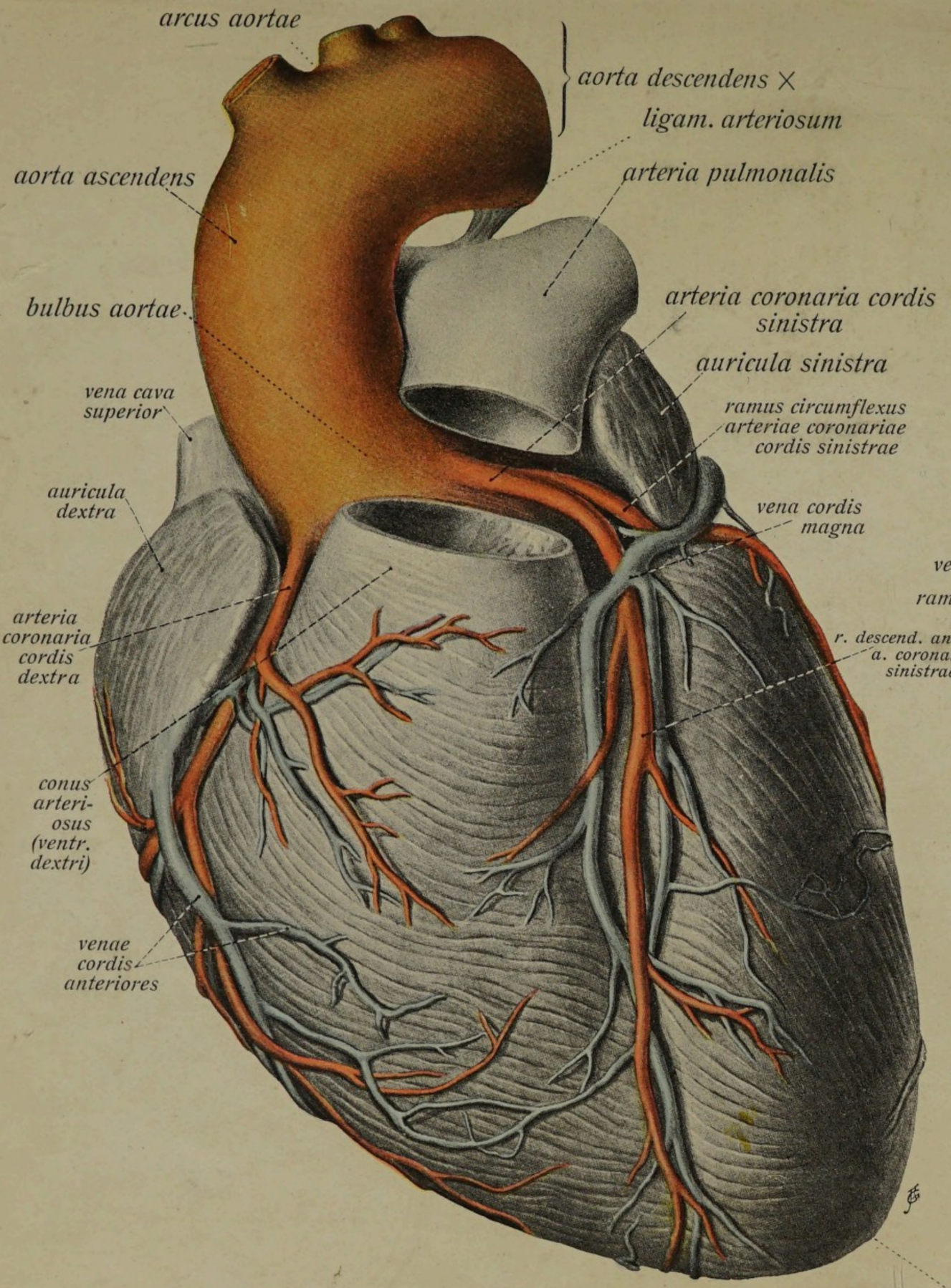
arcus aortae
aorta descendens ×
ligam. arteriosum
aorta ascendens
arteria pulmonalis
bulbus aortae
arteria coronaria cordis sinistra
auricula sinistra
vena cava superior
ramus circumflexus arteriae coronariae cordis sinistrae
auricula dextra
vena cordis magna
arteria coronaria cordis dextra
r. descend. anter. a. coronar. sinistrae
conus arteriosus (ventr. dextri)
venae cordis anteriores
apex cordis

Fig. 4.

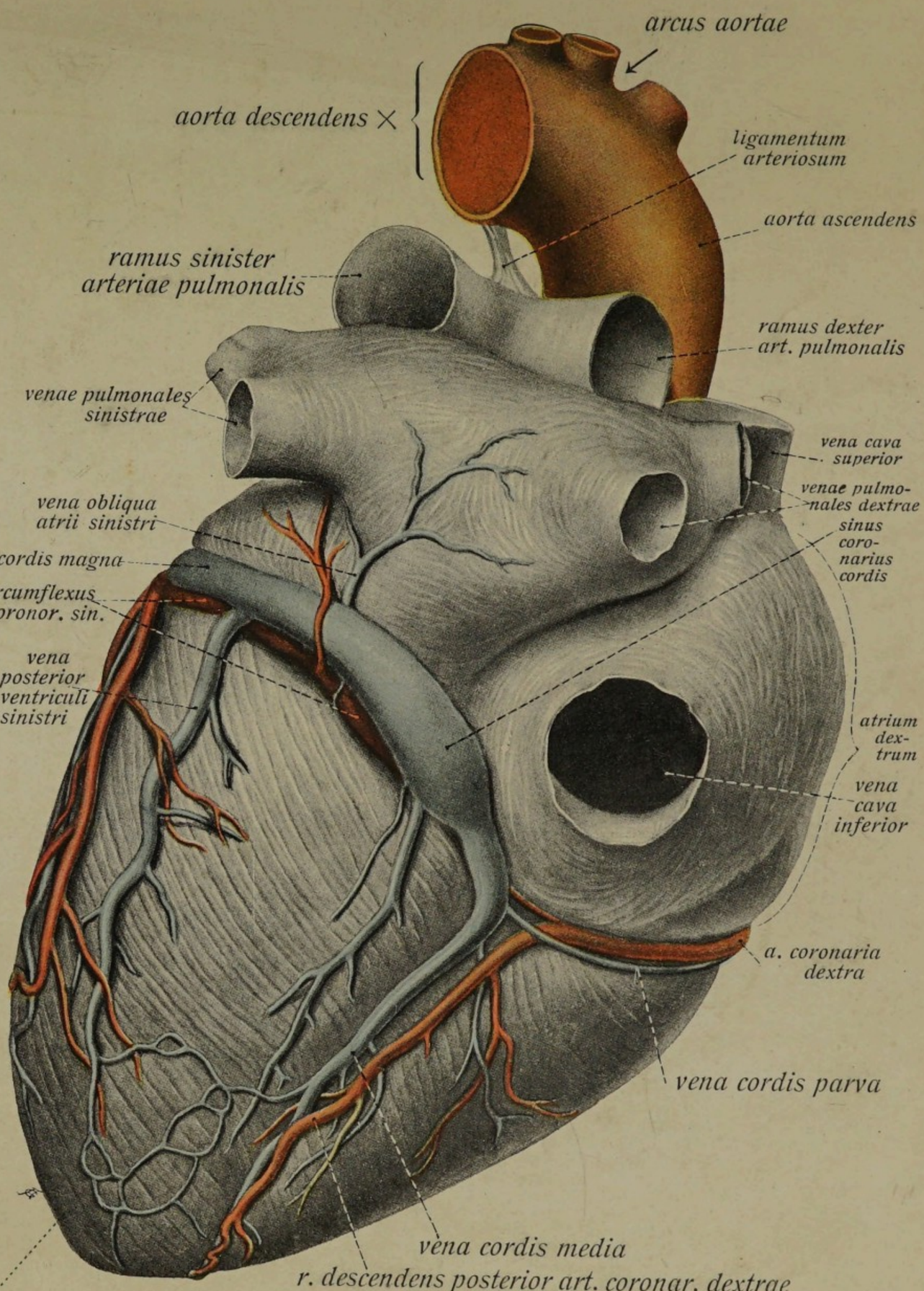
arcus aortae
aorta descendens ×
ligamentum arteriosum
aorta ascendens
ramus sinister arteriae pulmonalis
ramus dexter art. pulmonalis
venae pulmonales sinistrae
vena cava superior
venae pulmonales dextrae
vena obliqua atrii sinistri
sinus coronarius cordis
vena cordis magna
ram. circumflexus a. coronor. sin.
vena posterior ventriculi sinistri
atrium dextrum
vena cava inferior
a. coronaria dextra
vena cordis parva
vena cordis media
r. descendens posterior art. coronar. dextrae

Fig. 5.

Fig. 6.

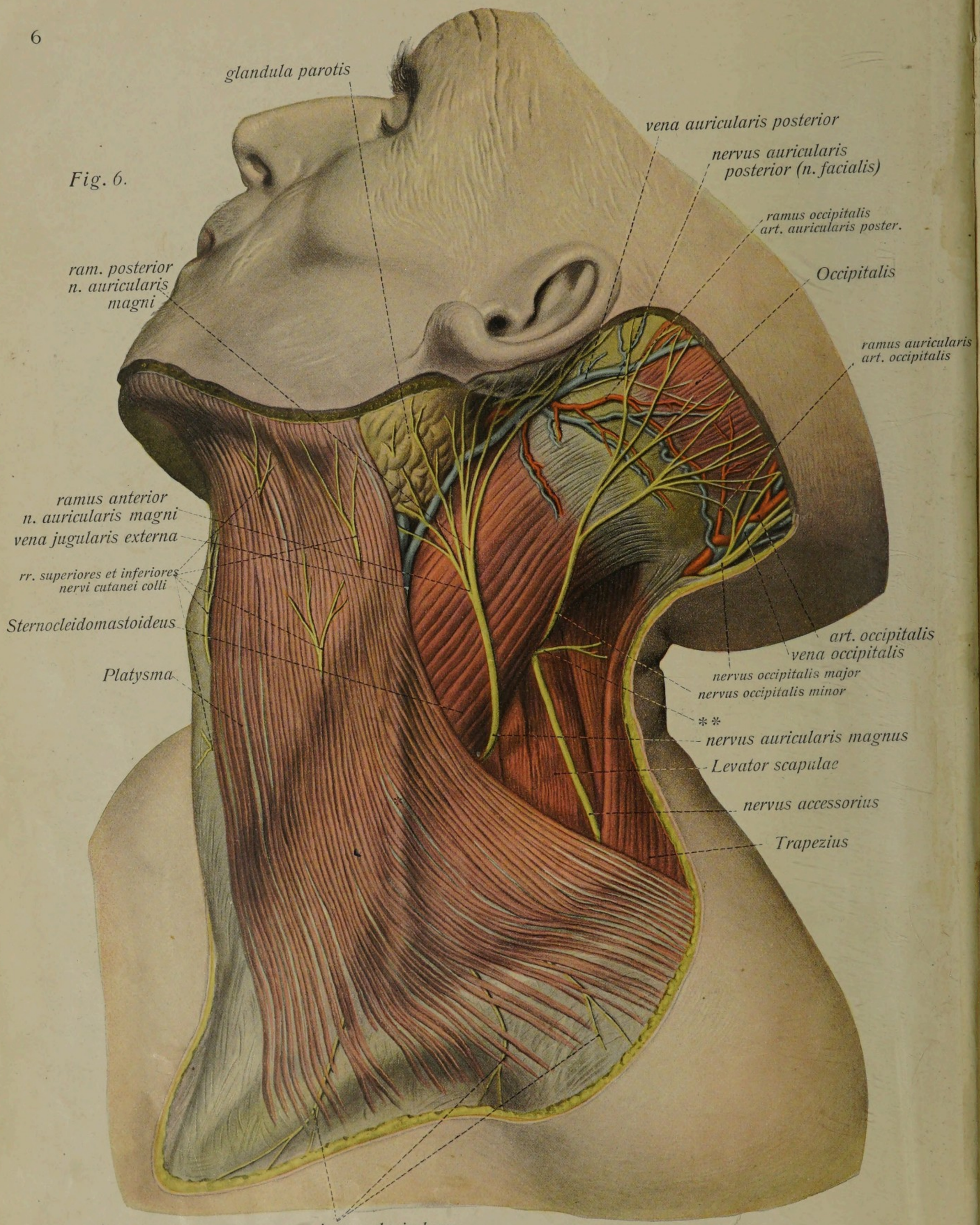
glandula parotis
vena auricularis posterior
nervus auricularis posterior (n. facialis)
ramus occipitalis art. auricularis poster.
Occipitalis
ram. posterior n. auricularis magni
ramus auricularis art. occipitalis
ramus anterior n. auricularis magni
vena jugularis externa
rr. superiores et inferiores nervi cutanei colli
Sternocleidomastoideus
Platysma
art. occipitalis
vena occipitalis
nervus occipitalis major
nervus occipitalis minor
* *
nervus auricularis magnus
Levator scapulae
nervus accessorius
Trapezius
nervi supraclaviculares

The Nerves and Blood Vessels of the Upper Half of the Body.
The Nerves and Blood Vessels of the Neck.

Fig. 6. The superficial nerves and blood vessels of the neck (1st layer). ($^1/_2$)
The skin is removed from the border of the mandible to below the clavicle and behind the Platysma the superficial layer of the cervical fascia is also removed. * = external jugular vein covered by the Platysma; ** = accessory cutaneous branch of the cervical plexus.

The Cervical Nerves. (Cont. on p. 8 and 36)

The *cervical plexus* is formed by the union of the ventral roots of the first to the fourth cervical nerves (C_1—C_4) (Fig. 12). Its branches are:

1. The *great auricular nerve* (large, sensory, from C_3) becomes visible at the lateral border of the Sterno-mastoid at about half the height of the muscle. It passes upwards over the lateral surface of the muscle and divides into the weaker *anterior branch* to the lower part of the skin of the face and the stronger *posterior* branch to the convex surface of the auricle and the neighboring portions of the skin. (Anastomoses with the lesser occipital.) Fig. 6, 7, 8, 51, 52.

2. The *lesser occipital nerve* (usually moderately large, sensory, from C_2 and C_3) comes into view above the preceding at the lateral border of the tendon of insertion of the Sterno-mastoid and ascends like this, but somewhat more posteriorly, to the skin of the lateral parts of the occipital region. (Anastomoses with great auricular, great occipital.) Fig. 6, 7, 8, 51—53.

3. The *n. cutaneus colli* (moderately large, sensory, from C_2 and C_3) lies between the Sterno-mastoid and the Platysma. Its branches, *superior* and *inferior*, pierce the Platysma at different levels and pass to the skin of the neck. (Anastomoses constantly with the cervical branch of the facial.) Fig. 7, 8.

4. The *supraclavicular nerves* (large, sensory, from C_3 and C_4) lie beneath the Platysma above the clavicle, and between this and the muscle, and divide into *anterior (suprasternal) branches* to the anterior portion of the skin of the pectoral region, *middle (supraclavicular) branches* to the lateral portion of the same, and *posterior (suprascapular) branches* to the skin over the Deltoid. Fig. 7, 8, 29, 31.

5. The *phrenic nerve* (rather large, principally motor, from C_4, partly also from C_3 or C_5) runs downwards on the Scalenus anterior beside the ascending cervical artery to the medial surface of the pleural dome, passes, in company with the pericardiaco-phrenic vessels, close under the mediastinal pleura to the pericardium (on the right in close relation to the right innominate vein and the superior vena cava), and then runs between the pericardium and the pericardial pleura to the diaphragm, which it supplies with muscular branches. Some branches of the right nerve, the *phrenico-abdominal*, traverse the diaphragm and pass to the muscle from the under surface; a sensory *pericardial branch* goes to the pericardium. Fig. 9, 10, 20.

The Nerves and Vessels of the Upper Half of the Body.
The Nerves and Blood Vessels of the Neck. (Cont.)

Fig. 7. The superficial nerves and veins of the neck (2nd layer). ($^1/_2$)

The Platysma is divided, the upper portion reflected toward the lower jaw, the lower part removed; the fascia is split over the facial veins.

** = Anastomosis of the spinal accessory nerve with the cervical plexus.
+ = Connection of the external jugular with the deep veins.
++ = The vena transversa colli, opening into the external jugular.
+* = Upper perforating branches of the internal mammary artery and vein, appearing between the two origins of the sterno-mastoid.

The Cervical Plexus. (Cont.)

6. A branch to the descending hypoglossal ramus to form the *ansa hypoglossi* (moderately large, often double; motor, from C_2 and C_3). It lies medial to the Sterno-mastoid and supplies the infrahyoid muscles. Fig. 8—10, 13.

7. *Muscular branches* (mostly rather small, variable in number, motor) to the Trapezius, Levator scapulae (upper part), the Scaleni and the praevertebral muscles of the neck. Fig. 7, 8.

The Veins of the Neck (Cont. on p. 19).

I. The Superficial Veins.

1. The *external jugular vein* (large, constant) lies between the Platysma and the fascia of the Sterno-mastoid. It has a posterior root, situated behind the ear and formed by the posterior auricular vein and partly by the occipital, and an anterior root formed by the posterior facial vein. Above the clavicle and behind the clavicular portion of the Sterno-mastoid it opens into the subclavian vein, forming with this and the internal jugular the innominate vein. In childhood the vein is always well developed, but in the adult it is not infrequently rudimentary. Fig. 7, 8, 14, 15, 23, 51, 52.

2. The *anterior jugular vein* (very variable in size and development, inconstant, often different on the two sides) lies between the Platysma and the cervical fascia. It arises in the region of the chin, unites with the external jugular and, above the clavicle, with its fellow of the opposite side by the *venous jugular arch*, and opens either into the lower part of the external jugular or beside this into the subclavian vein. Fig. 7, 14.

Fig. 7.

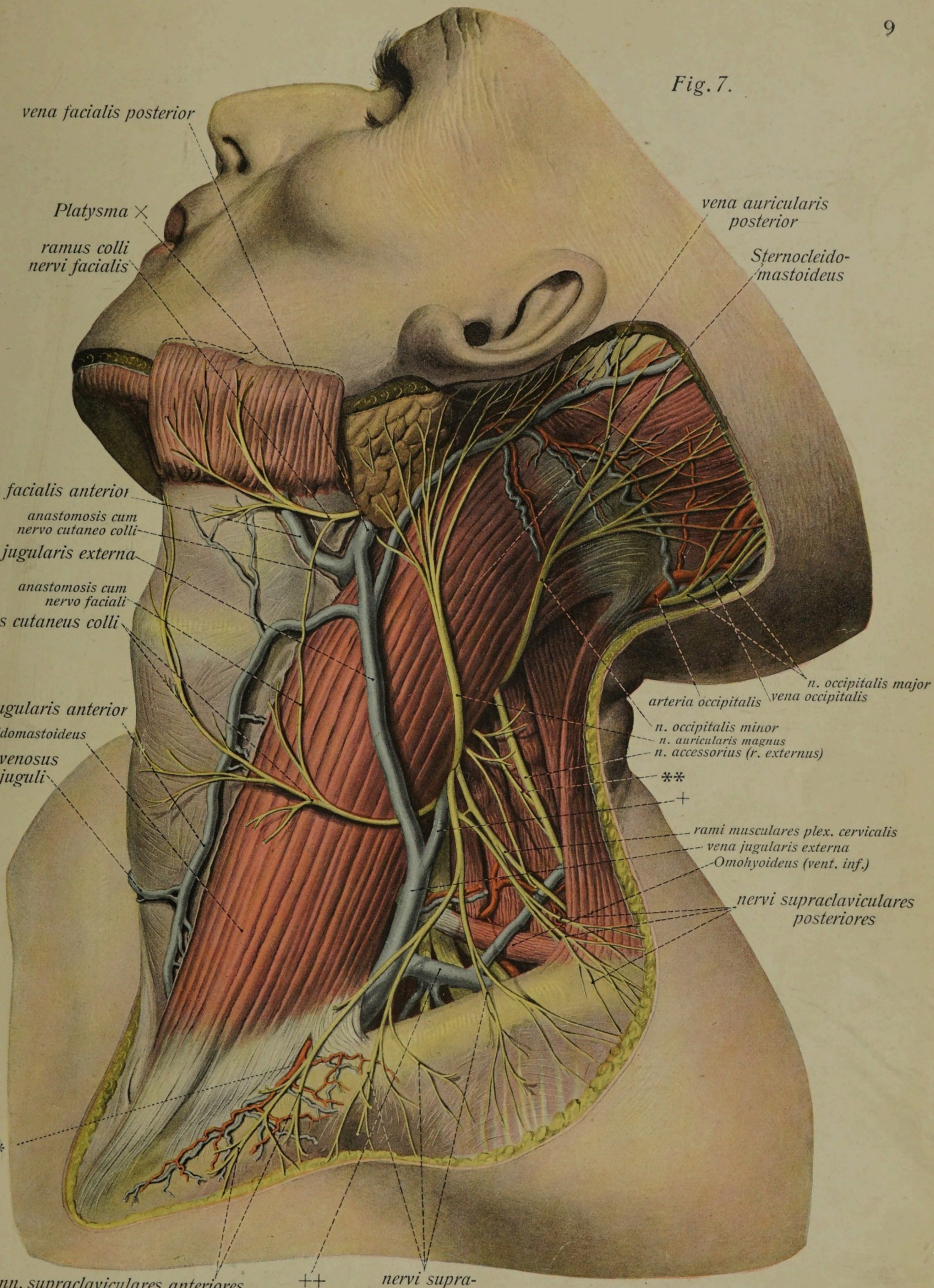
vena facialis posterior
Platysma ×
ramus colli nervi facialis
vena auricularis posterior
Sternocleido-mastoideus
vena facialis anterior
anastomosis cum nervo cutaneo colli
vena jugularis externa
anastomosis cum nervo faciali
nervus cutaneus colli
n. occipitalis major
arteria occipitalis
vena occipitalis
vena jugularis anterior
Sternocleidomastoideus
arcus venosus juguli
n. occipitalis minor
n. auricularis magnus
n. accessorius (r. externus)
**
+
rami musculares plex. cervicalis
vena jugularis externa
Omohyoideus (vent. inf.)
nervi supraclaviculares posteriores
+*
nn. supraclaviculares anteriores
++
nervi supra-claviculares medii

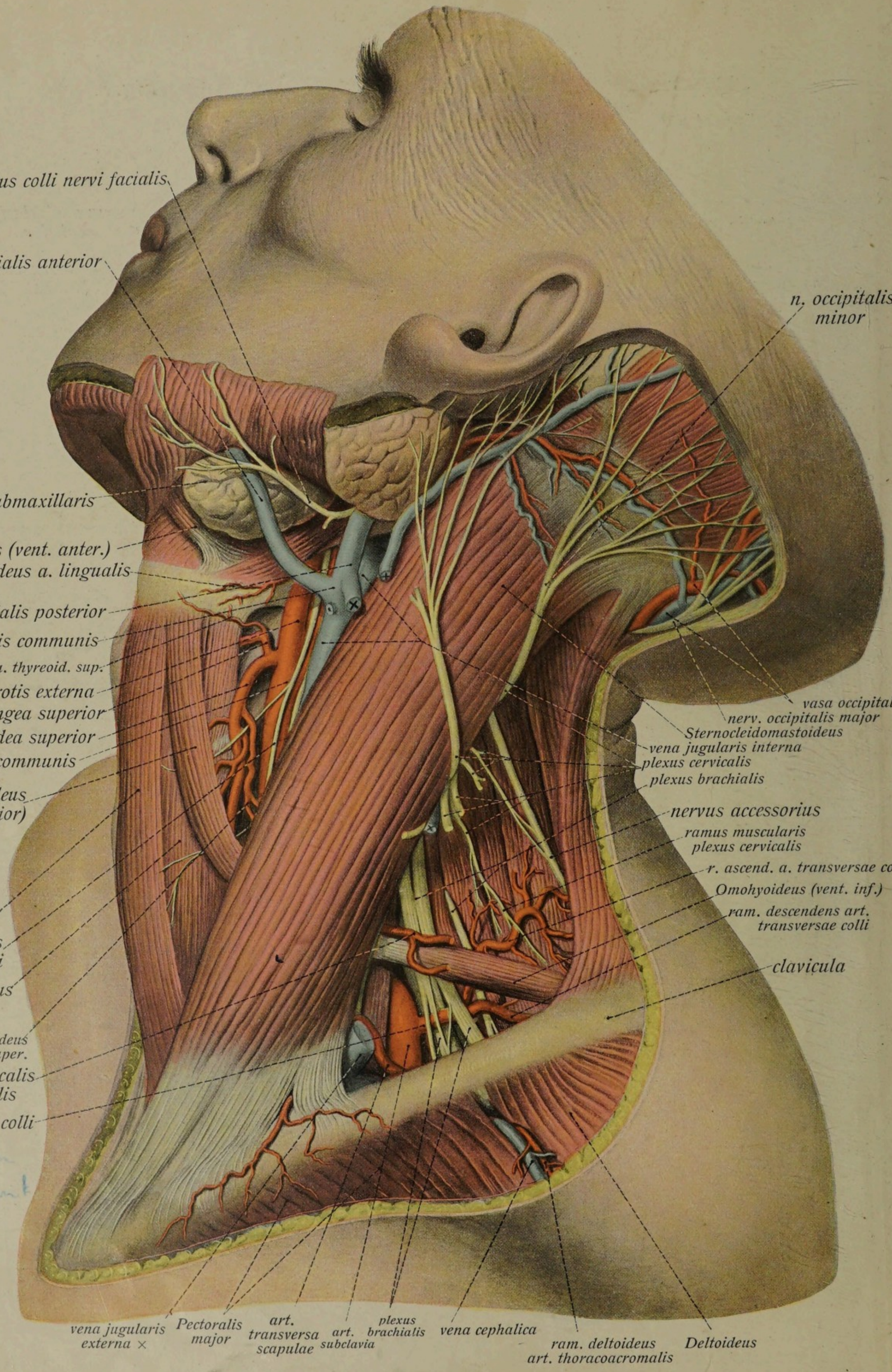
ramus colli nervi facialis
vena facialis anterior
n. occipitalis minor
glandula submaxillaris
Digastricus (vent. anter.)
ram. hyoideus a. lingualis
vena facialis posterior
vena facialis communis
r. hyoideus a. thyreoid. sup.
arteria carotis externa
art. laryngea superior
art. thyreoidea superior
art. carotis communis
Omohyoideus (vent. superior)
vasa occipitalia
nerv. occipitalis major
Sternocleidomastoideus
vena jugularis interna
plexus cervicalis
plexus brachialis
nervus accessorius
ramus muscularis
plexus cervicalis
r. ascend. a. transversae colli
Omohyoideus (vent. inf.)
ram. descendens art. transversae colli
clavicula
Sternohyoideus
ram. descendens nervi hypoglossi
Sternothyreoideus
ramus sternocleidomastoideus art. thyreoideae super.
arteria cervicalis superficialis
a. transversa colli
vena jugularis externa ×
Pectoralis major
art. transversa scapulae
art. subclavia
plexus brachialis
vena cephalica
ram. deltoideus art. thoracoacromalis
Deltoideus

Fig. 8.

The Nerves and Blood Vessels of the Upper Half of the Body.
The Nerves and Blood Vessels of the Neck. (Cont.)

Fig. 8. The nerves, arteries and veins of the neck (3rd layer). ($^1/_2$)

The superficial layer of the cervical fascia and the superficial veins have been removed, so that the superficial muscles are exposed. The superficial cervical artery was relatively weak in the subject from which the illustration was drawn and was partly replaced by the ascending branch of the arteria transversa colli; otherwise it was as in Fig. 7.

× = cut surface of the posterior auricular vein, the anterior jugular and the connection with the external jugular.

The Arteries of the Neck.

1. The *subclavian artery* arises on the right side from the innominate artery, on the left directly from the aortic arch. It passes at first upwards behind the sterno-clavicular joint without giving off any large branches and, in the neck, forms an arch, strongly convex upwards, in which lies the dome of the pleura. It then runs behind the insertion of the Scalenus anterior to the subclavian groove on the first rib and over this to behind the clavicle. Its branches arise chiefly from the portion medial to the Scalenus, only the transversa colli arising from the lateral portion. Fig. 8—11, 13, 18.

The branches of the subclavian, frequently inconstant, have a tendency to arise opposite one another or to branch from a common trunk; the ascending limb of the arch, much longer on the left than on the right, gives off no branches. The branches are the following:

1. The *vertebral artery* arises from the convexity of the arch of the artery, passes behind the common carotid artery to the foramen transversarium of the sixth cervical vertebra and through the foramina of succeeding vertebrae up to the first and then through the foramen magnum to the brain. For its branches see p. 36 and 164. Fig. 10, 11, 13, 135, 146, 147.

2. The *internal mammary artery* arises opposite the preceding from the concavity of the subclavian and passes downwards behind the subclavian vein, the sternoclavicular articulation and the costal cartilages. Fig. 10, 11, 20, 21. Its branches are:

a) Small branches to the thymus, trachea and bronchi.

b) The *pericardiaco-phrenic* artery (see Fig. 20) to the pericardium and diaphragm.

c) The *perforating branches* which pass through the intercostal spaces to the skin and muscles of the breast.

d) *Intercostal branches* to the anterior portion of the intercostal spaces.

e) The *musculo-phrenic artery*, one of the terminal branches, to the surface of the diaphragm.

f) The *superior epigastric artery*, the other terminal branch, to the posterior surface of the anterior abdominal wall. Anastomoses with the inferior epigastric.

3. The *thyreo-cervical trunk* arises from the anterior wall of the subclavian close to the medial border of the Scalenus anterior and gives rise usually, though variations are frequent, to the following branches. Fig. 10, 11, 13.

a) The *inferior thyreoid artery*, the strongest branch, passes upwards and medially behind the common carotid artery to the posterior surface and lower border of the thyreoid gland, giving off small pharyngeal, oesophageal and tracheal (Fig. 74) branches, the moderately large *inferior laryngeal* (Fig. 74, 75) and large glandular branches. Fig. 10, 11, 13, 15).

The Nerves and Blood Vessels of the Upper Half of the Body.
The Nerves and Vessels of the Neck. (Cont.)

Fig. 9. The nerves and blood vessels of the deeper layer of the neck (4th layer). (1/2) The Sterno-mastoid is removed except for small portions at its origin and insertion. The superficial veins of the neck have been removed (× × = cut surface of the external jugular near its opening; * = cut surface of the anterior jugular near its opening), as have also the common facial (× = cut surface near its opening) and smaller veins. The nerves of the cervical plexus have been cut, except the lesser occipital, the phrenic and muscle branches.

* = branch of the cervical plexus to form the ansa hypoglossi.
** = cut surface of the superior thyreoid vein.
\+ = sterno-mastoid branch of the superior thyreoid artery.

The Subclavian Artery. (Cont.)

b) The *superficial cervical artery*, moderately large, often replacing the transversa colli or partly replaced by it, usually arises with the ascending cervical from a short common trunk, passes behind the Sterno-mastoid, and, becoming superficial at its lateral border, continues over the Omohyoid and Levator scapulae through the supraclavicular fossa to the anterior border of the Trapezius. It supplies the skin and muscles. Fig. 8—13.

c) The *ascending cervical artery*, of moderate size, runs upwards in front of the insertions of the Longus capitis and Scaleni, beside the phrenic nerve. In addition to muscle branches and a *spinal branch* to each cervical intervertebral foramen, it sends a deep branch to the nape muscles. Fig. 8—11, 13.

d) The *transverse scapular artery*, usually moderately large and often arising directly from the subclavian, passes in front of the origin of the Scalenus anterior, beside the subclavian vein, and behind the clavicle, giving off small branches. It continues on to the scapular notch and into the supraspinous and infraspinous fossae, anastomosing with the circumflex scapular from the axillary artery and contributing an acromial branch to the formation of the acromial rete. Fig. 8, 10, 11, 17, 27.

4. The *costo-cervical trunk* arises as a fairly large but short trunk from the posterior surface of the subclavian and divides into the *deep cervical* and *supreme intercostal* arteries. See p. 36.

5. The *transversa colli artery* arises from the terminal portion of the subclavian (see p. 11) and, deeply seated, makes its way through the branches of the brachial plexus and divides, sooner or later, into an *ascending* and a *descending* terminal branch. The former passes upwards between the flat muscles of the back, the latter downwards, mainly between the Rhomboidei and the Serratus posterior superior, along with the dorsal scapular nerve. It is the largest artery of the back and anastomoses with various arteries of the axilla. Fig. 8—11, 23, 25.

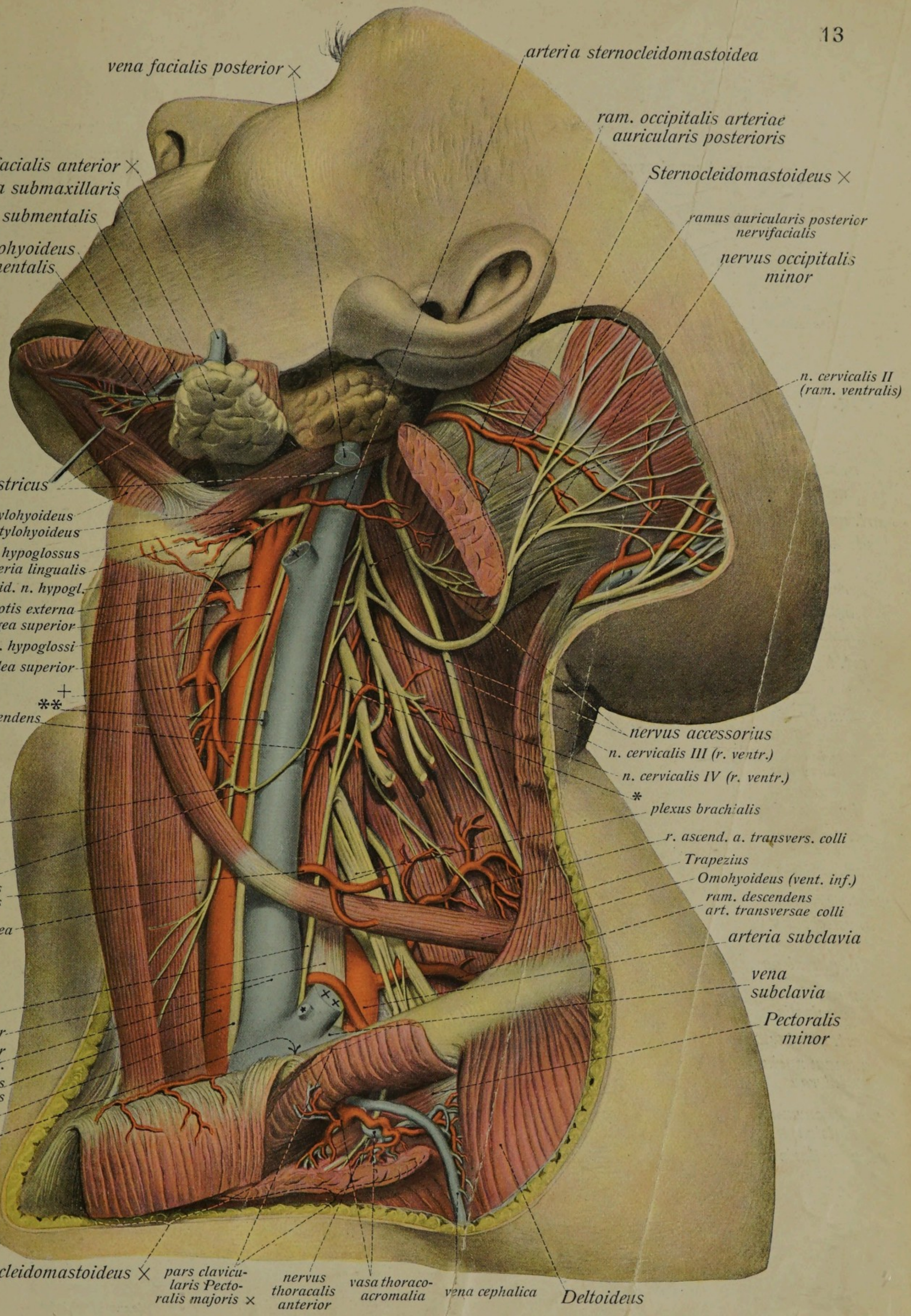
vena facialis posterior
arteria sternocleidomastoidea
ram. occipitalis arteriae auricularis posterioris
vena facialis anterior
glandula submaxillaris
Sternocleidomastoideus
vena submentalis
ramus auricularis posterior nervifacialis
nervus mylohyoideus
art. submentalis
nervus occipitalis minor
n. cervicalis II (ram. ventralis)
Digastricus
Mylohyoideus
Stylohyoideus
nervus hypoglossus
arteria lingualis
r. thyreohyoid. n. hypogl.
arteria carotis externa
art. laryngea superior
r. descendens n. hypoglossi
art. thyreoidea superior
a. cervicalis ascendens
nervus accessorius
n. cervicalis III (r. ventr.)
n. cervicalis IV (r. ventr.)
plexus brachialis
ram. descendens nervi hypoglossi
r. ascend. a. transvers. colli
Trapezius
ansa hypoglossi
Omohyoideus (vent. inf.)
art. cervicalis superficialis
ram. descendens art. transversae colli
glandula thyreoidea
arteria subclavia
vena subclavia
n. phrenicus
Scalenus anterior
Pectoralis minor
bulbus inferior venae jugul. int.
art. carotis communis
nervus vagus
vena anonyma sinistra
Sternocleidomastoideus
pars clavicularis Pectoralis majoris
nervus thoracalis anterior
vasa thoracoacromalia
vena cephalica
Deltoideus

Fig. 9.

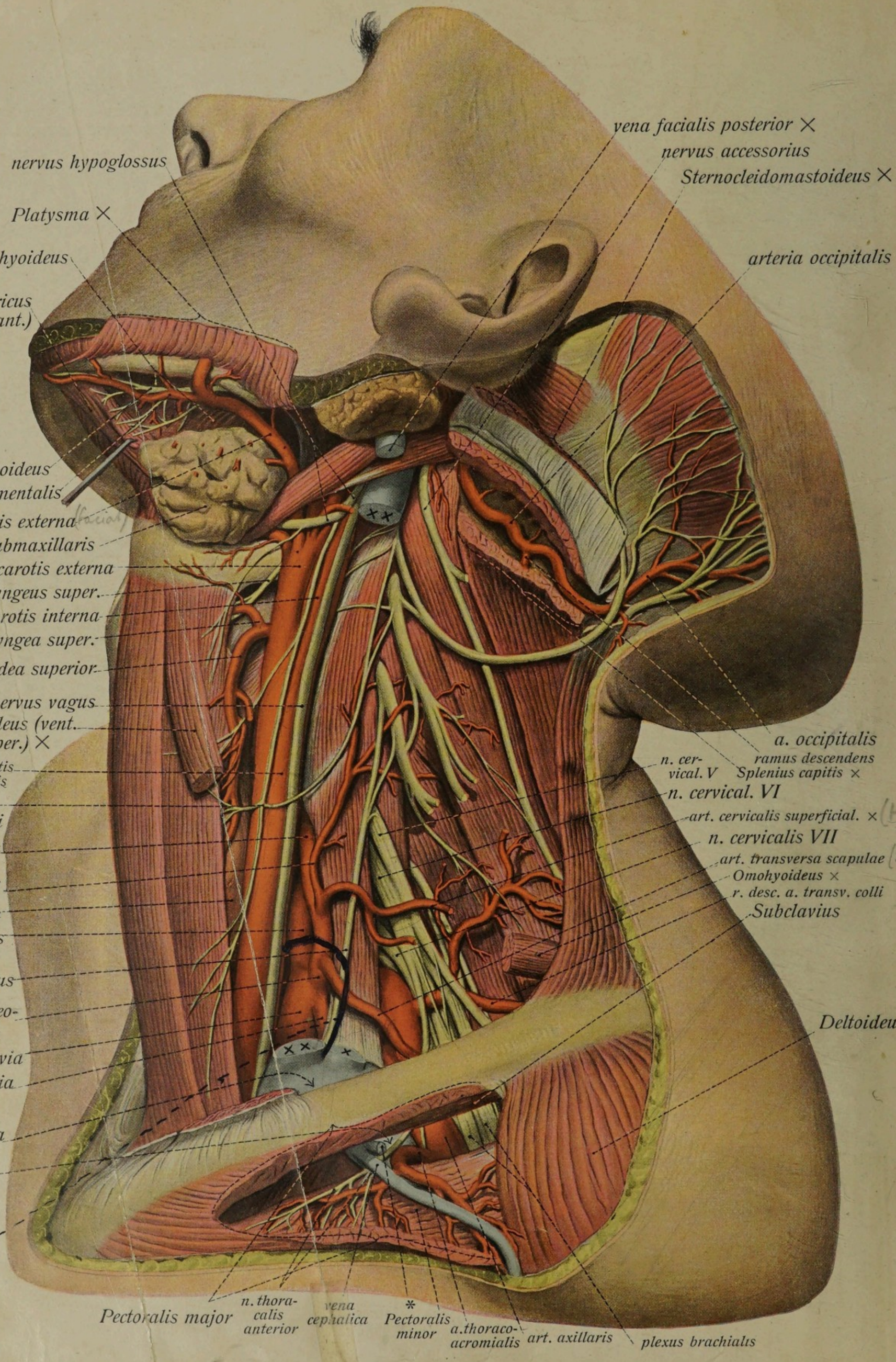
nervus hypoglossus
Platysma ×
Mylohyoideus
Digastricus (vent. ant.)
vena facialis posterior ×
nervus accessorius
Sternocleidomastoideus ×
arteria occipitalis
n. mylohyoideus
art. submentalis
art. maxillaris externa
glandula submaxillaris
arteria carotis externa
nervus laryngeus super.
arteria carotis interna
arteria laryngea super.
art. thyreoidea superior
nervus vagus
Omohyoideus (vent. super.) ×
arteria carotis communis
ansa hypoglossi
art. thyreoidea inferior
art. cervicalis ascendens
gland. thyreoidea
a. vertebralis
n. phrenicus
truncus thyreo-cervicalis
art. subclavia
a. mammaria interna
vena anonyma sinistra
vena axillaris
a. occipitalis
ramus descendens
n. cervical. V
Splenius capitis ×
n. cervical. VI
art. cervicalis superficial. ×
n. cervicalis VII
art. transversa scapulae
Omohyoideus ×
r. desc. a. transv. colli
Subclavius
Deltoideus
Pectoralis major
n. thoracalis anterior
vena cephalica
Pectoralis minor
a. thoraco-acromialis
art. axillaris
plexus brachialis

Fig. 10.

The Nerves and Blood Vessels of the Upper Half of the Body.
The Nerves and Blood Vessels of the Neck. (Cont.)

Fig. 10. The nerves and arteries of the deeper layer of the neck (5th layer). (1/2)

The Omohyoid has been removed, also the internal jugular vein. (× × = its cut surfaces, × = the cut surface of the external jugular.) The Sterno-mastoid is turned upwards at its insertion and the Splenius capitis divided along the course of the occipital artery. * = the thoraco-acromial vein cut at its opening into the cephalic vein.

Fig. 11. The branches of the subclavian and the course of the vertebral artery through the neck. (Schematic.)

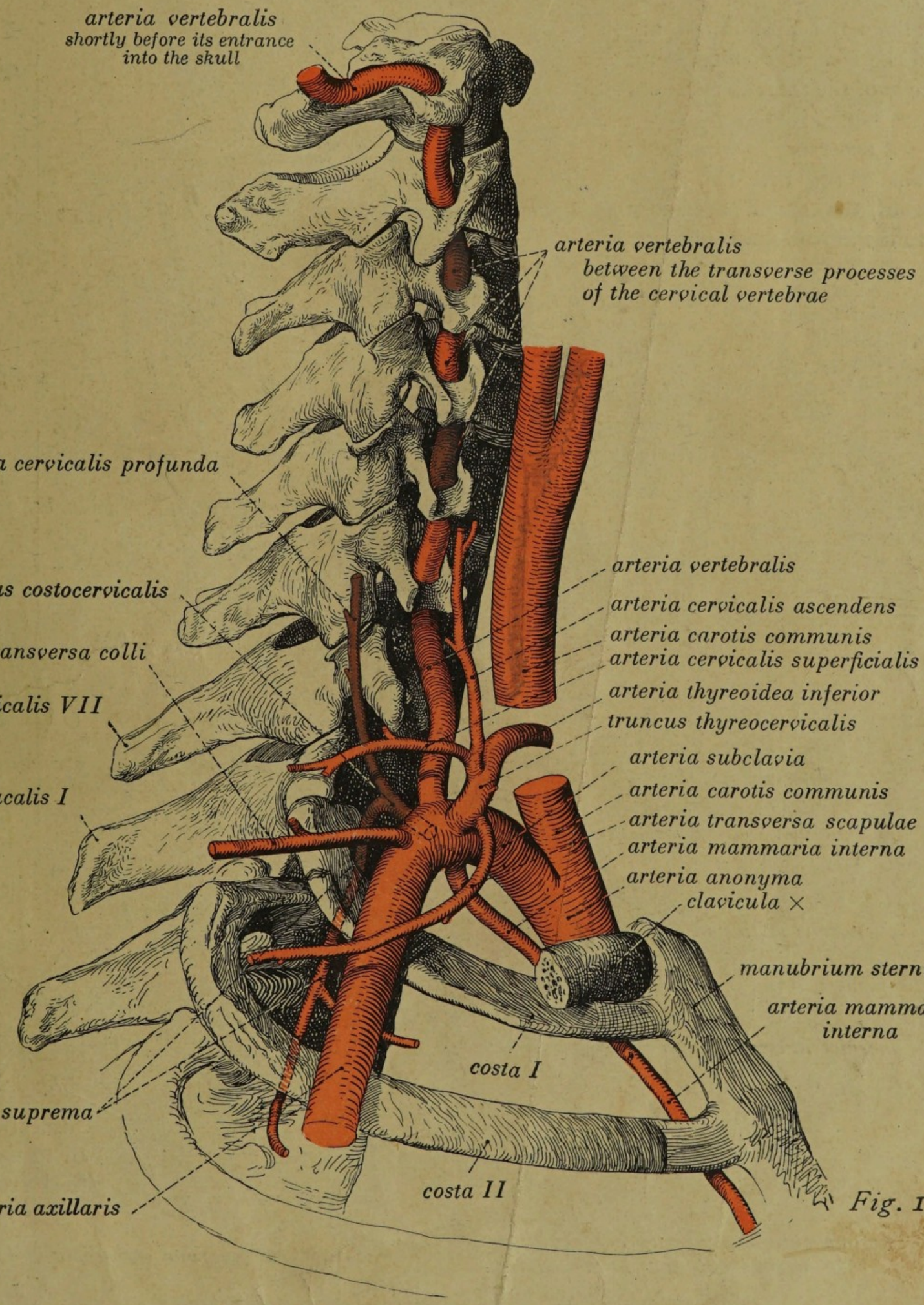

Fig. 11.

The Nerves and Blood Vessels of the Upper Half of the Body.
The Nerves and Blood Vessels of the Neck and Axilla.

Fig. 13. The nerves and blood vessels of the deep layers of the neck and axilla (6th layer). (Compare Fig. 17.) (1/2)

The infrahyoid muscles and the common carotid artery have been for the most part removed, the clavicle has been disarticulated at the sterno-clavicular joint and divided at about its middle. The Pectoralis major and minor are cut and the Deltoid divided along the course of the thoraco-acromial artery.

\+ = accessory sympathetic ganglion. ** = first rib, * = branch of the spinal accessory nerve to the Sterno-mastoid (cut).

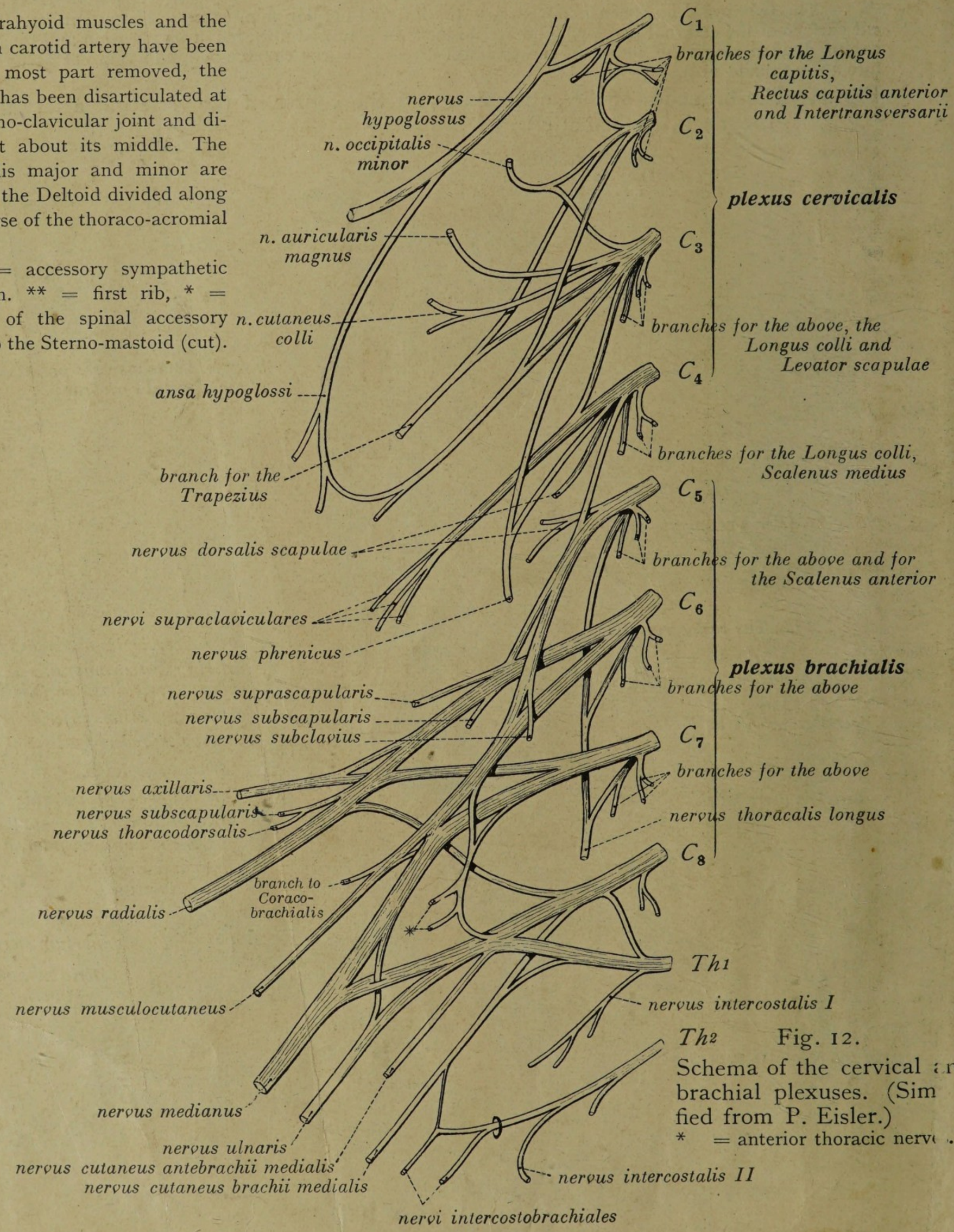

Fig. 12. Schema of the cervical and brachial plexuses. (Simplified from P. Eisler.) * = anterior thoracic nerve.

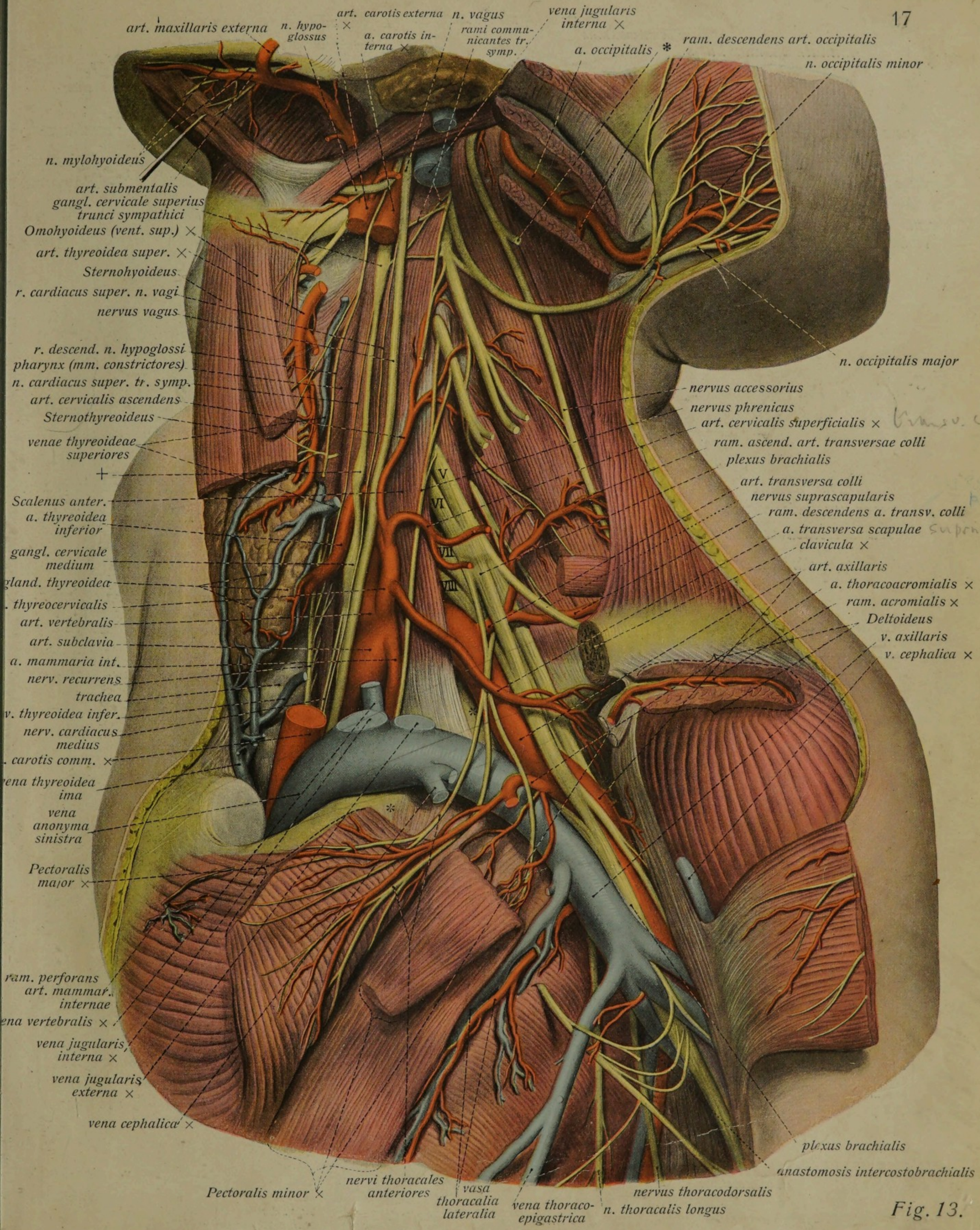
art. maxillaris externa
n. hypoglossus
art. carotis externa ×
a. carotis interna ×
n. vagus
rami communicantes tr. symp.
vena jugularis interna ×
a. occipitalis *
ram. descendens art. occipitalis
n. occipitalis minor
n. occipitalis major
n. mylohyoideus
art. submentalis
gangl. cervicale superius trunci sympathici
Omohyoideus (vent. sup.) ×
art. thyreoidea super. ×
Sternohyoideus
r. cardiacus super. n. vagi
nervus vagus
r. descend. n. hypoglossi
pharynx (mm. constrictores)
n. cardiacus super. tr. symp.
art. cervicalis ascendens
Sternothyreoideus
venae thyreoideae superiores
Scalenus anter.
a. thyreoidea inferior
gangl. cervicale medium
gland. thyreoidea
. thyreocervicalis
art. vertebralis
art. subclavia
a. mammaria int.
nerv. recurrens
trachea
v. thyreoidea infer.
nerv. cardiacus medius
. carotis comm. ×
ena thyreoidea ima
vena anonyma sinistra
Pectoralis major ×
ram. perforans art. mammar. internae
ena vertebralis ×
vena jugularis interna ×
vena jugularis externa ×
vena cephalica ×
nervus accessorius
nervus phrenicus
art. cervicalis superficialis ×
ram. ascend. art. transversae colli
plexus brachialis
art. transversa colli
nervus suprascapularis
ram. descendens a. transv. colli
a. transversa scapulae
clavicula ×
art. axillaris
a. thoracoacromialis ×
ram. acromialis ×
Deltoideus
v. axillaris
v. cephalica ×
plexus brachialis
anastomosis intercostobrachialis
nervus thoracodorsalis
n. thoracalis longus
vena thoraco-epigastrica
vasa thoracalia lateralia
nervi thoracales anteriores
Pectoralis minor ×
V
VI
VII
VIII

Fig. 13.

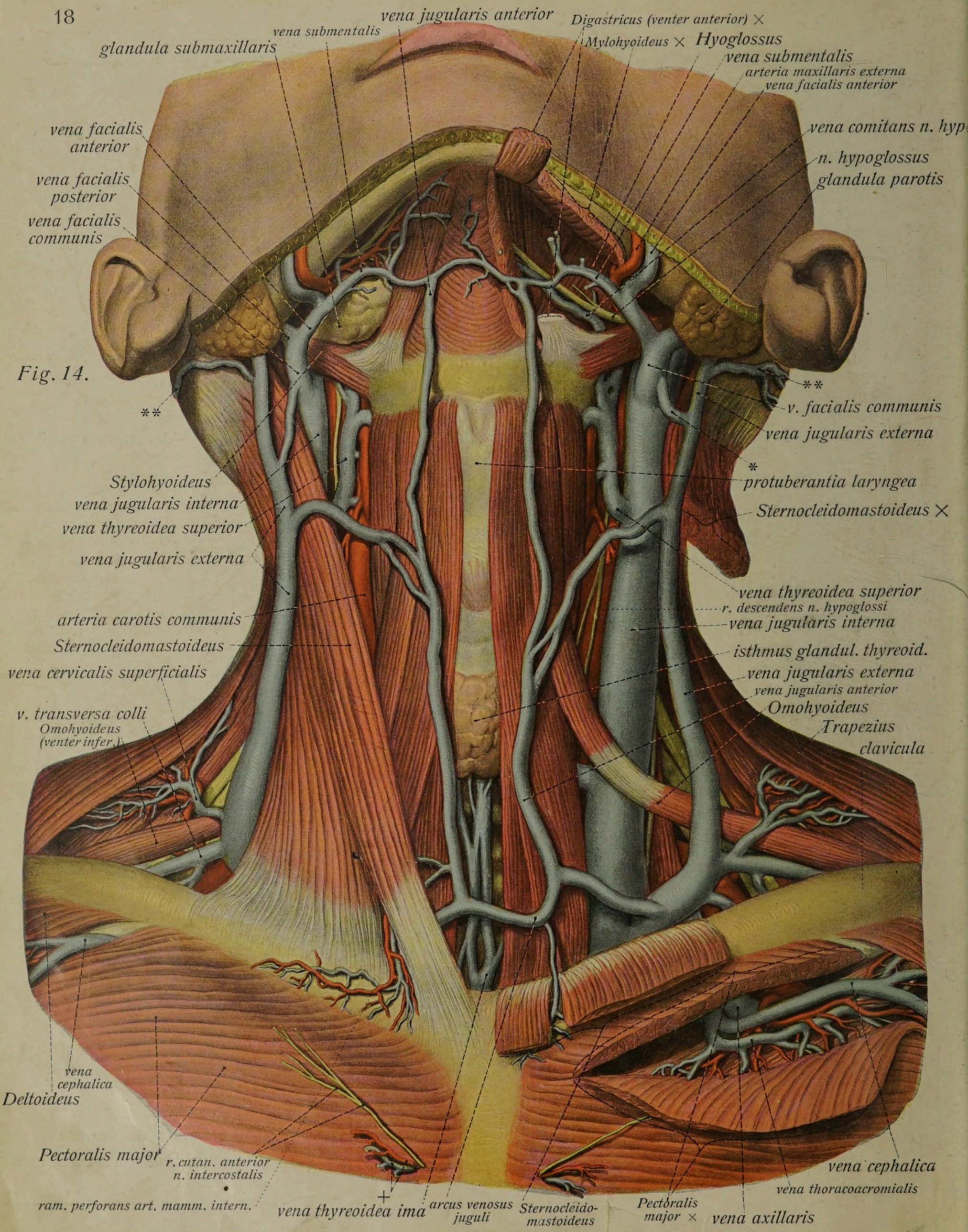
vena jugularis anterior
vena submentalis
glandula submaxillaris
Digastricus (venter anterior) ×
Mylohyoideus ×
Hyoglossus
vena submentalis
arteria maxillaris externa
vena facialis anterior
vena facialis anterior
vena facialis posterior
vena facialis communis
vena comitans n. hypo
n. hypoglossus
glandula parotis
**
v. facialis communis
vena jugularis externa
*
protuberantia laryngea
Sternocleidomastoideus ×
Stylohyoideus
vena jugularis interna
vena thyreoidea superior
vena jugularis externa
vena thyreoidea superior
r. descendens n. hypoglossi
vena jugularis interna
arteria carotis communis
Sternocleidomastoideus
vena cervicalis superficialis
isthmus glandul. thyreoid.
vena jugularis externa
vena jugularis anterior
Omohyoideus
Trapezius
clavicula
v. transversa colli
Omohyoideus
(venter infer.)
vena cephalica
Deltoideus
Pectoralis major
r. cutan. anterior
n. intercostalis
ram. perforans art. mamm. intern.
vena thyreoidea ima
arcus venosus juguli
Sternocleido-mastoideus
Pectoralis major ×
vena axillaris
vena cephalica
vena thoracoacromialis

Fig. 14.

The Nerves and Blood Vessels of the Upper Half of the Body.
The Veins of the Neck (superficial).

Fig. 14. The superficial veins of the neck and the subclavicular fossa. (1/2)

On the left side the Sterno-mastoid is cut and for the most part removed; the clavicular portion of the Pectoralis major is divided and the anterior belly of the Digastricus and the Mylohyoideus are cut. The rest of the superficial musculature is exposed.

* = Union of the external jugular vein with the common facial. ** = occipital root of external jugular vein. + = perforating branches of the internal mammary vessels.

The Veins of the Neck. (Cont. from p. 8.)

II. The Deep Veins of the Neck.

I. The *internal jugular vein* corresponds in general to the common carotid artery, yet not completely so, since some of the veins that correspond to branches of the external carotid artery open into the external jugular. In its upper part it corresponds to the internal carotid artery. It arises at the jugular foramen in an enlargement, the *superior bulb*, and carries off the blood of the cranial cavity as the direct continuation of the transverse sinus (see p. 152). In company with the internal carotid artery it runs downwards on the lateral wall of the pharynx and, after receiving its largest branch, the common facial vein, it continues down the neck, lateral to the common carotid artery and beneath the Sterno-mastoid. Behind the sterno-clavicular joint it has a second enlargement, the *inferior bulb*, and unites with the subclavian to form the innominate vein. Fig. 8, 9, 14, 15. Its chief branches, which vary greatly, are:

1. *Pharyngeal veins* from the pharyngeal plexus on the posterior surface of the pharynx; they open for the most part into the upper portion of the vein. Fig. 72.

2. The *superior thyreoid veins*, often several, corresponding to the branches of the artery of the same name. They either open directly into the internal jugular or also into the common facial vein. They often receive neighbouring veins. Fig. 14, 15.

3. The *lingual vein* corresponds to the artery of the same name. It divides into deep branches accompanying the deep artery of the tongue and one (or two) accompanying the hypoglossal nerve *(vena comitans n. hypoglossi)*; this, often quite large, arises usually from the large *sublingual vein*. The lingual vein frequently opens into one of the branches of the internal jugular, instead of directly into that vein. Fig. 14, 15, 75.

4. The *common facial vein*, the largest branch of the internal jugular, corresponding generally but not in detail to the external carotid artery. It is formed immediately below the angle of the mandible by the union of the *anterior* and *posterior facial veins* (see p. 67). Fig. 7, 8, 14, 15.

5. The *inferior thyreoid vein* corresponds only in part to the artery of the same name. It opens occasionally directly into the inferior bulb of the internal jugular, but more usually into the innominate vein (see p. 20). Fig. 15.

The Nerves and Blood Vessels of the Upper Half of the Body. The Deep Veins and Arteries of the Neck and Thorax.

Fig. 15. The deep veins and arteries of the neck and the large veins and arteries of the thorax. ($^1/_2$)

On each side the Sterno-mastoid, infrahyoid muscles, Mylohyoideus and Digastricus have been cut away. * = Point of formation of the right innominate vein. ** = posterior root of the external jugular vein. + = mucous membrane of the mouth. +* = anastomosis of hypoglossal and lingual nerves. × (on the vein) = opening of the anterior jugular vein into the external jugular.

The Deep Veins of the Neck and the Innominate Veins.

(Cont. from p. 19.)

II. The *subclavian vein* is the direct continuation of the axillary vein. It does not run in immediate contact with the subclavian artery, but is separated from it by the insertion of the Scalenus anterior. It forms a flat arch and, behind the sterno-clavicular joint, unites with the internal jugular to form the innominate vein. In its other relations it does not entirely correspond with the artery (see p. 9, 10, Fig. 13, 15, 17), receiving as a rule only the external jugular, which opens into its terminal portion. Only occasionally do the superficial cervical, transverse scapular and transversa colli veins open into it, passing as a rule to the external jugular.

III. The *left innominate (anonyma) vein* arises behind the left sterno-clavicular joint by the union of the left internal jugular, the external jugular and the subclavian, and passes obliquely, behind the manubrium sterni, to behind the first right costal cartilage, where it unites with the right innominate to form the superior vena cava. Fig. 9, 10, 13, 15. Its tributaries, in addition to the three main trunks by which it is formed, are:

1. Occasionally *inferior thyreoid veins* from the lower portion of the lobes of the thyreoid gland. They are variable and usually quite small.

2. The *v. thyreoidea ima* arises from the unpaired venous plexus of the thyreoid and passes downwards, practically in the median line, in front of the trachea. Fig. 14, 15.

3. Small thymic, pericardial, tracheal, oesophageal, etc. veins. Fig. 15.

4. The *vertebral vein*, a small vein accompanying the vertebral artery through the foramina transversaria of the cervical vertebrae. It does not drain the skull however, but takes its origin mainly from the external vertebral plexuses. Fig. 13, 15.

5. The *deep cervical vein*, a large vein corresponding to the artery of the same name. It runs downwards between the middle and deep muscles of the back of the neck, arising from the same plexus as the vertebral vein and also from the occipital vein. It usually receives the vertebral vein before opening into the innominate. Fig. 15.

6. The *internal mammary vein* accompanying the artery of the same name (see p. 31).

IV. The *right innominate (anonyma) vein* is shorter than the left and has a more vertical course. It receives the same veins as the left, except Nos. 2 and 3. Fig. 15, 20, 21.

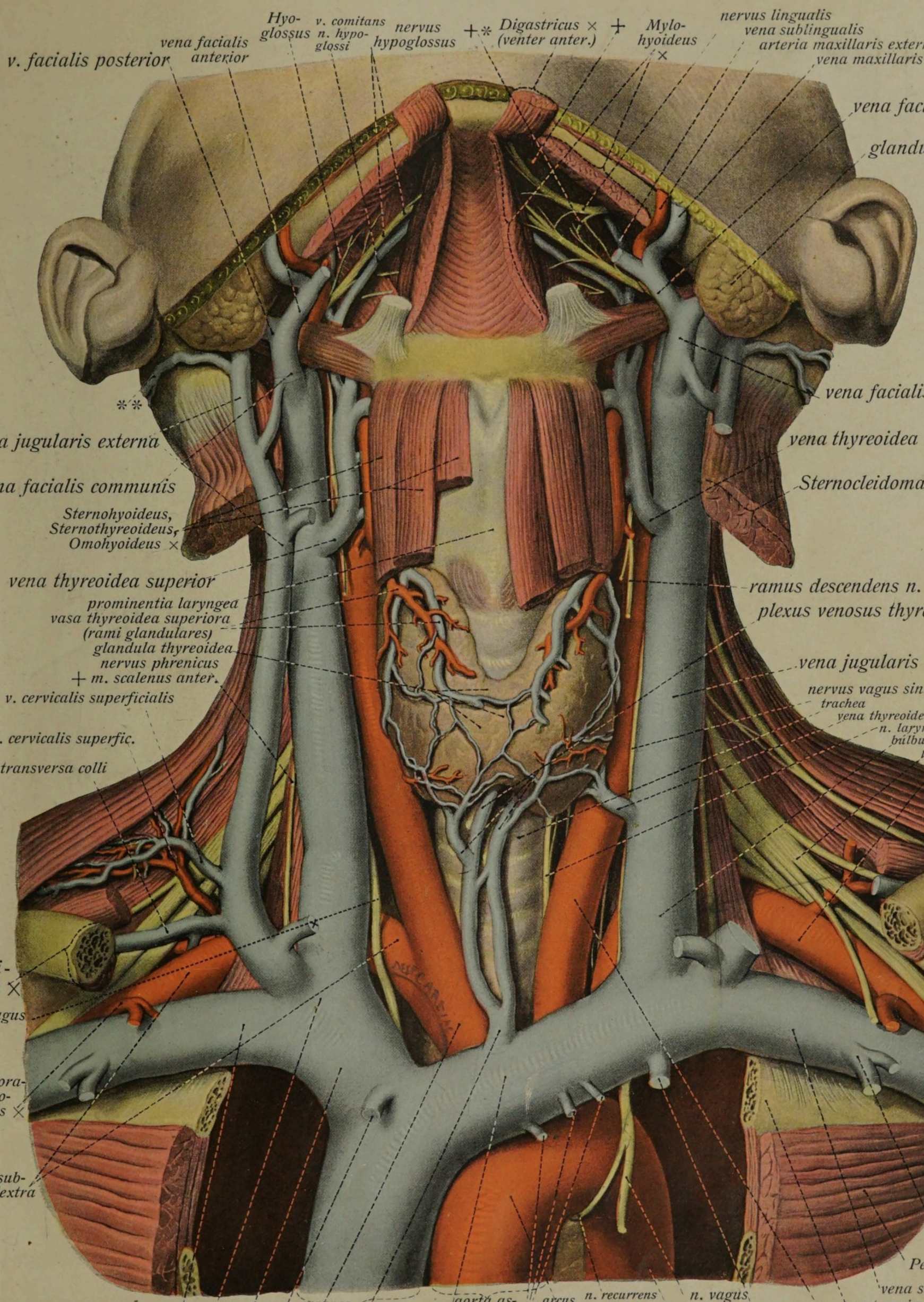
v. facialis posterior
vena facialis anterior
Hyoglossus
v. comitans n. hypoglossi
nervus hypoglossus
Digastricus (venter anter.)
Mylohyoideus
nervus lingualis
vena sublingualis
arteria maxillaris externa
vena maxillaris externa
vena facialis anterior
glandula parotis
vena facialis communis
vena jugularis externa
vena thyreoidea superior
Sternocleidomastoideus
Sternohyoideus, Sternothyreoideus, Omohyoideus
vena thyreoidea superior
ramus descendens n. hypoglossi
plexus venosus thyreoideus impar
prominentia laryngea
vasa thyreoidea superiora (rami glandulares)
glandula thyreoidea
nervus phrenicus
m. scalenus anter.
vena jugularis interna sinistra
v. cervicalis superficialis
nervus vagus sinister
trachea
vena thyreoidea inferior
n. laryngeus inferior
bulbus infer. v. jug. int.
plexus brachialis
a. subclavia sinistra
a. cervicalis superfic.
v. transversa colli
clavicula
clavicula
n. vagus
rt. thoracoacromialis
art. subclavia dextra
vena cephalica
Pectoralis major
vena subclavia sin.
costa prima
art. carotis communis sinistra
vena subclavia dextra
vena anonyma dextra
vena mammaria interna dextra
arteria anonyma
vena thyreoidea ima
vena cava super.
aorta ascendens
vena anonyma sinistra
arcus aortae
venae thymicae
n. recurrens sinister
n. vagus sinister
aorta thoracalis descendens
vena mammaria interna sinistra

Fig. 15.

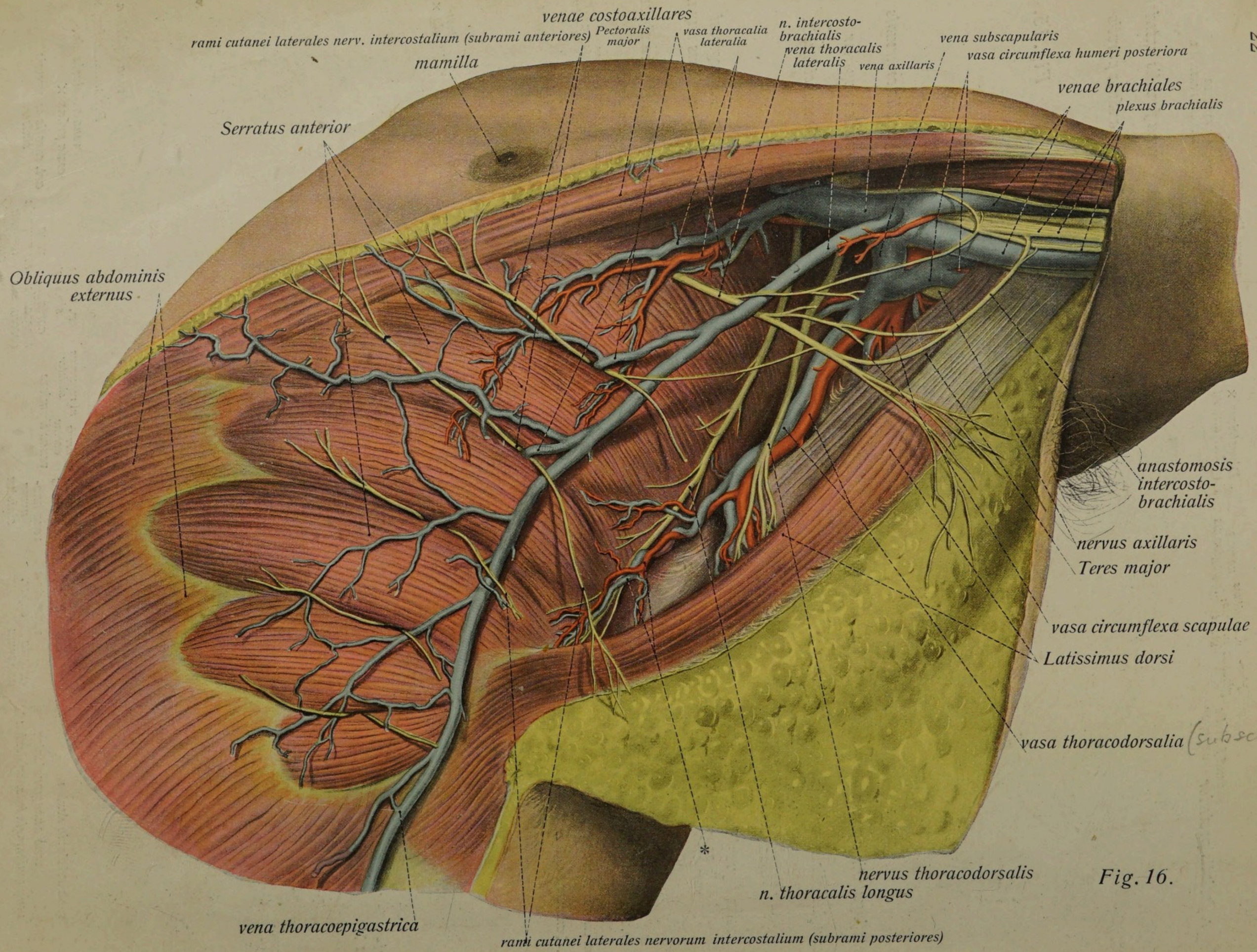

Fig. 16.

Fig. 16. Superficial layer of vessels and nerves in the axilla. (1/2)
The skin and fat have been reflected below the lower border of the Pectoralis major and the superficial fascia has been removed. * = twigs of the thoraco-dorsal vessels that go to the chest wall and the Serratus anterior.

The Nerves and Blood Vessels of the Upper Half of the Body.
The Blood Vessels and Nerves of the Axilla.

The Axillary Vein.

The *axillary vein* is formed by the union of the two brachial veins and runs through the axilla, medial to and in front of the axillary artery, to open into the subclavian vein (see p. 19) behind the Subclavius. Fig. 13, 14, 15 (not labelled), 18, 19. Its roots are:

1. The *cephalic vein*, a cutaneous vein of the arm (see p. 40). Fig. 8—10, 13—17, 28—30.

2. The *thoraco-acromial vein*, corresponding to the artery of the same name; it usually opens into the preceding. Fig. 10, 13—17.

3. The *lateral thoracic vein*, usually a partly doubled, superficial vein, which is often reinforced by a *thoraco-epigastric vein* (a large cutaneous vein from the abdominal wall) and by *costo-axillary veins*. (Anastomoses with the upper intercostal veins.) Fig. 13—17.

4. Veins which accompany the branches of the axiliary artery *(subscapular, thoraco-dorsal, circumflex scapular and humeral circumflex* veins). Fig. 13—17.

The Axillary Artery.

The axillary artery is the direct continuation of the subclavian and at the lower end of the axilla is directly continued into the brachial artery. Fig. 10, 11, 13—17, 26, 33, 34. Its branches are:

1. The *thoraco-acromial* arises at the upper border of the Pectoralis minor and runs with the cephalic vein in the subclavicular groove. Fig. 8, 10, 17. Its branches are:

a) The *acromial* branch, passes beneath the Deltoideus to the acromial rete. Fig. 17.

b) The *deltoid* branch accompanies the cephalic vein in the deltoideo-pectoral trigone. Fig. 8, 17.

c) *Pectoral* branches to the Pectoral muscles (an occasional branch arising directly from the axillary artery is termed the supreme thoracic artery). Fig. 17.

2. The *lateral (long) thoracic* passes downwards on the thoracic wall, resting on the Serratus anterior (often partly replaced by branches of the thoraco-dorsal). Fig. 13, 16, 17.

3. The *subscapular* a large, short vessel, quickly dividing into its terminal branches. Fig. 16.

a) The *thoraco-dorsal* runs downwards parallel to the axillary border of the scapula between the Serratus anterior and the Latissimus dorsi, supplying the latter and the Teres major. (Anastomoses with the lateral thoracic, transversa colli, etc.) Fig. 16, 17, 26.

b) The *circumflex scapular* passes through the medial muscular foramen to the dorsum of the scapula, supplying the Subscapularis, Teres major, Teres minor, long head of the Triceps and the Infraspinatus. Its terminal branches anastomose in the infraspinatus fossa with the transverse scapular artery. Fig. 16, 17, 27.

Fig. 16. Superficial layer of vessels and nerves in the axilla. (1/2)
The skin and fat have been reflected below the lower border of the Pectoralis major and the superficial fascia has been removed. * = twigs of the thoraco-dorsal vessels that go to the chest wall and the Serratus anterior.

The Nerves and Blood Vessels of the Upper Half of the Body.
The Blood Vessels and Nerves of the Axilla. (Cont.)

Fig. 17. The deep layer of vessels and nerves in the axilla. (1/2)
The Pectoralis major and the Sterno-mastoideus are cut and reflected.
* = phrenic nerve, ** = Scalenus anterior, + = clavicle.

The Axillary Artery. (Cont.)

4. The *anterior humeral circumflex*, rather small, passes around the anterior surface of the surgical neck of the humerus supplying the neighboring muscles. Fig. 26, 33.

5. The *posterior humeral circumflex* arises opposite the preceding from the terminal part of the axillary. It is quite large, curves backwards around the surgical neck of the humerus and passes with the axillary (circumflex) nerve through the lateral muscular foramen. It accompanies the axillary (circumflex) nerve and branches with this to the Deltoideus and the neighboring muscles. It makes many anastomoses. Fig. 16, 26, 27, 36.

The Brachial Plexus, Supraclavicular Portion.

1. The *anterior thoracic nerves* are 2—3 moderately large nerves that pass behind the clavicle to the Pectoralis major and minor. Fig. 9, 10, 17. A slender *subclavian* nerve goes to the Subclavius.

2. The *posterior thoracic nerves* divide into two branches:

a) The *dorsal scapular*, which accompanies the descending branch of the a. transversa colli and passes with it to the Levator scapulae (lower dentation) and to the Rhomboidei. Fig. 23, 25.

b) The *long thoracic nerve* passes down upon the Serratus anterior, some distance away from the lateral (long) thoracic artery, supplying the muscle. Fig. 13, 16, 17.

3. The *suprascapular nerve* passes with the transverse scapular artery through the supraclavicular fossa to the scapular notch, where it passes under the superior transverse ligament and supplies the Supraspinatus and Infraspinatus. Fig. 15, 26, 27.

4. The *subscapular nerves*, several small branches to the Subscapularis and Teres major, a larger *thoraco-dorsal* nerve passing to the Latissimus dorsi with the vessels of the same name. Fig. 16, 17, 26, 27.

5. The *axillary (circumflex) nerve* is the strongest nerve of the supraclavicular portion. It arises in conjunction with the posterior bundle of the infraclavicular portion and accompanies the posterior humeral circumflex artery through the lateral muscle foramen to be supplied to the Deltoideus, a branch also going to the Teres minor. In addition to these muscular branches it gives off a cutaneous branch, which bends around the posterior border of the Deltoideus and supplies the skin over the insertion of that muscle and that of the neighboring parts of the upper arm. Fig. 16, 26, 27, 33, 34.

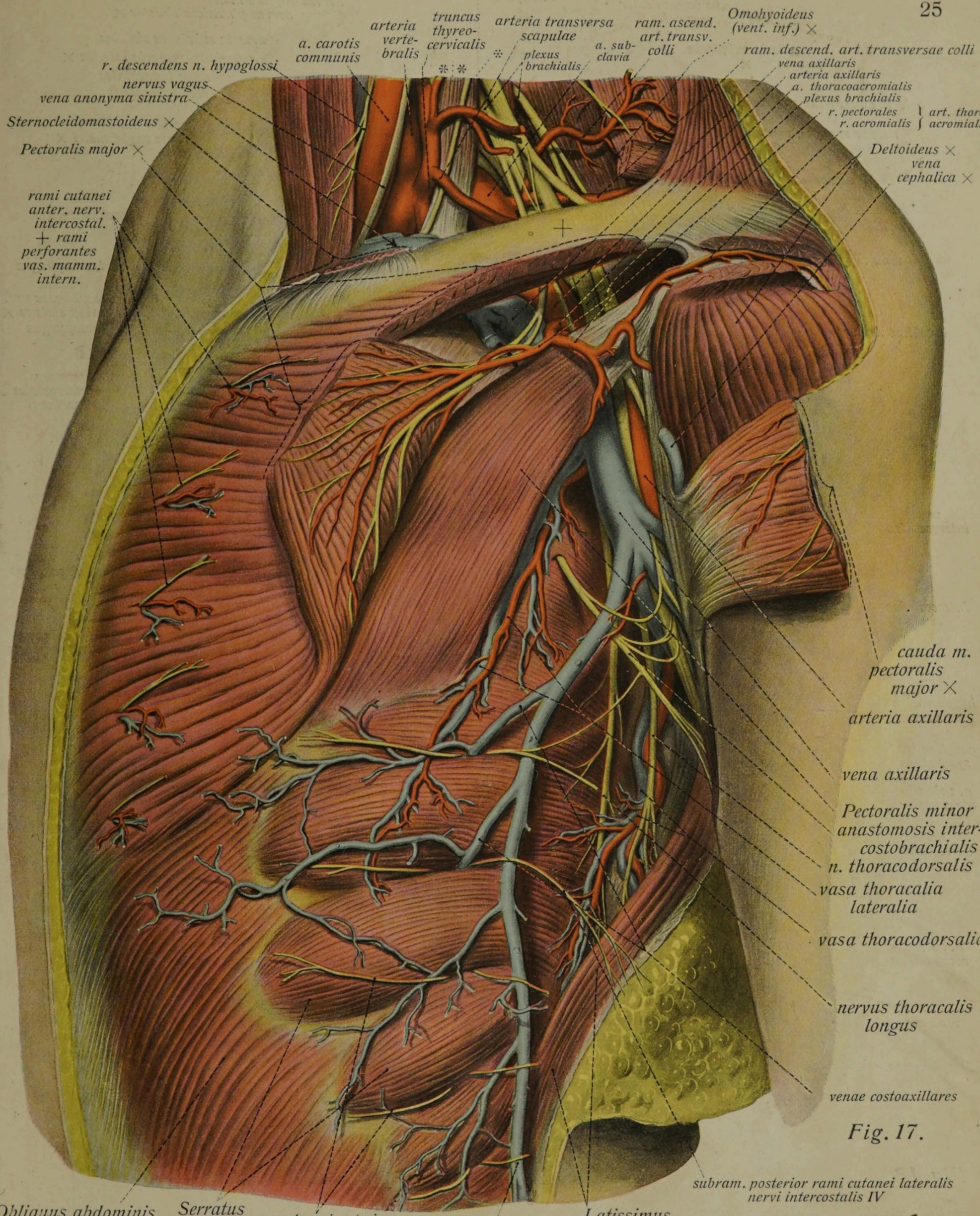
r. descendens n. hypoglossi
nervus vagus
vena anonyma sinistra
Sternocleidomastoideus ×
Pectoralis major ×
rami cutanei anter. nerv. intercostal. + rami perforantes vas. mamm. intern.
a. carotis communis
arteria vertebralis
truncus thyreo-cervicalis
arteria transversa scapulae
plexus brachialis
a. subclavia
ram. ascend. art. transv. colli
Omohyoideus (vent. inf.) ×
ram. descend. art. transversae colli
vena axillaris
arteria axillaris
a. thoracoacromialis
plexus brachialis
r. pectorales
r. acromialis
art. thoraco-acromialis
Deltoideus ×
vena cephalica ×
cauda m. pectoralis major ×
arteria axillaris
vena axillaris
Pectoralis minor
anastomosis inter-costobrachialis
n. thoracodorsalis
vasa thoracalia lateralia
vasa thoracodorsalia
nervus thoracalis longus
venae costoaxillares
subram. posterior rami cutanei lateralis nervi intercostalis IV
Obliquus abdominis externus
Serratus anterior
subrami anteriores ramorum cutan. lateral. nn. intercost.
vena thoraco-epigastrica
Latissimus dorsi

Fig. 17.

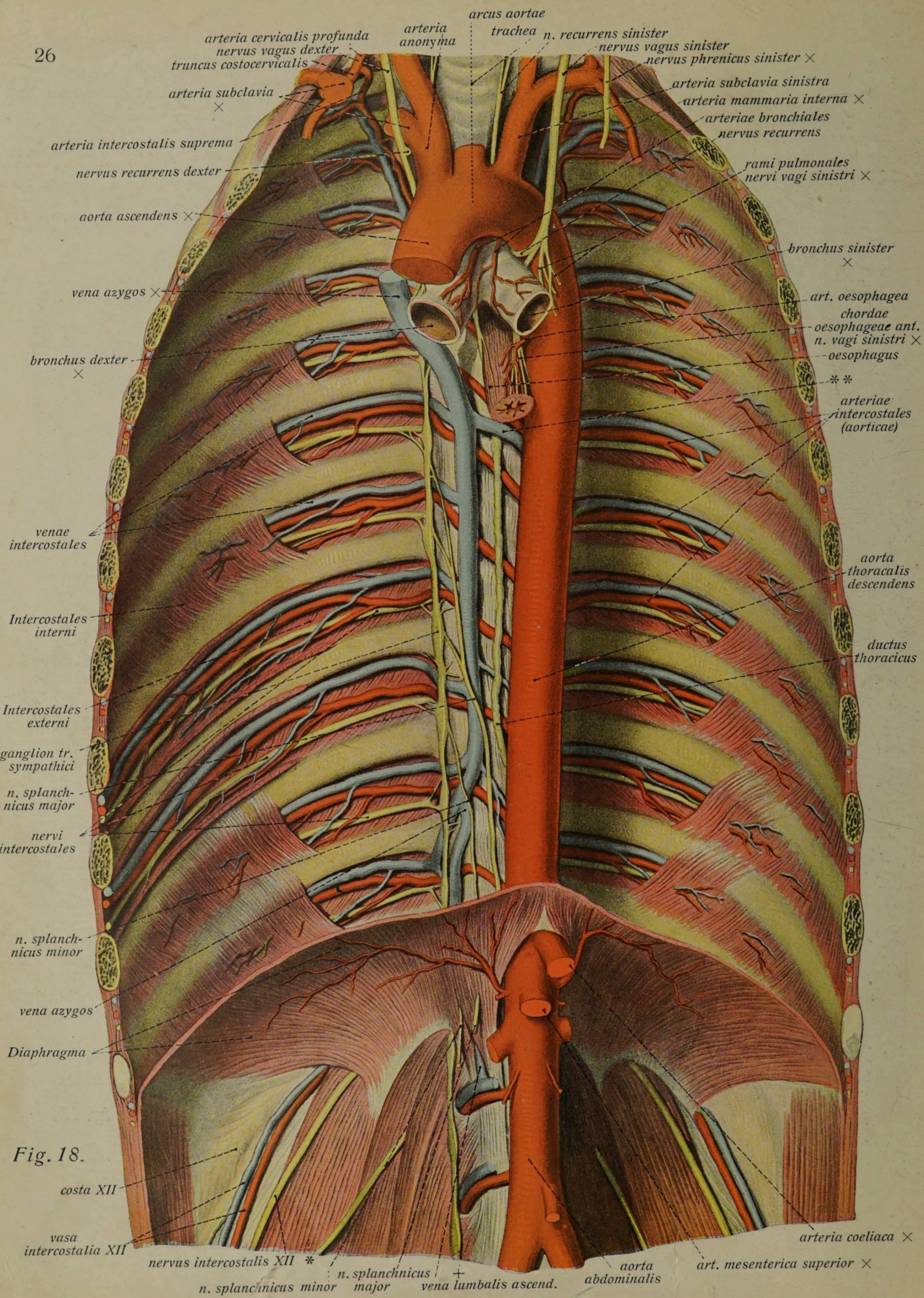
arcus aortae
arteria anonyma
trachea
n. recurrens sinister
arteria cervicalis profunda
nervus vagus dexter
truncus costocervicalis
nervus vagus sinister
nervus phrenicus sinister ×
arteria subclavia ×
arteria subclavia sinistra
arteria mammaria interna ×
arteriae bronchiales
nervus recurrens
arteria intercostalis suprema
nervus recurrens dexter
rami pulmonales
nervi vagi sinistri ×
aorta ascendens ×
bronchus sinister ×
vena azygos ×
art. oesophagea
chordae oesophageae ant.
n. vagi sinistri ×
bronchus dexter ×
oesophagus
* *
arteriae intercostales (aorticae)
venae intercostales
aorta thoracalis descendens
Intercostales interni
ductus thoracicus
Intercostales externi
ganglion tr. sympathici
n. splanchnicus major
nervi intercostales
n. splanchnicus minor
vena azygos
Diaphragma
costa XII
vasa intercostalia XII
nervus intercostalis XII *
n. splanchnicus minor
n. splanchnicus major
+
vena lumbalis ascend.
aorta abdominalis
art. mesenterica superior ×
arteria coeliaca ×

Fig. 18.

The Nerves and Blood Vessels of the Posterior Thoracic Wall and of the Superior Mediastinum.

Fig. 18. The large vessels and nerves of the posterior thoracic wall, from in front and somewhat from the right. ($^1/_3$)

* = ilio-hypogastric nerve. ** = connection between the azygos and hemiazygos veins. + = Lumbar ganglion of the sympathetic trunk.

The Thoracic Aorta.

The *thoracic aorta* is the portion of the aorta above the diaphragm and may be divided into three portions: 1. the *ascending aorta*, 2. the *aortic arch* and 3. the *descending* aorta, which passes at the diaphragm directly into the abdominal aorta.

I. The *ascending aorta* is contained within the pericardium (Fig. 4, 5) and gives off only the coronary arteries of the heart, these arising from it immediately above its origin, from the bulbus aortae (Fig. 4).

II. The aortic arch lies outside the pericardium in the superior mediastinum and forms an arch convex upwards, which, at its left and posterior end, passes directly into the descending aorta. Its main branches, the three great trunks for the upper parts of the body, arise from the convex surface of the arch, only a number of small arteries to the neighbouring viscera arising from the concave surface. Fig. 4, 5, 15, 18. The branches of the aorta are:

a) From its convexity:

1. The *innominate (anonyma) artery* arises immediately after the aorta emerges from the pericardium, somewhat to the left of the median line. It is the largest branch of the aorta and gives rise to the arteries for the right upper half of the body. It passes behind the left innominate vein and crosses in front of the thoracic portion of the trachea at an acute angle, to the posterior surface of the right sterno-clavicular joint, where it divides into its two terminal branches, the right common carotid and the right subclavian arteries. Normally is does not give off any lateral branches. Fig. 11, 13, 18, 20.

2. The *left common carotid artery* arises from the aortic arch close to the innominate artery and ascends almost vertically upwards in the neck, along the left surface of the trachea.

3. The *left subclavian artery* arises to the left of the left common carotid and runs to the posterior surface of the left sterno-clavicular joint (see p. 11 and Fig. 8—11, 13—15, 17, 18).

b) From the concavity of the arch:

1. *Bronchial arteries* to the bronchi and the hilus of the lung. Fig. 18. 2. *Oesophageal arteries* to the thoracic portion of the oesophagus. Fig. 18. 3. *Pericardial branches* to the pericardium.

All these small visceral branches may arise from the upper part of the descending aorta.

III. The *descending aorta* is the direct continuation of the aortic arch and at its origin is connected with the bifurcation of the pulmonary artery by a ligamentum arteriosum (Botalli). Fig. 4, 5. At first it lies decidedly to the left of the median line, but gradually approaches this below, until at its entrance into the aortic opening of the diaphragm it is almost median in position. It is crossed at an acute angle by the oesophagus. Fig. 15, 18, 20, 117. Its branches are:

1. Small *parietal branches (superior phrenic* and *mediastinal arteries)* to the diaphragm and the mediastinal structures.

2. The third to the twelfth *right* and *left intercostal arteries*. These take their origin, the right and left close together, from the posterior wall of the aorta; the right cross the median line lying on the bodies of the vertebrae and are consequently longer than the left. Each divides into an *anterior branch*, the actual intercostal, and a weak *posterior branch* that passes to the back. Fig. 18, 22.

The Nerves and Blood Vessels of the Thorax.

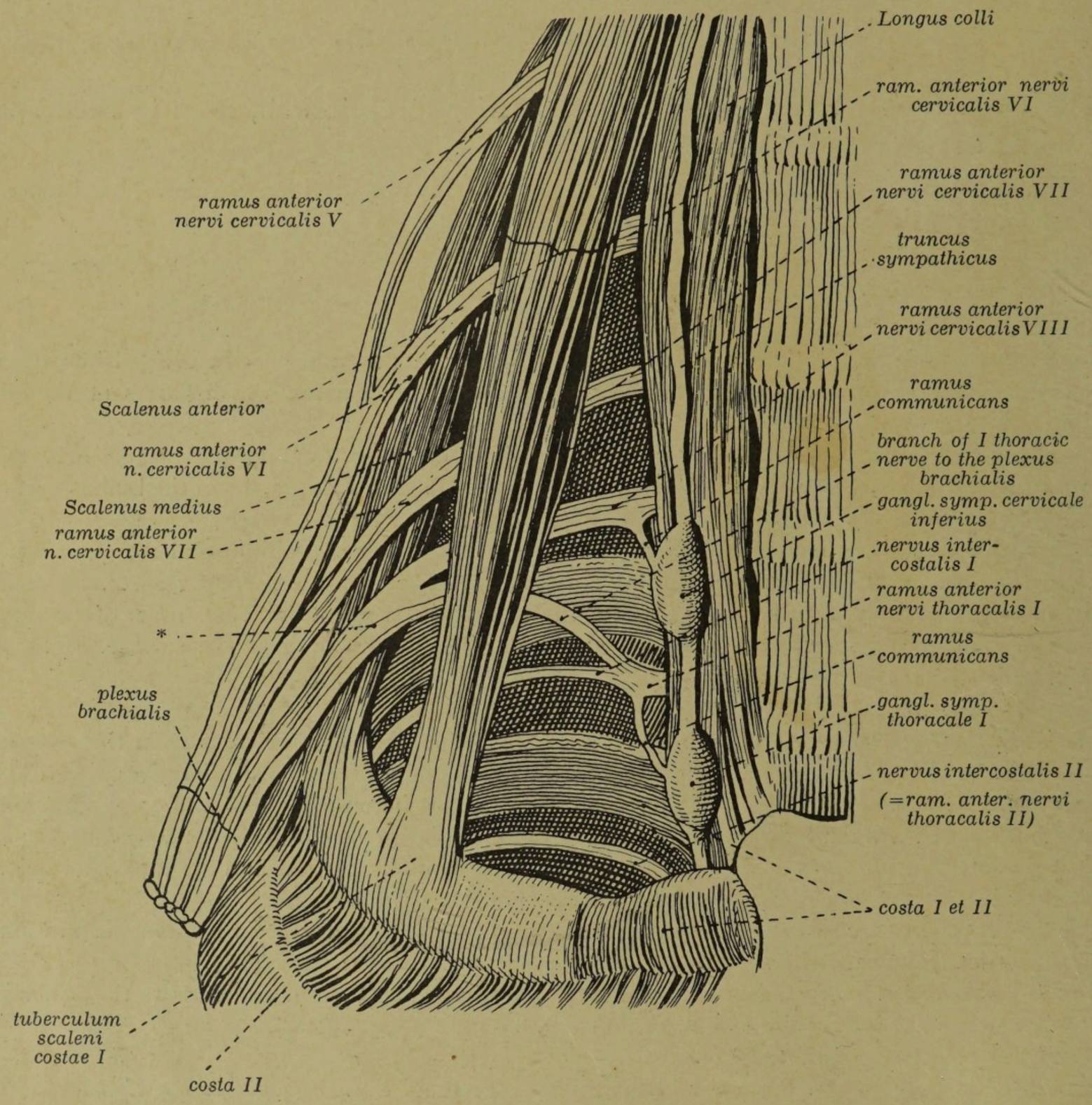

Fig. 19. The relations of the upper thoracic nerves to the brachial plexus (semi-schematic).

* = trunk of the brachial plexus formed by the anterior ramus of the eighth cervical nerve and the principal part of the same ramus of the first thoracic nerve.

The anterior ramus of the first thoracic nerve forms only a small part of the first intercostal nerve, which is small in accordance with the narrowness of the first intercostal space; for the most part it unites with the anterior ramus of the eighth cervical nerve to take part in the formation of the brachial plexus. Fig. 12 (see also p. 32).

The Cutaneous Branches of the Intercostal Nerves.

The intercostal nerves (see p. 32) give off two series of cutaneous nerves. There is a strong series, the *lateral cutaneous branches*, in the axillary line, emerging between the serrations of the Serratus anterior and dividing each into an anterior and a posterior branch; the weaker, *anterior cutaneous branches* emerge with the perforating branches of the internal mammary artery. Fig. 14, 16, 17.

Fig. 20. The course of the phrenic nerves through the thorax to the diaphragm. (1/3) The thoracic wall is cut lateral to the mammary line; the right lung is divided in the plane of the section, the left partly in a deeper plane. The pericardial pleurae are dissected from the pericardium to show the phrenic nerves and the pleuro-pericardial vessels; half of the left innominate vein is removed and the musculature of the diaphragm split along the branches of the phrenic nerve.

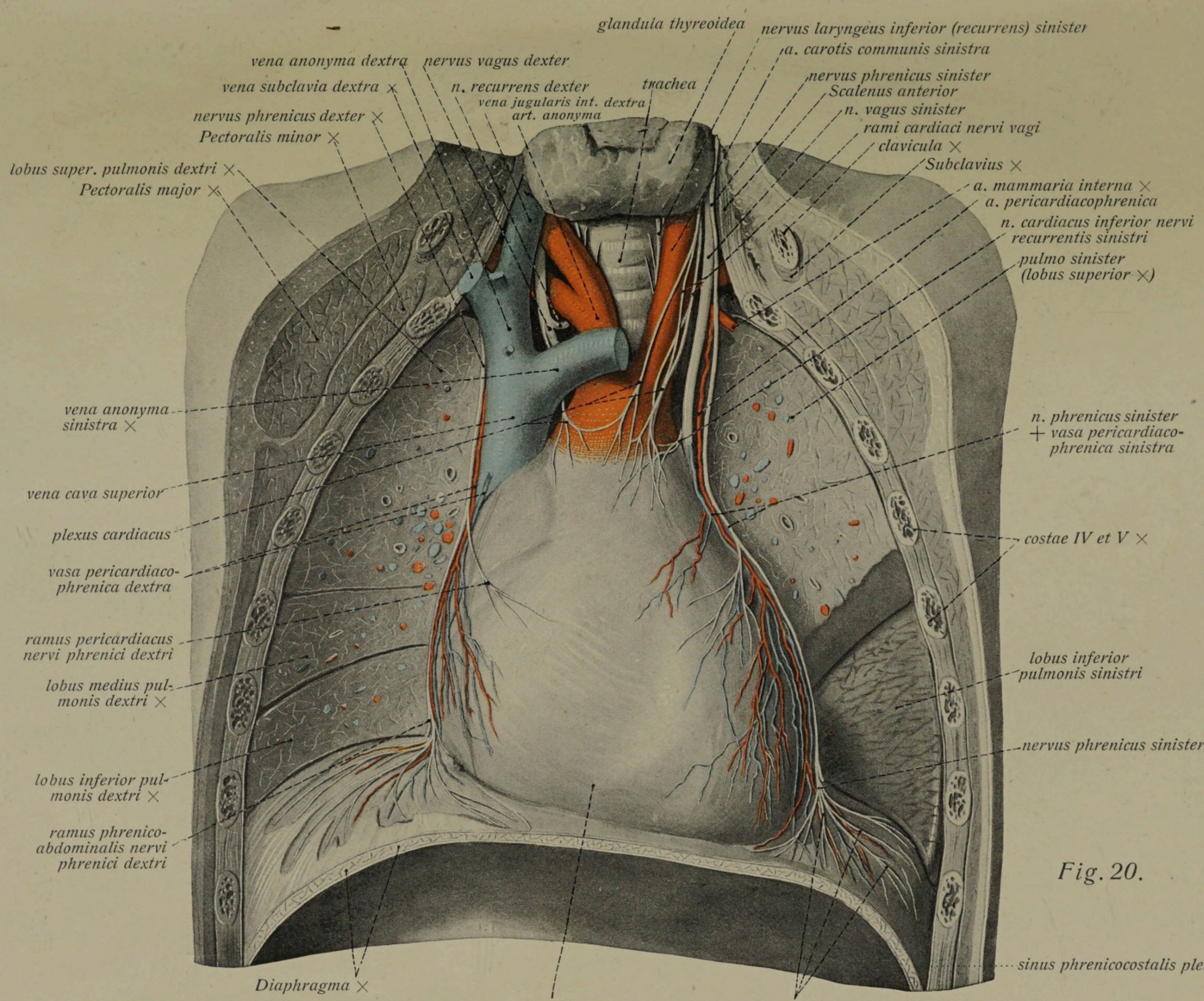
glandula thyreoidea
nervus laryngeus inferior (recurrens) sinister
a. carotis communis sinistra
vena anonyma dextra
nervus vagus dexter
vena subclavia dextra
n. recurrens dexter
vena jugularis int. dextra
art. anonyma
trachea
nervus phrenicus sinister
Scalenus anterior
n. vagus sinister
nervus phrenicus dexter
rami cardiaci nervi vagi
Pectoralis minor
clavicula
lobus super. pulmonis dextri
Subclavius
Pectoralis major
a. mammaria interna
a. pericardiacophrenica
n. cardiacus inferior nervi recurrentis sinistri
pulmo sinister (lobus superior)
vena anonyma sinistra
n. phrenicus sinister + vasa pericardiaco-phrenica sinistra
vena cava superior
plexus cardiacus
costae IV et V
vasa pericardiaco-phrenica dextra
ramus pericardiacus nervi phrenici dextri
lobus inferior pulmonis sinistri
lobus medius pulmonis dextri
nervus phrenicus sinister
lobus inferior pulmonis dextri
nervus phrenicus sinister
ramus phrenico-abdominalis nervi phrenici dextri
sinus phrenicocostalis pleurae
Diaphragma
pericardium
rami musculares nervi phrenici sinistri

Fig. 20.

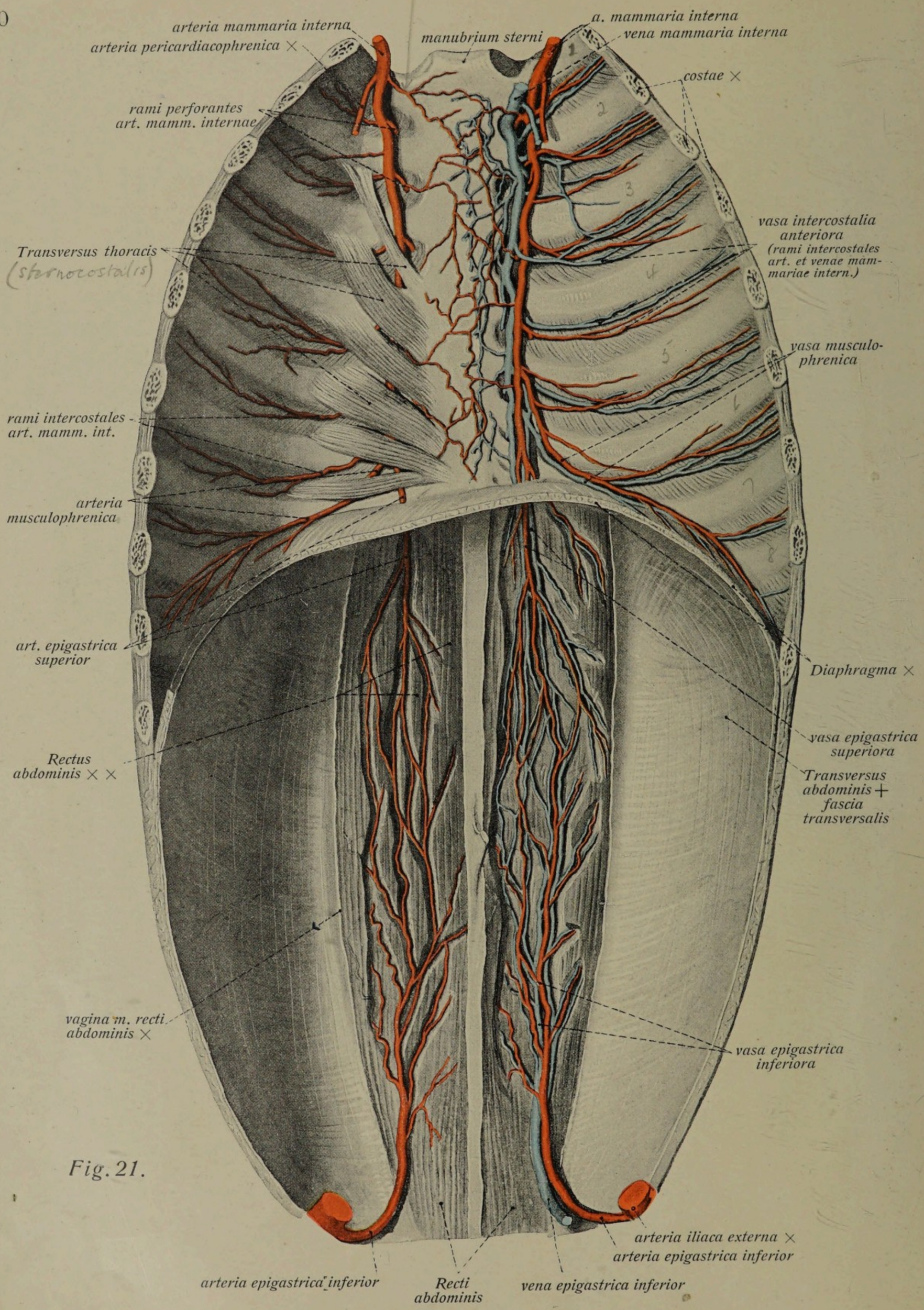
arteria mammaria interna
arteria pericardiacophrenica ×
manubrium sterni
a. mammaria interna
vena mammaria interna
costae ×
rami perforantes
art. mamm. internae
Transversus thoracis
(sternocostalis)
vasa intercostalia
anteriora
(rami intercostales
art. et venae mam-
mariae intern.)
vasa musculo-
phrenica
rami intercostales
art. mamm. int.
arteria
musculophrenica
art. epigastrica
superior
Diaphragma ×
Rectus
abdominis × ×
vasa epigastrica
superiora
Transversus
abdominis +
fascia
transversalis
vagina m. recti
abdominis ×
vasa epigastrica
inferiora
arteria iliaca externa ×
arteria epigastrica inferior
arteria epigastrica inferior
Recti
abdominis
vena epigastrica inferior

Fig. 21.

The Blood Vessels of the Thoracic Wall.

Fig. 21. The blood vessels of the anterior thoracic and abdominal walls. ($^1/_3$)

The posterior thoracic and abdominal walls are removed by a frontal section and the viscera cut away; the portion of the diaphragm in front of the plane of section is retained. One looks from behind on the posterior surface of the anterior thoracic and abdominal walls. On the left only the arteries are shown; on the right the veins also. In addition the Transversus thoracis is removed on the right to expose the internal mammary vessels. The Rectus abdominis is divided over the branches of the epigastric vessels (superior and inferior) to show the anastomosis ($\times\times$).

The Internal Mammary Artery.

The internal mammary artery arises from the concavity of the subclavian (see p. 11), almost opposite the vertebral artery which runs upwards towards the head, while the internal mammary runs downwards. At first it lies behind the subclavian vein and the sterno-clavicular joint and then passes through the anterior part of the upper aperture of the thorax and comes to lie on the posterior surface of the costal cartilages and the internal intercostal muscles. It runs downwards parallel to the lateral border of the sternum to what is termed Larrey's cleft of the diaphragm, to divide there into its two terminal branches. Posteriorly it lies partly directly on the costal pleura, partly on the Transversus thoracis. Its branches are:

1. Small twigs to the thymus, the trachea and bronchi.

2. The *pericardiaco-phrenic artery* arises from the internal mammary as it enters the upper thoracic aperture and accompanies the phrenic nerve, lying with this between the pericardial pleura and the peritoneum. It supplies the pericardium and also, by its terminal branches, the diaphragm. Fig. II 165, 166, III 19.

3. The *perforating branches* pierce the intercostal muscles close to the border of the sternum and pass between the muscle bundles of the Pectoralis major. The uppermost branch makes its way through the gap between the two heads of origin of the Sternomastoideus. Fig. 7, 14, 17.

4. The *intercostal branches (anterior intercostals)* supply the anterior portion of each intercostal space. They anastomose with the anterior ends of the intercostal (posterior) arteries from the aorta. Fig. 21.

5. The *musculo-phrenic artery*, one of the terminal branches, is the principal supply of the thoracic surface of the diaphragm. Fig. 21.

6. The *superior epigastric artery*, the other terminal branch, pierces the diaphragm and runs downwards on the posterior surface of the anterior abdominal wall, partly in the substance of the Rectus abdominis, in which it ramifies, its terminal branches anastomosing with those of the inferior epigastric artery from the external iliac. Fig. 21.

The **internal mammary vein** corresponds in its course to the artery and the majority of its branches. It lies closely medial to the artery, and is usually a single stem on either side of the body, although at its origin on the diaphragm its branches are doubled companion veins. It opens usually into the left innominate vein. Fig. 21.

The Nerves and Vessels of the Upper Half of the Body. The Vessels and Nerves of the Posterior Thoracic Wall.

Fig. 22. The large venous trunks of the thorax as seen on the posterior thoracic and abdominal wall, from in front and somewhat from the right. (1/3)

The aorta is removed; the superior vena cava is cut just before it enters the pericardium and the inferior vena cava below the diaphragm. The latter is almost completely removed. On the right the internal intercostals are removed in two intercostal spaces. * = transverse connection between the azygos and hemiazygos veins.

The Veins of the Thoracic Cavity. (See p. 20.)

1. The *superior vena cava* is formed behind the first right costal cartilage by the union of the two innominate veins. Before it enters the pericardium it receives on its posterior wall the vena azygos. Fig. II 165, 166, 227—229, III 4, 5, 15, 21.

2. The *vena azygos* begins in the interval between the medial and intermediate crura of the diaphragm, as the continuation of the *right ascending lumbar vein*, and passes upwards on the right lateral surfaces of the thoracic vertebrae in front of the intercostal arteries. It receives the right intercostal veins as far up as the third and is usually connected with the v. hemiazygos. At the level of the third thoracic vertebra it forms a short arch lying almost in the sagittal plane over the root of the right lung and opens into the superior vena cava. The blood from the upper right intercostal spaces flows usually, in part at least, by a *supreme intercostal vein* into the v. azygos, which may also receive the left intercostal veins should the v. hemiazygos be rudimentary. Fig. II 166, III 18, 22, 116.

3. The *vena hemiazygos* arises similarly to the v. azygos from the *left ascending lumbar vein*, but is weaker than the azygos. It runs on the left lateral surface of the thoracic vertebrae to about the sixth or fifth, to pass in a very variable manner behind the aorta to open into the v. azygos. Fig. II 165, III 22.

4. The *accessory hemiazygos vein*, inconstant and very variable in its details, forms a sort of *left supreme intercostal vein*. It receives blood from the upper intercostal veins and opens either into the connection between the azygos and hemiazygos or into the left innominate. Fig. 22.

5. The *intercostal veins* lie above the arteries in the intercostal spaces. Fig. 18, 22.

The Thoracic Duct.

The *thoracic duct* (see p. 327), the chief lymphatic stem of the body, arises from the somewhat inconstant *cisterna (receptaculum) chyli* in front of the first lumbar vertebra. It passes upwards at first behind and then to the right of the descending aorta, between it and the v. azygos and in front of the right intercostal arteries. Fig. 22, 116, 356 (359).

The Intercostal Nerves.

The twelve intercostal nerves, the last of which is below the twelfth rib, lie about midway in the intercostal spaces and between the two layers of muscles. They are the anterior rami of the twelve thoracic spinal nerves[1]); the first intercostal, however, represents only a part of the first thoracic nerve, whose larger part helps to form the brachial plexus (cf. Fig. 19). Fig. 18, 22. For their cutaneous branches see p. 28.

[1]) They do not form any plexus.

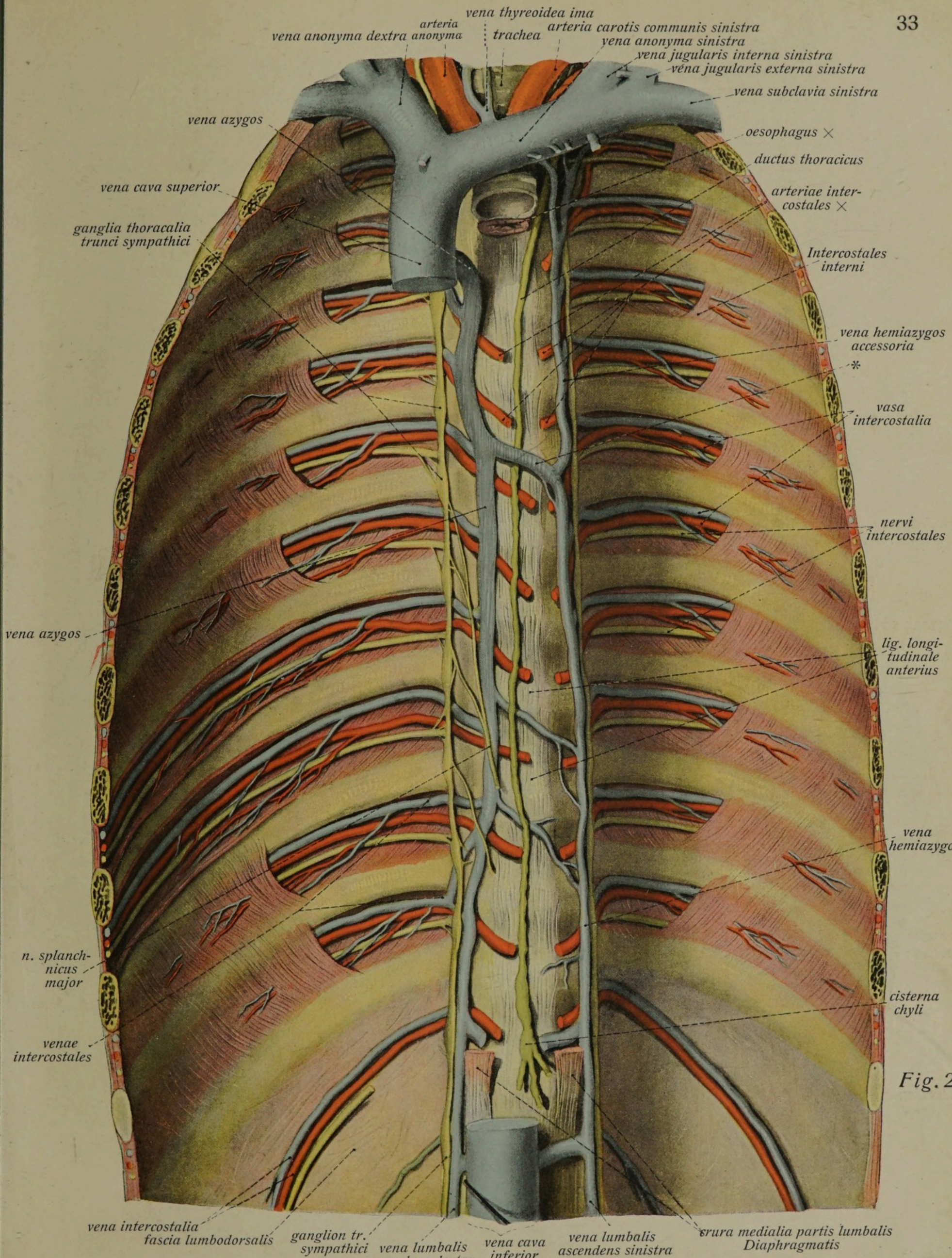
vena thyreoidea ima
arteria anonyma
vena anonyma dextra
trachea
arteria carotis communis sinistra
vena anonyma sinistra
vena jugularis interna sinistra
vena jugularis externa sinistra
vena subclavia sinistra
vena azygos
oesophagus ×
ductus thoracicus
vena cava superior
arteriae intercostales ×
ganglia thoracalia trunci sympathici
Intercostales interni
vena hemiazygos accessoria
*
vasa intercostalia
nervi intercostales
vena azygos
lig. longitudinale anterius
vena hemiazygos
n. splanchnicus major
cisterna chyli
venae intercostales
vena intercostalia
fascia lumbodorsalis
ganglion tr. sympathici
vena lumbalis ascendens dextra
vena cava inferior
vena lumbalis ascendens sinistra
crura medialia partis lumbalis Diaphragmatis

Fig. 22.

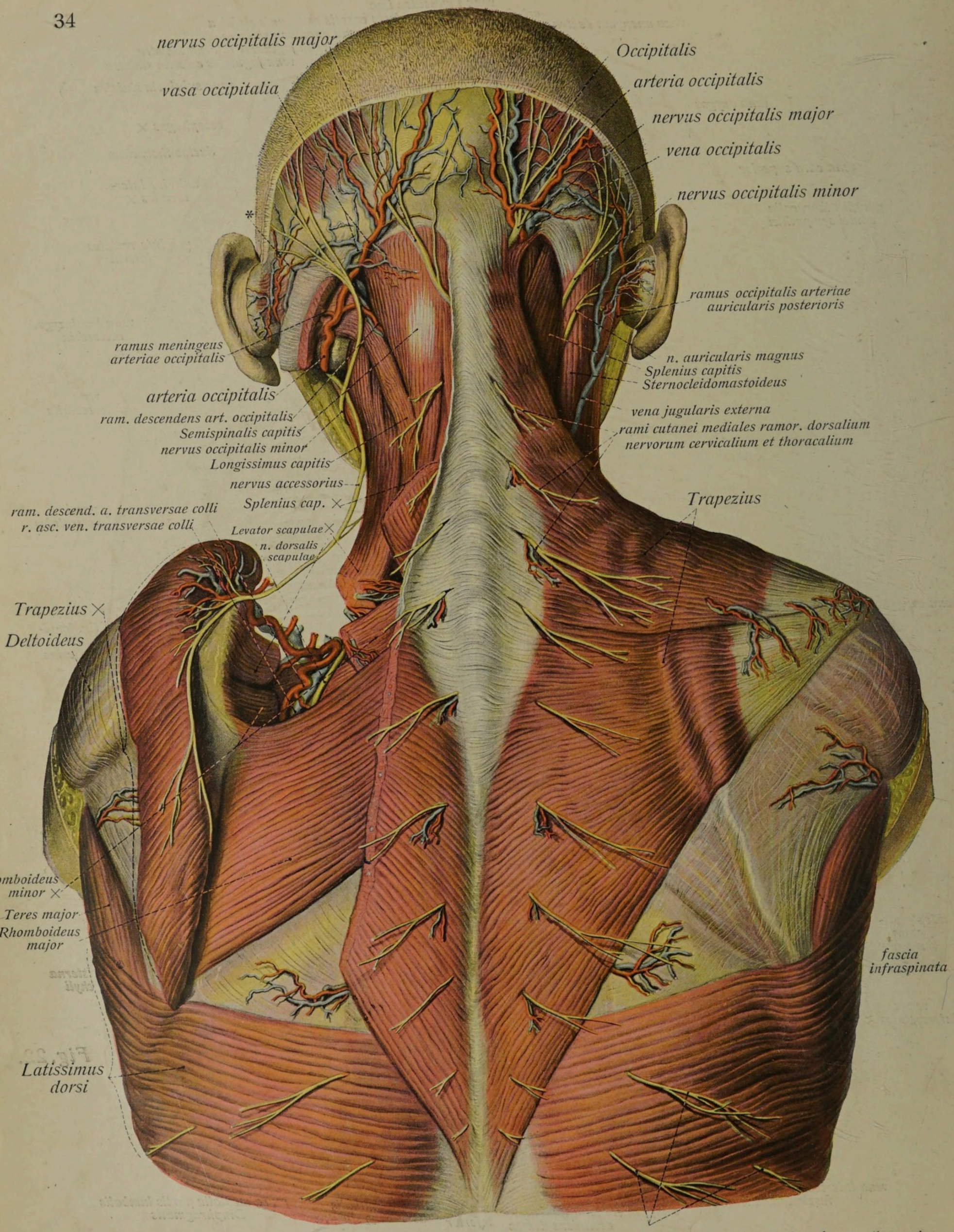
nervus occipitalis major
vasa occipitalia
Occipitalis
arteria occipitalis
nervus occipitalis major
vena occipitalis
nervus occipitalis minor
*
ramus occipitalis arteriae auricularis posterioris
ramus meningeus arteriae occipitalis
n. auricularis magnus
Splenius capitis
Sternocleidomastoideus
arteria occipitalis
ram. descendens art. occipitalis
vena jugularis externa
rami cutanei mediales ramor. dorsalium nervorum cervicalium et thoracalium
Semispinalis capitis
nervus occipitalis minor
Longissimus capitis
nervus accessorius
Splenius cap.
Trapezius
ram. descend. a. transversae colli
r. asc. ven. transversae colli
Levator scapulae
n. dorsalis scapulae
Trapezius
Deltoideus
Rhomboideus minor
Teres major
Rhomboideus major
fascia infraspinata
Latissimus dorsi
rami cutanei laterales ram. dorsal. nerv. thoracal.

Fig. 23.

The Nerves and Blood Vessels of the Upper Half of the Body.
The Nerves and Blood Vessels of the Back.

Fig. 23. The superficial and middle layers of the nerves and vessels of the back. (1/3)
On the left the Trapezius, Sterno-mastoideus, Splenius and Levator scapulae are cut.
* = occipital tributary of the external jugular vein.

Fig. 24. Schema of the Branching of the Spinal Nerves.

Each *spinal nerve* is a mixed nerve, formed from anterior motor and posterior sensory roots (see p. 147). After a short course it divides into an *anterior (ventral)* and a *posterior (dorsal) ramus*, both of which contain both motor and sensory fibres. Except in the 2—3 upper cervical nerves the anterior ramus is much larger than the posterior, and in the cervical, lumbar and sacral regions they form by union with neighboring ventral branches, the cervical, brachial, lumbar and sacral plexuses. The ventral rami of the thoracic nerves form the intercostal nerves, only the first taking part in the formation of the brachial plexus. The ventral rami also send rami communicantes to the adjacent sympathetic ganglia, these, however, being inconstant in the cervical nerves.

The *dorsal rami*, with the exceptions mentioned above, are much weaker than the ventral and do not form plexuses. They penetrate the dorsal musculature, dividing into medial and lateral branches which supply the musculature and may reach the skin by their terminal branches. In the neck and upper part of the back the medial cutaneous branch is the stronger, the lateral frequently not reaching the skin. In the lower part of the back and in the lumbar region the lateral branch is the stronger. The dorsal rami of the sacral nerves are quite weak and almost purely sensory. Fig. 23, 25.

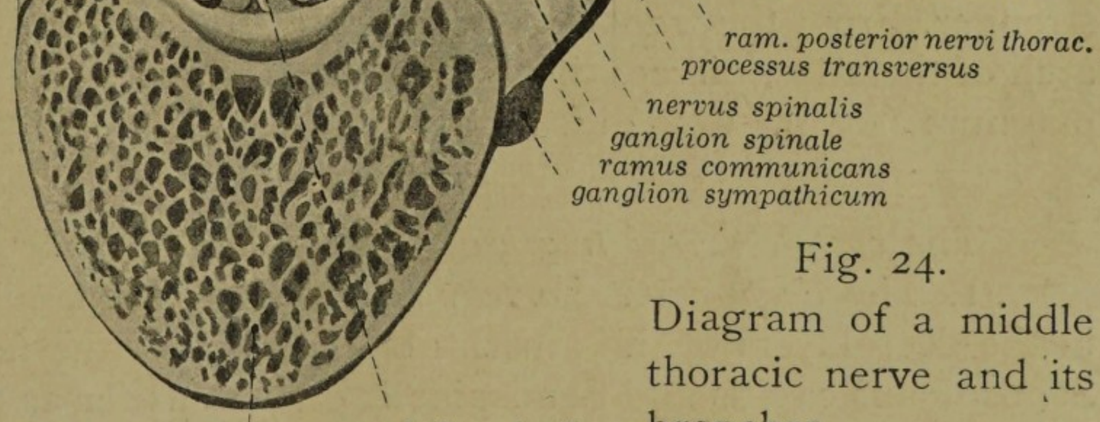

Fig. 24.
Diagram of a middle thoracic nerve and its branches.

The Nerves and Blood Vessels of the Upper Half oft the Body.
The Nerves and Blood Vessels of the Back. (Cont.)

Fig. 25. Deep layer of the nerves and vessels of the back. (3/5)

On both right and left the Semispinalis capitis is cut to expose the suboccipital triangles; the veins are retained on the left. On the right the Trapezius is partly divided, on the left it is cut and the Rhomboidei partly divided.

* = branch of the dorsal scapular nerve to the Levator scapulae.
** = branch of the occipital vein to the mastoid emissary.
\+ = connection between the occipital and external jugular veins.
+* = connection between the 2 and 3 cervical nerves.
I = Multifidus cervicis.
II = Semispinalis cervicis.

The Posterior Rami of the Cervical Nerves.

The following receive special names (see p. 35).

1. The *suboccipital nerve* is the posterior, stronger branch of the first cervical nerve and is purely motor. It enters the suboccipital triangle along side of the vertebral artery, between the occipital bone and the atlas, and supplies the short suboccipital muscles and part of the Semispinalis capitis. Fig. 25.

2. The *greater occipital nerve* is the terminal sensory portion of the strong posterior branch of the second cervical nerve which, together with the suboccipital nerve, supplies the muscles of the back of the neck. It unites with a portion of the third cervical nerve (+*) and, piercing the Semispinalis capitis and the Trapezius and running medial to the occipital artery, supplies the scalp in the occipital region and as far upwards as the vertex. Fig. 7—11, 23, 25.

The *vertebral artery* in the neck (see p. 11 and 164). During its course through the foramina of the transverse processes of the cervical vertebrae (Fig. 11) the vertebral artery gives off *spinal branches* to the spinal cord, as well as *muscular branches* to the muscles of the back of the neck, the branches from the upper part of the artery being the stronger. From the transverse foramen of the atlas it bends in an arch over the posterior arch of the atlas, pierces the posterior atlanto-occipital membrane and enters the foramen magnum (see p. 164). Fig. 11, 25.

The *costo-cervical trunk* of the *subclavian artery* (cf. p. 12).

1. The *deep cervical artery* accompanies the similarly named, but much larger vein in the deep layers of the muscles of the back of the neck, passing upwards between the Semispinalis capitis and Semispinalis cervicis as far as the level of the axis (epistropheus). It may be entirely or partly replaced by posterior branches of the ascending cervical artery. Fig. 25.

2. The *supreme intercostal artery* runs backwards and downwards in front of the neck of the first rib and divides into the intercostal arteries that supply the first and second intercostal spaces. Fig. 11, 18.

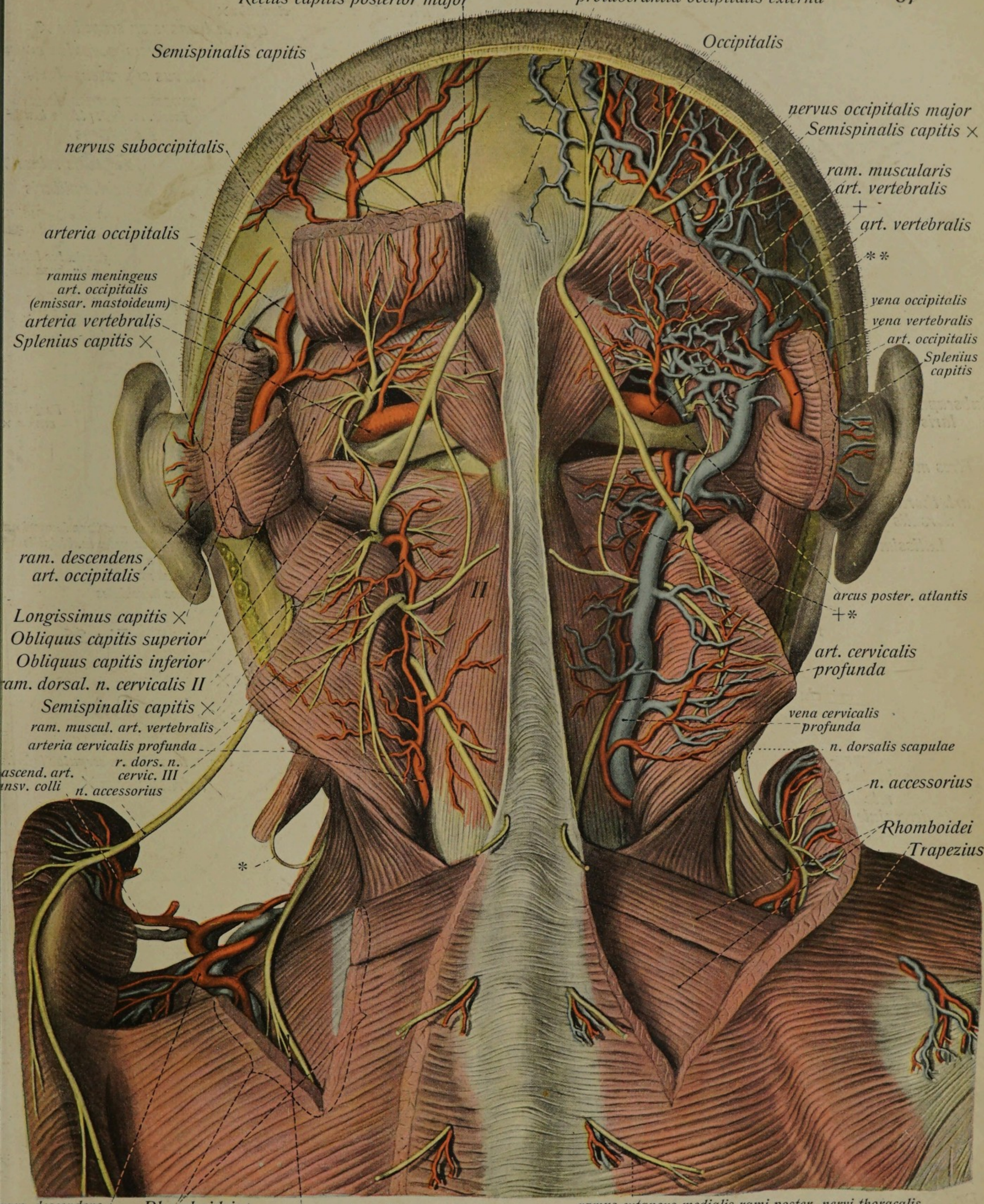
Rectus capitis posterior major
protuberantia occipitalis externa
Semispinalis capitis
Occipitalis
nervus occipitalis major
Semispinalis capitis ×
nervus suboccipitalis
ram. muscularis
art. vertebralis
+ -
art. vertebralis
arteria occipitalis
* *
ramus meningeus
art. occipitalis
(emissar. mastoideum)
vena occipitalis
arteria vertebralis
vena vertebralis
art. occipitalis
Splenius capitis ×
Splenius capitis
ram. descendens
art. occipitalis
II
arcus poster. atlantis
+ *
Longissimus capitis ×
Obliquus capitis superior
Obliquus capitis inferior
ram. dorsal. n. cervicalis II
Semispinalis capitis ×
art. cervicalis profunda
vena cervicalis profunda
ram. muscul. art. vertebralis
arteria cervicalis profunda
n. dorsalis scapulae
r. dors. n. cervic. III
ascend. art.
nsv. colli
n. accessorius
n. accessorius
Rhomboidei
Trapezius
*
ram. descendens
art. transversae colli
Rhomboidei ×
nervus dorsalis scapulae
ramus cutaneus medialis rami poster. nervi thoracalis

Fig. 25.

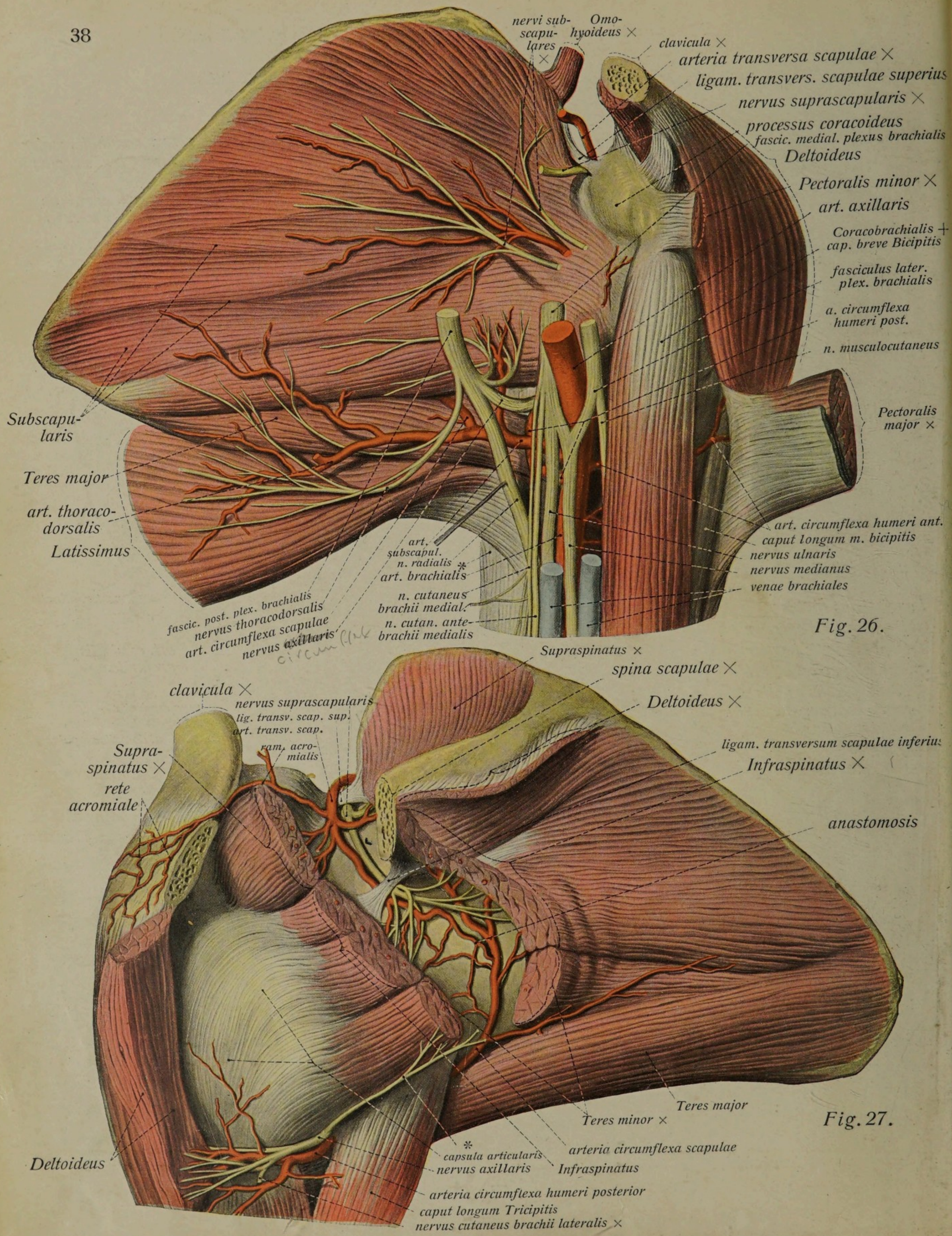
nervi sub-scapu-lares ×
Omo-hyoideus ×
clavicula ×
arteria transversa scapulae ×
ligam. transvers. scapulae superius
nervus suprascapularis ×
processus coracoideus
fascic. medial. plexus brachialis
Deltoideus
Pectoralis minor ×
art. axillaris
Coracobrachialis + cap. breve Bicipitis
fasciculus later. plex. brachialis
a. circumflexa humeri post.
n. musculocutaneus
Pectoralis major ×
Subscapu-laris
Teres major
art. thoraco-dorsalis
Latissimus
art. subscapul.
n. radialis *
art. brachialis
n. cutaneus brachii medial.
n. cutan. ante-brachii medialis
art. circumflexa humeri ant.
caput longum m. bicipitis
nervus ulnaris
nervus medianus
venae brachiales
fascic. post. plex. brachialis
nervus thoracodorsalis
art. circumflexa scapulae
nervus axillaris
Supraspinatus ×
spina scapulae ×
clavicula ×
nervus suprascapularis
lig. transv. scap. sup.
art. transv. scap.
ram. acro-mialis
Deltoideus ×
ligam. transversum scapulae inferius
Supra-spinatus ×
rete acromiale
Infraspinatus ×
anastomosis
Teres major
Teres minor ×
arteria circumflexa scapulae
* capsula articularis
nervus axillaris
Infraspinatus
arteria circumflexa humeri posterior
caput longum Tricipitis
nervus cutaneus brachii lateralis ×
Deltoideus

Fig. 26.

Fig. 27.

The Nerves and Blood Vessels of the Upper Extremity.

Fig. 26. The nerves and vessels of the shoulder region, from in front. (2/3)
* = long head of Triceps.

Fig. 27. The nerves and vessels of the shoulder region from behind. (2/3)
The Deltoideus is partly cut away and reflected; a piece of the acromion is removed and the Supraspinatus, Infraspinatus and Teres minor are divided and partly separated. * = branch of the axillary nerve to the Teres minor.

The Brachial Plexus. Infraclavicular Portion.

The infraclavicular portion of the brachial plexus consists of three cords which surround the upper part of the brachial artery and are named according to their relations to it (Fig. 26).

1. The *lateral cord (fasciculus)* is formed chiefly by the 5th to the 7th cervical nerves. It gives origin to the lateral root of the median nerve and to the musculo-cutaneous nerve.

2. The *medial cord (fasciculus)* is formed chiefly from the 8th cervical and 1st thoracic nerves. It gives origin to the ulnar, the medial root of the median, the medial brachial cutaneous and the medial antibrachial cutaneous nerves. The two roots of the median unite at an acute angle in front of the axillary or brachial artery.

3. The *posterior cord (fasciculus)* is formed mainly by the 5th, 6th, and 7th cervical nerves. It gives origin to the axillary nerve (usually regarded as belonging to the supraclavicular portion of the plexus) and to the radial (musculo-spiral) nerve.

The Axillary Artery.

The *axillary artery* is the direct continuation of the subclavian and at the base of the axilla it passes directly into the brachial artery. Fig. 10, 11, 13, 15, 27, 33, 34. Its branches are:

1. The *thoraco-acromial* artery arises at the upper border of the Pectoralis minor and lies in the subclavicular fossa in company with the cephalic vein. Fig. 9, 10, 15, 17. Its branches are: a) the *acromial branch* passing beneath the Deltoideus to the acromial rete (Fig. 17); b) the *deltoid branch* accompanying the cephalic vein in the deltoideo-pectoral triangle (Fig. 8, 17); c) *pectoral branches* to the pectoral muscles, Fig. 17.

2. The *lateral (long) thoracic artery* passes downwards on the medial axillary wall upon the Serratus anterior, Fig. 16, 17.

3. The *subscapular artery* is a strong, short trunk which quickly divides into its terminal branches. Fig. 26. a) The *thoraco-dorsal artery* runs downwards parallel to the axillary border of the scapula, between the Serratus anterior and the Latissimus dorsi, supplying both these muscles and the Teres major. Fig. 16, 17, 26. b) The *circumflex scapular artery* passes through the medial axillary foramen to the dorsum of the scapula. It supplies the Subscapularis, Teres major, Teres minor, the long head of the Triceps and the Infraspinatus. Fig. 16, 26, 27.

4. The *anterior humeral circumflex artery* (weak) winds around the anterior surface of the surgical neck of the humerus supplying neighboring muscles. Fig. 26, 34.

5. The *posterior humeral circumflex artery* is a strong artery arising opposite the preceding from the lower part of the axillary. It curves posteriorly around the surgical neck of the humerus, passing with the axillary nerve through the lateral axillary foramen to supply the Deltoideus and neighboring muscles. Fig. 16, 26, 27, 34, 35.

The Nerves and Blood Vessels of the Upper Extremity. (Cont.)

Fig. 29. The cutaneous nerves and veins of the flexor surface of the upper arm. (1/2)

Fig. 30. The cutaneous nerves and veins of the flexor surface of the forearm. (1/2)
The skin and fatty tissue are removed but the fascia is retained. * = anastomosis between the lateral antibrachial cutaneous nerve and the superficial branch of the radial (musculospiral) nerve. ** = the radial artery seen through the fascia.

The Cutaneous Veins of the Arm.

1. The *cephalic vein* begins on the radial side of the dorsum of the hand from the dorsal venous network and the digital venous arches (Fig. 45). It receives tributaries from the volar surface of the hand, the intercapitular veins (Fig. 45), and passes up the radial side of the forearm as far as the bend of the elbow, where it anastomoses with the basilic vein (see below). It passes up the upper arm, as a rule somewhat smaller than it is in the forearm, in the lateral bicipital groove to the deltoideo-pectoral triangle, where it pierces the fascia to open into the axillary vein. Fig. 8—10, 13—15, 17, 28—32, 45.

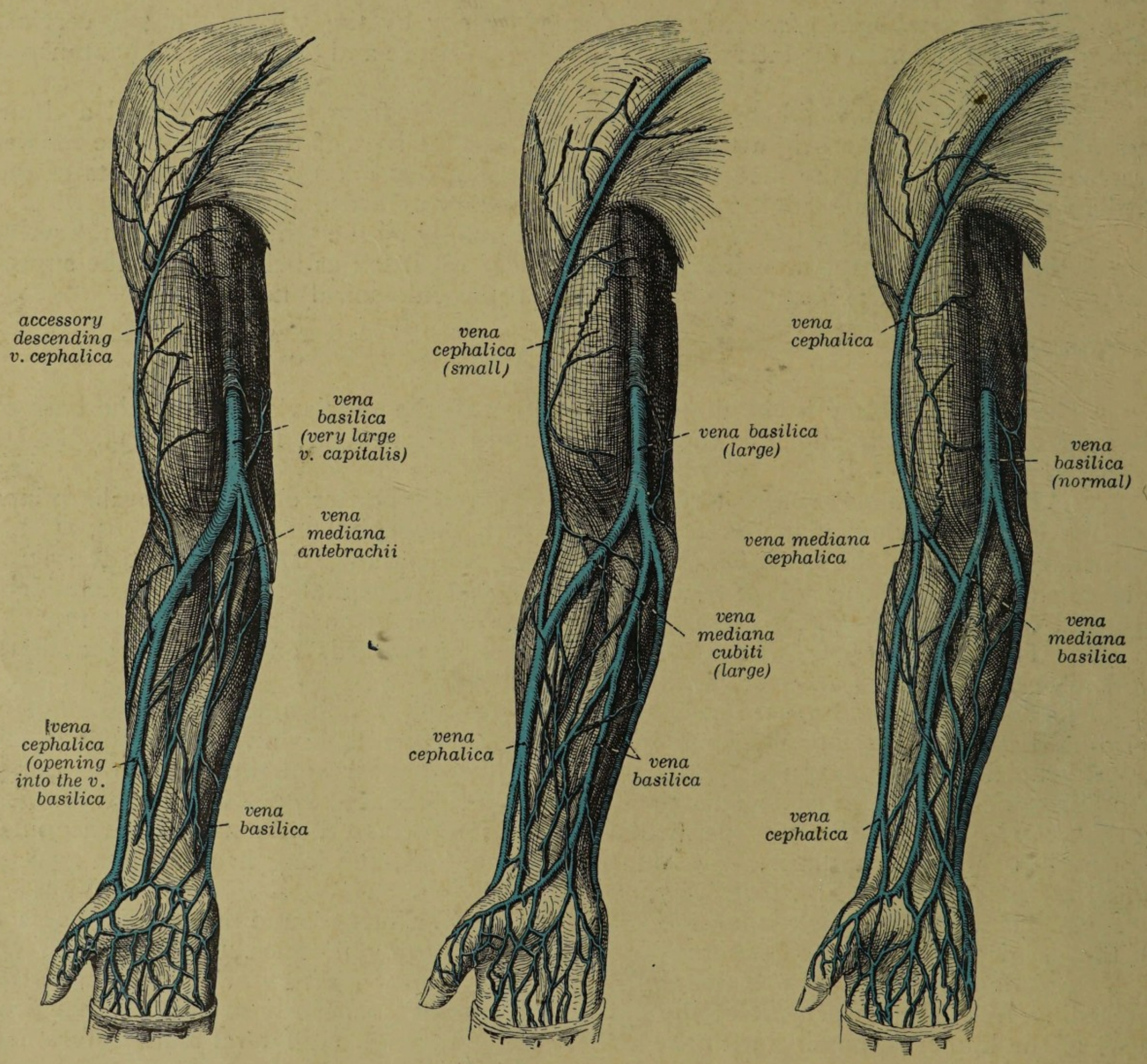

Fig. 28. The most frequent variations of the veins of the forearm (schematic).

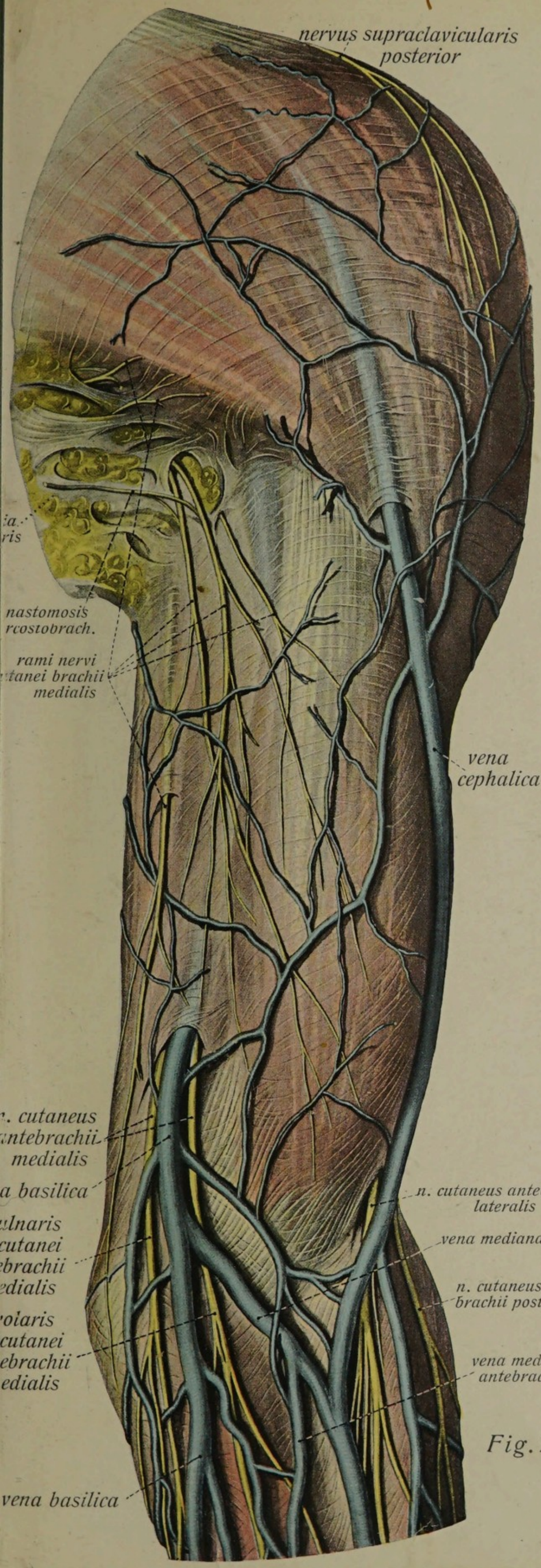
nervus supraclavicularis posterior
ia.
ris
nastomosis
rcostobrach.
rami nervi
tanei brachii
medialis
vena cephalica
r. cutaneus
ntebrachii
medialis
a basilica
ulnaris
cutanei
ebrachii
edialis
volaris
cutanei
ebrachii
edialis
vena basilica
n. cutaneus antebrachii lateralis
vena mediana cubiti
n. cutaneus antebrachii posterior
vena mediana antebrachii

Fig. 29.

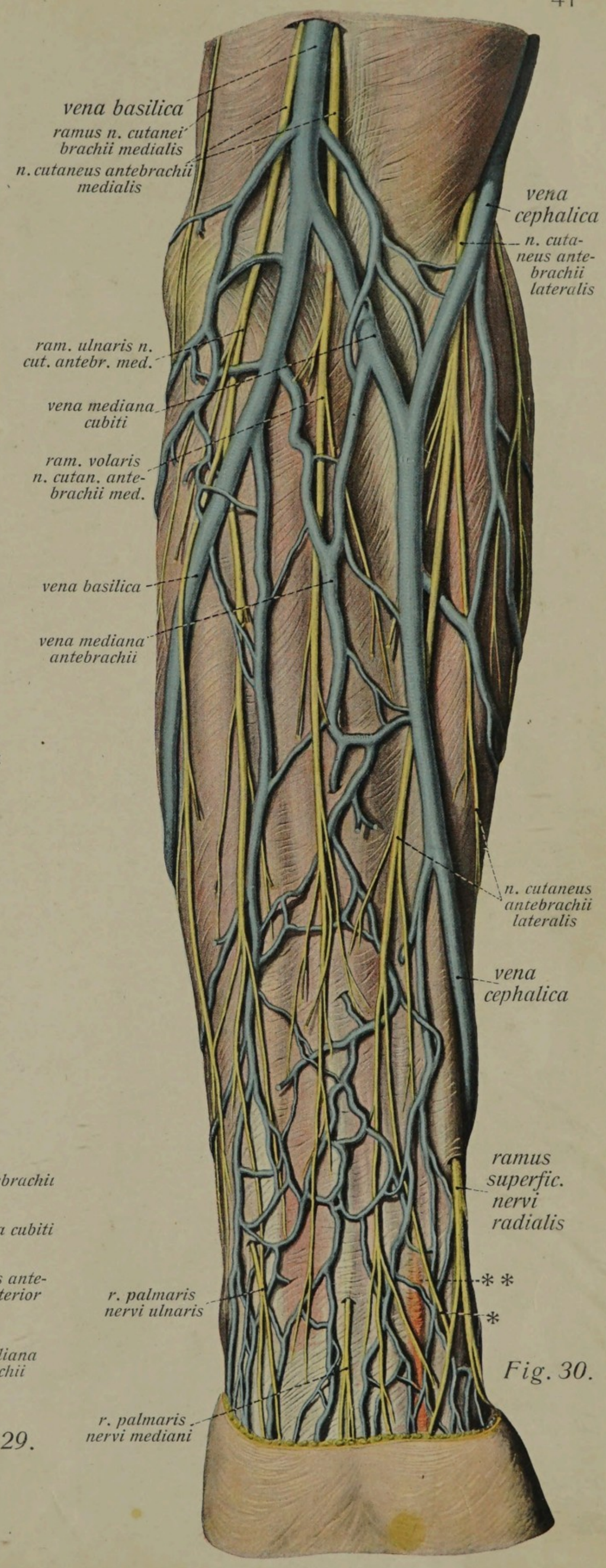
vena basilica
ramus n. cutanei brachii medialis
n. cutaneus antebrachii medialis
vena cephalica
n. cutaneus antebrachii lateralis
ram. ulnaris n. cut. antebr. med.
vena mediana cubiti
ram. volaris n. cutan. antebrachii med.
vena basilica
vena mediana antebrachii
n. cutaneus antebrachii lateralis
vena cephalica
ramus superfic. nervi radialis
* *
*
r. palmaris nervi ulnaris
r. palmaris nervi mediani

Fig. 30.

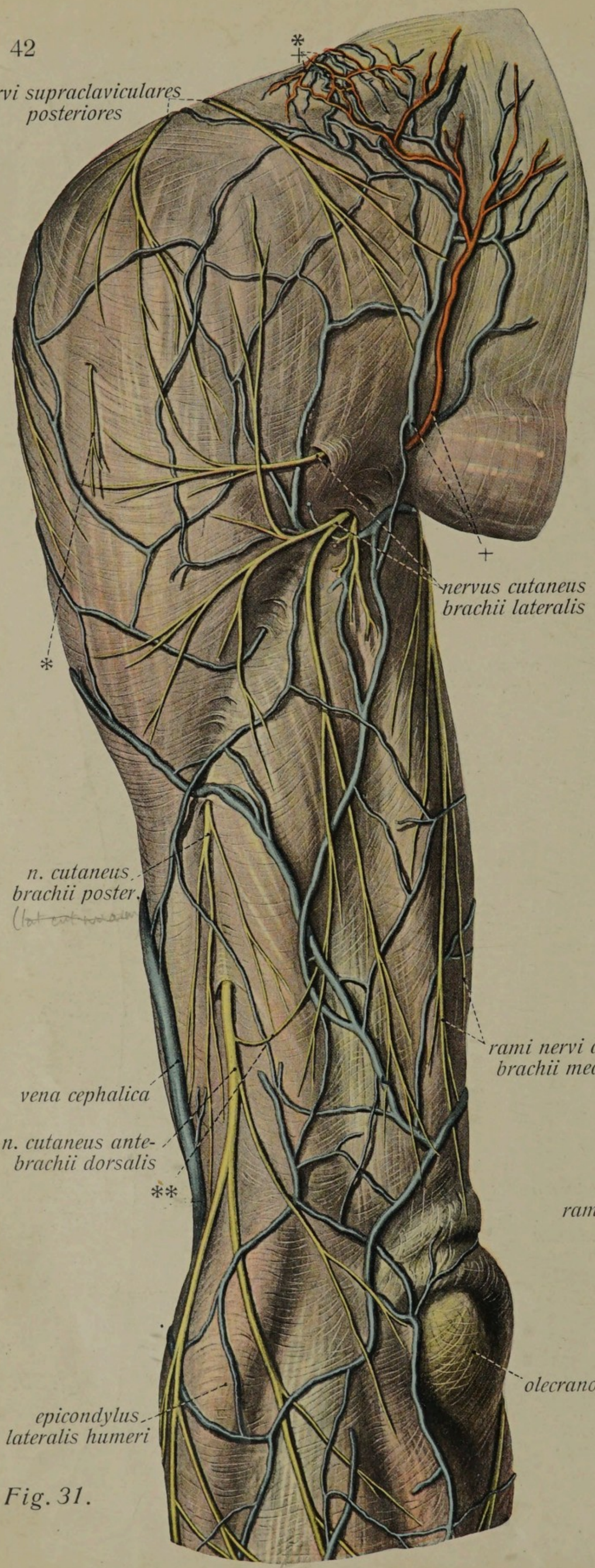
nervi supraclaviculares posteriores
nervus cutaneus brachii lateralis
n. cutaneus brachii poster.
rami nervi cutanei brachii medialis
vena cephalica
n. cutaneus antebrachii dorsalis
olecranon
epicondylus lateralis humeri

Fig. 31.

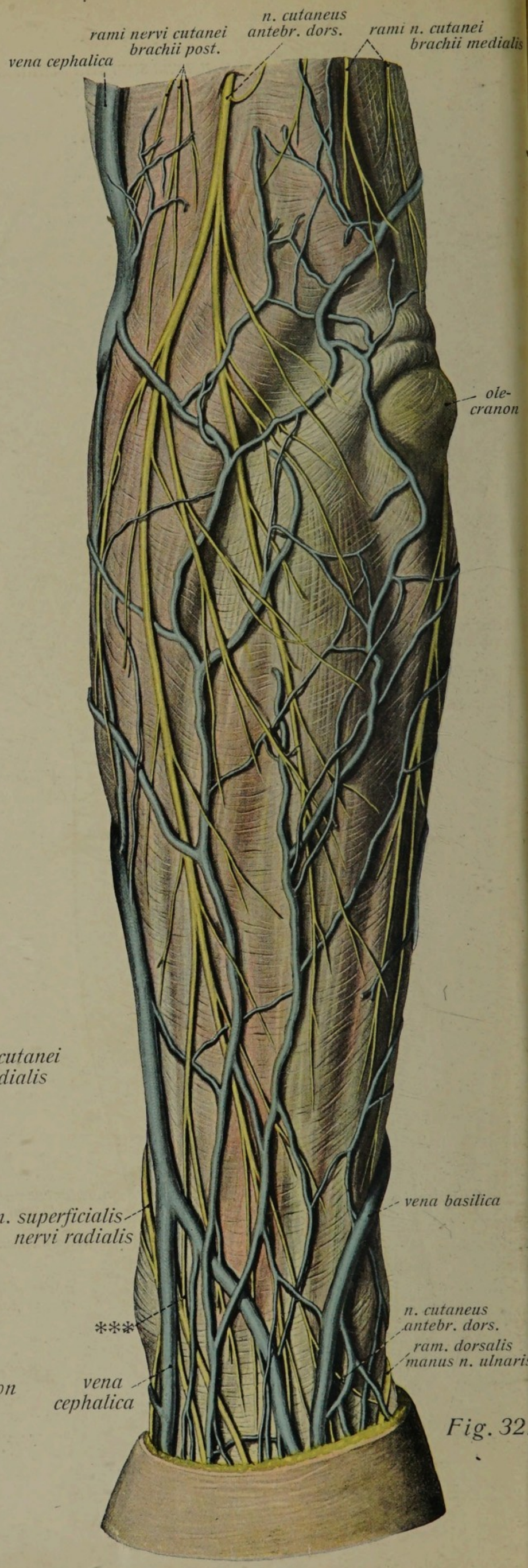
vena cephalica
rami nervi cutanei brachii post.
n. cutaneus antebr. dors.
rami n. cutanei brachii medialis
olecranon
ram. superficialis nervi radialis
vena basilica
n. cutaneus antebr. dors.
ram. dorsalis manus n. ulnaris
vena cephalica

Fig. 32.

The Nerves and Blood Vessels of the Upper Extremity. (Cont.)

Fig. 31. The cutaneous nerves and veins of the extensor surface of the upper arm. (1/2)
Fig. 32. The cutaneous nerves and veins of the extensor surface of the forearm. (1/2)
* = accessory cutaneous branch of the axillary nerve. ** = anastomosis between the posterior brachial and the dorsal antebrachial cutaneous nerves. *** = anastomosis between the dorsal antebrachial cutaneous and radial nerves. + = cutaneous branch of the posterior humeral circumflex artery. +* = cutaneous branches of the thoraco-acromial vessels (rete acromiale).

(continued from p. 40.)

2. The *basilic vein* arises, similarly to the cephalic, on the ulnar side of the dorsum of the hand. It runs upwards on the ulnar side of the volar surface of the forearm to the level of the bend of the elbow, where it unites by means of the median cubital vein with the cephalic, becoming thereby the larger of the two. It continues upward in the upper arm in the medial bicipital groove and at about the middle of the arm pierces the brachial fascia and opens into the medial brachial vein, which is usually its direct continuation. Fig. 28—30, 32.

3. The *median cubital vein* is an oblique anastomosis between the basilic and cephalic veins, which is, however, quite variable (cf. Fig. 28). It usually receives the *median antebrachial vein* formed by veins from the volar surface of the hand and forearm. Fig. 28—30.

The Cutaneous Nerves of the Upper Arm and Forearm.

In addition to the *posterior supraclavicular nerves* (see p. 7, Fig. 29, 31) supplying a part of the skin of the shoulder, there are the following:

1. The *lateral brachial cutaneous nerve* from the axillary (see p. 23). Fig. 27, 31.

2. The *medial brachial cutaneous nerve* from the medial cord of the brachial plexus. It anastomoses with the intercosto-brachial nerve, pierces partly the axillary fascia and partly the medial portion of the brachial fascia and supplies the skin of the medial surface of the upper arm as far as the bend of the elbow and the adjacent part of the skin of the axilla. Fig. 13, 14, 29—32.

3. The *medial antebrachial cutaneous nerve* also from the medial cord of the brachial plexus. It is much stronger than the medial brachial cutaneous, pierces the brachial fascia with the basilic vein and divides into a *volar* and an *ulnar* branch. The latter continues on with the basilic vein and both extend as far as the wrist joint. Fig. 26, 29, 30, 33.

4. The *lateral antebrachial cutaneous nerve* is the sensory terminal branch of the musculo-cutaneous. It pierces the fascia near the tendon of insertion of the Biceps and is distributed with the cephalic vein to the skin of the radial side of the forearm, as far down as the wrist. Fig. 29, 30, 33, 34.

5. The *posterior brachial cutaneous nerve* is a branch of the radial (musculo-spiral) nerve (p. 47). At about the level of the insertion of the Deltoideus it pierces the brachial fascia and is distributed to the skin of the posterior surface of the upper arm as far as the elbow joint. It is usually weak and not quite constant; it anastomoses with the succeeding. Fig. 31, 35.

6. The *dorsal antebrachial cutaneous nerve*, larger than the preceding, also arises from the radial (musculo-spiral). It pierces the brachial fascia in the region of the lateral intermuscular septum and supplies the skin of the posterior surface of the forearm almost as far down as the wrist. Fig. 31, 32, 35, 36, 45.

The Nerves and Blood Vessels of the Upper Extremity. (Cont.)

Fig. 33. The nerves and blood vessels of the flexor surface of the upper arm. (1/2)
Fig. 34. The same as Fig. 33, but with the veins omitted.
The Biceps in Fig. 34 is drawn outwards.

The Brachial Artery.

The *brachial artery* is the direct continuation of the axillary (see p. 23) and is accompanied by two brachial veins and the median nerve. It passes downwards beneath the brachial fascia in the medial bicipital groove to the cubital fossa, where it lies upon the tendon of insertion of the Brachialis, covered by the lacertus fibrosus. It divides into two terminal branches, the radial and ulnar arteries. Fig. 33—39. Its branches are:

1. The *deep brachial artery* arises from the upper part of the brachial and, accompanied by the radial (musculo-spiral) nerve, passes between the medial and long heads of the Triceps in the groove for the radial (musculo-spiral) nerve. It is chiefly supplied to the Triceps. Fig. 33—35. Its branches are:

a) A *deltoid branch* to the muscle of that name. Fig. 35, 36.

b) The *radial collateral artery* runs with the radial (musculo-spiral) nerve in the groove for that nerve between the medial and lateral heads of the Triceps. A more definite dorsal branch emerges with the dorsal antebrachial cutaneous nerve at the lateral intermuscular septum and runs along this superficially to join the *cubital articular rete*, while a ventral branch accompanies the radial (musculo-spiral) nerve towards the volar surface and supplies the neighboring muscles. Fig. 35, 36, 41, 43.

c) The *middle collateral artery* is frequently the direct continuation of the main stem; it penetrates the medial head of the Triceps and runs to the cubital rete. Fig. 36.

2. The *superior ulnar collateral artery* arises just below the deep brachial, runs obliquely towards the medial intermuscular septum and then along this, in company with the ulnar nerve, behind the medial epicondyle to the cubital rete. It supplies the adjacent muscles. Fig. 33—37, 39.

3. The *inferior ulnar collateral artery* arises a short distance above the medial epicondyle, pierces the medial intermuscular septum and passes deeply between the tendon of the Triceps and the humerus to the cubital rete. It supplies the adjacent muscles and may partly replace the preceding. Fig. 33, 34, 37, 39.

4. The *nutrient arteries* of the humerus and independent *muscular branches* to the Biceps and Brachialis. Fig. 33, 34.

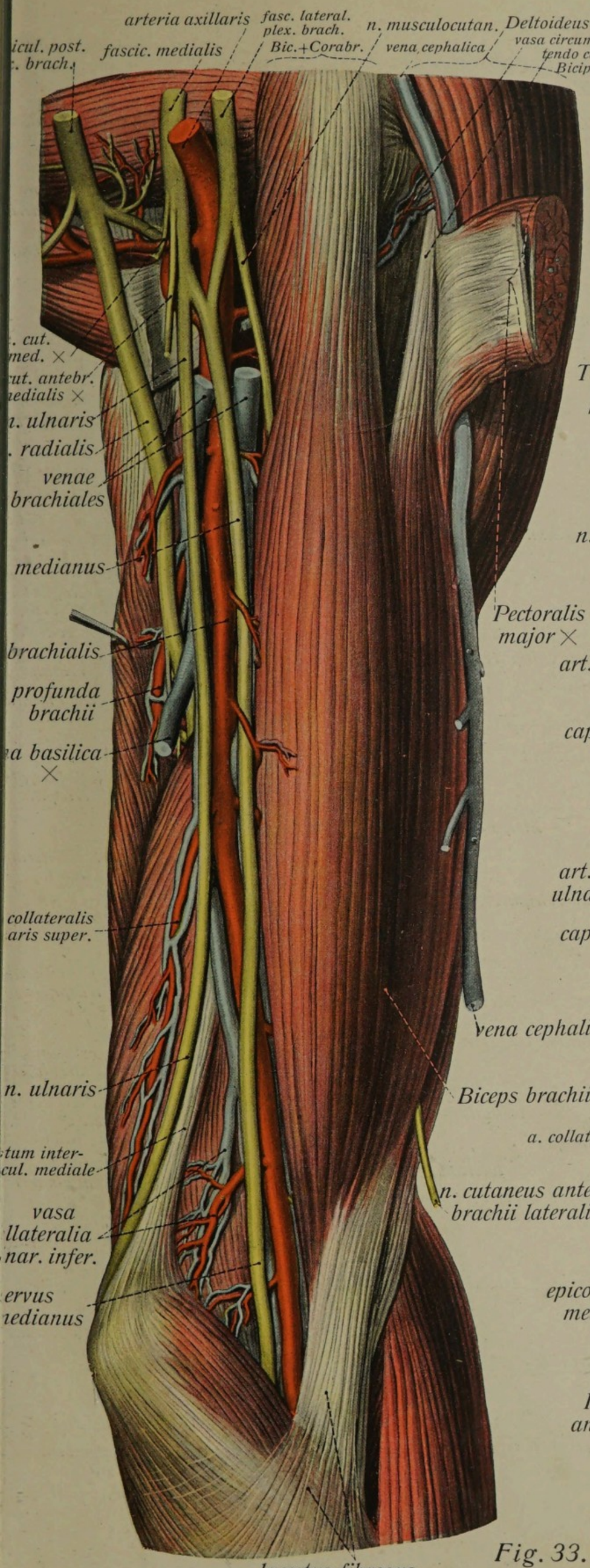
arteria axillaris
fasc. lateral. plex. brach.
n. musculocutan.
Deltoideus
fascic. medialis
Bic.+Corabr.
vena cephalica
vasa circumflexa humeri ant.
tendo cap. longi Bicipitis
. cut. med. ×
ut. antebr. edialis ×
n. ulnaris
. radialis
venae brachiales
medianus
brachialis
profunda brachii
a basilica ×
collateralis aris super.
n. ulnaris
tum inter- cul. mediale
vasa llateralia nar. infer.
ervus edianus
Teres major
n. radialis
n. medianus
Pectoralis major ×
art. profunda brachii
caput longum Tricipitis
n. ulnaris
art. collateralis ulnaris superior
caput mediale Tricipitis
vena cephalica
Biceps brachii
a. collateralis ulnaris inferior
n. cutaneus antebrachii lateralis
epicondylus medialis
Flexores antebrachii
lacertus fibrosus

Fig. 33.

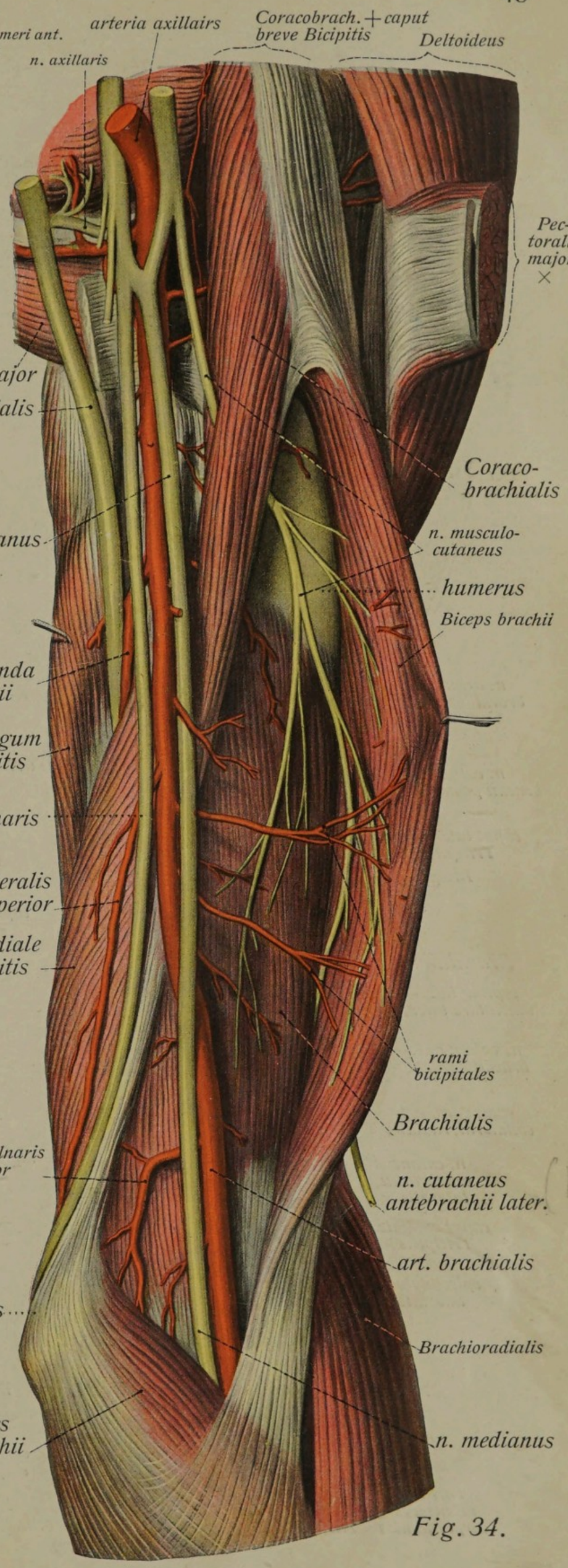
arteria axillairs
Coracobrach. + caput breve Bicipitis
Deltoideus
n. axillaris
Pectoralis major ×
Coraco- brachialis
n. musculo- cutaneus
humerus
Biceps brachii
rami bicipitales
Brachialis
n. cutaneus antebrachii later.
art. brachialis
Brachioradialis
n. medianus

Fig. 34.

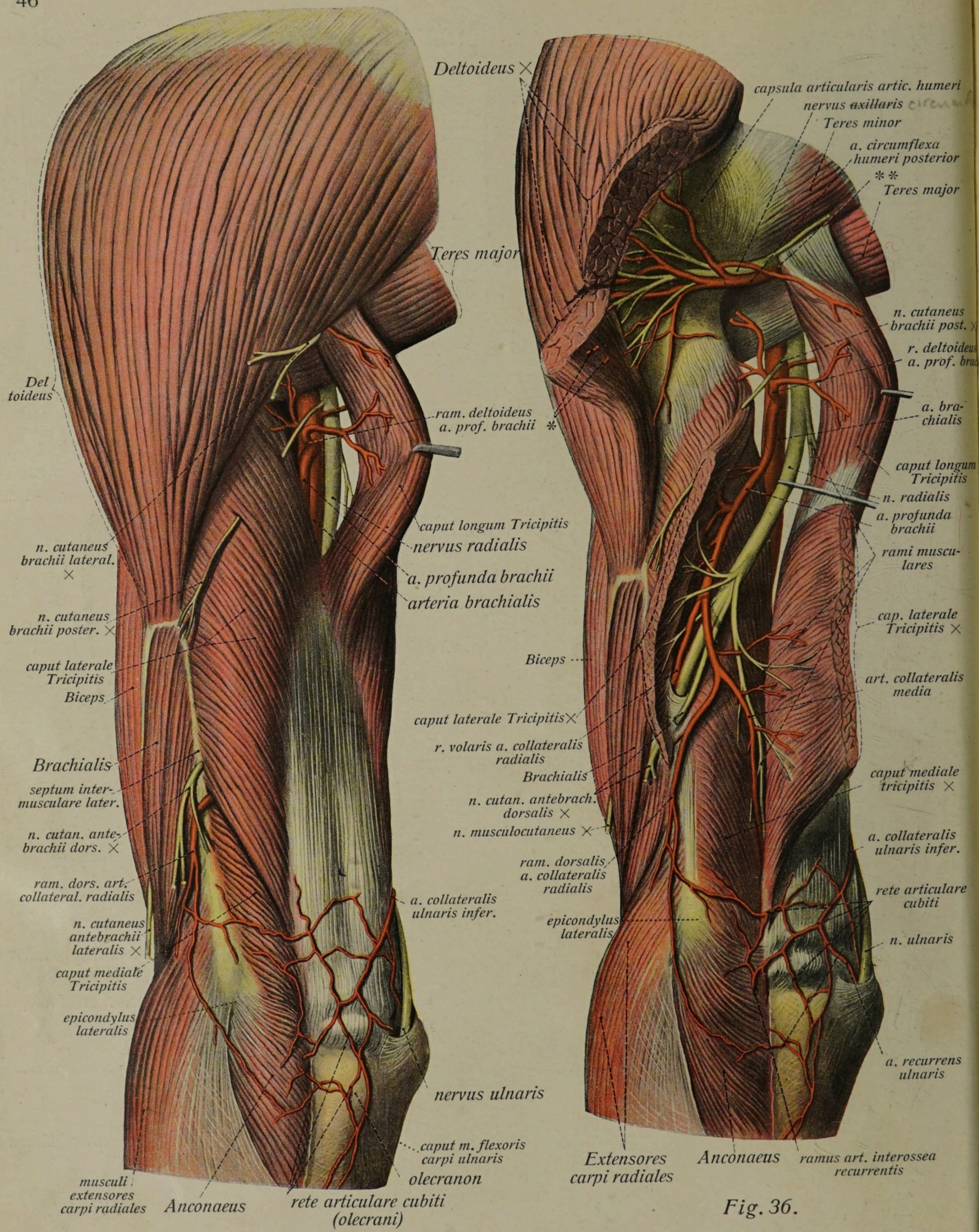
Deltoideus
Teres major
Del toideus
ram. deltoideus
a. prof. brachii
n. cutaneus brachii lateral.
caput longum Tricipitis
nervus radialis
a. profunda brachii
arteria brachialis
n. cutaneus brachii poster.
caput laterale Tricipitis
Biceps
Brachialis
septum inter-musculare later.
n. cutan. ante-brachii dors.
ram. dors. art. collateral. radialis
n. cutaneus antebrachii lateralis
caput mediale Tricipitis
epicondylus lateralis
musculi extensores carpi radiales
Anconaeus
a. collateralis ulnaris infer.
nervus ulnaris
caput m. flexoris carpi ulnaris
olecranon
rete articulare cubiti (olecrani)
capsula articularis artic. humeri
nervus axillaris
Teres minor
a. circumflexa humeri posterior
Teres major
n. cutaneus brachii post.
r. deltoideus
a. prof. brac
a. bra-chialis
caput longum Tricipitis
n. radialis
a. profunda brachii
rami muscu-lares
cap. laterale Tricipitis
Biceps
art. collateralis media
caput laterale Tricipitis
r. volaris a. collateralis radialis
Brachialis
caput mediale tricipitis
n. cutan. antebrach. dorsalis
n. musculocutaneus
a. collateralis ulnaris infer.
ram. dorsalis a. collateralis radialis
rete articulare cubiti
epicondylus lateralis
n. ulnaris
a. recurrens ulnaris
Extensores carpi radiales
Anconaeus
ramus art. interossea recurrentis

Fig. 35.

Fig. 36.

The Nerves and Blood Vessels of the Upper Extremity. (Cont.)

Fig. 35. The superficial nerves and blood vessels of the extensor surface of the upper arm. (1/2)

Fig. 36. The deep nerves and blood vessels of the extensor surface of the upper arm. (1/2)
* = cut twigs of the deltoid branch of the deep brachial artery.
** = lateral axillary foramen.

The Musculo-cutaneous Nerve

arises from the lateral cord of the brachial plexus, traverses as a rule the Coraco-brachialis, giving branches to it, and comes to lie between the Biceps and Brachialis. It supplies both these muscles and becomes superficial as the *lateral antebrachial cutaneous nerve* (see p. 43) at the radial border of the tendon of insertion of the Biceps. Fig. 29, 30, 33, 34.

The Radial (Musculo-spiral) Nerve.

The *radial (musculo-spiral) nerve* is a mixed nerve and the largest of the brachial nerves. It arises from the posterior cord of the brachial plexus and lies at first behind the brachial artery. It then passes, in company with the deep brachial artery, between the long and medial heads of the Triceps and later between the medial and lateral heads, close to the bone, in the groove for the radial (musculo-spiral) nerve, on the posterior surface of the humerus. It then follows the course of the groove and, piercing the lateral intermuscular septum in company with the volar branch of the radial collateral artery (see p. 44), it comes to lie in the groove between the Brachialis and the Brachio-radialis, where it divides into its two terminal branches. Fig. 33—39, 41. Its branches are:

1. The *posterior brachial cutaneous nerve*, see p. 43.

2. *Muscular branches* to the three heads of the Triceps and to the Anconeus, to the radial portion of the Brachialis and to the Brachio-radialis and the Extensor carpi radialis longus. Fig. 36—39, 41.

3. The *dorsal antebrachial cutaneous nerve* leaves the groove for the radial nerve between the lateral and medial heads of the Triceps, in company with the dorsal branch of the radial collateral artery (see p. 44).

4. The *deep radial (posterior interosseous) nerve*, is the larger terminal branch and is almost entirely motor. It traverses the Supinator to the dorsal surface of the forearm, where, in company with the dorsal interosseous artery, it runs between the superficial and deep layers of the Extensors, giving branches to the Extensor carpi radialis brevis, the Supinator, the Extensor digitorum communis, the Extensor digiti V, the Extensores pollicis longus and brevis, the Extensor indicis and the Abductor pollicis longus. The purely sensory, slender terminal branch, the *dorsal interosseous nerve* passes with the dorsal branch of the volar interosseous artery to the dorsal surface of the wrist joint. Fig. 37—39, 41, 48.

5. The *superficial radial nerve*, the other terminal branch, is weaker than the deep one and is almost purely sensory. It lies radial to the radial artery, but separate from it by a distinct interval, and passes downwards under cover of the Brachio-radialis to which it may give branches. In the lower third of the forearm it passes to the dorsal surface between the tendons of the Brachio-radialis and the bone, pierces the antibrachial fascia and supplies the radial half of the skin of the dorsum of the hand, as far as the bases of the terminal phalanges. It anastomoses with the lateral antibrachial cutaneous and ulnar nerves. Fig. 39, 40, 42, 43, 45, 46.

The Nerves and Blood Vessels of the Upper Extremity. (Cont.)

Fig. 37. The superficial nerves and blood vessels of the flexor surface of the forearm. (1/2)
The lacertus fibrosus is cut and the Brachio-radialis drawn aside.

Fig. 38. The deep nerves and blood vessels of the flexor surface of the forearm. (1/2)
The Pronator teres, Palmaris longus and Flexor carpi radialis are partly removed and the tendon of the Flexor carpi ulnaris is cut.
+ = entrance of the deep radial nerve into the Supinator.

The Radial Artery

arises at the bend of the elbow by the division of the brachial artery (see p. 44), being its weaker terminal branch. It runs at first between the lacertus fibrosus and the tendon of the Biceps, then passes to the ulnar side of the superficial radial nerve under cover of the Brachio-radialis and runs downwards in the groove between this and the forearm flexors, first in front of the tendon of the Pronator teres and then between the Brachio-radialis and the Flexor carpi radialis. It rests for some distance on the Flexor pollicis longus and for a short distance on the Pronator quadratus and in the lower third of the forearm it is covered only by the antebrachial fascia and lies accordingly quite superficially in front of (volar to) the styloid process of the radius. Below this it bends under the tendons of the Abductor pollicis longus and the Extensor pollicis brevis to the dorsum of the hand, traversing the radial foveola (tabatière), and there passes between the two heads of the first dorsal Interosseous muscle to the volar surface of the hand to form the deep volar arch. Fig. 37—41, 47—50. Its branches are:

1. The *radial recurrent artery* arises from the upper part of the radial and runs upwards and backwards over the Supinator. It is covered by the radial group of muscles, sends branches to adjacent muscles, anastomoses with the volar branch of the radial collateral and ends in the cubital rete. Fig. 37—39, 41.

2. *Muscular branches* given off along its course in the forearm to the neighboring muscles. Fig. 37—39.

3. The *superficial volar branch*, usually weak, is given off just before the radial passes to the dorsum of the hand. It runs superficially over the thenar eminence to the superficial volar arch (see p. 59). Fig. 37—39, 49, 50.

4. The *volar carpal branch*, a thin, not quite constant branch given off from the artery in the lower part of its course through the forearm, passes to the volar carpal rete. Fig. 50.

5. The *dorsal carpal branch* arises on the dorsum of the hand and, with other branches (see p. 59), forms the dorsal carpal rete. Fig. 42, 47, 48.

Continued on p. 59.

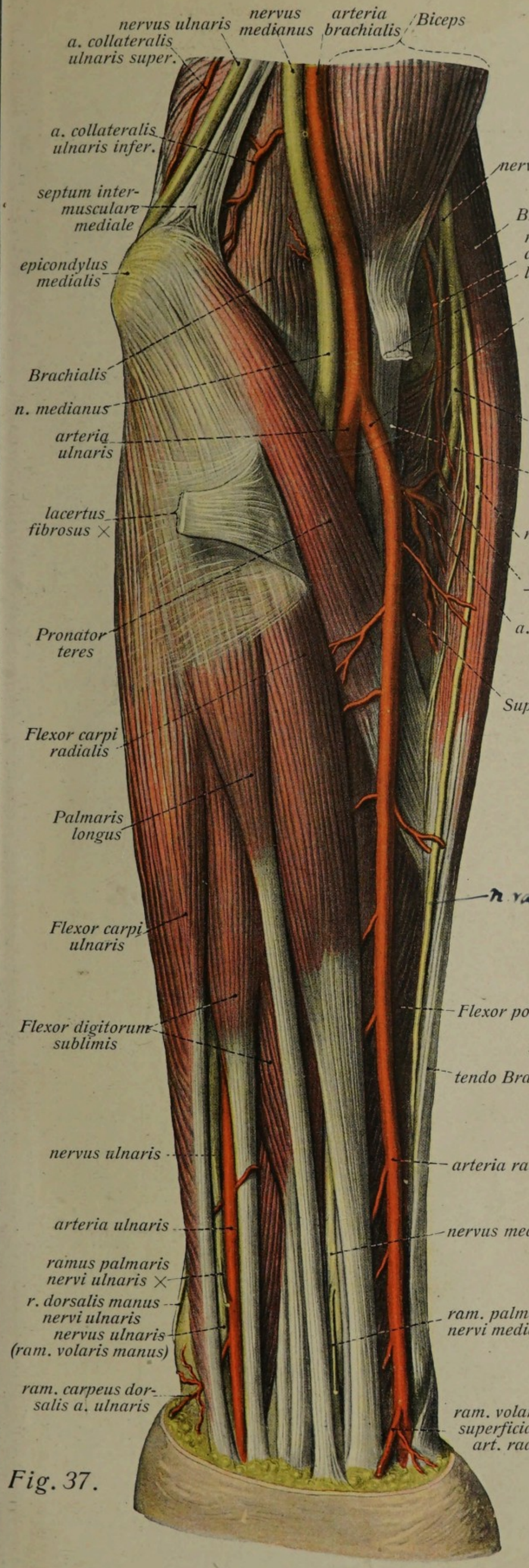
nervus ulnaris
nervus medianus
arteria brachialis
Biceps
a. collateralis ulnaris super.
a. collateralis ulnaris infer.
septum intermusculare mediale
epicondylus medialis
Brachialis
n. medianus
arteria ulnaris
lacertus fibrosus ×
Pronator teres
Flexor carpi radialis
Palmaris longus
Flexor carpi ulnaris
Flexor digitorum sublimis
nervus ulnaris
ramus palmaris nervi ulnaris ×
r. dorsalis manus nervi ulnaris
nervus ulnaris (ram. volaris manus)
ram. carpeus dorsalis a. ulnaris
arteria ulnaris
nervus radialis
Brachioradialis
ram. volar. arteriae collateral. radialis
lacertus fibrosus ×
arteria radialis
ram. profundus nervi radialis
tendo Bicipitis
ram. superficialis nervi radialis
a. recurrens radialis
Supinator
Flexor pollicis longus
tendo Brachioradialis
arteria radialis
nervus medianus
ram. palmaris nervi mediani ×
ram. volaris superficialis art. radialis

Fig. 37.

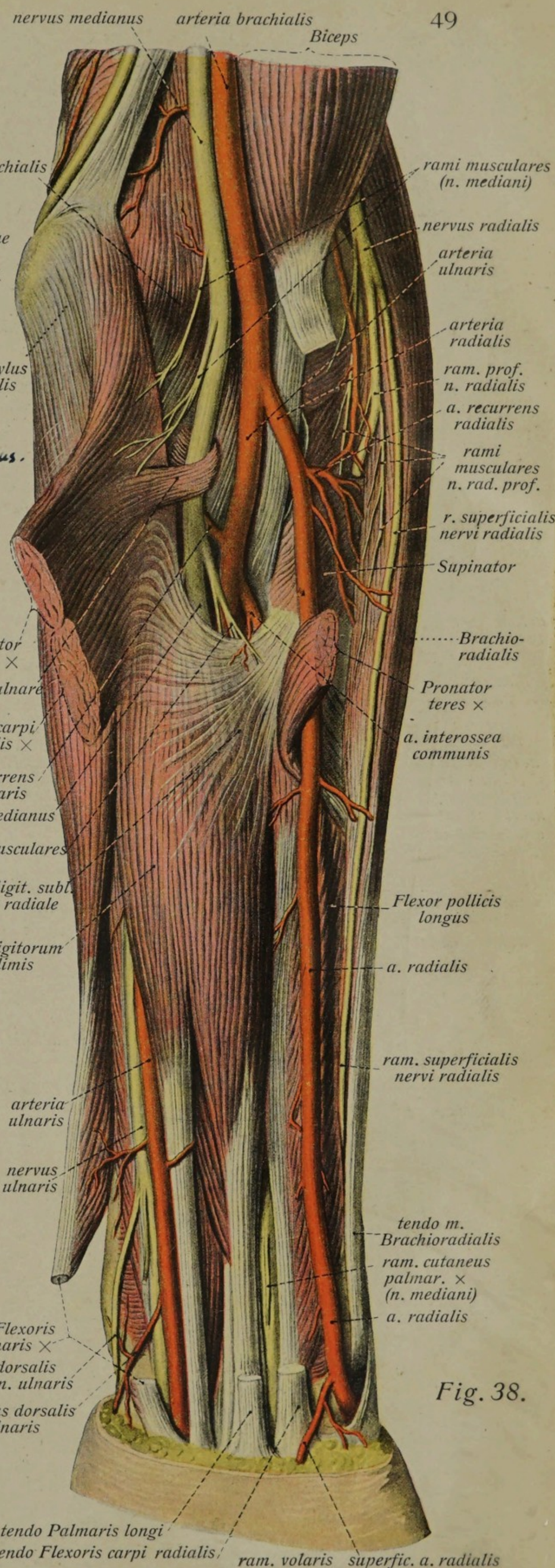
nervus medianus
arteria brachialis
Biceps
Brachialis
epicondylus medialis
Pronator teres ×
caput ulnare
Flexor carpi radialis ×
a. recurrens ulnaris
nervus medianus
rami musculares
Flexor digit. subl. caput radiale
Flexor digitorum sublimis
arteria ulnaris
nervus ulnaris
tendo Flexoris carpi ulnaris ×
ram. dorsalis manus n. ulnaris
ram. carpeus dorsalis art. ulnaris
tendo Palmaris longi
tendo Flexoris carpi radialis
rami musculares (n. mediani)
nervus radialis
arteria ulnaris
arteria radialis
ram. prof. n. radialis
a. recurrens radialis
rami musculares n. rad. prof.
r. superficialis nervi radialis
Supinator
Brachioradialis
Pronator teres ×
a. interossea communis
Flexor pollicis longus
a. radialis
ram. superficialis nervi radialis
tendo m. Brachioradialis
ram. cutaneus palmar. × (n. mediani)
a. radialis
ram. volaris
superfic. a. radialis

Fig. 38.

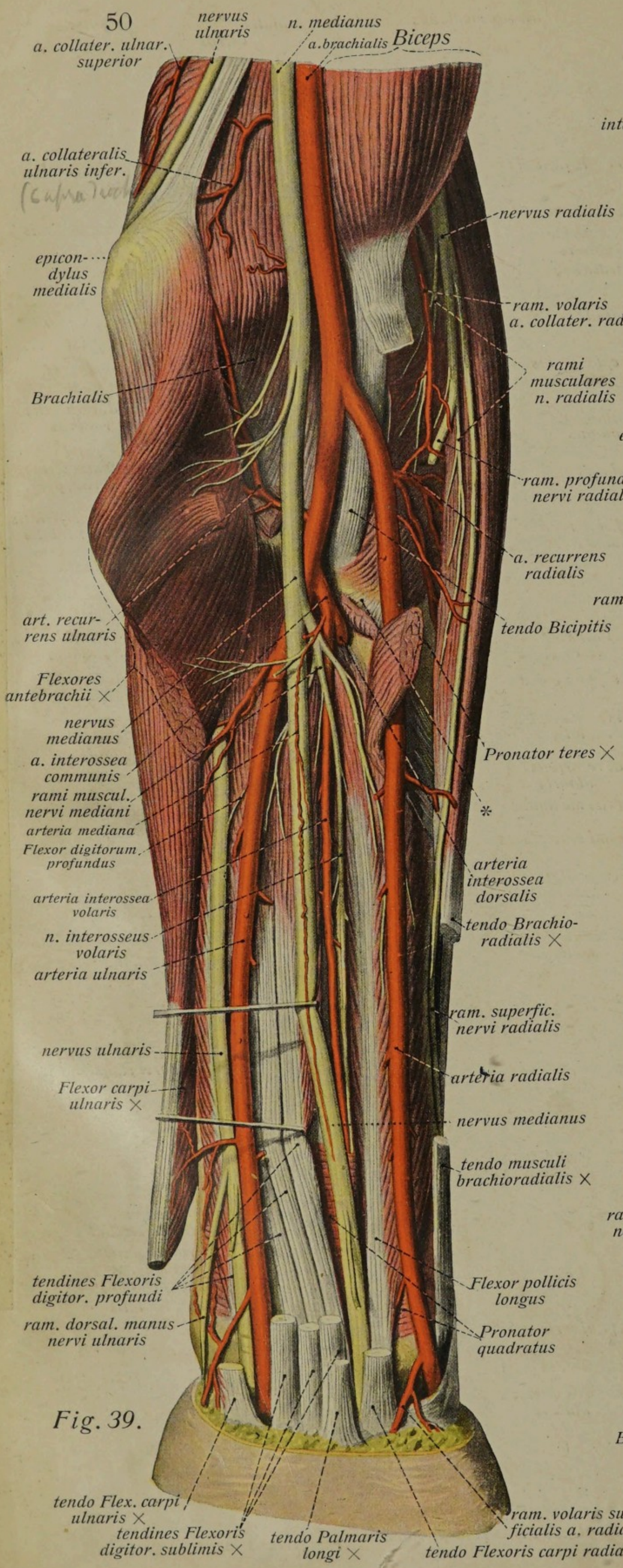

Fig. 39.

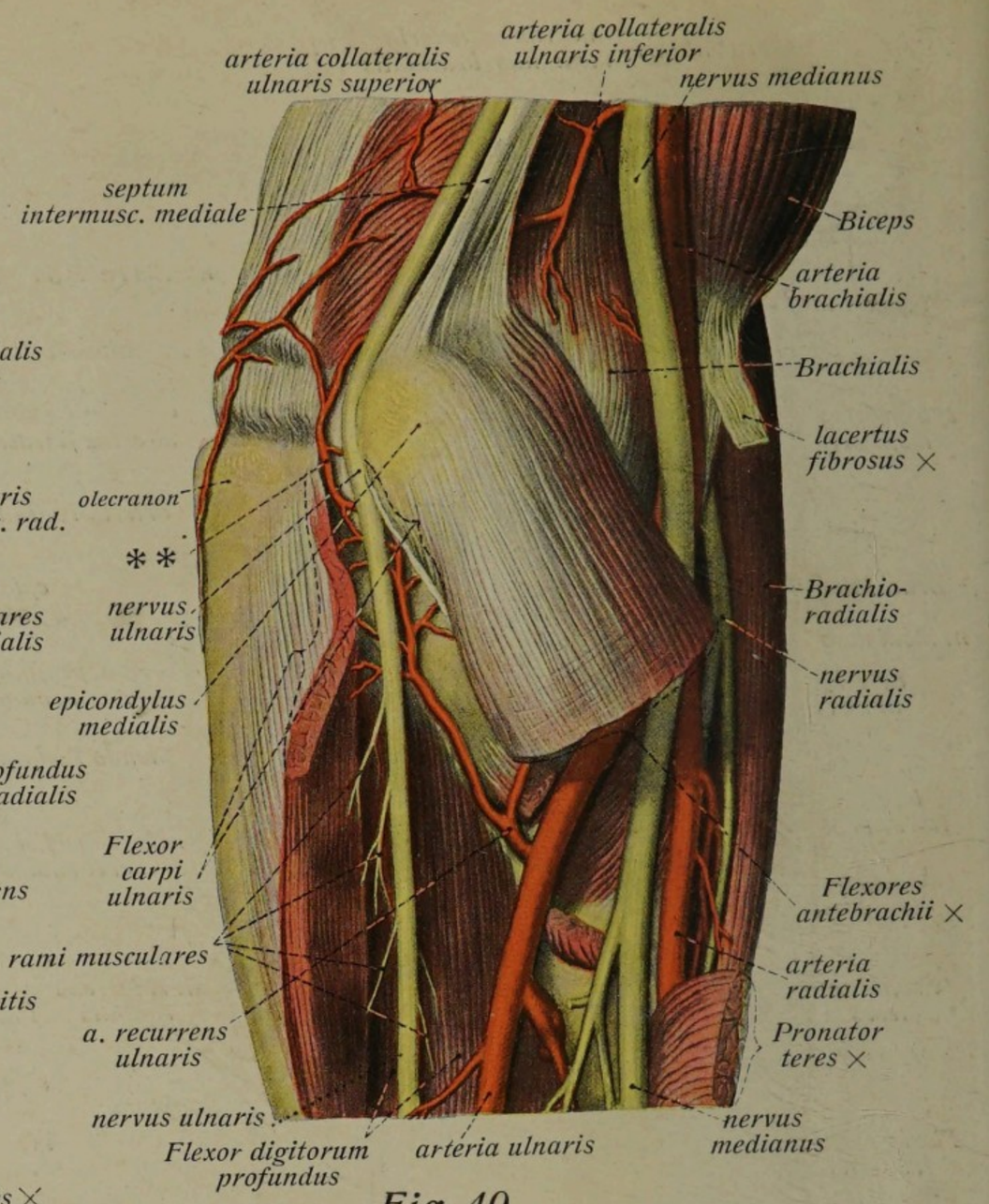

Fig. 40.

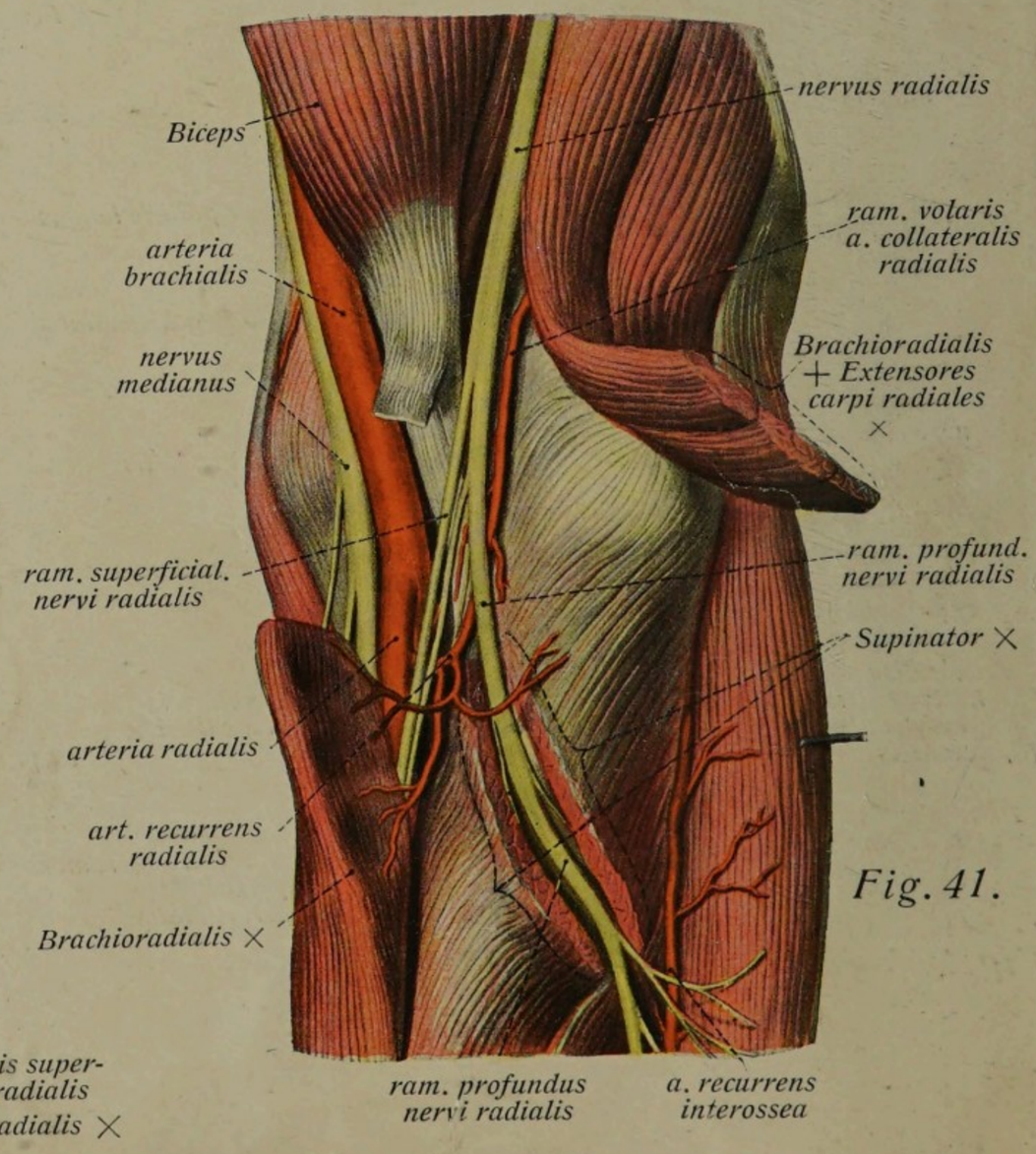

Fig. 41.

The Nerves and Blood Vessels of the Upper Extremity. (Cont.)

Fig. 39. The deep nerves and vessels of the flexor surface of the forearm. (1/2)
All the superficial flexors and pronators are cut away; the median nerve and the Flexor digitorum profundus are drawn ulnarly.

Fig. 40. The vessels and nerves of the ulnar surface of the elbow. (1/2)
The flexors and pronators of the forearm are cut away or incised.

Fig. 41. The vessels and nerves of the radial surface of the elbow. (1/2)
The radial group of forearm muscles is cut away and the Supinator divided over the deep radial (posterior interosseous) nerve.
* = the cut radial head of the Flexor digitorum profundus.
** = anastomosis of the ulnar recurrent artery with the inferior ulnar collateral.

The Median Nerve

arises in front of the lower part of the axillary artery by the union of two branches which come from the medial and lateral cords of the brachial plexus. In the upper arm it lies at first on the lateral side of the brachial artery, but crosses in front of it in the lower third of the upper arm and so comes to lie medial to the artery. Along with it it passes through the bend of the elbow, covered by the lacertus fibrosus, accompanies the upper part of the ulnar artery for a short distance, passes between the ulnar and humeral heads of the Pronator teres, crosses over the ulnar artery and runs down the forearm between the superficial and deep layers of flexors. With the tendons of these it passes through the carpal canal into the palm of the hand, where its terminal branches are given off. Fig. 26, 33, 34, 37—41, 49. It is a strong, mixed nerve. It gives off no branches in the upper arm; its branchings begin in the cubital fossa and are:

1. *Muscular branches* in the upper third of the forearm to the Pronator teres, Flexor carpi radialis, Palmaris longus, Flexor digitorum sublimis, the radial part of the Flexor digitorum profundus, Flexor pollicis longus, and Pronator quadratus. The long, slender branch to the last two muscles, the *volar interosseous nerve*, runs with the volar interosseous artery on the surface of the interosseous membrane and contains some sensory fibres. Fig. 37—39.

2. The *palmar branch* arises in the lower third of the forearm; it is long, slender and sensory. Above the wrist it pierces the antebrachial fascia and is distributed to the skin of the palm of the hand. Fig. 30, 37, 38, 44.

3. The *anastomotic branch* is a rather constant and moderately strong oblique branch passing from the median to the ulnar nerve in the palm of the hand. Fig. 49.

4. *Muscular branches* for the two radial Lumbricals and for the thenar muscles, with the exception of the Abductor pollicis brevis and the deep head of the Flexor pollicis brevis. Fig. 49.

5. The *common volar digital nerves* I—III strong sensory branches for the volar surfaces of the fingers, except the little finger and the ulnar side of the ring finger, and the *proper volar digital nerve I*, for the radial side of the thumb. Each of the former, after giving off short sensory branches to the skin of the palm, divides into two *proper volar digital nerves*. Fig. 44, 46, 49, 50.

The Nerves and Blood Vessels of the Upper Extremity. (Cont.)

Fig. 42. The superficial nerves and blood vessels of the extensor surface of the forearm. (1/2)
The Extensor digitorum and the Extensor digiti V are drawn to the side.

Fig. 43. The deep nerves and blood vessels of the extensor surface of the forearm. (1/2)
The Extensor digitorum and Extensor digiti V are drawn strongly to the ulnar side. The Extensor pollicis longus is cut and the Supinator is divided for a short distance over the deep branch of the radial.

The Ulnar Artery

arises in the cubital fossa as the stronger terminal branch of the brachial artery (see p. 44). It curves gradually toward the ulnar side of the volar surface of the forearm, being situated on the origin of the Flexor digitorum profundus and behind the median nerve and the superficial flexors. It comes to lie on the radial side of the ulnar nerve, but in contrast to the radial artery, it remains covered by the Flexor digitorum sublimis and the Flexor carpi ulnaris until the lower fourth of the forearm, where it becomes visible between the tendons of these two muscles, close beside the ulnar nerve. With this it runs over the radial surface of the pisiform bone between the volar and transverse carpal ligaments, and so, covered at first by the Palmaris brevis, to the palm of the hand, where it is the chief constituent of the superficial volar arch. Fig. 37—40, 44, 49, 50. Its branches are:

1. The *recurrent ulnar arteries*, one or two in number, arise from the upper part of the artery. The anterior weaker stem, which is often a branch of the following vessel, runs upwards volarly to the medial epicondyle to supply the neighboring muscles; the posterior stem goes dorsally to the epicondyle, covered by the muscles arising from it, to the cubital rete. Fig. 38—40.

2. The *common interosseous artery*, the strongest branch of the ulnar, arise from the posterior surface of the artery and after a short course (Fig. 38, 39) divides into:

a) The *volar interosseous artery* runs downwards on the volar surface of the interosseous membrane between the Flexor digitorum profundus and the Flexor pollicis longus, covered at first by the edges of both muscles. It gives off a small *median artery* to the median nerve and sends perforating branches through the membrane to the extensor surface. It then passes beneath the Pronator quadratus, which it supplies, and pierces the interosseous membrane to join the dorsal carpal rete. Fig. 39, 48, 50.

b) The *dorsal interosseous artery* passes through the gap above the interosseous membrane to the dorsal surface of the forearm and gives off the *recurrent interosseous artery* which passes to the cubital rete in front of the origin of the superficial Extensors and the Anconeus. The main stem of the dorsal interosseous lies between the superficial and deep Extensors, supplies these muscles and joins, by weak branches, the dorsal carpal rete. Fig. 42, 43.

3. Muscular branches to the adjacent muscles. Fig. 39.

4. A weak *volar carpal branch* to the volar carpal rete. Fig. 50.

5. The *dorsal carpal branch* arises above the wrist and passes over the dorsal surface of the capitulum of the ulna to the dorsal carpal rete and to the ulnar side of the fifth finger. Fig. 47, 48.

6. The *deep volar branch* passes in company with the deep volar branch of the ulnar nerve between the hypothenar muscles to the deep volar arch (see p. 59). Fig. 49, 50.

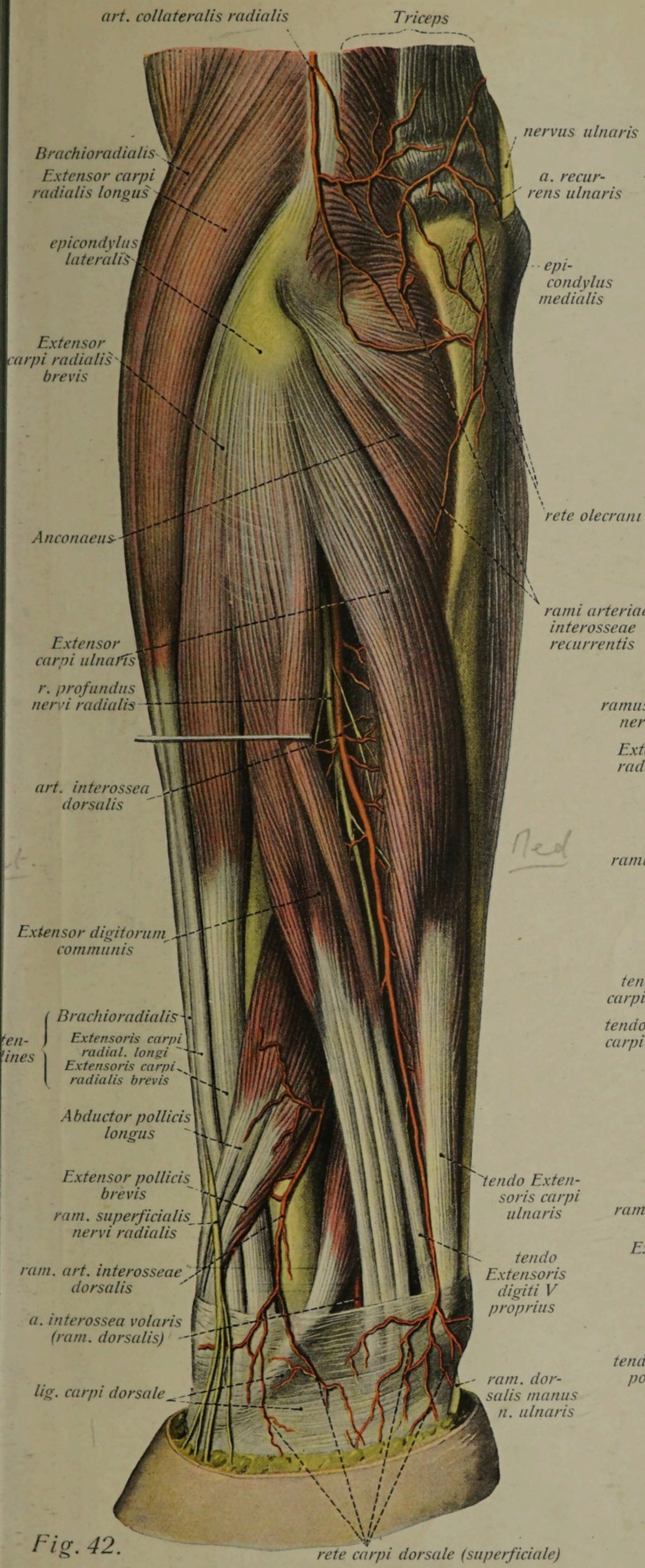
art. collateralis radialis
Triceps
nervus ulnaris
Brachioradialis
Extensor carpi radialis longus
a. recurrens ulnaris
epicondylus lateralis
epicondylus medialis
Extensor carpi radialis brevis
rete olecrani
Anconaeus
rami arteriae interosseae recurrentis
Extensor carpi ulnaris
r. profundus nervi radialis
art. interossea dorsalis
Extensor digitorum communis
Brachioradialis
Extensoris carpi radial. longi
Extensoris carpi radialis brevis
Abductor pollicis longus
Extensor pollicis brevis
ram. superficialis nervi radialis
tendo Extensoris carpi ulnaris
ram. art. interosseae dorsalis
tendo Extensoris digiti V proprius
a. interossea volaris (ram. dorsalis)
ram. dorsalis manus n. ulnaris
lig. carpi dorsale
rete carpi dorsale (superficiale)

Fig. 42.

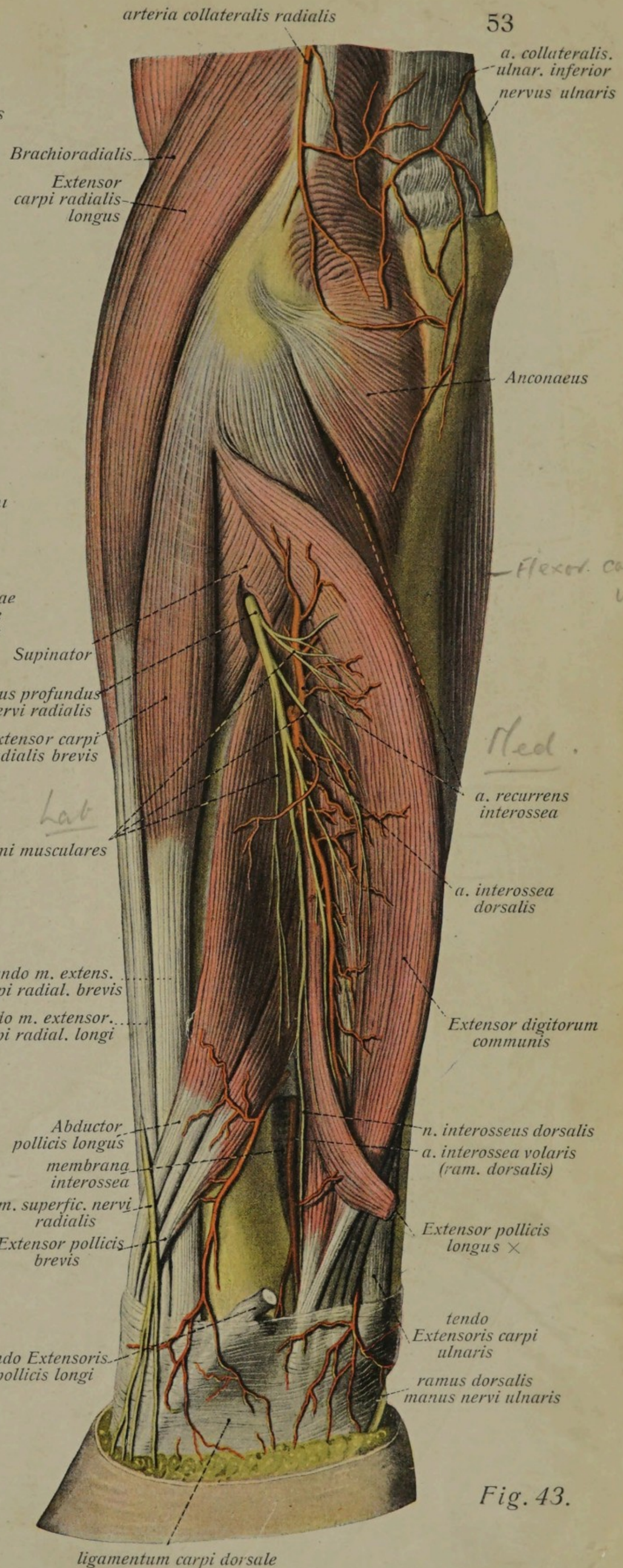
arteria collateralis radialis
a. collateralis. ulnar. inferior
nervus ulnaris
Brachioradialis
Extensor carpi radialis longus
Anconaeus
Supinator
ramus profundus nervi radialis
Extensor carpi radialis brevis
rami musculares
a. recurrens interossea
a. interossea dorsalis
tendo m. extens. carpi radial. brevis
tendo m. extensor. carpi radial. longi
Extensor digitorum communis
Abductor pollicis longus
membrana interossea
ram. superfic. nervi radialis
Extensor pollicis brevis
n. interosseus dorsalis
a. interossea volaris (ram. dorsalis)
Extensor pollicis longus ×
tendo Extensoris carpi ulnaris
tendo Extensoris pollicis longi
ramus dorsalis manus nervi ulnaris
ligamentum carpi dorsale

Fig. 43.

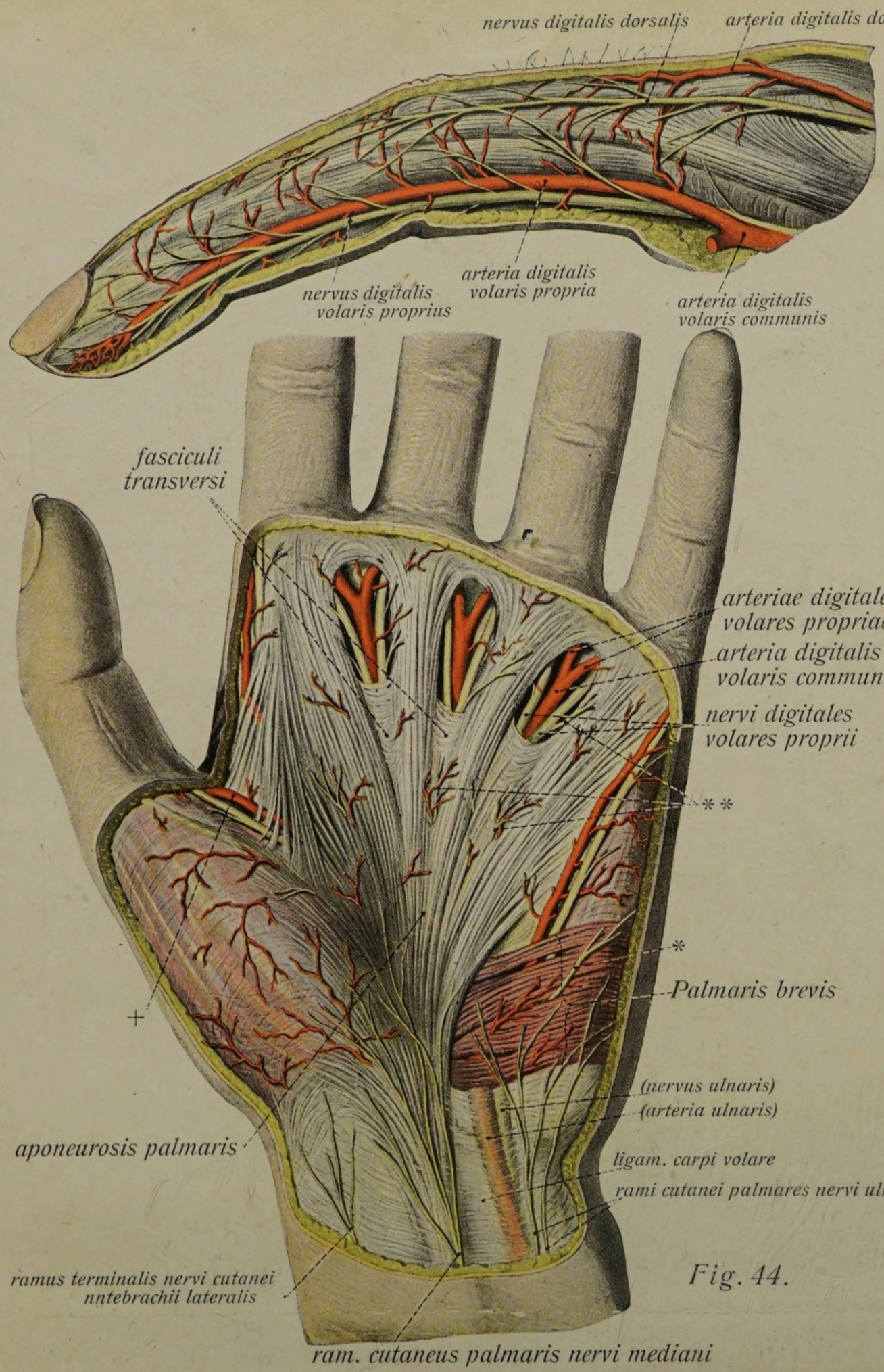

Fig. 44.

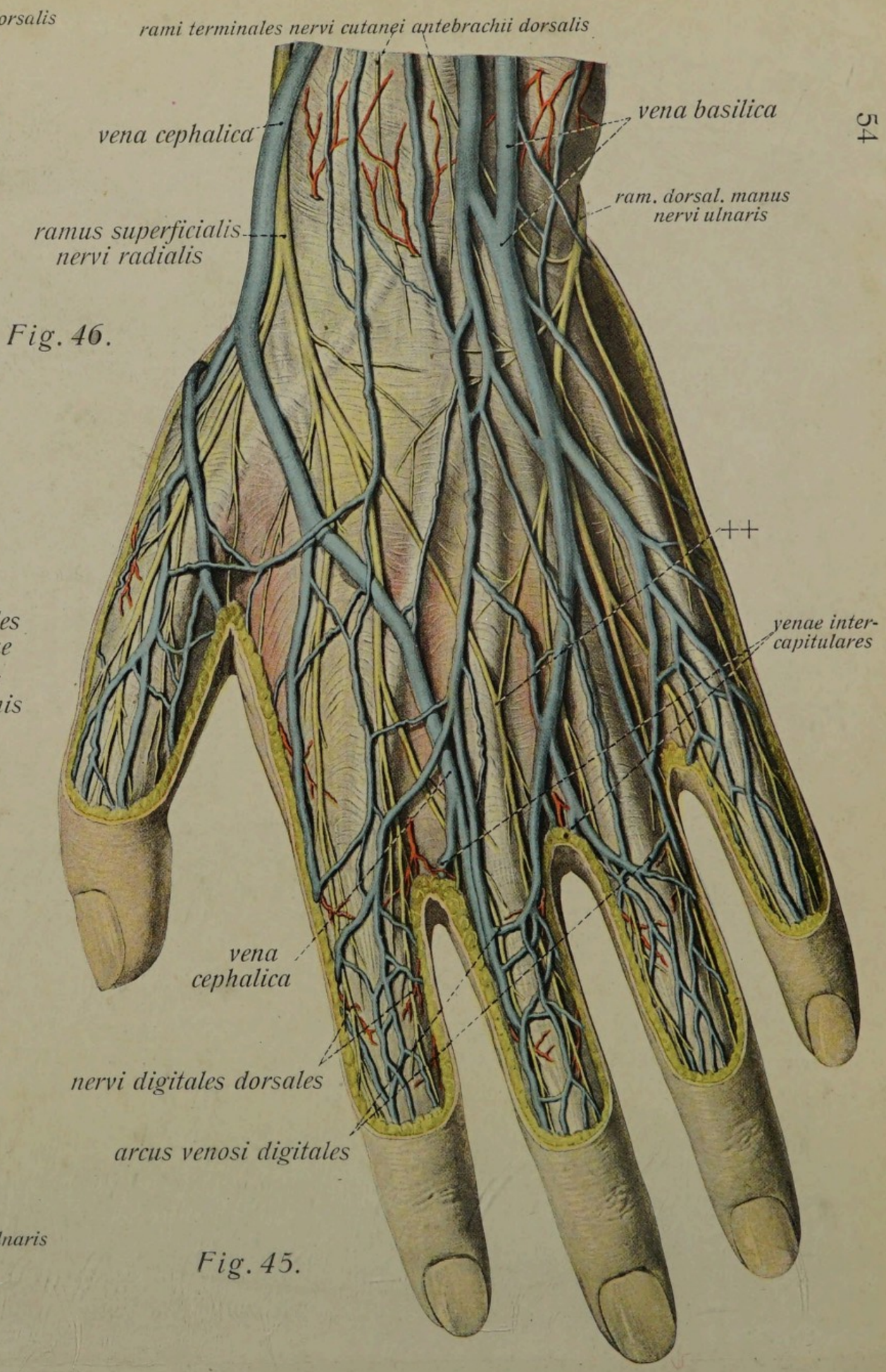

Fig. 45.

Fig. 46.

Fig. 44. The superficial nerves and blood vessels of the palm of the hand. (2/3)
* = cutaneous branch of the ulnar nerve. ** = volar cutaneous branches of the median and ulnar nerves.
+ = volar digital artery of the thumb.

Fig. 45. The superficial nerves and veins of the dorsum of the hand. (2/3)
++ = anastomosis between the ulnar and radial nerves.

Fig. 46. [illegible] of the forefinger. (1/1)

The Nerves and Blood Vessels of the Upper Extremity. (Cont.)

The Ulnar Nerve

is formed from the medial cord of the brachial plexus and is a mixed nerve. It lies at first on the medial side of the brachial artery but as it descends the arm it inclines more and more toward the medial intermuscular septum, in which it comes to lie superficially or imbedded and is accompanied by the superior ulnar collateral artery. The nerve then passes between the medial epicondyle and the olecranon, and then bends deeply and volarly, passing between the Flexor carpi ulnaris and the Flexor digitorum profundus. At this level it begins to give off its branches, supplying the former muscle and part (ulnar half) of the latter. It comes to lie close to the ulnar side of the ulnar artery (see p. 52), runs down the forearm with this, and, passing close to the pisiform bone, enters the palm of the hand, after it has given off a branch for the dorsal surface. Fig. 26, 33, 34, 37—40. Its branches are:

1. *Muscular branches* to the Flexor carpi ulnaris and to the ulnar portion of the Flexor digitorum profundus. Fig. 40.

2. The *palmar cutaneous branch* is small. It pierces the antebrachial fascia in the lower fourth of the forearm and supplies the skin of the ulnar side of the palm. Fig. 30, 37.

3. The *dorsal (cutaneous) branch* passes to the dorsal surface of the hand above the capitulum of the ulna, by passing between the ulna and the tendon of the Flexor carpi ulnaris. It then pierces the fascia and supplies the ulnar side of the dorsum of the hand and, through the *dorsal digital nerves*, the dorsal surfaces of the two ulnar digits and of the ulnar side of the third, anastomosing constantly with the superficial radial nerve. Fig. 37—39, 42, 43, 45.

4. The *volar branch* is the terminal part of the nerve. It runs under the Palmaris brevis in company with the ulnar artery, sending branches to the skin of the palm (Fig. 44), and divides into an almost purely motor deep and a sensory superficial branch. Fig. 49.

a) The *superficial (volar) branch* gives off the *proper volar digital nerve* for the fifth finger and, under cover of the palmar aponeurosis and making anastomoses with the median nerve, passes to the interval between the fourth and fifth fingers, where it divides into the *proper volar digital nerves* for the adjacent sides of these two fingers. Fig. 46, 49.

b) The *deep (volar) branch* passes deeply into the hollow of the hand between the hypothenar muscles, accompanying the deep volar branch of the ulnar artery. It supplies the hypothenar muscles and in addition the Adductor pollicis, all the Interossei, the two ulnar Lumbricals and the deep head of the Flexor pollicis brevis. It gives small branches to the finger joints. Fig. 50.

Fig. 44. The superficial nerves and blood vessels of the palm of the hand. (2/3)
* = cutaneous branch of the ulnar nerve. ** = volar cutaneous branches of the median and ulnar nerves.
+ = volar digital artery of the thumb.

Fig. 45. The superficial nerves and veins of the dorsum of the hand. (2/3)
++ = anastomosis between the ulnar and radial nerves.

Fig. 46. Lateral view of the nerves and blood vessels of the forefinger. (1/1)

The Nerves and Blood Vessels of the Upper Extremity. (Cont.)

The Deep Veins of the Upper Extremity.

The deep veins of the upper extremity accompany the arteries as paired venae comites. They take origin in the *deep* and *superficial volar venous arches* and terminate with the *brachial veins*, from which the axillary vein is formed. They are connected by numerous anastomoses *(venae intercapitulares, etc.)* with the superficial veins (see p. 40, 41) and during their course along with the arteries the members of each pair are frequently connected by transverse anastomoses.

The Arterial Retia of the Upper Extremity.

1. The *acromial rete* is situated superficially upon the acromion, between the skin and the periosteum. It is formed by the anastomoses of the following arteries: 1. the acromial branch of the thoraco-acromial artery, 2. the acromial branch of the transverse scapular. Fig. 27.

2. The *cubital articular rete* lies partly superficially between the skin and the olecranon or tendon of the Triceps (olecranal rete), but for the most part deeply, between the Triceps tendon and the dorsal surface of the elbow joint. It is formed by the following arteries: a) From above, 1. the radial collateral, 2. the middle collateral, both these from the deep brachial, 3. (not constant) the superior ulnar collateral, 4. the inferior ulnar collateral, these two from the brachial. b) From below, 1. the radial recurrent from the radial, 2. the ulnar recurrent, one or two, from the ulnar, 3. the interosseous recurrent from the dorsal interosseous. Fig. 42, 43.

Fig. 47. The superficial arteries of the dorsum of the hand. (2/3) The fascia is removed.

Fig. 48. The arteries of the dorsum of the hand and the lower part of the dorsum of the forearm. (2/3)

The tendons of the Extensors, with the exception of the Abductor pollicis longus and the Extensor pollicis brevis, have been cut and partly removed. The dorsal carpal ligament has been partly cut away and the first dorsal Interosseous is cut.

* = twig of the volar digital arteries. ** = twigs of the volar digital nerves bending around to the dorsal surface.

\+ = entrance of the terminal branch of the radial artery into the palm.

rete carpi dorsale (superficiale)
tendo Extensoris carpi radialis brevis
tendo Extensoris carpi radialis longi
arteria radialis (foveola radialis)
ligamentum carpi dorsale
ram. carpeus dorsalis arteriae ulnaris
ramus carpeus dorsalis art. radialis
tendines Extensoris digitorum communis
arteria radialis
tendo Extensor. pollicis longi
tendines Extensoris digiti V proprii
tendo Extensoris pollicis brevis
nervus digitalis dorsalis ×
arteria digitalis dorsalis pollicis
arteriae metacarpeace dorsales
arteriae digitales dorsales
Interosseus dorsalis I
*
**

Fig. 47.

ram. perforans a. interosseae volaris
membrana interossea
Extensor carpi ulnaris
Extensor pollicis brevis
ramus dorsalis arter. interosseae volaris
tendines Abductoris pollicis longi
n. interosseus dorsalis ×
ligamentum carpi dorsale ×
tendo Extensoris carpi ulnaris ×
rete carpi dorsale (profundum)
arteria radialis
ramus carpeus dorsalis arteriae ulnaris
ram. carpeus dorsalis a. radialis
Interosseus dorsalis I ×
tendo Extensoris pollicis longi ×
Adductor pollicis
arteria princeps pollicis
arteriae metacarpeae dorsales II–V

Fig. 48.

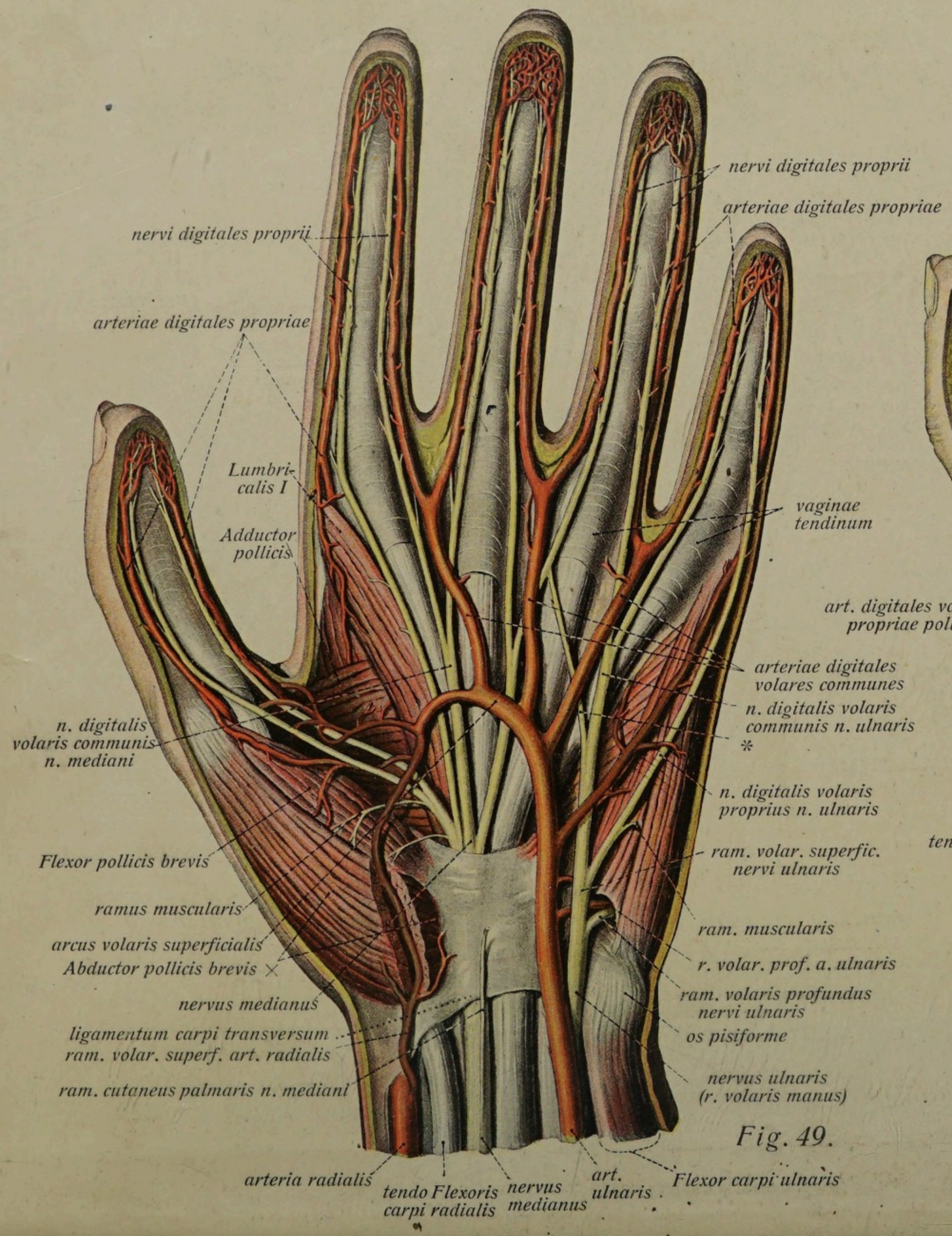

Fig. 49.

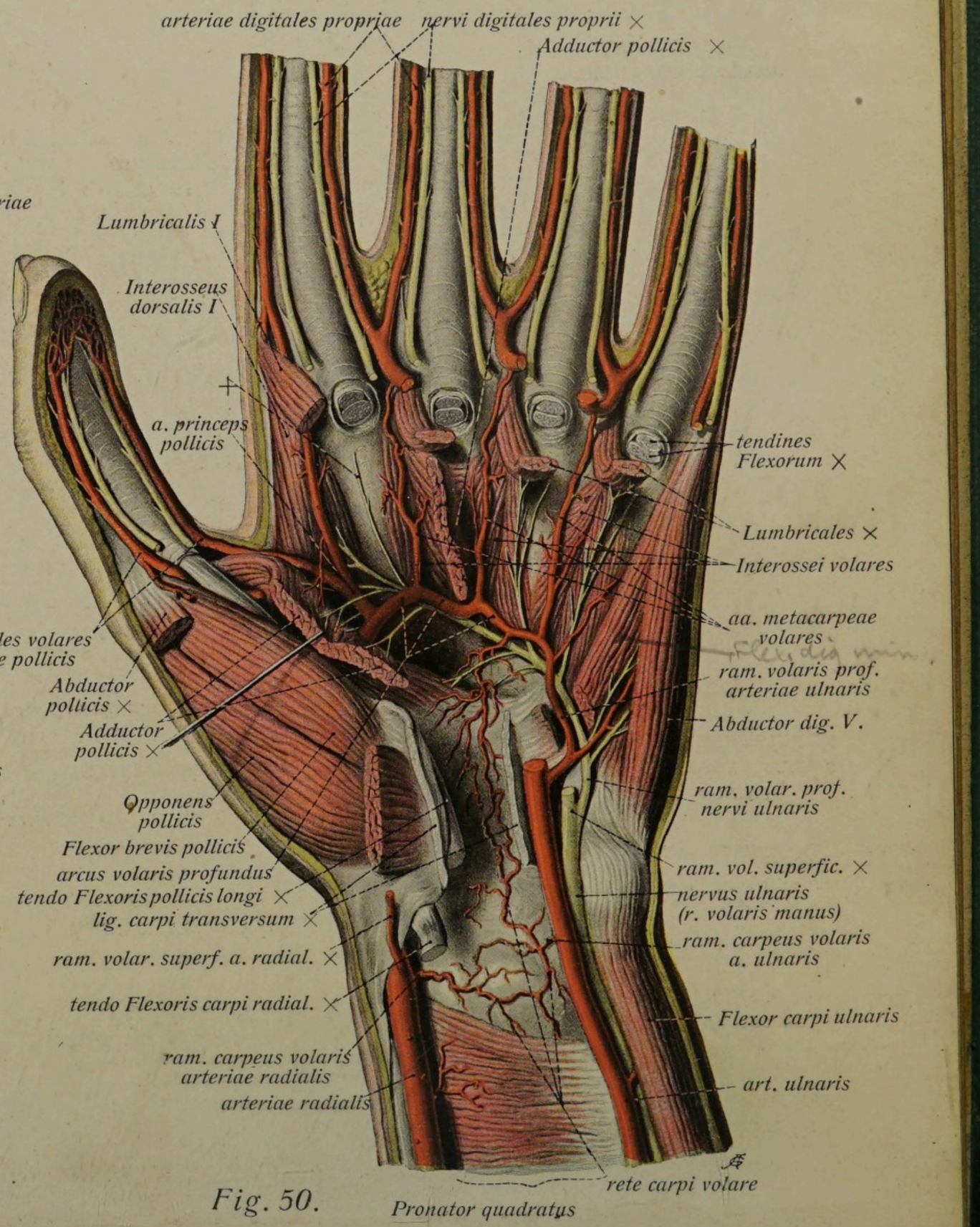

Fig. 50.

Fig. 49. The middle layer of the nerves and arteries of the palm of the hand. (2/3)
The palmar aponeurosis is removed and the Abductor pollicis brevis divided along the superficial volar branch of the radial artery. * = Anastomosis of the median and ulnar nerves.

Fig. 50. The deep layer of the nerves and arteries of the palm of the hand. (2/3)

The Nerves and Blood Vessels of the Upper Extremity. (Cont.)

The Arterial Retia of the Upper Extremity. (Cont. from p. 56.)

3. The *dorsal carpal rete* is partly superficial between the dorsal carpal ligament and the skin, but mainly deep between the ligament and the dorsal surface of the wrist joint. It is formed by the following arteries: 1. the dorsal carpal branch of the radial; 2. the dorsal branch of the volar interosseous; 3. the dorsal carpal branch of the ulnar; and 4. the terminal branches of the dorsal interosseous, these last usually contributing only to the superficial portion of the rete. From the rete 3 or 4 *dorsal metacarpal arteries* arise, which give origin to 6 or 7 dorsal *digital arteries*, while the three radial dorsal digitales arise directly from the radial artery. Fig. 45—48.

4. The *volar carpal rete* is much weaker than the dorsal and lies on the floor of the carpal canal, on the volar surface of the wrist joint. It is formed by the following small branches: 1. The volar carpal branch of the radial; 2. the volar carpal branch of the ulnar; 3. volar terminal branches of the volar interosseous; and 4. recurrent branches from the deep volar arch. Fig. 50.

The Superficial Volar (Palmar) Arch

is formed by the anastomosis of the terminal branch of the ulnar artery with the superficial volar branch of the radial. It is convex distally and lies between the palmar aponeurosis and the sheaths of the Flexor tendons, at about the middle of the length of the palm of the hand. From its convexity the *common volar digital arteries* II—IV arise; in the region of the finger webs these divide into *proper arteries* for the sides of the three middle fingers, the proper artery for the fifth digit arising independently from the ulnar artery and the three radial ones from the princeps pollicis. Fig. 49.

The Deep Volar (Palmar) Arch.

On its entrance into the palm of the hand the radial artery (see p. 48) divides into the a. princeps pollicis and the chief branch to the deep arch.

The *a. princeps pollicis* divides between the thenar muscles into the *proper volar radial digital artery* for the thumb and a short stem, the *volar digital artery I*, which supplies the adjacent sides of the thumb and index finger; it represents a volar metacarpal artery 1. Fig. 50.

The *deep volar (palmar) arch* is formed chiefly by the anastomosis of the terminal branch of the radial artery with the deep volar branch of the ulnar. It is situated more proximally than the superficial arch and is less convex, though longer, and it lies between the Interossei volares and the sheaths of the Flexor tendons and the Adductor pollicis. From it there arise, in addition to small branches to the volar carpal rete, the *volar metacarpal arteries* II—IV, which supply the Interossei and, in the region of the capitula of the metacarpal bones, anastomose with the common volar digital arteries. Fig. 50.

Fig. 49. The middle layer of the nerves and arteries of the palm of the hand. (2/3)
The palmar aponeurosis is removed and the Abductor pollicis brevis divided along the superficial volar branch of the radial artery. * = Anastomosis of the median and ulnar nerves.

Fig. 50. The deep layer of the nerves and arteries of the palm of the hand. (2/3)
The Abductor pollicis brevis, Adductor pollicis and Flexor digiti V are cut. The tendons of the Flexors, the median nerve, the superficial volar branch of the ulnar nerve and the superficial volar arch have been removed. + = articular branch of the deep branch of the ulnar nerve.

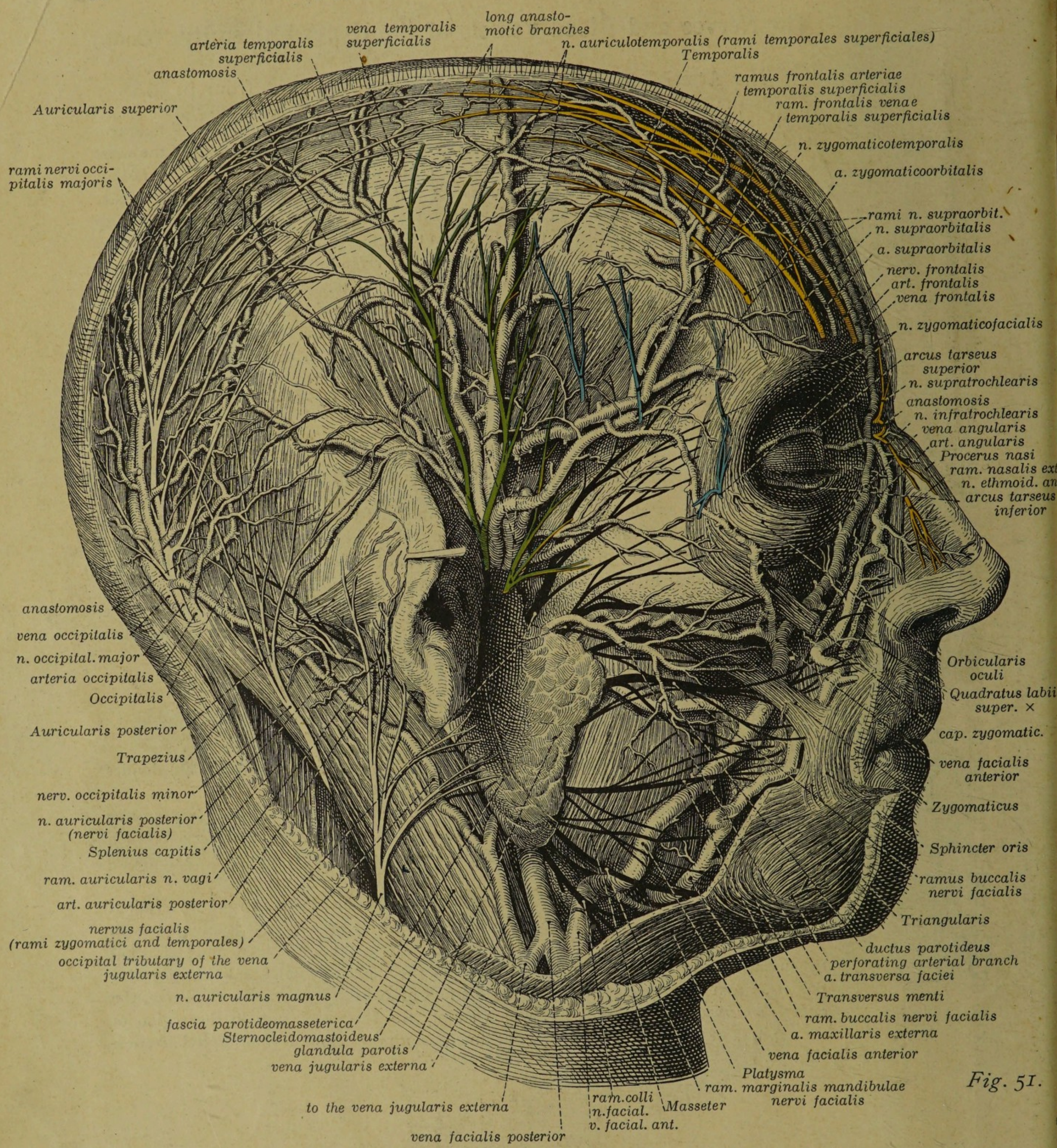

Fig. 51.

Fig. 51 and 52. The superficial nerves and blood vessels of the head. (2/3)

In Fig. 51 the branches of the facial nerve are black, those of the cervical nerves white, those of the ophthalmic division of the trigeminus yellow, those of the maxillary division blue and those of the mandibular division green. A portion of the platysma is removed and the Quadratus labii superioris is cut.

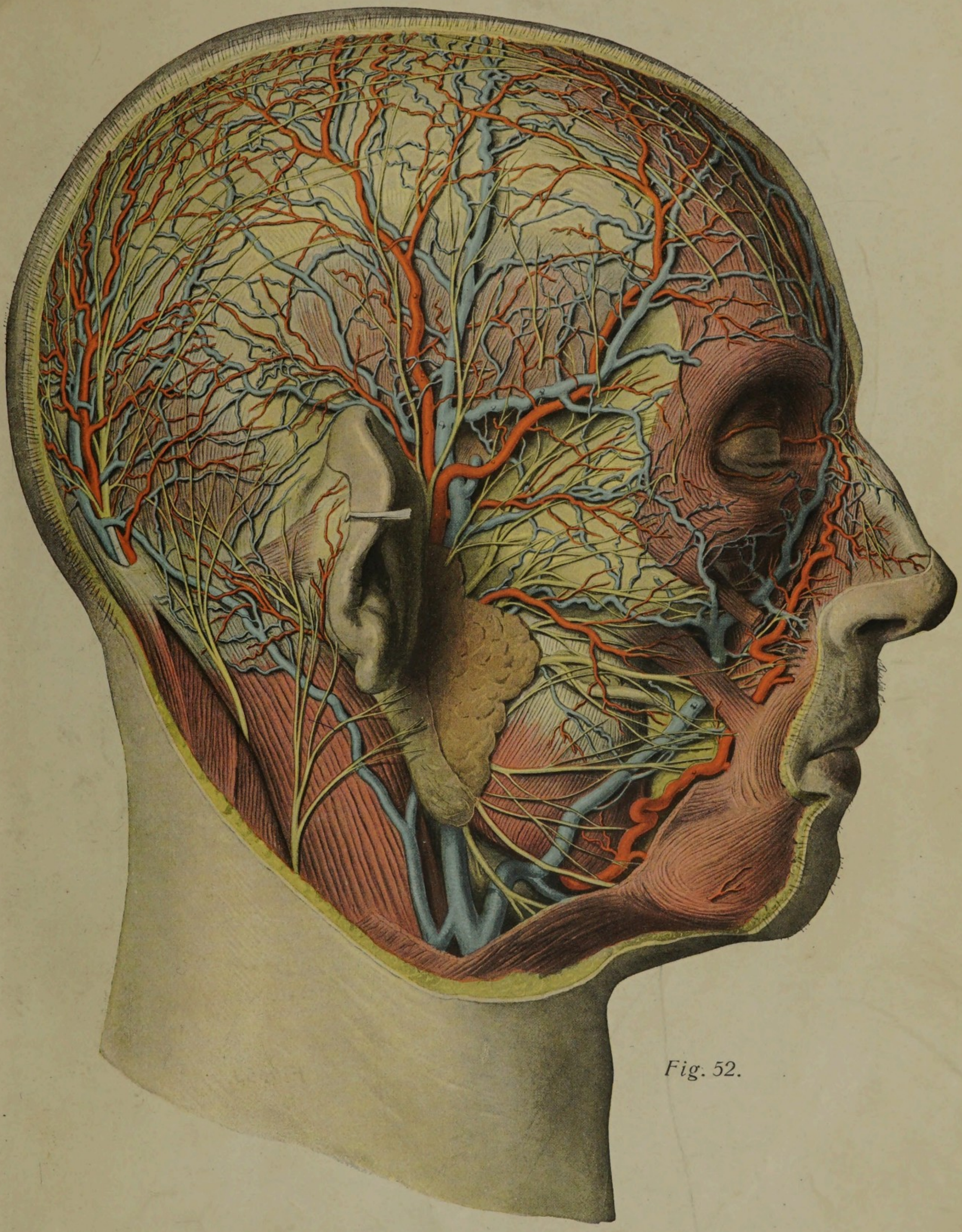

Fig. 52.

Fig. 53.

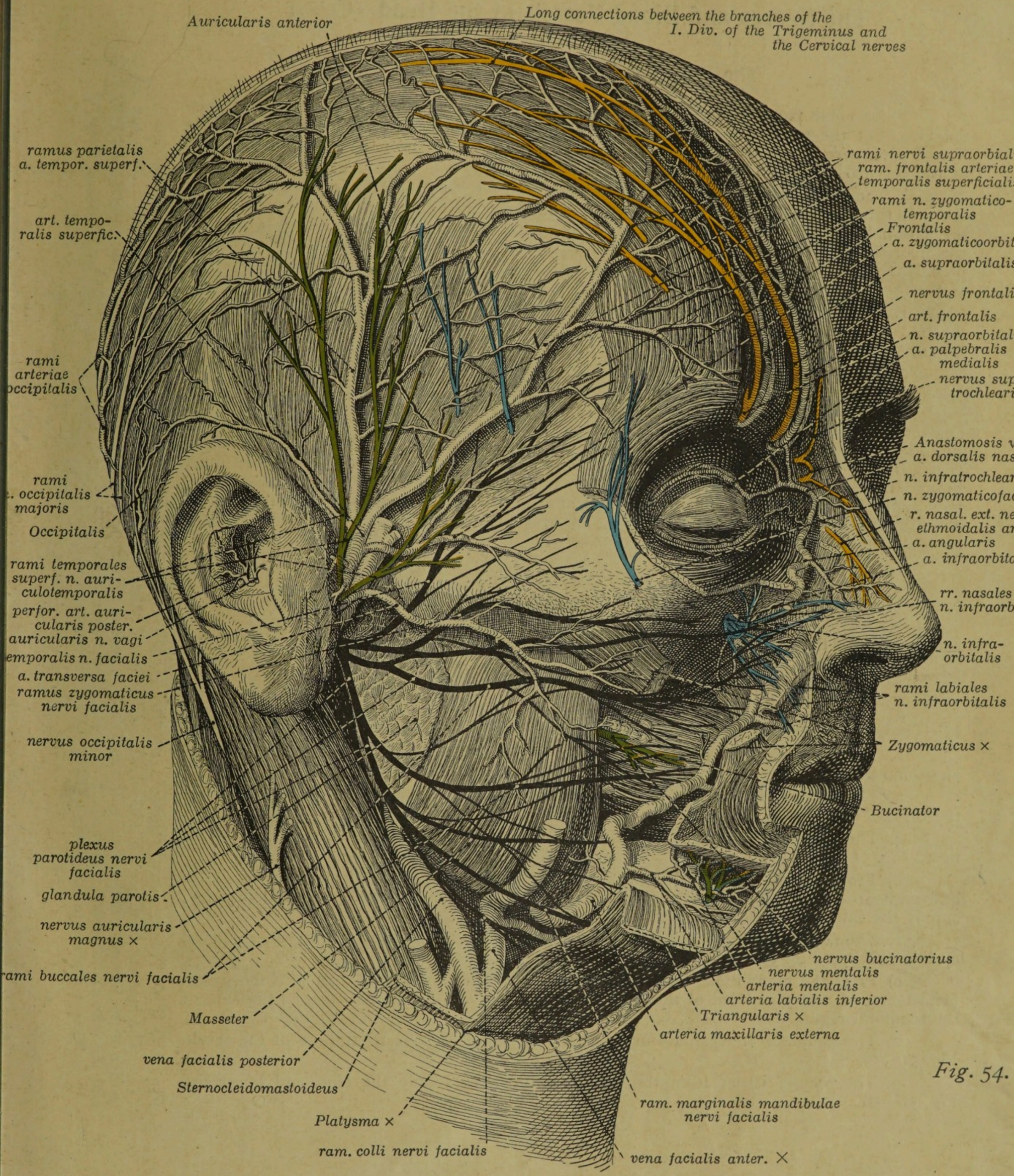

Fig. 54.

Fig. 53 and 54. The deep layer of the superficial nerves and arteries of the face. (2/3)

The parotid gland is largely removed and a number of facial muscles are either cut or divided for a distance or partly removed. The nerves are colored as in Fig. 51.

The Nerves and Blood Vessels of the Head. (Cont.)

The Superficial Nerves of the Head.

These come partly from the facial nerve, motor branches for the mimetic facial musculature, but the sensory nerves come from all three divisions of the Trigeminus, from the Vagus (*n. auricularis*, see p. 85), from the cervical plexus and from the posterior branches of the cervical nerves.

I. The **facial nerve,** in its extracranial portion (see p. 80), is a motor nerve. It leaves the skull through the stylo-mastoid foramen and runs in a gentle curve, concave upward, below the external auditory meatus between the lobes of the parotid gland, covered, however, by the main mass of the gland and divided into several anastomosing branches (the parotid plexus). At the anterior border of the gland it gives off its terminal branches to the muscles of the face. Fig. 51—55. Its branches are:

1. The *posterior auricular nerve* arises soon after the exit of the nerve from the stylo-mastoid foramen and passes behind the ear to the Auricularis posterior and the Occipitalis. Fig. 9, 51, 52, 55.

2. The *digastric branch* to the posterior belly of the Digastricus and to the Stylohyoideus. Fig. 55, 71.

The following branches arise from the parotid plexus: 3. *ramus colli* to the Platysma, anastomosing with the cutaneus colli. Fig. 10, 51—54. 4. the *marginal mandibular branch* running along the mandible to the muscles of the chin and lower lip. Fig. 51—54. 5. *buccal branches* passing transversely over the Masseter to the Bucinator, to the muscles of the upper lip and nose, and to part of the Orbicularis oculi. Fig. 51—54. 6. *zygomatic branches* running along the zygoma with the transverse facial artery to the Zygomaticus, Orbicularis oculi, etc. Fig. 51—54. 7. *temporal branches* passing over the temporal fascia to the Auricularis, Frontalis and Orbicularis oculi. Fig. 51—54.

The Sensory Nerves of the Head.

A. From the cervical plexus: the *great auricular* and the *lesser occipital nerves* (see p. 505)

B. The *great occipital nerve* (see p. 36)

C. Branches of the Trigeminus (see p. 76)

a) From the ophthalmic (I) division: 1. The *frontal*, to the skin of the forehead. Fig. 51—58.

2. The *supraorbital*, to the skin of the forehead and to the scalp as far up as the vertex, anastomosing with the greater occipital. Fig. 51—58.

3. The *supratrochlear* and *infratrochlear* and their anastomosis at the inner angle of the orbit. Fig. 51—58.

4. The *external nasal*, a branch of the anterior ethmoidal nerve to the surface of the nose. Fig. 51—58.

b) From the maxillary (II) division: 1. The *zygomatic* goes, as its *zygomatico-facial* and *zygomatico-temporal* branches, through the zygomatic bone and the temporal fascia to supply the skin over these structures. Fig. 51—55.

2. The *infraorbital* makes its exit through the infraorbital foramen to supply the nose, eyelids and lips. Fig. 53—59, 70, 71.

c) From the mandibular (III) division: 1. The *auriculo-temporal* runs with the superficial temporal artery in front of the ear to give *superficial temporal branches* to the skin of the temporal region. Fig. 51—58.

2. The *bucinator* pierces the Bucinator to supply the mucous membrane of the cheek. Fig. 51—59.

3. The *mental* issues from the mental foramen to supply the chin and lower lip. Fig. 51—58.

Fig. 55. The Nerves and Vessels of the Head, third layer. (2/3)
The masseter is divided in the middle and reflected; the two layers of the temporal fascia are reflected from the upper border of the zygoma; the parotid gland and facial nerve are completely removed; several of the facial muscles are removed; and the mandibular canal is opened. * = anastomosis between the supra- and infratrochlear nerves.
** = tributary to the posterior facial vein from the pterygoid plexus.

fascia temporalis ×
vena temporalis media
ram. frontalis art. temporal. superf. ×
Frontalis
Temporalis
n. zygomaticotemporalis
ram. parietalis art. temporalis superficialis
Auricularis
art. temporalis media
rami n. supraorbitalis
arteria supraorbitalis
arteria frontalis
nervus frontalis
n. zygomaticofacialis
Masseter ×
art. dorsalis nasi
nervus supra-trochlearis
*
nervus infra-trochlearis
art. angularis
r. nasal. extern. n. ethmoid. ant.
ramus palpebralis n. infraorbit.
rami labiales n. infraorbit.
Auricularis post.
nerv. occipitalis major
arteria occipitalis
ramus auricularis n. vagi
r. auricularis poster. n. facialis
Trapezius
a. temporalis superficialis
nervus auriculotemporalis
arteria zygomaticoorbitalis
nervus occipitalis minor
processus mastoideus
art. auricularis posterior
nervus facialis ×
ram. digastricus n. facialis
Sternocleidomastoideus ×
**
arteria occipitalis
Stylohyoideus
n. glossopharyngeus
Digastricus (vent. post.)
arteria carotis externa
Masseter ×
arteria maxillaris externa
art. carotis int.
art. lingualis
art. carotis externa post.
vena facialis communis
anter. nerv.+art. masseterica
vena sub-mentalis
n. infraorbitalis
Zygomaticus ×
Quadrat. labii super. ×
vena anastomatica facialis
arteria maxillaris externa
Sphincter oris
Bucinator
arteria bucinatoria
nervus mentalis
arteria mentalis
nervus bucinatorius
nervus alveolaris inferior
arteria alveolaris inferior
arteria maxillaris externa ×
Digastricus (venter anterior)

Fig. 55.

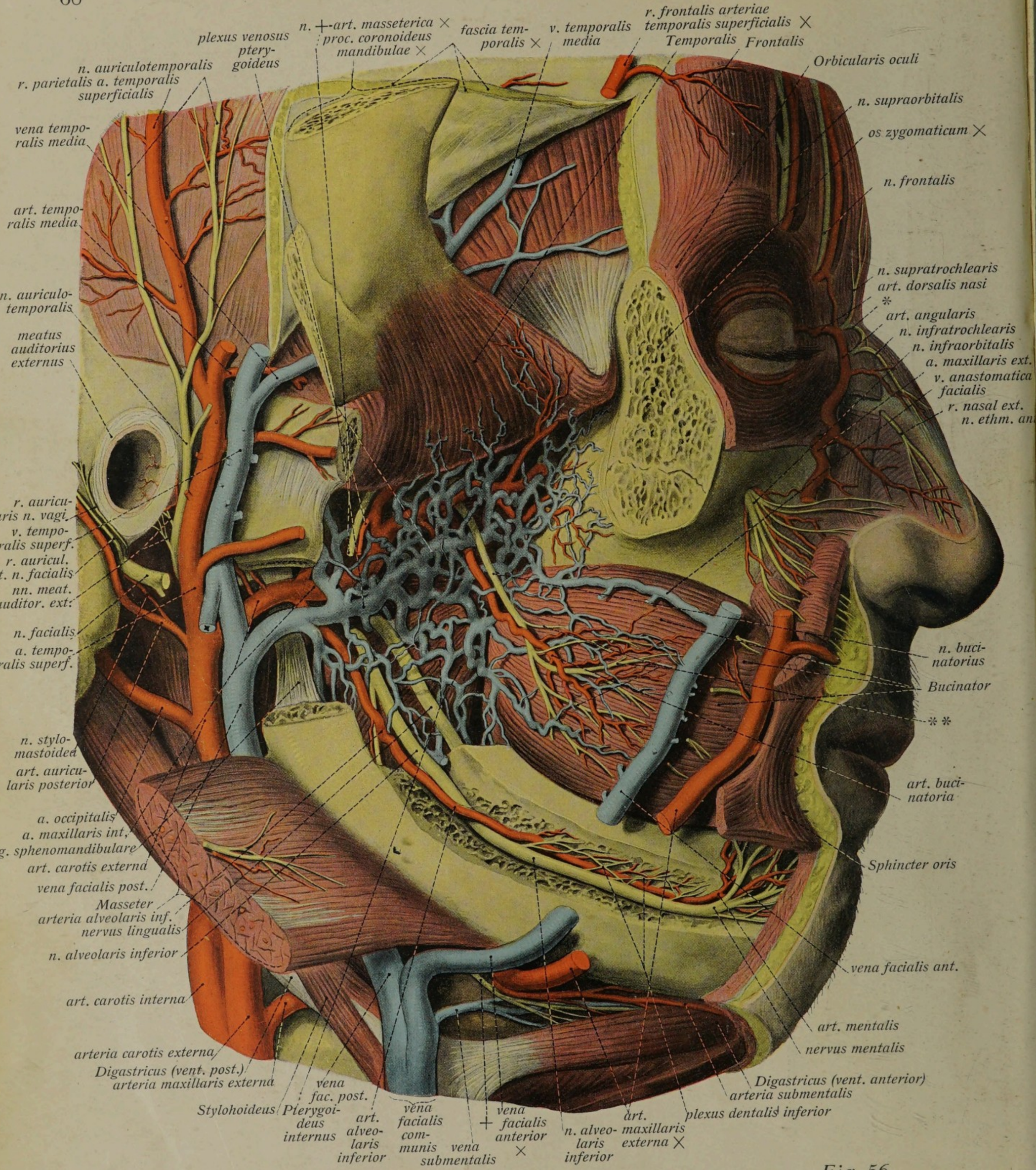
n. auriculotemporalis
r. parietalis a. temporalis superficialis
vena temporalis media
art. temporalis media
n. auriculotemporalis
meatus auditorius externus
r. auricularis n. vagi
v. temporalis superf.
r. auricul. post. n. facialis
nn. meat. auditor. ext.
n. facialis
a. temporalis superf.
n. stylomastoidea
art. auricularis posterior
a. occipitalis
a. maxillaris int.
lig. sphenomandibulare
art. carotis externa
vena facialis post.
Masseter
arteria alveolaris inf.
nervus lingualis
n. alveolaris inferior
art. carotis interna
arteria carotis externa
Digastricus (vent. post.)
arteria maxillaris externa
Stylohoideus
Pterygoideus internus
vena fac. post.
art. alveolaris inferior
vena facialis communis
vena submentalis
vena facialis anterior
n. alveolaris inferior
art. maxillaris externa
plexus venosus pterygoideus
n. + art. masseterica
proc. coronoideus mandibulae
fascia temporalis
v. temporalis media
r. frontalis arteriae temporalis superficialis
Temporalis
Frontalis
Orbicularis oculi
n. supraorbitalis
os zygomaticum
n. frontalis
n. supratrochlearis
art. dorsalis nasi
*
art. angularis
n. infratrochlearis
n. infraorbitalis
a. maxillaris ext.
v. anastomatica facialis
r. nasal ext.
n. ethm. an
n. buccinatorius
Bucinator
* *
art. buccinatoria
Sphincter oris
vena facialis ant.
art. mentalis
nervus mentalis
Digastricus (vent. anterior)
arteria submentalis
plexus dentalis inferior

Fig. 56.

The Nerves and Blood Vessels of the Head. (Cont.)

Fig. 56. The Nerves and Vessels of the Head, fourth layer, the deep facial veins. (1/1)

The zygoma is removed, the Temporalis with the coronoid process of the mandible is reflected upwards, the neck of the mandible is removed, the outer ear is cut away and the mandibular canal is opened throughout its entire length.

* = anastomosis between the infra- and supratrochlear nerves. ** = branches to the bucinator muscle which pierce the muscle to supply the mucous membrane of the cheek. + = mylohyoid nerve. × (on the vein) = cut connection with the external jugular vein.

The Veins of the Face.

1. The *anterior facial vein* is formed at the medial angle of the orbit by the anastomosis of the angular vein with the frontal and supraorbital. Its course and branches correspond in general to those of the external maxillary (facial) artery, behind which it lies, but it receives a tributary, the *facial anastomotic vein*, from the deep pterygoid plexus. Below the angle of the mandible it receives the *submental vein* and forms with the posterior facial the common facial vein. Fig. 7—9, 14, 15, 51, 52, 55, 56.

2. The *posterior facial vein* is formed mainly by the superficial temporal veins which accompany the branches of the artery of the same name, lying in front of them. Immediately above the zygoma the superficial temporal vein receives the large middle temporal, which lies between the Temporalis and the fascia temporalis and pierces the latter in this region. It also receives the smaller venae comites of the neighboring arteries of the face, anastomoses with the external jugular and forms, with a short trunk which accompanies the internal maxillary artery for a short distance, corresponding to its branches and draining the *pterygoid venous plexus*, the posterior facial vein. This, covered by the parotid gland, accompanies the terminal portion of the external carotid artery into the submaxillary region. Here it frequently receives the superior thyreoid vein and opens into the common facial. Fig. 7—9, 14, 15, 51, 52, 55, 56.

3. The *common facial vein* is a short, stout trunk, which runs obliquely in the carotid fossa, in front of and lateral to the external carotid artery. It is covered only by the platysma and the superficial layer of the cervical fascia, and opens into the internal jugular vein, often after receiving the lingual vein or the superior thyreoid or a connection with the external jugular vein. Fig. 7, 8 et seq. as above.

The Common Carotid Artery.

The *common carotid artery* on the left side arises directly from the arch of the aorta, on the right from the innominate artery, and runs up the neck in company with the internal jugular vein and the vagus nerve. It is covered at first by the Sterno-mastoideus, later appearing at its anterior border in the carotid fossa, in which, placed rather superficially, it divides into its two terminal branches, the external and internal carotid. It has no other branches. Fig. 7—11, 15, 17, 18, 20, 55, 57, 58.

I. The *external carotid artery* runs upwards through the carotid fossa almost in the line of the common carotid, giving off large branches and diminishing rapidly in caliber. At first it is somewhat superficial, but higher up is covered by the posterior belly of the Digastricus and by the Stylo-hyoideus. Higher still it is covered by the parotid gland, as it runs along the posterior border of the ramus of the mandible up to the level of the neck of that bone. Fig. 8, 9, 13—15, 56—58.

Fig. 58. The nerves and vessels of the head, fifth layer, the internal maxillary artery. (1/1)

The preparation as in Fig. 56, except that the insertion of the Temporalis and the coronoid process of the mandible are completely removed and the muscle divided over the temporal arteries. ++ = the deep auricular and anterior tympanic arteries. +* = deep auricular branches of the auriculo-temporal nerve.

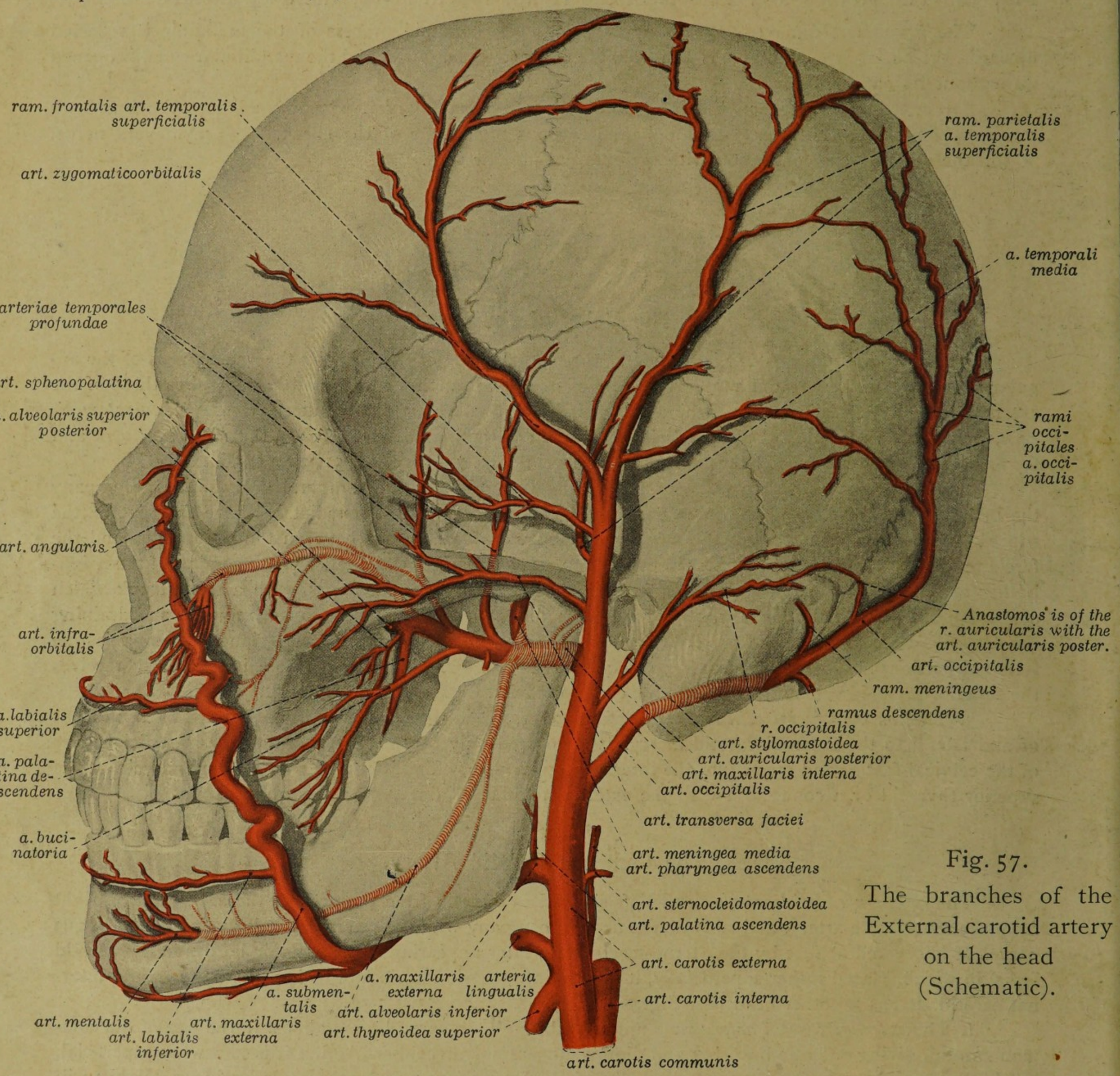

Fig. 57.
The branches of the External carotid artery on the head (Schematic).

The Branches of the External Carotid Artery.

1. The **superior thyreoid artery** arises immediately above the bifurcation of the common carotid and runs at first forwards and upwards, placed somewhat superficially in the carotid fossa. It then bends downwards behind the upper belly of the Omohyoideus to the thyreoid gland. Fig. 8—10, 13, 74, 75. Its branches are: a) the *hyoid branch* to the hyoid bone Fig. 8—10; b) the *superior laryngeal* (see p. 84) Fig. 74, 75; c) the *sterno-mastoid* to the muscle of that name. Fig. 9; and d) *glandular branches* to the thyreoid gland. Fig. 13, 15.

2. The **ascending pharyngeal artery,** see p. 83.

3. The **lingual artery,** see p. 84.

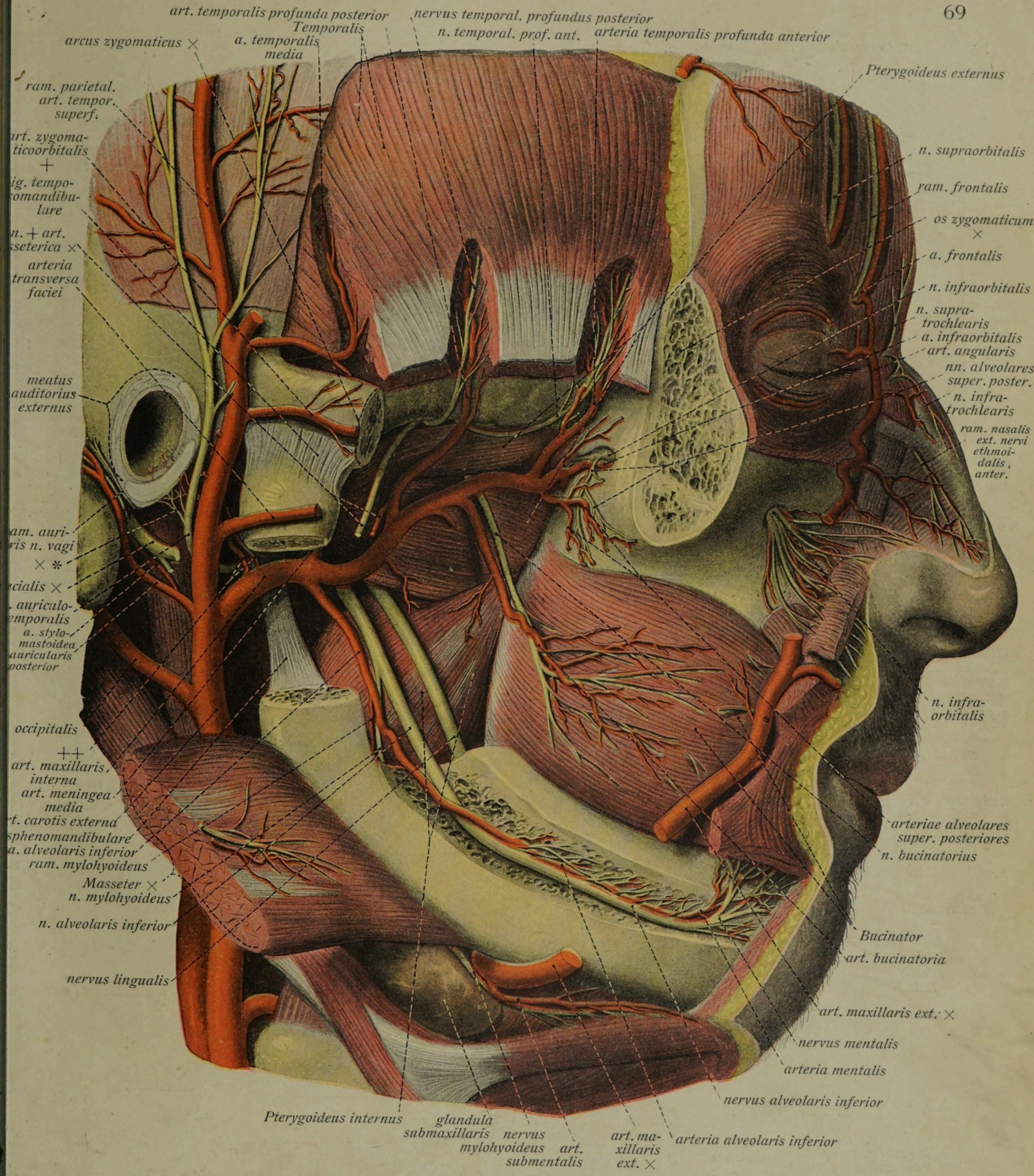
art. temporalis profunda posterior
Temporalis
nervus temporal. profundus posterior
n. temporal. prof. ant.
arteria temporalis profunda anterior
arcus zygomaticus ×
a. temporalis media
ram. parietal. art. tempor. superf.
Pterygoideus externus
n. supraorbitalis
ram. frontalis
os zygomaticum ×
a. frontalis
n. infraorbitalis
n. supra-trochlearis
a. infraorbitalis
art. angularis
nn. alveolares super. poster.
n. infra-trochlearis
ram. nasalis ext. nervi ethmoi-dalis, anter.
meatus auditorius externus
n. infra-orbitalis
arteriae alveolares super. posteriores
n. bucinatorius
Bucinator
art. bucinatoria
art. maxillaris ext. ×
nervus mentalis
arteria mentalis
nervus alveolaris inferior
arteria alveolaris inferior
art. maxillaris ext. ×
art. submentalis
nervus mylohyoideus
glandula submaxillaris
Pterygoideus internus
n. alveolaris inferior
nervus lingualis
Masseter ×
n. mylohyoideus
ram. mylohyoideus
a. alveolaris inferior
art. maxillaris interna
art. meningea media
art. carotis externa
sphenomandibulare
occipitalis
++
n. + art. sseterica ×
arteria transversa faciei
ig. tempo-omandibu-lare
urt. zygoma-ticoorbitalis
+
ram. auri-ris n. vagi
× *
cialis ×
auriculo-emporalis
a. stylo-mastoidea auricularis posterior
meatus auditorius externus

Fig. 58.

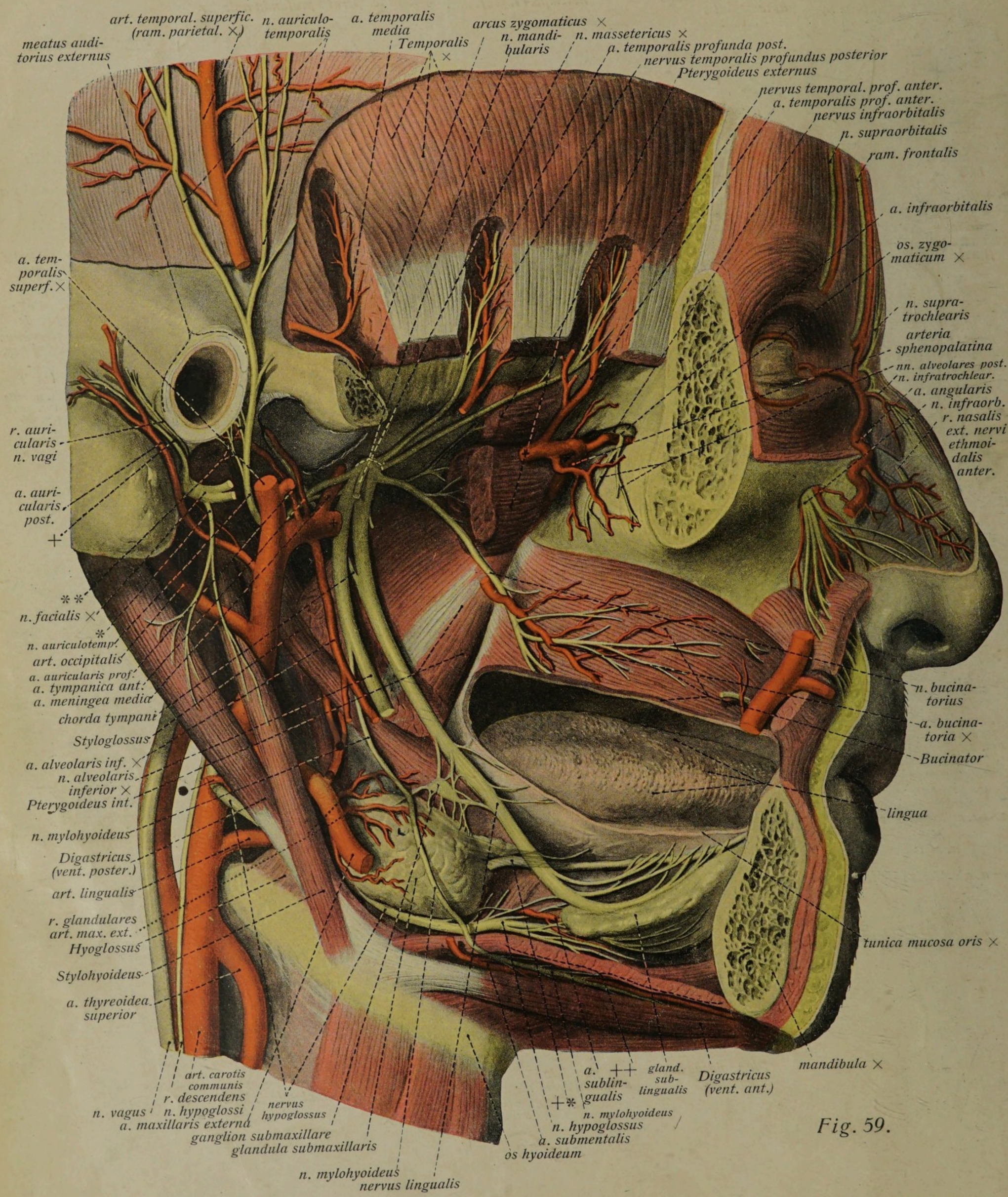
art. temporal. superfic. (ram. parietal. ×)
n. auriculo-temporalis
a. temporalis media
arcus zygomaticus ×
n. mandi-bularis
n. massetericus ×
meatus audi-torius externus
Temporalis ×
a. temporalis profunda post.
nervus temporalis profundus posterior
Pterygoideus externus
nervus temporal. prof. anter.
a. temporalis prof. anter.
nervus infraorbitalis
n. supraorbitalis
ram. frontalis
a. infraorbitalis
os. zygo-maticum ×
n. supra-trochlearis
arteria sphenopalatina
nn. alveolares post. super.
n. infratrochlear.
a. angularis
n. infraorb.
r. nasalis ext. nervi ethmoi-dalis anter.
a. tem-poralis superf. ×
r. auri-cularis n. vagi
a. auri-cularis post.
+
* *
n. facialis ×
*
n. auriculotemp.
art. occipitalis
a. auricularis prof.
a. tympanica ant.
a. meningea media
chorda tympani
Styloglossus
a. alveolaris inf. ×
n. alveolaris inferior ×
Pterygoideus int.
n. mylohyoideus
Digastricus (vent. poster.)
art. lingualis
r. glandulares art. max. ext.
Hyoglossus
Stylohyoideus
a. thyreoidea superior
n. bucina-torius
a. bucina-toria ×
Bucinator
lingua
tunica mucosa oris ×
mandibula ×
art. carotis communis
r. descendens
n. hypoglossi
n. vagus
a. maxillaris externa
nervus hypoglossus
ganglion submaxillare
glandula submaxillaris
n. mylohyoideus
nervus lingualis
a. sublin-gualis
++
gland. sub-lingualis
Digastricus (vent. ant.)
+*
n. mylohyoideus
n. hypoglossus
a. submentalis
os hyoideum

Fig. 59.

The Nerves and Blood Vessels of the Head. (Cont.)

Fig. 59. The nerves and vessels of the head, deepest (6th) layer. The mandibular nerve. ($^1/_1$)

The preparation as in Fig. 58, except that the condyloid process of the mandible is disarticulated; the right half of the mandible and the lower half of the Bucinator have been almost entirely removed. + = posterior auricular nerve. ** = nerves to the external auditory meatus from the auriculo-temporal. * = digastric branch of the facial nerve. ++ = Mylohyoideus cut. +—+ (on the artery) = cut surface of the internal maxillary artery. ●● (on the artery) = ascending palatine artery. ● = stump of the Sterno-mastoid artery. +* = submaxillary duct.

Branches of the External Carotid Artery. (Cont. from p. 68.)

4. The **sterno-mastoid artery** is a small branch that arises immediately above the lingual, almost at the same level as the following. It curves around the hypoglossal nerve and runs through the carotid fossa backwards and downwards to the Sterno-mastoideus. Fig. 9, 10, 13.

5. The **external maxillary (facial) artery** arises from the anterior surface of the external carotid a short distance above the lingual artery. It first ascends somewhat upwards on the medial surface of the posterior belly of the Digastricus and then runs horizontally along the base of the mandible and, at the anterior border of the Masseter, turns upwards over the mandible to the face. There it pursues a tortuous course to the side of the nose, being covered at first only by the Risorius but higher by the Zygomaticus and partly by the Quadratus labii superioris. Fig. 10, 13, 14, 51—58, 114.

Its branches are: a) The *ascending palatine*, sometimes arises directly from the external carotid or from the ascending pharyngeal. It runs upwards on the lateral wall of the pharynx, pierces this wall and passes to the soft palate, giving off a *tonsillar* branch. Fig. 59, 74. b) *Glandular branches* to the submaxillary gland. Fig. 59. c) The *submental*, below the Mylohyoideus, supplying this and the anterior belly of the Digastricus and passing on to the chin. Fig. 9, 10, 13, 14, 56—59. d) The *inferior labial* to the lower lip. Fig. 51—54. e) The *superior labial* to the upper lip. Fig. 51—54. f) The *angular*, the terminal branch, which unites at the medial angle of the orbit with the dorsal nasal branch of the ophthalmic artery. Fig. 51—54.

6. The **occipital artery** arises a short distance above the external maxillary and runs backwards and upwards in a groove on the posterior surface of the mastoid process, covered by the Sterno-mastoideus and the posterior belly of the Digastricus. It passes beneath the Splenius capitis near its insertion and then, piercing the Trapezius, becomes superficial on the occipital region. Fig. 7—10, 13, 25, 51—55, 57. Its branches are: a) The *meningeal branch*, which passes through the mastoid foramen to the dura mater. Fig. 25, 135. b) The *descending branch*, a strong branch to the muscles of the back of the neck. Fig. 13, 25. c) The *auricular* to the region of the ear, where it anastomoses with the posterior auricular. Fig. 7. d) The *occipital branches* which supply the scalp up to the vertex. Fig. 7, 13, 14, 51, 52, 57.

7. The **posterior auricular artery** arises above the preceding and is at first covered by the parotid gland. It runs upwards on the anterior border of the mastoid process to behind the ear, where it divides into *auricular* and *occipital branches*. Fig. 7 et seq. 55, 57—59. In addition to muscular branches it gives off the *stylo-mastoid artery*, which enters the canal of that name, and the *posterior tympanic*, which passes through the canaliculus for the chorda tympani to the tympanic cavity. Fig. 57, 58.

8. The **superficial temporal artery** is the more superficial of the two terminal branches of the external carotid. It passes upwards, covered at first by the parotid gland to which it sends branches, but later being superficial in front of the ear. Fig. 51—59. Its branches are: a) The *transverse facial*, which passes over the Masseter with the zygomatic branches of the facial nerve. Fig. 51—58. b) The *anterior auricular branches* to the external auditory meatus and the concha. Fig. 53, 54. c) The *zygomatico-orbitalis*, passing over the temporal region to the Orbicularis oculi. Fig. 51—54, 57. d) The *middle temporal* pierces the temporal fascia above the zygoma to supply the temporal muscle. Fig. 55—58. e) and f) The *frontal* and *parietal*, the superficial terminal branches to the scalp. Fig. 51—59.

The Nerves and Blood Vessels of the Head. (Cont.)

(Cont. from p. 71.)

9. The **internal maxillary artery,** the deeper and stronger terminal branch of the external carotid, is covered by the Masseter, the ramus of the mandible and the insertion of the Temporalis, and runs forward between the Temporalis and the Pterygoideus externus (or between this and the Pterygoideus internus) to the pterygo-palatine fossa, where its terminal branches are given off. Fig. 56—59.

Its branches are: a) The *deep auricular*, a small branch to the temporo-mandibular joint, the external auditory meatus and the tympanic membrane. Fig. 58, 59. b) The *tympanic*, also small, passes through the petro-tympanic fissure to the tympanic cavity. Fig. 58, 59. c) The *inferior alveolar* passes downwards to the mandibular foramen, giving off a *mylohyoid branch* to the muscle of that name, and then traverses the mandibular canal, sending branches to the teeth. It issues as the *mental artery* from the mental foramen. Fig. 55—59, 114. d) The *middle meningeal* artery to the foramen spinosum (see p. 156). Fig. 57—60, 135. e) The *masseteric artery* passes through the mandibular notch to the Masseter. Fig. 55. f) and g) The *anterior* and *posterior deep temporal* to the Temporalis, passing between the muscle and the bone. Fig. 57—59. Branches from the anterior traverse the zygomatic bone to the orbit and the skin of the cheek. Fig. 57—60. h) The *bucinator* passes between the Masseter and the Bucinator to supply the latter. Fig. 55—59. i) The *pterygoid* branches to the Pterygoid muscles. Fig. 58. k) The *posterior superior alveolar*, of which there are frequently several, passes through foramina in the maxilla to the posterior teeth of the upper jaw. Fig. 57—59, 114. l) The *infraorbital artery* passes through the inferior orbital fissure into the orbit and through the infraorbital canal to the face where it is chiefly supplied. It gives anterior superior alveolar branches to the teeth. Fig. 57—59, 114. m) and n) The two terminal branches, the *descending palatine* and the *spheno-palatine* (see p. 79).

The Oculomotor Nerve

runs beside the internal carotid artery in the wall of the cavernous sinus to the superior orbital fissure and divides on its entrance into the orbit (Fig. 50—53, 114, 135) into 1. A *superior branch*, which passes above the optic nerve to the under surfaces of the Rectus superior and the Levator palpebrae superioris. Fig. 61, 62. 2. An *inferior branch*, stronger than the superior and running beneath the optic nerve; it gives the *short root* to the ciliary ganglion and supplies the Rectus medialis, Rectus inferior and Obliquus inferior. Fig. 61—63.

The Trochlear Nerve

runs beside the internal carotid artery and the oculomotor nerve in the wall of the cavernous sinus (Fig. 60—62, 135, 138, 139) and through the superior orbital fissure into the orbit to supply the Obliquus superior. Fig. 60, 61.

The Abducens Nerve

runs beside the preceding with the internal carotid through the cavernous sinus (Fig. 60, 114, 135) and through the superior orbital fissure to the medial surface of the Rectus lateralis. Fig. 60—62, 135, 138, 139.

Fig. 60. The nerves and arteries of the orbit, superficial layer. (3/2) The roof of the orbit and the periorbita are removed, also the upper part of the lateral wall. The dura mater is divided along the course of the middle meningeal artery and over the semilunar ganglion and the nerves to the orbital muscles. * = accessory branches to the lacrimal gland from the zygomatico-orbital branch of the superficial temporal artery.

Fig. 61. The nerves and arteries of the orbit, second layer. (3/2) The preparation as in Fig. 60, except that the frontal nerve is almost completely removed, as is also some of the orbital fat on the lateral side. The Rectus superior and Levator palpebrae superioris are drawn aside.

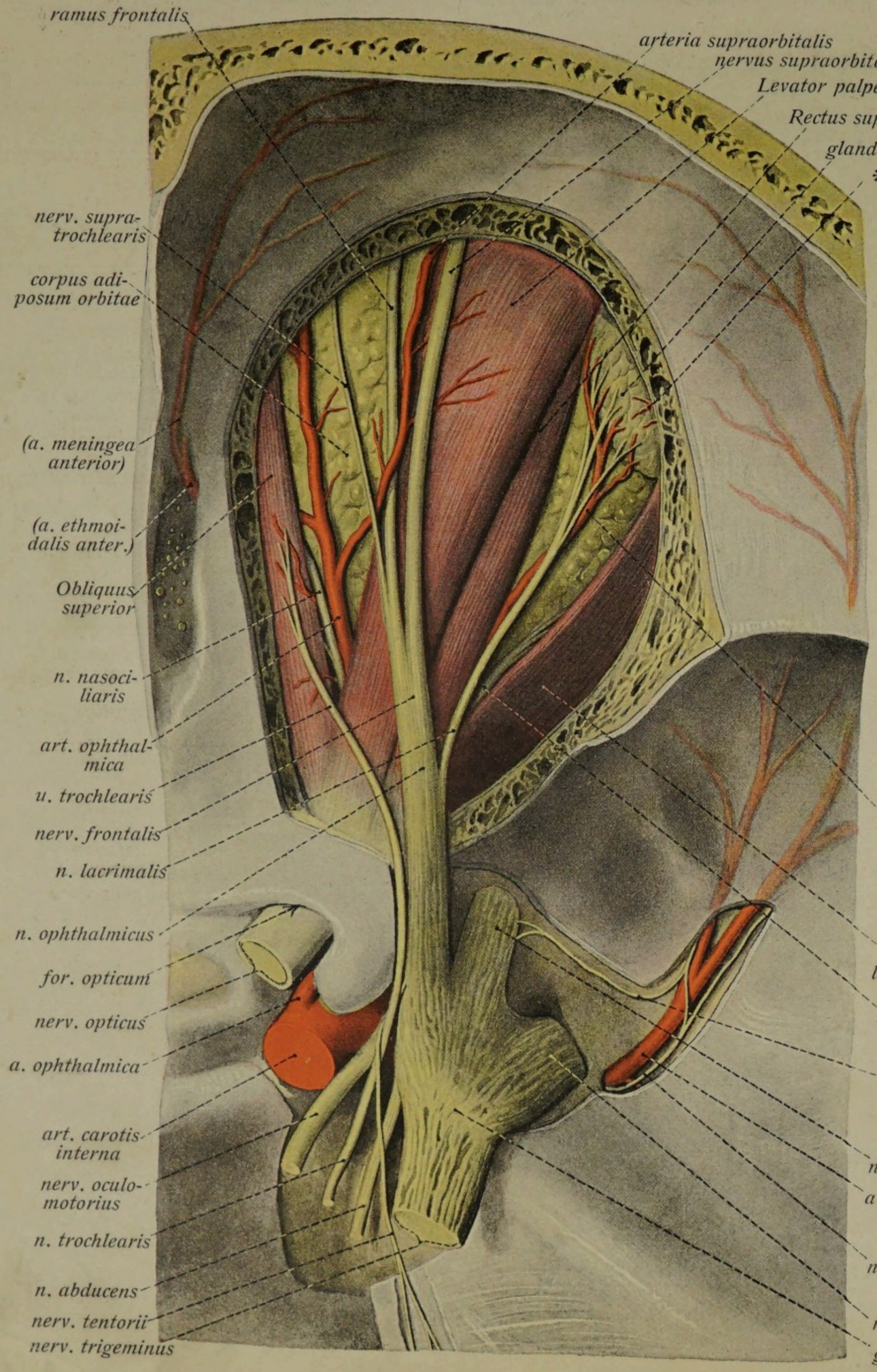
ramus frontalis
arteria supraorbitalis
nervus supraorbitalis
Levator palpebrae superioris
Rectus superior
glandula lacrimalis superior
nerv. supra-trochlearis
corpus adi-posum orbitae
(a. meningea anterior)
(a. ethmoi-dalis anter.)
Obliquus superior
n. nasoci-liaris
art. ophthal-mica
u. trochlearis
nerv. frontalis
n. lacrimalis
n. ophthalmicus
for. opticum
nerv. opticus
a. ophthalmica
art. carotis interna
nerv. oculo-motorius
n. trochlearis
n. abducens
nerv. tentorii
nerv. trigeminus
arteria lacrimalis
Rectus lateralis
n. abducens
n. meningeus medius
n. maxillaris
a. meningea media
n. spinosus
n. mandibularis
ganglion semilunare

Fig. 60.

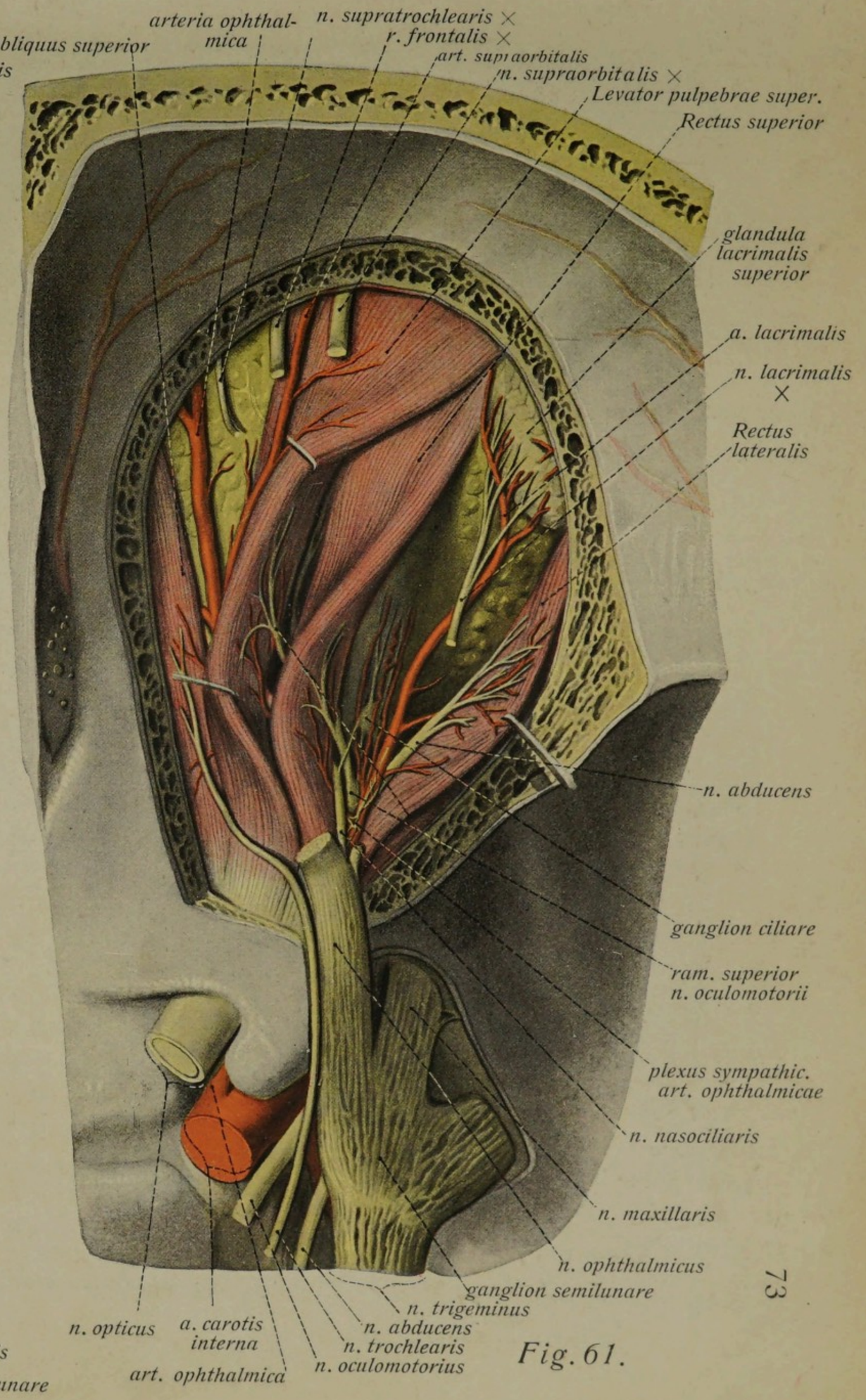
Obliquus superior
arteria ophthal-mica
n. supratrochlearis ×
r. frontalis ×
art. supraorbitalis
n. supraorbitalis ×
Levator pulpebrae super.
Rectus superior
glandula lacrimalis superior
a. lacrimalis
n. lacrimalis ×
Rectus lateralis
n. abducens
ganglion ciliare
ram. superior n. oculomotorii
plexus sympathic. art. ophthalmicae
n. nasociliaris
n. maxillaris
n. ophthalmicus
ganglion semilunare
n. trigeminus
n. opticus
a. carotis interna
art. ophthalmica
n. abducens
n. trochlearis
n. oculomotorius

Fig. 61.

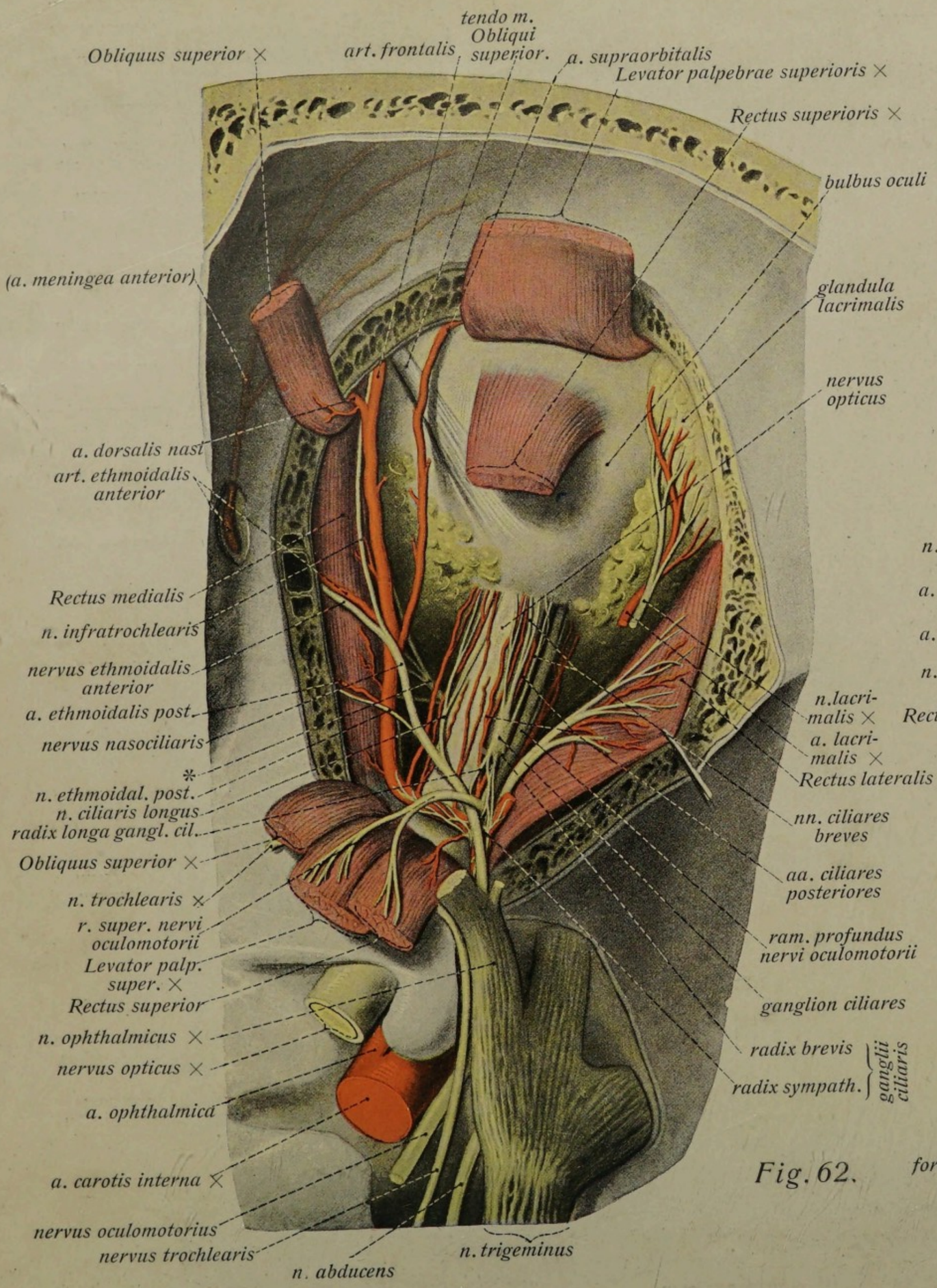

Fig. 62.

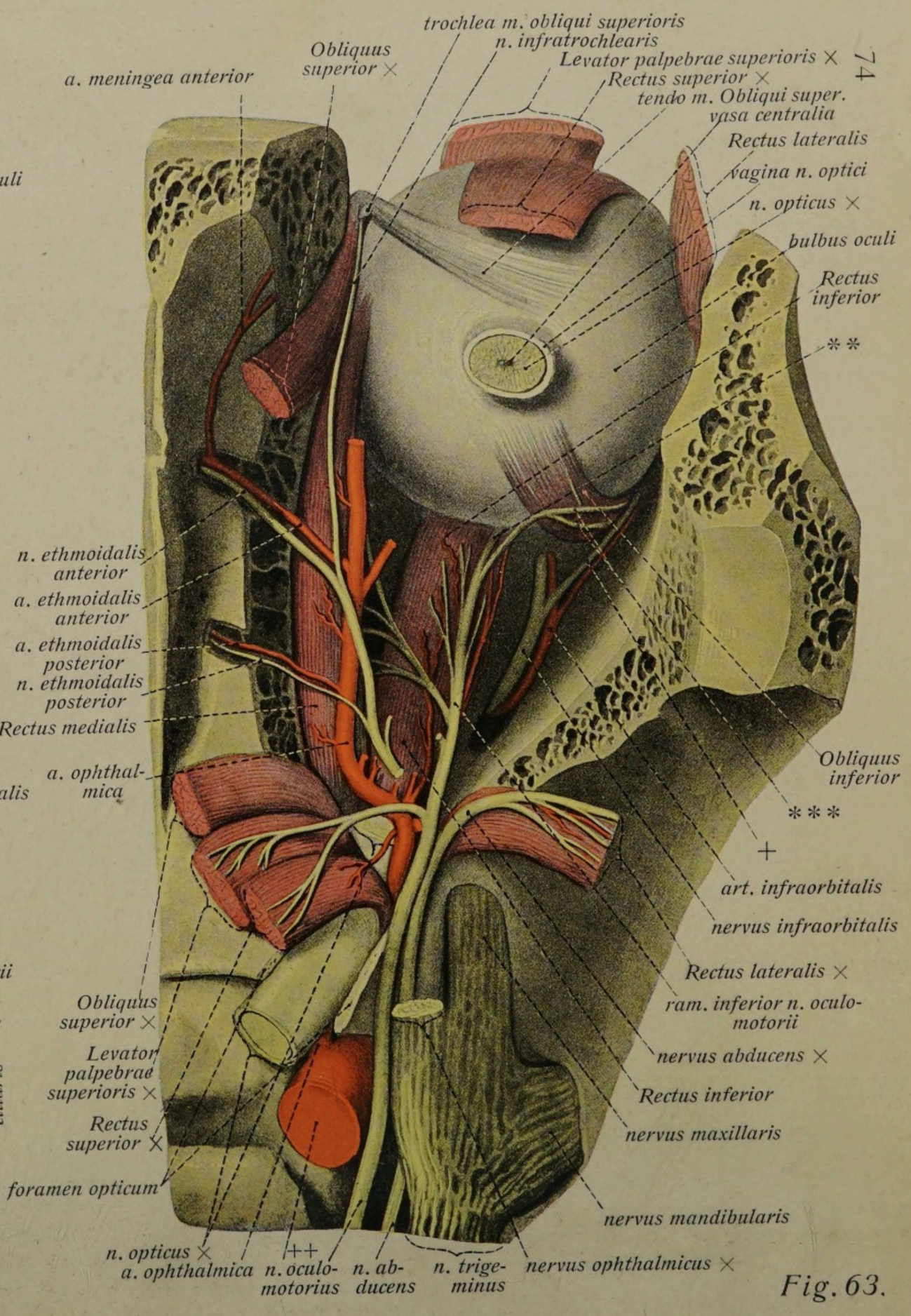

Fig. 63.

Fig. 62. The nerves and arteries of the orbit, third layer. (a/2) The preparation as in Fig. 61 and, in addition, the Rectus superior, Obliquus superior and Levator palpebrae superioris are cut. The Rectus lateralis is drawn aside. * = branch of oculomotor to Rectus medialis.

Fig. 63. Nerves and Arteries of the Orbit, fourth layer. (a/2) Preparation as in Fig. 62, but, in addition, the Rectus lateralis, the optic nerve and the anterior end of the ophthalmic artery are cut. The eyeball, with the stump of the optic nerve is reflected

The Nerves and Blood Vessels of the Head. (Cont.)

The Ophthalmic Artery.

The ophthalmic artery is the only large branch given off by the internal carotid before it reaches the brain (see p. 167). It passes through the optic foramen below the optic nerve and then inclines to the lateral side of the nerve, giving off its first branches. It then crosses above the optic nerve to the medial surface of the orbit and passes to the vicinity of the pulley for the Obliquus superior. Fig. 60—63, 138. Its branches are:

1. The *lacrimal* runs superficially between the Rectus superior and the Rectus lateralis to the lacrimal gland, supplying this and the neighboring muscles. It terminates in the lateral palpebral arteries to the eyelids. Fig. 60, 61, 70.

2. *Muscular branches* to the orbital muscles. Fig. 60—63.

3. The *long and short posterior ciliary arteries* accompany the optic nerve to the eyeball and pierce the sclerotic. They arise in part from the larger branches of the ophthalmic artery; one of them, *a. centralis retinae*, penetrates the optic nerve on its lower lateral surface. Fig. 61, 62, 248, 249.

4. The *anterior ciliary arteries* are small branches, for the most part from other branches of the ophthalmic. They pass to the anterior part of the eyeball. Fig. 248.

5. The *supraorbital artery* runs above the Levator palpebrae superioris to the supraorbital foramen or notch, where it branches to follow the distribution of the supraorbital nerve. Fig. 51—56, 58, 62.

6. The *posterior ethmoidal artery*, a small branch to the ethmoidal cells and the upper part of the nasal mucous membrane. Fig. 62—65.

7. The *anterior ethmoidal artery* passes through the anterior ethmoidal foramen into the cranial cavity, where it gives off an anterior meningeal branch. It then passes through the cribriform plate of the ethmoid into the nasal cavity, supplying its upper anterior part. Fig. 60, 62—65.

8. The *medial palpebral arteries*, from the terminal part of the artery, form with the lateral palpebrals the *superior* and *inferior tarsal arches* in the eyelids. Fig. 53, 54, 58, 59.

9. The *frontal artery*, one of the terminal branches, runs with the frontal nerve through the frontal notch to the forehead. Fig. 51—56, 58, 62.

10. The *dorsal artery of the nose*, the other terminal branch, emerges through the Orbicularis oculi at the medial angle of the orbit and anastomoses with the angular artery. Fig. 55, 56.

The Ophthalmic (I) Division of the Trigeminal Nerve

runs beside the internal carotid artery and the nerves to the orbital muscles in the wall of the cavernous sinus, where it gives off a *tentorial branch*, and at the superior orbital fissure, lying superficially, it divides into three terminal branches. Fig. 60, 61, 68—71, 135, 138, 139.

1. The **frontal nerve**, a strong, flattened branch, lies immediately beneath the periorbita above the Levator palpebrae superioris, and divides into three branches. a) The *supraorbital*, distributed to the forehead with the supraorbital artery. Fig. 51—56, 58—61, 68. b) The *frontal*, weaker than the supraorbital but with a similar distribution. Fig. 51—56, 58—61, 68. c) The *supratrochlear*, quite small, passes above the pulley for the Obliquus superior to the skin over the medial angle of the orbit, uniting with the infratrochlear. Fig. 51—56, 58, 59, 61, 68.

2. The **lacrimal nerve** passes with the lacrimal artery to the lacrimal gland, the conjunctiva, the eyelid, uniting with the zygomatic nerve. Fig. 60—62, 68, 70, 114.

3. The **naso-ciliary** (nasal) **nerve** is at first lateral to the optic nerve, but crosses over this to pass towards the medial wall of the orbit, where it divides into its branches between the Obliquus superior and the Rectus medialis. Fig. 60—63. In addition to the long root to the ciliary ganglion (see p. 76) its branches are: a) The *long ciliary nerves*, several slender nerves that pass with the short ciliaries (see p. 76) to the eyeball. Fig. 62, 255. b) The *posterior ethmoidal nerve*, very small, passes with the posterior ethmoidal artery to the posterior ethmoidal cells. Fig. 63. c) The *anterior ethmoidal nerve*, the stronger terminal branch, passes with the anterior ethmoidal artery into the cranial cavity and then into the nasal cavity through the cribriform plate. Its internal branch supplies the mucous membrane of the nose, its external branch the skin of the nose (see p. 64). Fig. 62—66. d) The *infratrochlear*, the smaller terminal branch, passes beneath the pulley of the Obliquus superior to the conjunctiva, the eyelids and the lacrimal sac; it anastomoses with the supratrochlear. Fig. 51—56, 58, 59, 63.

Fig. 62. The nerves and arteries of the orbit, third layer. (3/2) The preparation as in Fig. 61 and, in addition, the Rectus superior, Obliquus superior and Levator palpebrae superioris are cut. The Rectus lateralis is drawn aside. * = branch of oculomotor to Rectus medialis.

Fig. 63. Nerves and Arteries of the Orbit, fourth layer. (3/2) Preparation as in Fig. 62, but, in addition, the Rectus lateralis, the optic nerve and the anterior end of the ophthalmic artery are cut. The eyeball, with the stump of the optic nerve is reflected forward, to show the branching of the inferior branch of the oculomotor nerve; furthermore, the canals for the anterior and posterior ethmoidal arteries and nerves are opened. + = zygomatic nerve. ++ = arteria carotis interna. ** = branch of the oculomotor to the Rectus inferior. *** = to the Obliquus inferior.

The Nerves and Blood Vessels of the Head. (Cont.)

The Ciliary Ganglion.

The ciliary ganglion is a flat, somewhat quadrangular structure about the size of a hemp seed, to whose posterior extremity three roots are attached; the slender *long root* from the naso-ciliary nerve, the strong *short root* from the oculo-motor and fine twigs forming the *sympathetic root* from the internal carotid plexus. From the anterior end of the ganglion the slender *short ciliary nerves* pass along the optic nerve to the eyeball, Fig. 61, 62, 114.

The Maxillary (II) Division of the Trigeminal Nerve

passes through the foramen rotundum into the pterygo-palatine fossa, where it gives off some branches and divides into its terminals. Fig. 66—70. Its branches are:

1. The **meningeal** is given off before the nerve leaves the cranial cavity and passes to the dura mater with the anterior branch of the anterior meningeal artery. Fig. 60, 135.

2. The **spheno-palatine,** usually several short and, frequently, anastomosing branches to the spheno-palatine ganglion (see below).

3. The **zygomatic,** a small branch which is given off in the pterygo-palatine fossa from the main nerve (or from its infraorbital branch). It enters the orbit through the inferior orbital fissure and after coursing along its lateral wall, passes into a canal in the zygomatic bone, where it divides into its terminal branches. a) The *zygomatico-facial* branch passes through the canal of that name and through the Orbicularis oculi to the skin of the cheek. Fig. 51—55. b) The *zygomatico-temporal* anastomoses with the lacrimal nerve (Fig. 70), passes through the zygomatico-temporal canal in the zygomatic bone and through the temporal fascia to the skin of the temporal region; it carries the secretory fibres for the lacrimal gland. Fig. 51—55 (see also p. 64).

4. The **superior alveolar nerves** arise mostly in the pterygo-palatine fossa and pass with the arteries through the alveolar foramina of the maxilla to the roots of the upper molar teeth. Fig. 58, 59, 68, 114.

5. The **infraorbital nerve** is really the continuation of the main nerve. It enters the orbit through the inferior orbital fissure and passes by way of the infraorbital canal and foramen to the face, where it is covered by the Quadratus labii superioris. Fig. 67 to 70. It branches are: a) The *middle superior alveolar*, arises usually before the nerve enters the infraorbital canal and passes, in the lateral wall of the maxillary sinus, to the superior dental plexus (middle teeth). Fig. 69, 114. b) The *anterior superior alveolar* are given off in the infraorbital canal and pass to the anterior teeth. Fig. 69, 114. c) The terminal branches, the *inferior palpebral*, *external nasal* and *superior labial*. Fig. 51—57, 68, 69.

The Spheno-palatine Ganglion

is a flat, triangular structure, situated in the pterygo-palatine fossa, medial to the maxillary nerve and close to the spheno-palatine foramen. It receives three roots: 1. the sensory *spheno-palatine nerves* (see above); 2. the motor (or secretory), *superficial petrosal nerve* from the facial; 3. the sympathetic *deep petrosal nerve* from the internal carotid plexus. The two last run together through the pterygoid canal and are united for a short distance to form the *nerve of the pterygoid canal (Vidian)*. Fig. 66—69, 114.

The ganglion gives off the following branches. a) The *lateral* and *medial superior posterior nasal branches* which pass through the spheno-palatine foramen to the posterior part of the nasal mucous membrane. An especially long medial nasal branch, the *naso-palatine*, passes over the lower part of the nasal septum to the incisive canal. Fig. 65, 69. b) The *inferior posterior nasal branches* arise in the pterygo-palatine canal and supply the inferior and middle conchae. Fig. 66, 67. c) The *palatine nerves* accompany the descending palatine artery through the pterygo-palatine canal. The largest, the *anterior palatine*, leaves the canal by the greater palatine foramen and supplies the hard palate as far forward as the incisive canal. The two smaller *middle* and *posterior palatines* pass to the soft palate, supplying its mucous membrane and also sending motor fibres to the Levator veli palatini, Azygos, Glosso-palatinus and Pharyngo-palatinus. Fig. 65—69.

Fig. 64. The nerves and arteries of the nasal septum and of the tongue. ($^1/_1$) * = sphenoidal sinus.

Fig. 65. The nerves and arteries of the lateral wall of the nose and of the palate. ($^1/_1$) The tongue is displaced and the nasal septum removed except in its lowest part; the mucous membrane of the isthmus of the fauces is divided over the glossopharyngeal nerve and the ascending palatine artery. * = Sphenoidal sinus. + = cut branches to the nasal septum. ** = connection of the naso-palatine and anterior palatine nerves. *+ = mucous membrane of the hard palate.

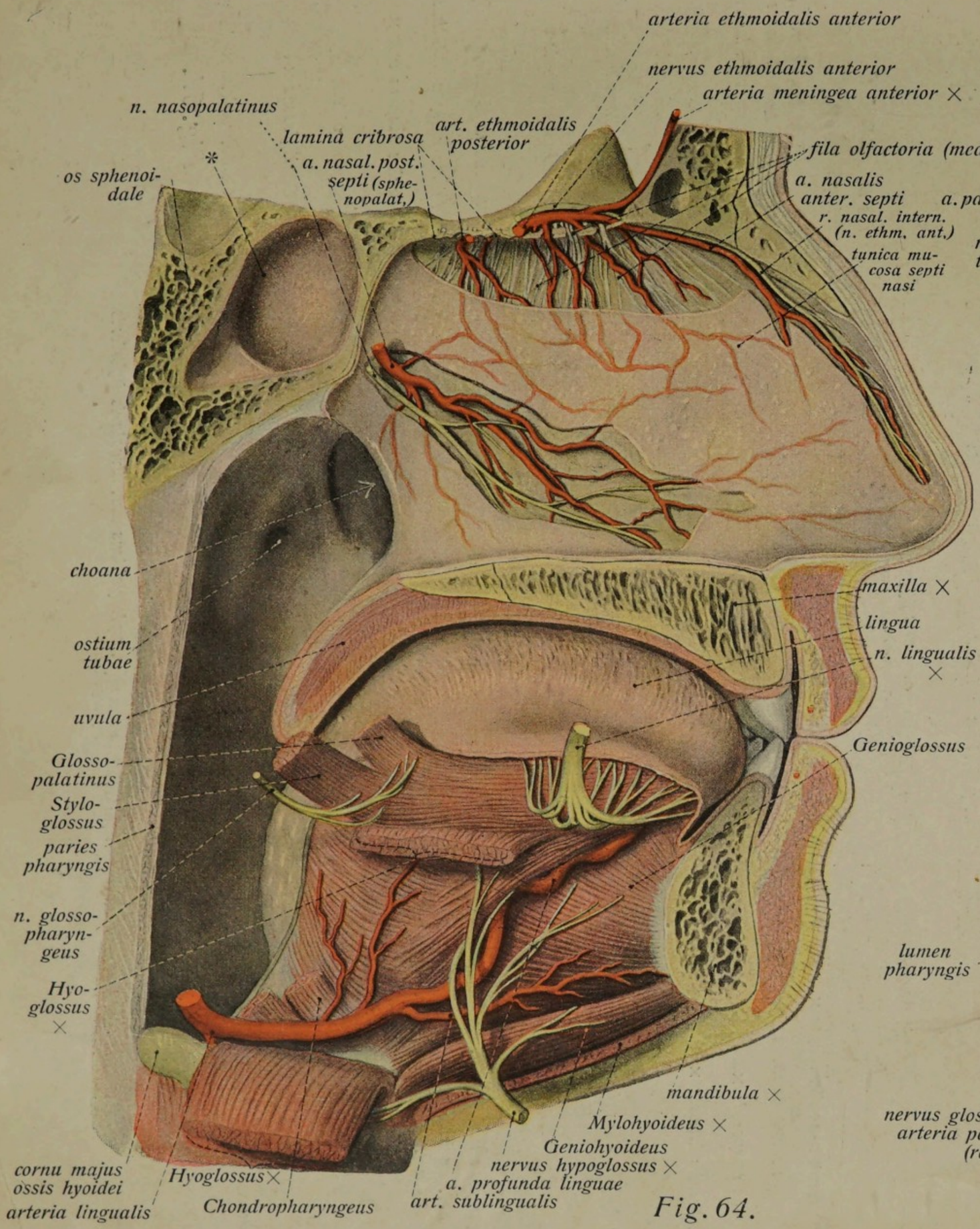
arteria ethmoidalis anterior
nervus ethmoidalis anterior
arteria meningea anterior ×
n. nasopalatinus
lamina cribrosa
art. ethmoidalis posterior
a. nasal. post. septi (sphenopalat.)
os sphenoidale
fila olfactoria (medialia)
a. nasalis anter. septi
r. nasal. intern. (n. ethm. ant.)
tunica mucosa septi nasi
choana
ostium tubae
uvula
Glossopalatinus
Styloglossus
paries pharyngis
n. glossopharyngeus
Hyoglossus ×
maxilla ×
lingua
n. lingualis ×
Genioglossus
mandibula ×
Mylohyoideus ×
Geniohyoideus
nervus hypoglossus ×
a. profunda linguae
art. sublingualis
cornu majus ossis hyoidei
arteria lingualis
Hyoglossus ×
Chondropharyngeus

Fig. 64.

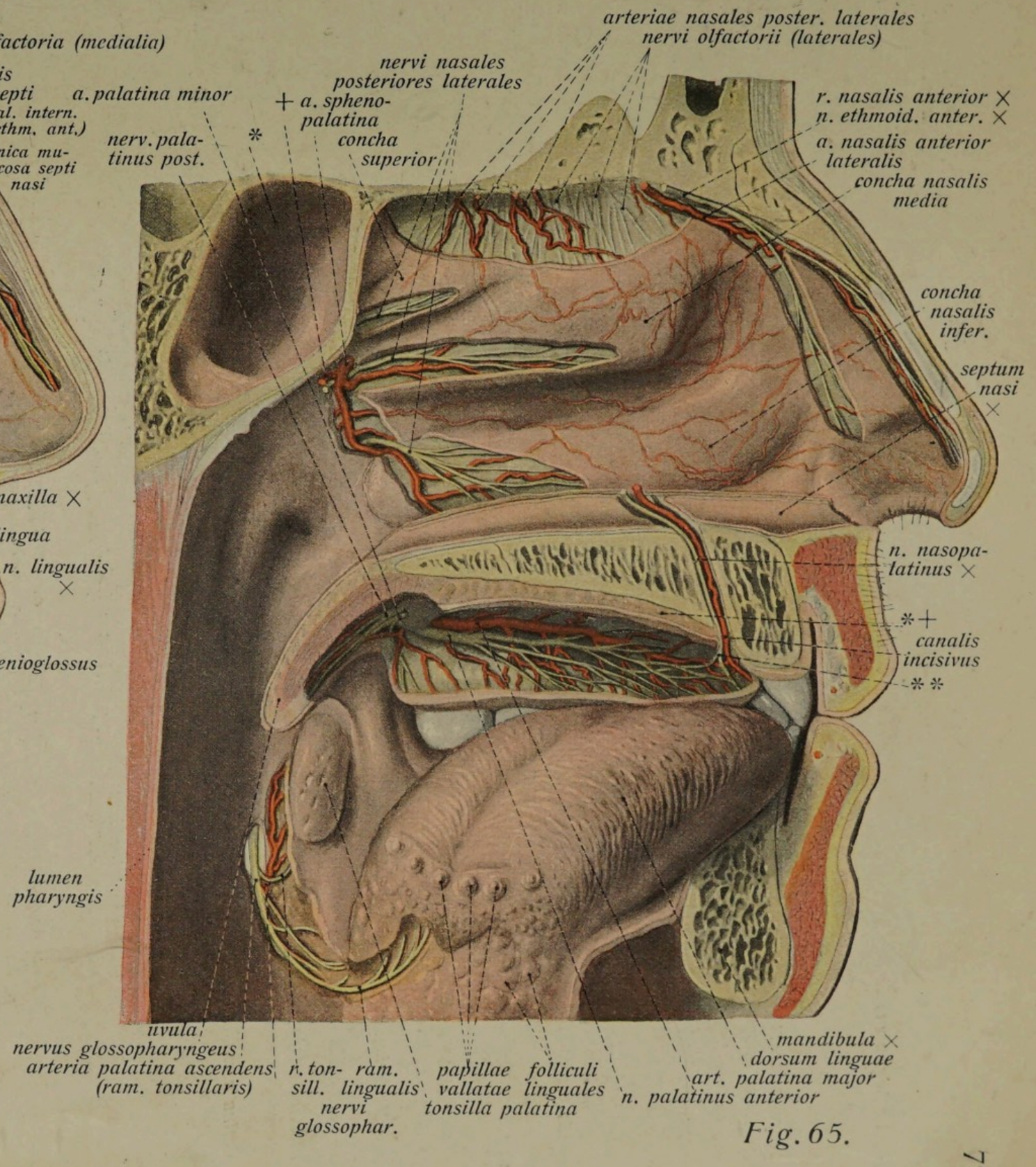
arteriae nasales poster. laterales
nervi olfactorii (laterales)
nervi nasales posteriores laterales
a. palatina minor
+ a. sphenopalatina
concha superior
nerv. palatinus post.
r. nasalis anterior ×
n. ethmoid. anter. ×
a. nasalis anterior lateralis
concha nasalis media
concha nasalis infer.
septum nasi ×
n. nasopalatinus ×
*+ canalis incisivus
**
lumen pharyngis
uvula
nervus glossopharyngeus
arteria palatina ascendens (ram. tonsillaris)
r. tonsill.
ram. lingualis
nervi glossophar.
papillae vallatae
folliculi linguales
tonsilla palatina
n. palatinus anterior
art. palatina major
dorsum linguae
mandibula ×

Fig. 65.

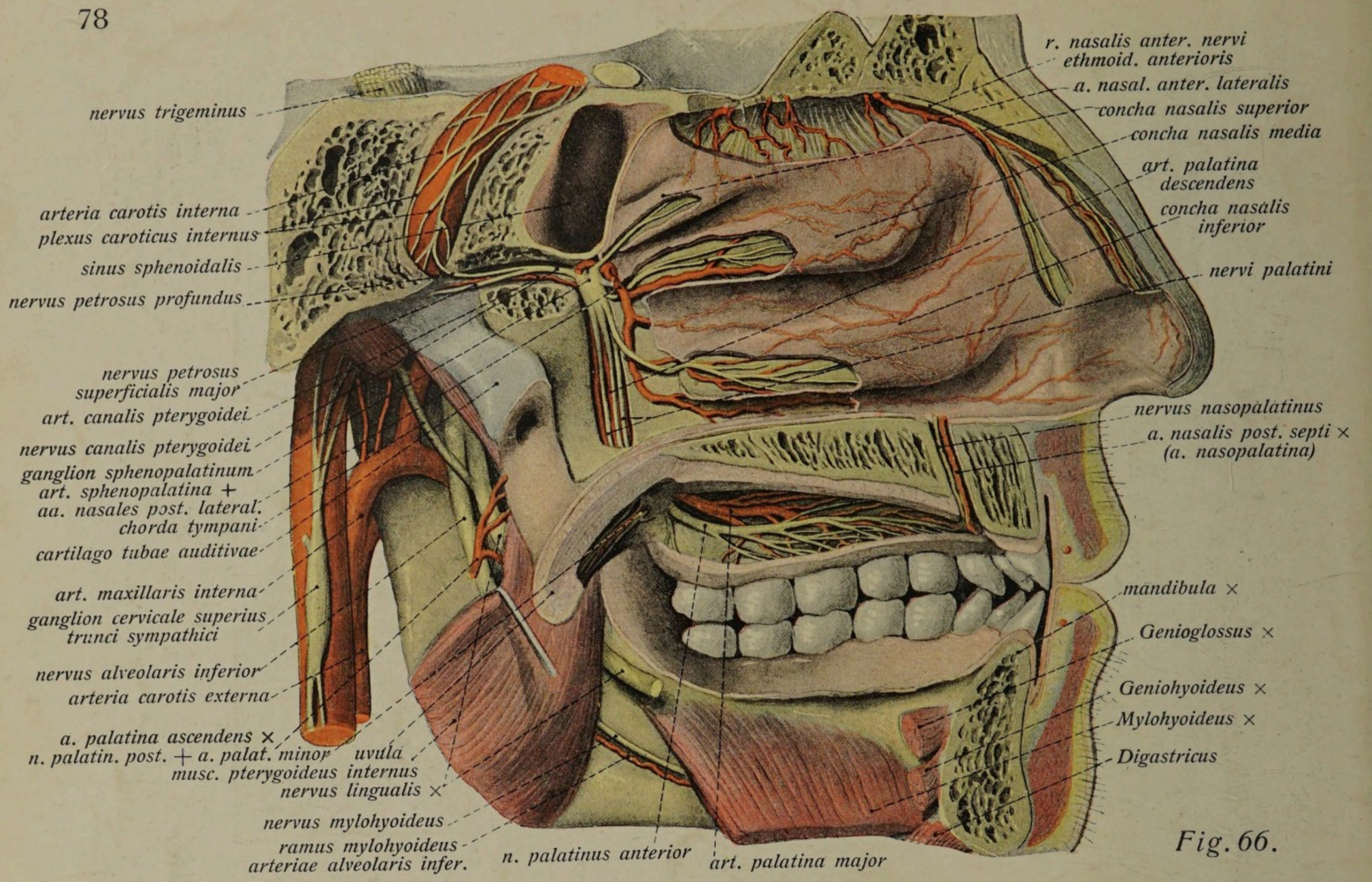
nervus trigeminus
arteria carotis interna
plexus caroticus internus
sinus sphenoidalis
nervus petrosus profundus
nervus petrosus superficialis major
art. canalis pterygoidei
nervus canalis pterygoidei
ganglion sphenopalatinum
art. sphenopalatina +
aa. nasales post. lateral.
chorda tympani
cartilago tubae auditivae
art. maxillaris interna
ganglion cervicale superius trunci sympathici
nervus alveolaris inferior
arteria carotis externa
a. palatina ascendens ×
n. palatin. post. + a. palat. minor
uvula
musc. pterygoideus internus
nervus lingualis ×
nervus mylohyoideus
ramus mylohyoideus arteriae alveolaris infer.
n. palatinus anterior
art. palatina major
r. nasalis anter. nervi ethmoid. anterioris
a. nasal. anter. lateralis
concha nasalis superior
concha nasalis media
art. palatina descendens
concha nasalis inferior
nervi palatini
nervus nasopalatinus
a. nasalis post. septi × (a. nasopalatina)
mandibula ×
Genioglossus ×
Geniohyoideus ×
Mylohyoideus ×
Digastricus

Fig. 66.

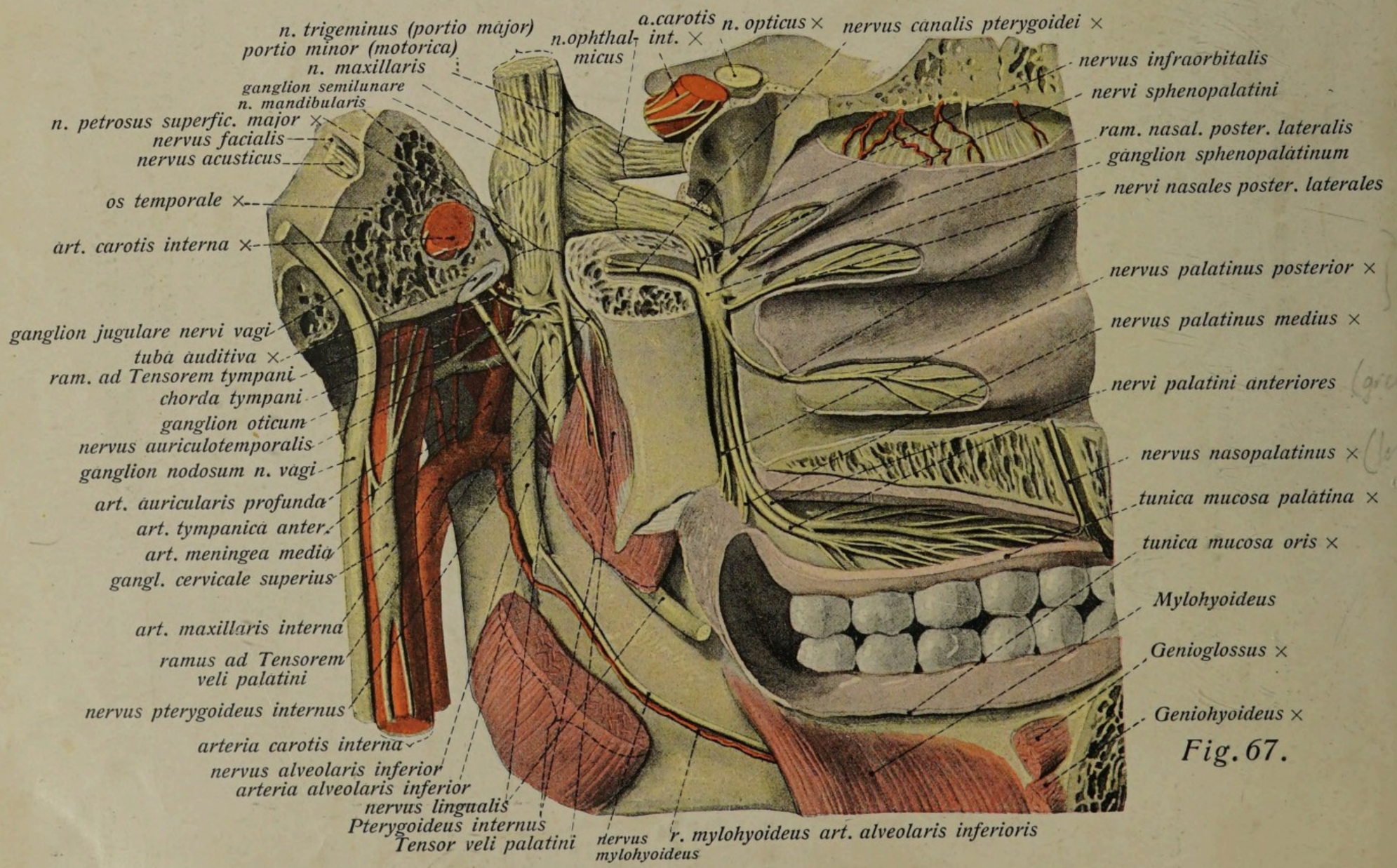
n. trigeminus (portio major)
portio minor (motorica)
n. maxillaris
ganglion semilunare
n. mandibularis
n. petrosus superfic. major ×
nervus facialis
nervus acusticus
os temporale ×
art. carotis interna ×
ganglion jugulare nervi vagi
tuba auditiva ×
ram. ad Tensorem tympani
chorda tympani
ganglion oticum
nervus auriculotemporalis
ganglion nodosum n. vagi
art. auricularis profunda
art. tympanica anter.
art. meningea media
gangl. cervicale superius
art. maxillaris interna
ramus ad Tensorem veli palatini
nervus pterygoideus internus
arteria carotis interna
nervus alveolaris inferior
arteria alveolaris inferior
nervus lingualis
Pterygoideus internus
Tensor veli palatini
a.carotis int. ×
n.ophthalmicus
n. opticus ×
nervus canalis pterygoidei ×
nervus infraorbitalis
nervi sphenopalatini
ram. nasal. poster. lateralis
ganglion sphenopalatinum
nervi nasales poster. laterales
nervus palatinus posterior ×
nervus palatinus medius ×
nervi palatini anteriores
nervus nasopalatinus ×
tunica mucosa palatina ×
tunica mucosa oris ×
Mylohyoideus
Genioglossus ×
Geniohyoideus ×
nervus mylohyoideus
r. mylohyoideus art. alveolaris inferioris

Fig. 67.

The Nerves and Blood Vessels of the Head. (Cont.)

Fig. 66. The nerves and vessels of the nose, deeper layer, and the spheno-palatine ganglion. (1/1) The preparation as in Fig. 65. In addition the pterygo-palatine and pterygoid canals are opened and the pyramid of the temporal bone is divided obliquely. The tongue is removed.

Fig. 67. The otic and spheno-palatine ganglia. (1/1) The preparation as in Fig. 66, but the body of the sphenoid is almost completely removed, the foramen ovale and the palatine foramina opened, the temporal bone sawed away as far as the jugular foramen, the Pterygoideus internus cut and the soft palate removed. + (in white on the middle meningeal art.) = the lesser superficial petrosal nerve (cut).

Branches of the Internal Maxillary Artery. (Cont. from p. 72.)

m) The *descending palatine artery* gives off the small *artery of the pterygoid canal (Vidian)*, which passes to the tuba auditiva and its surroundings and descends in the pterygo-palatine canal. It divides into the *greater palatine artery* to the hard palate and the *lesser palatines* to the soft palate. Fig. 66.

n) The *spheno-palatine* gives off the *lateral* and *medial posterior nasal arteries* to the walls and septum of the nose. The posterior artery of the septum (naso-palatine) reaches the incisive canal. Fig. 64—67.

The Mandibular (III) Division of the Trigeminal Nerve

contains the motor portio minor and is consequently a mixed nerve. It passes through the foramen ovale and immediately branches. Fig. 58—63. Its branches are:

1. The *spinous branch*, a fine twig to the dura mater passing through the foramen spinosum. Fig. 69, 135.

2. The *masticatory nerve*, a short stem that carries in the first place the nerves for the muscles of mastication and accordingly contains the portio minor. It quickly divides into the following branches, which may be more or less connected with one another. a) The *masseteric* passing through the mandibular notch to the Masseter Fig. 55, 58. b) the *anterior* and *posterior deep temporal*, accompanying the corresponding arteries to the Temporalis. Fig. 58, 59. c) The *external* and *internal pterygoid*, often several, to the pterygoid muscles. Fig. 59. d) The *bucinator (buccal)*, a large nerve that accompanies the bucinator artery between the Temporalis and Pterygoideus externus to the Bucinator and, piercing this, supplies the mucous membrane and in part the skin of the cheek. Fig. 53—56, 58, 59.

3. The *auriculo-temporal nerve* usually arises by two roots, between which the middle meningeal artery passes. It runs backward behind the temporal-mandibular joint and the condylar process of the mandible and curves upwards, gradually becoming more and more superficial, in front of the external auditory meatus and the concha, often quite surrounded by the parotid gland. It gives off branches to the external auditory meatus, *parotid branches* to the gland, *anterior auricular branches* to the concha and ends in *superficial temporal branches* to the skin of the temporal region. Fig. 51—56, 58, 59.

4. The *lingual nerve*, one of the two terminal branches, receives at an acute angle the *chorda tympani* from the facial (see p. 80) and lies at first between the two pterygoid muscles; it then passes lateral to the Styloglossus and Hyoglossus and above the submaxillary gland to the tongue. It is distributed to the mucous membrane to the tongue by *lingual branches*, which connect with the hypoglossal nerve; to the sublingual glands and mucous membrane of the mouth by *sublingual branches*; and sends a branch from the chorda tympani and *communicating branches* to the *submaxillary ganglion*, which is situated above the submaxillary gland. It also receives sympathetic fibres from the external maxillary plexus. Fig. 15, 56, 57, 62, 66—68, 75, 114.

5. The *inferior alveolar nerve*, Fig. 55, 56, 58, 59, 68, the other terminal branch, lies at first beside the preceding between the two pterygoid muscles. It gives off the slender *mylohyoid nerve* to the Mylohyoideus and anterior belly of the Digastricus. (Fig. 9, 10, 11, 58, 59, 66—68.) It passes then with the inferior alveolar artery into the mandibular canal, forming the *inferior dental plexus*, and leaves the canal as the *mental nerve*, which sends branches to the chin and *inferior labial branches* to the skin and mucous membrane of the lower lip. Fig. 55, 56, 58, 114.

The Otic Ganglion, Fig. 67, 68, 114

is situated on the medial surface of the mandibular nerve immediately below the foramen ovale. It is a small, flattened, plexiform body, which receives branches from the auriculo-temporal, internal pterygoid and chorda tympani and, in addition, sympathetic fibres from the meningeal plexus and the lesser superficial petrosal nerve from the glosso-pharyngeal (see p. 83). From the ganglion are given off, 1. a *nerve to the tensor veli palatini*, usually united with the internal pterygoid nerve, and 2. a *nerve to the tensor tympani*. Fig. 67.

Fig. 69. The second division of the Trigeminus, the spheno-palatine ganglion, the intracranial portion of the facial nerve and the tympanic nerve. (1/1) The orbit is opened from the lateral side by a sagittal section and its contents removed; the pterygoid canal is opened; the temporal bone is sawn through obliquely; the tympanic cavity and facial canal are opened. * = lateral plate of the pterygoid process. ** = infraorbital nerve with the zygomatic nerve resting upon it. + = the carotico-tympanic nerve. ++ = connection between the facial and tympanic nerves. *+ = connection between the greater and lesser superficial petrosal nerves.

Fig. 70. The zygomatic and lacrimal nerves, with their anastomosis in the orbital cavity. (Somewhat enlarged.) The orbit is opened from the medial side, about half its wall being cut away; its contents, except the lacrimal gland and the nerves in question, have been removed. o = position of the inferior orbital fissure. oo = entrance of the zygomatic nerve into the zygomatic bone.

Fig. 71. Intracranial Section of the n. facialis. (1/1) The canalis facialis is opened, the tympanic cavity with the proc. mastoideus is sawed through from behind.

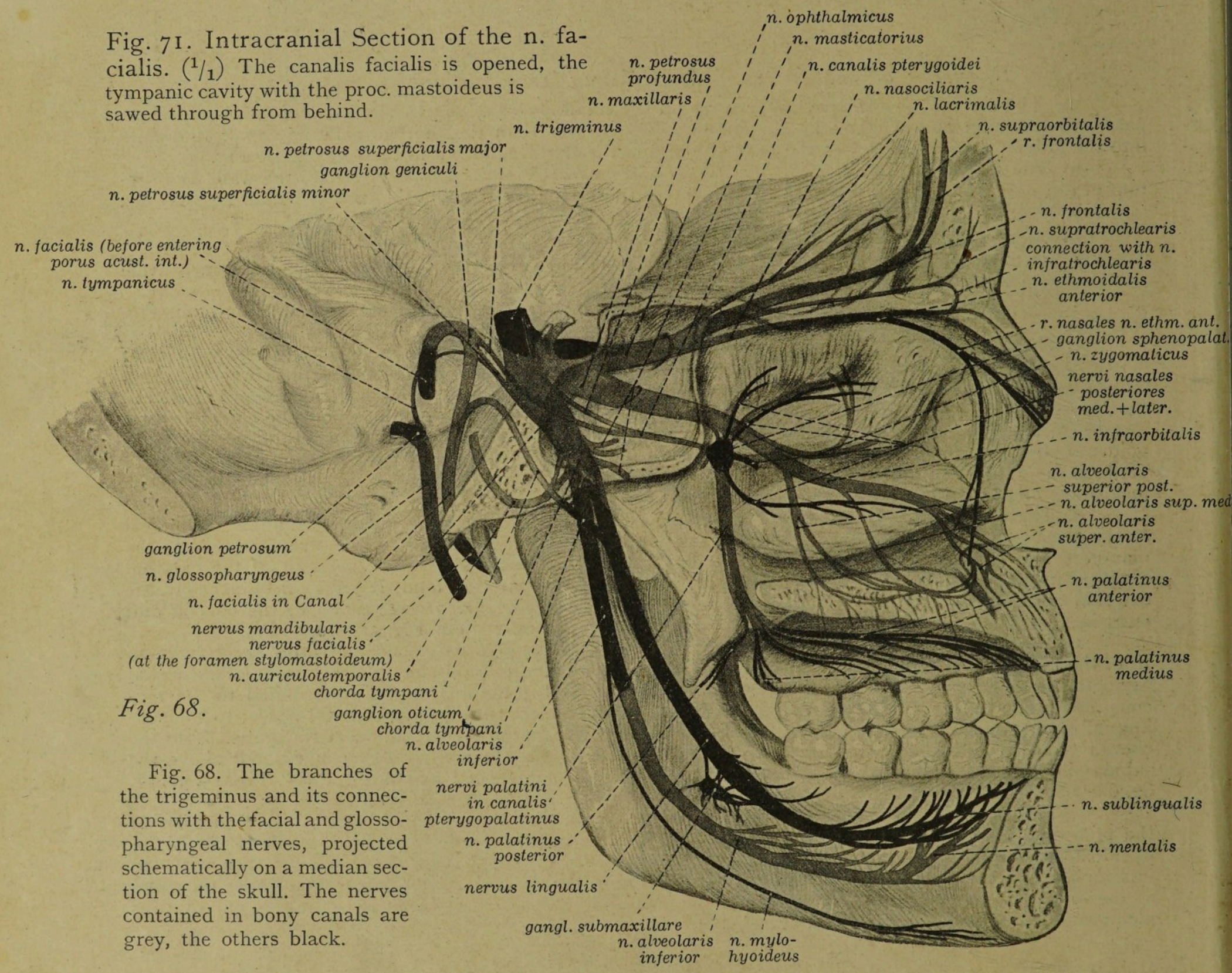

Fig. 68.

Fig. 68. The branches of the trigeminus and its connections with the facial and glossopharyngeal nerves, projected schematically on a median section of the skull. The nerves contained in bony canals are grey, the others black.

The *facial nerve*, intracranial portion, runs in the facial canal of the temporal bone, receives the *n. intermedius* while still in the skull in the vicinity of the internal auditory opening (Fig. 69), forms the *geniculate ganglion* at the knee of the facial canal and gives off from this the *greater superficial petrosal nerve*. This passes through the hiatus of the facial canal, through the foramen lacerum, and through the pterygoid canal, to pass to the spheno-palatine ganglion. Fig. 66, 67, 71 (see p. 76). The facial nerve also gives off branches to the tympanic plexus (see below) and to the Stapedius muscle and just above the stylo-mastoid foramen the *chorda tympani* (actually the n. intermedius) is given off to join the lingual nerve (see p. 79). The chorda passes through the bone to the tympanic cavity, across this between the malleus and incus, and leaves it by the petro-tympanic fissure. Fig. 68, 69, 71, 73, 114 (see also p. 64).

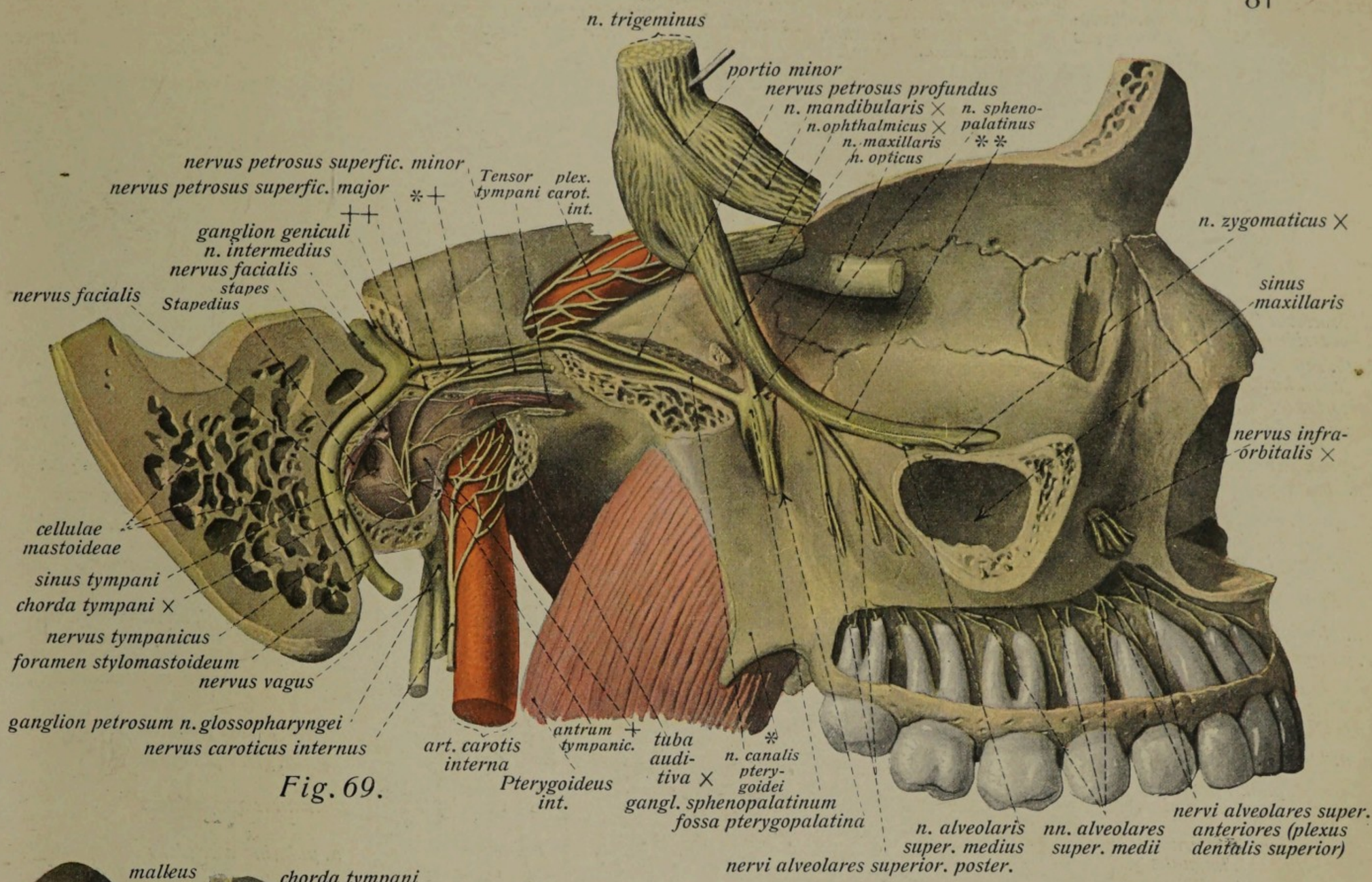

Fig. 69.

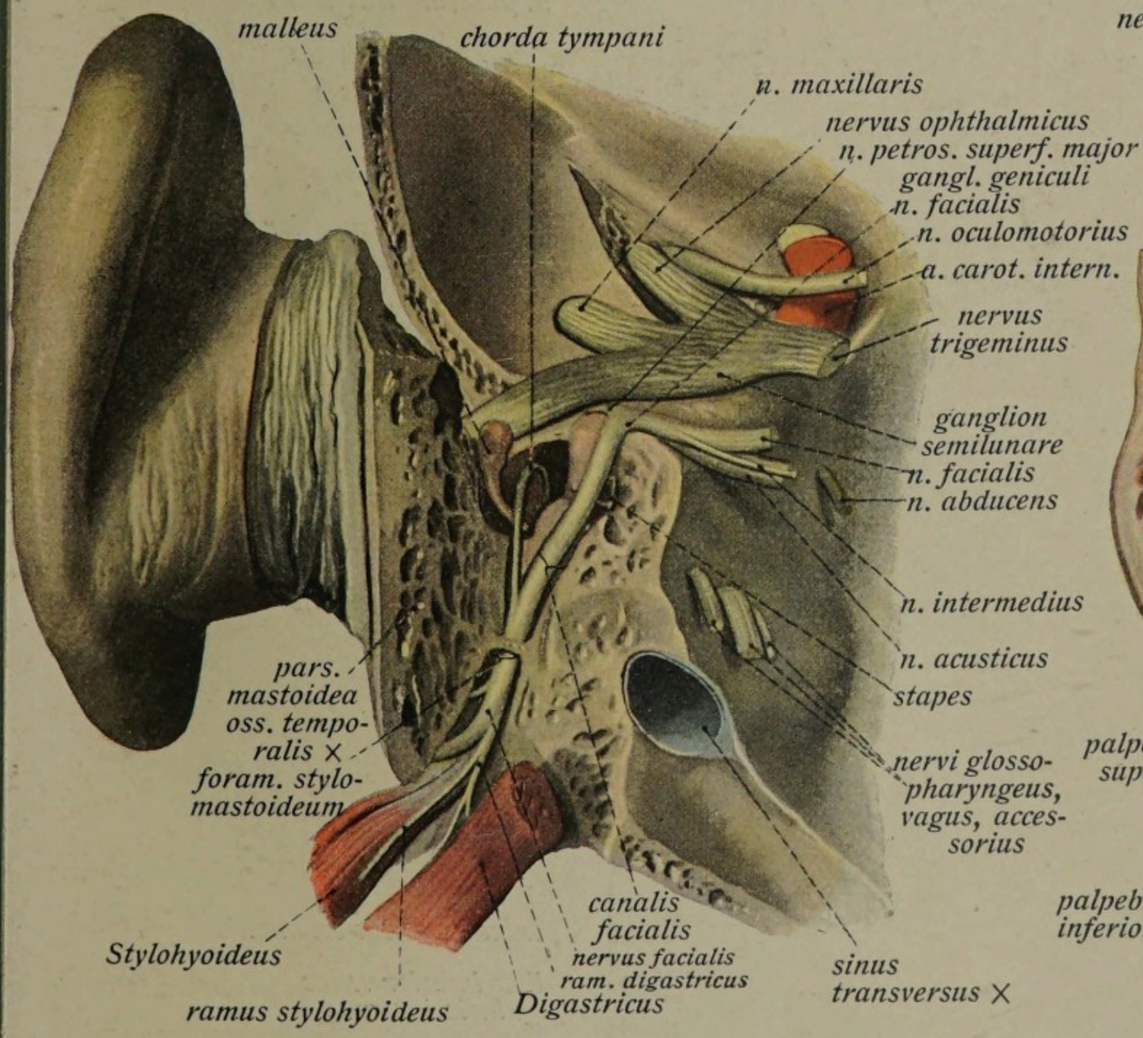

Fig. 71.

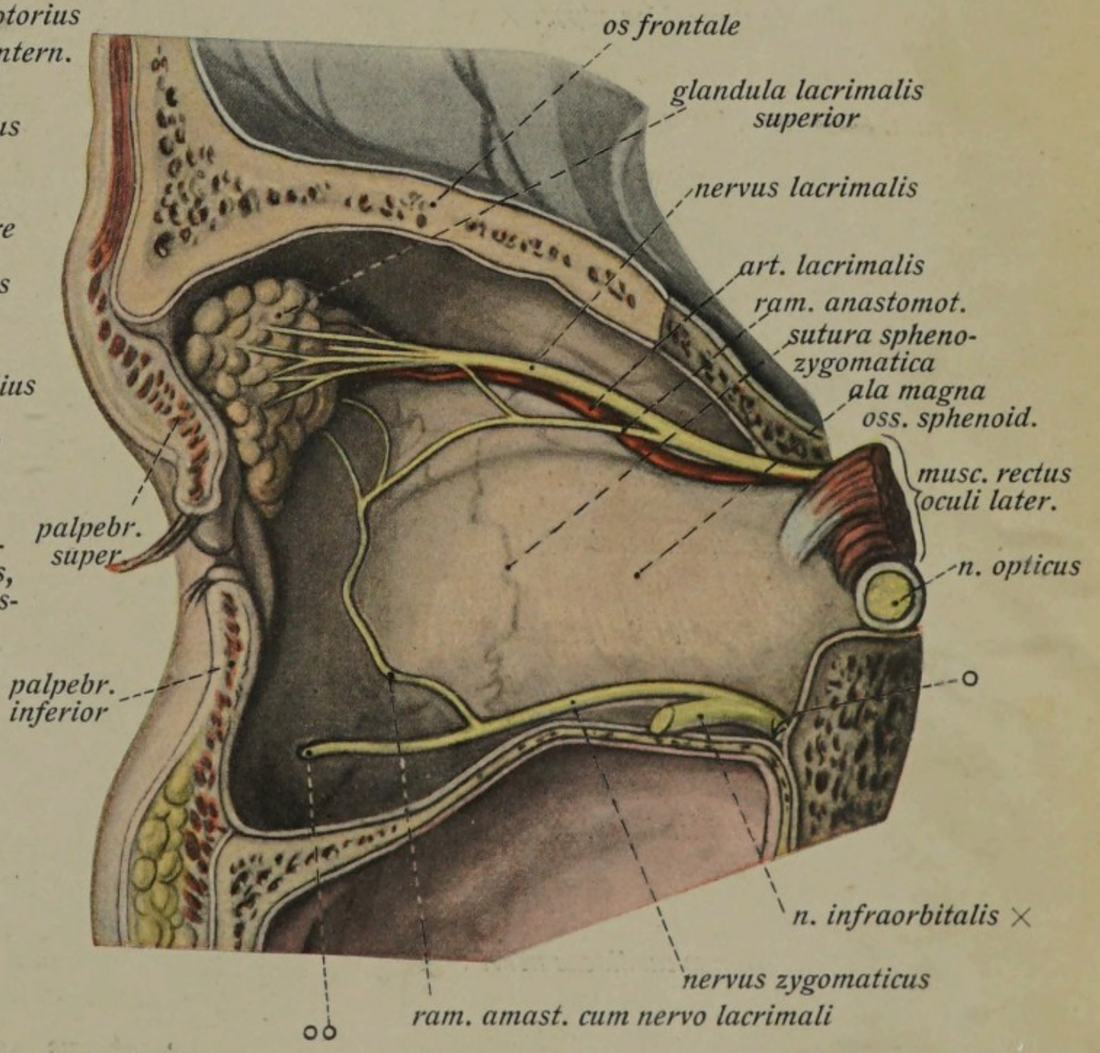

Fig. 70.

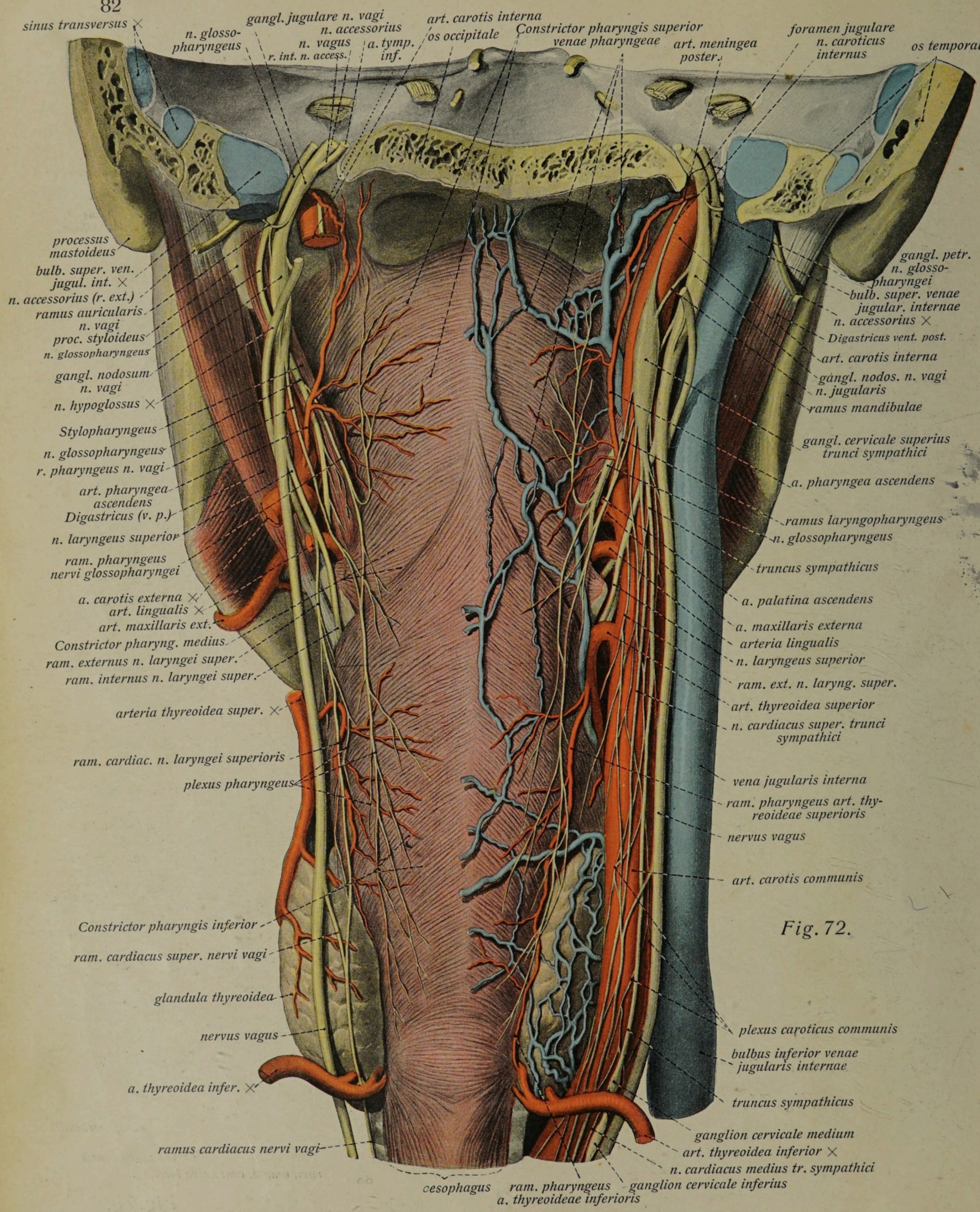
sinus transversus ×
n. glosso-pharyngeus
gangl. jugulare n. vagi
n. accessorius
n. vagus
r. int. n. access.
a. tymp. inf.
art. carotis interna
os occipitale
Constrictor pharyngis superior
venae pharyngeae
art. meningea poster.
foramen jugulare
n. caroticus internus
os temporale ×
processus mastoideus
bulb. super. ven. jugul. int. ×
n. accessorius (r. ext.)
ramus auricularis n. vagi
proc. styloideus
n. glossopharyngeus
gangl. nodosum n. vagi
n. hypoglossus ×
Stylopharyngeus
n. glossopharyngeus
r. pharyngeus n. vagi
art. pharyngea ascendens
Digastricus (v. p.)
n. laryngeus superior
ram. pharyngeus nervi glossopharyngei
a. carotis externa ×
art. lingualis ×
art. maxillaris ext.
Constrictor pharyng. medius
ram. externus n. laryngei super.
ram. internus n. laryngei super.
arteria thyreoidea super. ×
ram. cardiac. n. laryngei superioris
plexus pharyngeus
Constrictor pharyngis inferior
ram. cardiacus super. nervi vagi
glandula thyreoidea
nervus vagus
a. thyreoidea infer. ×
ramus cardiacus nervi vagi
cesophagus
ram. pharyngeus
a. thyreoideae inferioris
ganglion cervicale inferius
gangl. petr.
n. glosso-pharyngei
bulb. super. venae jugular. internae
n. accessorius ×
Digastricus vent. post.
art. carotis interna
gangl. nodos. n. vagi
n. jugularis
ramus mandibulae
gangl. cervicale superius trunci sympathici
a. pharyngea ascendens
ramus laryngopharyngeus
n. glossopharyngeus
truncus sympathicus
a. palatina ascendens
a. maxillaris externa
arteria lingualis
n. laryngeus superior
ram. ext. n. laryng. super.
art. thyreoidea superior
n. cardiacus super. trunci sympathici
vena jugularis interna
ram. pharyngeus art. thyreoideae superioris
nervus vagus
art. carotis communis
plexus caroticus communis
bulbus inferior venae jugularis internae
truncus sympathicus
ganglion cervicale medium
art. thyreoidea inferior ×
n. cardiacus medius tr. sympathici

Fig. 72.

The Nerves and Blood Vessels of the Head. (Cont.)

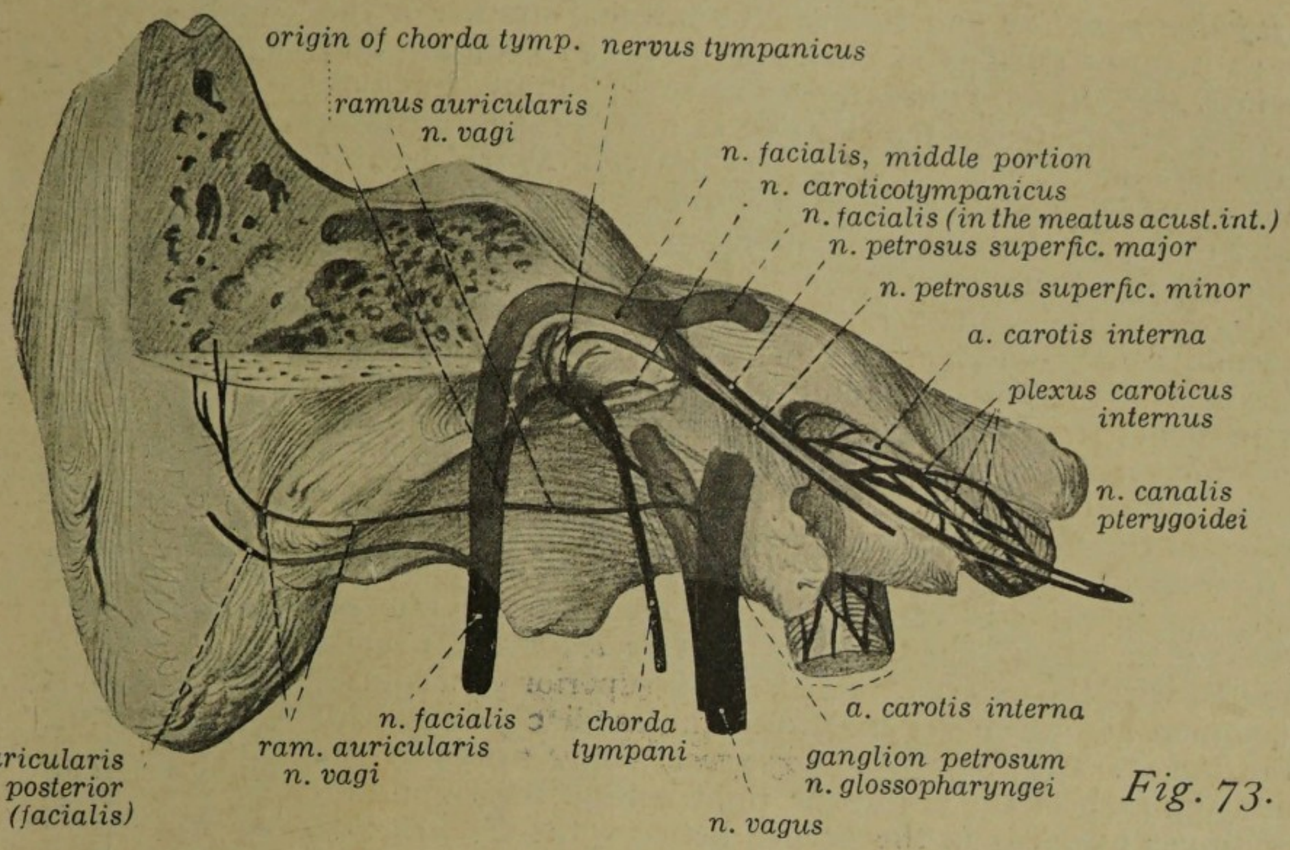

Fig. 73.

Fig. 73. The intracranial course of the facial nerve and its connections, schematically projected on Fig. 70. (Vol. I.)

Fig. 72. The nerves and blood vessels of the posterior and lateral walls of the pharynx. ($^1/_1$)

On the right arc veins and arteries, on the left the nerves and some of the arteries are shown. The posterior part of the skull is removed by a section passing through the jugular foramina. The sympathetic cord is shown only on the right side.

The *ascending pharyngeal artery* arises from posterior wall of the external carotid near its beginning (Fig. 57) and passes upwards on the lateral wall of the pharynx, to which it gives *pharyngeal branches*. It terminates at the base of the skull in the *inferior tympanic* (accompanying the tympanic nerve) and the *posterior meningeal* (passing through the jugular foramen to the dura mater). Fig. 72.

The *glossopharyngeal nerve*, the ninth cranial nerve, is a mixed nerve. It passes through the jugular foramen with the vagus and accessorius, forming the small *superior ganglion*, receives fibres from the superior sympathetic ganglion and forms the *petrosal ganglion*. Then it passes between the two carotid arteries and applies itself to the medial surface of the Stylopharyngeus, with which it runs to the pharynx. Fig. 72, 114. Its branches are: 1. The *tympanic*, which passes from the petrosal ganglion into the tympanic cavity, in the medial wall of which it forms the *tympanic plexus* with branches from the facial and with the *superior* and *inferior carotico-tympanic nerves* from the sympathetic internal carotid plexus. It leaves the tympanic cavity through the superior tympanic canaliculus to pass to the otic ganglion (see p. 79). Fig. 68, 69, 72. 2. *Pharyngeal* branches to the pharyngeal plexus. 3. A *stylo-pharyngeal* branch to the Stylopharyngeus. 4. *Tonsillar* branches to the palatine tonsil. 5. *Lingual* branches, the actual terminal branches, which run along the Stylo-glossus, arching around the palatine tonsil, to supply the root of the tongue (the vallate papillae, lingual follicles) and the epiglottis. Fig. 60, 64, 74.

The *(Spinal) Accessory Nerve* also passes through the jugular foramen and immediately below this divides into the *internal branch*, that joins the vagus (Fig. 72), and the *external branch*. This passes in front of the internal jugular vein to the medial surface of the Sterno-mastoideus, which it penetrates above its middle, giving off *muscular branches*. It leaves the muscle at its lateral border and passes obliquely downwards and laterally through the supraclavicular fossa, uniting with branches of the cervical plexus, to the anterior surface of the Trapezius, which it supplies. Fig. 8—10, 13, 23, 25.

The *Hypoglossal Nerve* leaves the skull through the hypoglossal canal and lies at first medial to and behind the vagus nerve and the internal jugular vein. It then curves forwards and laterally on the lateral side of the internal and external carotids, medial to the Digastricus and Stylo-hyoideus, to reach the submaxillary region. It then crosses the lateral surface of the Hyo-glossus, which separates it from the lingual artery, and passes to the tongue. Fig. 9, 10, 13—15, 75, 114. In addition to connections with the vagus and sympathetic it gives off the fellowing branches. 1. The *descending branch*, which comes from the upper part of the nerve and runs downwards in front of the common carotid artery. It unites with cervical nerves to form the ansa hypoglossi (see p. 8) and supplies the infrahyoid muscles. Fig. 9, 10, 13, 15, 114. 2. A *thyreo-hyoid branch* to the Thyreo-hyoideus. Fig. 9, 114. 3. *Lingual branches* to all the muscles of the tongue except the Glosso-palatinus and to the Genio-hyoideus. Fig. 15, 64, 75.

The Nerves and Blood Vessels of the Neck.

The Vagus Nerve (see also Fig. 114 and 117, and p. 140)

forms in the jugular foramen a *jugular ganglion* and receives the internal branch of the accessory nerve. Below the foramen it forms the larger, elongated *ganglion nodosum* and then runs downwards with the internal carotid artery (lower down with the common carotid) and the internal jugular vein, lying between the two and at first behind, but later in front of them. It passes into the thorax, the left vagus passing in front of the arch of the aorta and the right over the right subclavian artery; they then run along the two bronchi to the hilus of the lung, and then pass through the diaphragm with the oesophagus to the stomach (and intestine). Fig. 10, 13, 18, 20, 72, 114—117.

The principal branches of the vagus are: 1. The *auricular branch*, from the jugular ganglion, passes through the mastoid canaliculus, connects with the facial in the facial canal and passes to the posterior part of the external auditory meatus and the concha. Fig. 53, 54, 56, 59. 2. *Pharyngeal* branches from the ganglion nodosum to the pharyngeal plexus. Fig. 72, 114. 3. The *superior laryngeal nerve*, from the lower part of the ganglion nodosum, passes downwards behind the carotid arteries and divides. Its smaller *external* branch runs over the lateral surface of the Constrictor pharyngis, supplying this and the Crico-thyreoideus; the stronger internal branch pierces the hyo-thyreoid membrane with the superior laryngeal artery and runs in the wall of the piriform recess to the mucous membrane of the larynx. Fig. 10, 13, 72, 74. 4. The *superior cardiac branches*, usually several, run downwards, partly united with the external branch of the superior pharyngeal, to the posterior surface of the common carotid artery and form the cardiac plexus with branches of the sympathetic. Fig. 72. 5. The *recurrent (laryngeal) nerve* arises in the thorax. The left one passes behind the arch of the aorta, the right behind the right subclavian artery, and each then continues upwards in the groove between the trachea and oesophagus. Each gives off *inferior cardiac* branches to the cardiac plexus and *tracheal* and *oesophageal* branches, and ends at the larynx in the *inferior laryngeal* nerve, which supplies all the laryngeal muscles except the Crico-thyreoideus (see above). Fig. 15, 17, 19, 74, 114. 6. *Anterior* and *posterior bronchial* branches which together with the sympathetic form at the hilus of the lung the *anterior* and *posterior pulmonary plexuses*. Fig. 115—117. 7. *Oesophageal* branches form the anterior and posterior oesophageal plexuses. Fig. 115—117. 8. *Gastric* branches form on the stomach the *anterior* and *posterior gastric plexuses*. Fig. 117.

The Superior Laryngeal Artery

arises from the superior thyreoid (see p. 68) and passes to the larynx between the greater cornu of the hyoid bone and the upper border of the thyreoid cartilage. It gives branches to the Sterno-mastoideus and the neighboring muscles of the tongue, and also the *long crico-thyreoid* branch to the Crico-thyreoid muscle and ligament. The main stem of the artery goes with the superior laryngeal nerve through the hyo-thyreoid membrane to the interior of the larynx. Fig. 9, 10, 13—15, 74.

The Lingual Artery

from the external carotid (see p. 68) runs at first horizontally immediately above the greater cornu of the hyoid bone, separated from the hypoglossal nerve by the Hyo-glossus. It then runs rather steeply upwards, at first between the Hyo-glossus and Genio-glossus and then between the latter and the Longitudinalis inferior as far as the tip of the tongue. Fig. 9, 64, 75.

Its branches are: 1. The *hyoid* branch from near the origin of the artery to the hyoid bone and the adjacent muscles. Fig. 8—10. 2. The *dorsal lingual* branches to the mucous membrane of the dorsum of the tongue. 3. The *sublingual*, one of the terminal branches, continues the more horizontal course of the main artery and passes to the sublingual gland and the sublingual mucous membrane. Fig. 64, 75. 4. The *deep lingual*, the stronger terminal branch, runs a tortuous course between the Genio-hyoideus and the Longitudinalis to the tip of the tongue, giving off branches to its muscles. The two arteries of opposite sides are connected by an arched anastomosis, the *ranine arch*. Fig. 64, 75.

Fig. 74. The nerves and arteries of the larynx and root of the tongue, from behind. (1/1)
The mucous membrane of the anterior wall of the larynx is removed, as is also that of the tongue over the glosso-pharyngeal nerve.

Fig. 75. The nerves and arteries of the tongue and of the larynx from in front and below. (1/1)
The veins of the tongue are shown on the left; on the right the Hyo-glossus is cut.



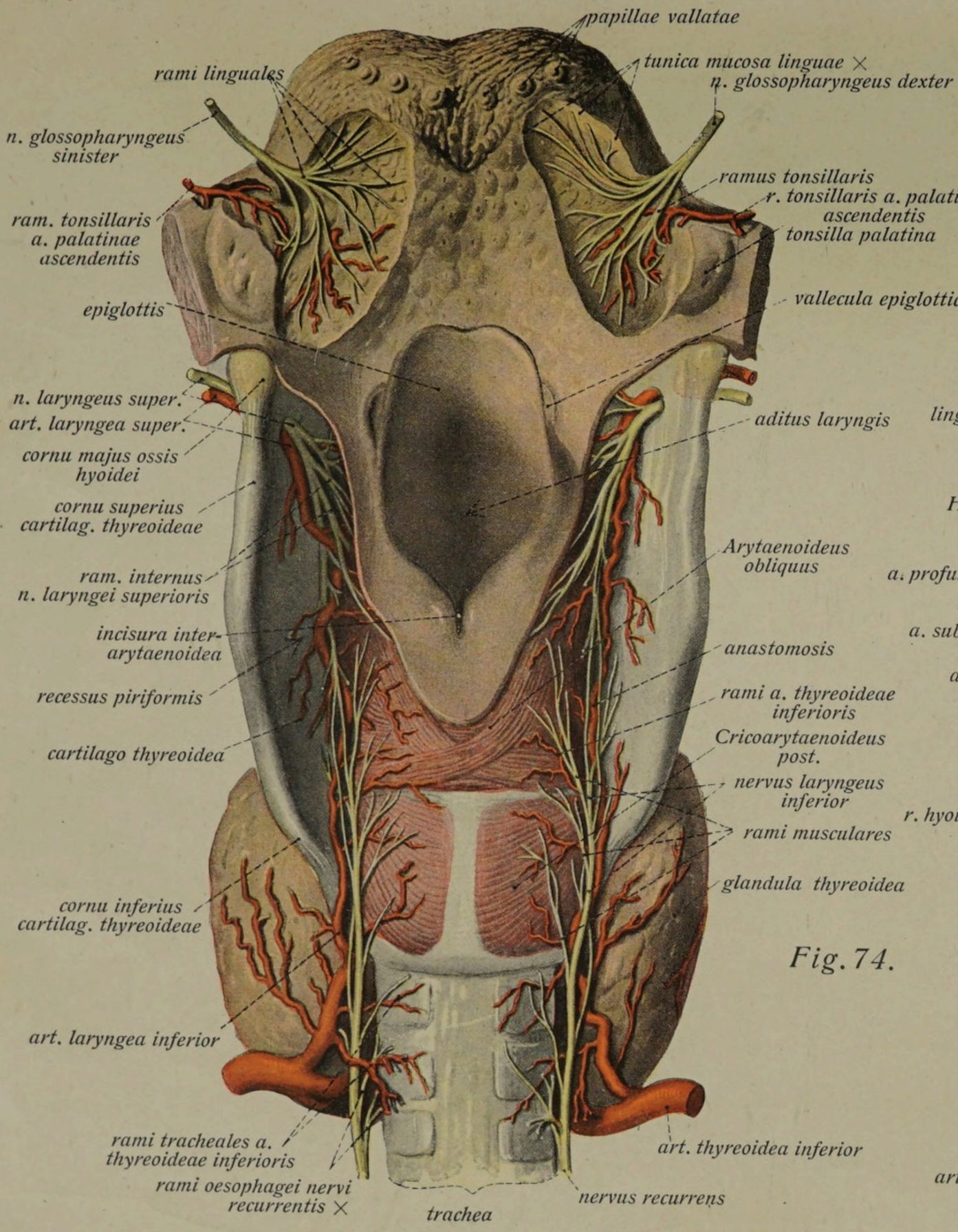
papillae vallatae
tunica mucosa linguae ×
n. glossopharyngeus dexter
rami linguales
n. glossopharyngeus sinister
ramus tonsillaris
r. tonsillaris a. palatinae ascendentis
tonsilla palatina
ram. tonsillaris a. palatinae ascendentis
vallecula epiglottica
epiglottis
n. laryngeus super.
art. laryngea super.
aditus laryngis
cornu majus ossis hyoidei
cornu superius cartilag. thyreoideae
Arytaenoideus obliquus
ram. internus n. laryngei superioris
incisura inter-arytaenoidea
anastomosis
recessus piriformis
rami a. thyreoideae inferioris
Cricoarytaenoideus post.
cartilago thyreoidea
nervus laryngeus inferior
rami musculares
glandula thyreoidea
cornu inferius cartilag. thyreoideae
art. laryngea inferior
rami tracheales a. thyreoideae inferioris
art. thyreoidea inferior
rami oesophagei nervi recurrentis ×
nervus recurrens
trachea

Fig. 74.

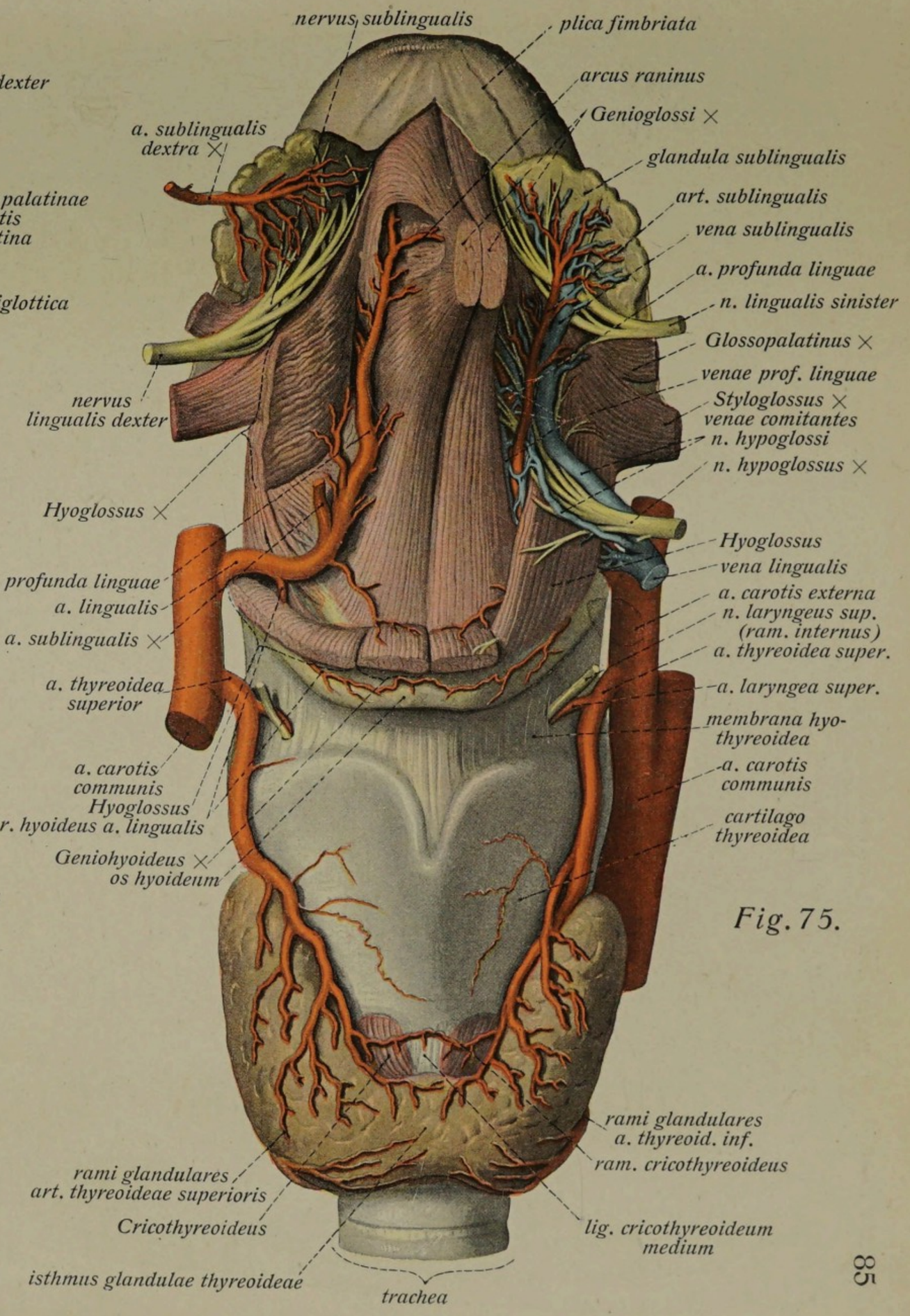
nervus sublingualis
plica fimbriata
arcus raninus
Genioglossi ×
a. sublingualis dextra ×
glandula sublingualis
art. sublingualis
vena sublingualis
a. profunda linguae
n. lingualis sinister
Glossopalatinus ×
venae prof. linguae
nervus lingualis dexter
Styloglossus ×
venae comitantes
n. hypoglossi
n. hypoglossus ×
Hyoglossus ×
Hyoglossus
vena lingualis
a. profunda linguae
a. carotis externa
a. lingualis
n. laryngeus sup. (ram. internus)
a. sublingualis ×
a. thyreoidea super.
a. thyreoidea superior
a. laryngea super.
membrana hyo-thyreoidea
a. carotis communis
a. carotis communis
Hyoglossus
r. hyoideus a. lingualis
cartilago thyreoidea
Geniohyoideus ×
os hyoideum
rami glandulares a. thyreoid. inf.
ram. cricothyreoideus
rami glandulares art. thyreoideae superioris
Cricothyreoideus
lig. cricothyreoideum medium
isthmus glandulae thyreoideae
trachea

Fig. 75.

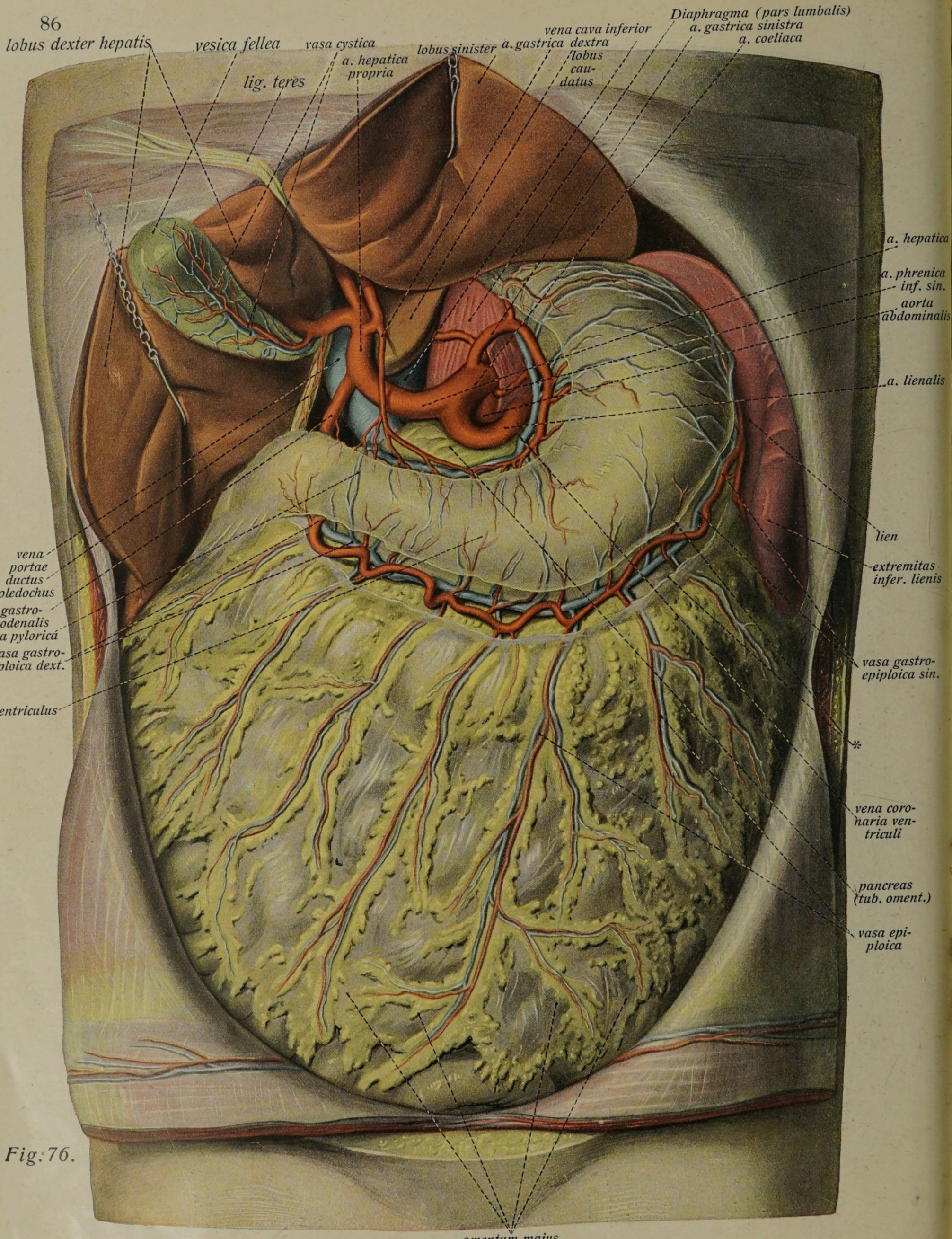
lobus dexter hepatis
vesica fellea
vasa cystica
a. hepatica propria
lig. teres
lobus sinister
a. gastrica dextra
vena cava inferior
Diaphragma (pars lumbalis)
a. gastrica sinistra
a. coeliaca
lobus caudatus
a. hepatica
a. phrenica inf. sin.
aorta abdominalis
a. lienalis
lien
extremitas infer. lienis
vasa gastro-epiploica sin.
*
vena coronaria ventriculi
pancreas (tub. oment.)
vasa epiploica
vena portae
ductus choledochus
a. gastro-duodenalis
vena pylorica
vasa gastro-epiploica dext.
ventriculus
omentum majus

Fig. 76.

The Abdominal Blood Vessels.

Fig. 76. The blood vessels of the stomach and liver. (1/2)

The abdominal cavity is opened, its anterior wall being cut and reflected; the great omentum is left in position; the left and right lobes of the liver are drawn upward, the coeliac artery is exposed at its origin, the anterior layer of the great omentum is divided along the greater curvature of the stomach, the lesser omentum and the peritoneum of the vestibule of the bursa omentalis are removed.

* = cut edges the great omentum.

The Abdominal Aorta

begins at the aortic opening of the diaphragm, as the direct continuation of the thoracic aorta. It lies on the anterior surfaces of the lumbar vertebrae, almost in the median line and to the left of the inferior vena cava. In front of the fourth lumbar vertebra it divides into its terminal branches, the two common iliac arteries. Fig. II 109, 110, III 76, 77, 79, 80, 82, 83. Its branches are visceral and parietal.

I. *The Visceral Branches.*

These are the largest and most important branches of the abdominal aorta and may be divided into the unpaired and the paired branches.

The Unpaired Branches.

1. The **coeliac artery** is the largest branch of the abdominal aorta and arises as a short, thick stem from the anterior wall of the artery (Fig. 76, 77, 80, 82), while it is yet in the region of the aortic opening of the diaphragm. It divides almost at once into three branches.

a) The **left gastric artery,** the weakest of the three branches, runs in the gastro-pancreatic fold of the peritoneum upwards and forwards to the cardia, and gives branches to this and to the abdominal portion of the oesophagus. It then runs along the lesser curvature of the stomach, forming with the right gastric artery a vascular arch from which branches pass to both surfaces of the stomach. Fig. 76, 77.

b) The **hepatic artery** passes in a flat curve upwards and to the right to the porta of the liver. In the hepato-duodenal ligament its terminal branch lies in front of the portal vein and to the left of the ductus choledochus. Fig. II 109, 110, III 76, 77. It has two terminal branches.

α) The *gastro-duodenal artery* is a strong branch that runs downwards behind the pylorus and divides into 1. the *right gastro-epiploic* to the right end of the greater curvature of the stomach, supplying this and the great omentum. Fig. 76, 77, and 2. the *superior pancreatico-duodenal* to the superior and descending portions of the duodenum and to the head of the pancreas. Fig. 77.

β) The *hepatic artery proper*, the actual terminal branch, runs upwards in the hepato-duodenal ligament (see above) and enters the porta of the liver as two relatively weak branches *(ramus dexter* and *r. sinister)*. It gives off 1. the *right gastric* to the right end of the lesser curvature of the stomach (Fig. 75), and 2. the *cystic* to the gall bladder, usually from the right terminal branch. Fig. 75.

The Abdominal Blood Vessels. (Cont.)

Fig. 77. The branches of the coeliac artery and the roots of the portal vein. (1/2)
Preparation as in Fig. 76. The stomach is turned upwards after cutting through the anterior layers of the great omentum, so that its posterior surface looks forward; the pancreas is divided over the superior mesenteric vessels. * = cut edge of the gastro-colic ligament at the greater curvature of the stomach; above is the inferior portion of the duodenum. ** = cut edge of the lesser omentum at the lesser curvature of the stomach.

The Coeliac Artery. (Cont. from p. 87.)

c) the **splenic (lienal) artery** is a strong branch that runs to the hilus of the spleen in a tortuous course along the upper border of the pancreas. Fig. 76, 77. It gives off:

α) *Pancreatic* branches to the body and tail of the pancreas.

β) The *left gastro-epiploic* to the left half of the greater curvature of the stomach, sending branches to the stomach and great omentum and anastomosing with the corresponding right artery. Fig. 76, 77.

γ) The *short gastric arteries* to the fundus of the stomach, arising in part from the following. Fig. 77.

δ) The *splenic (lienal) branches* to the hilus of the spleen. Fig. II 82, 87, III 77.

2. The **superior mesenteric artery,** the second large unpaired branch of the abdominal aorta, arises from the anterior surface of the artery a short distance below the coeliac. It passes behind the head of the pancreas and over the inferior portion of the duodenum into the root of the mesentery, in which it runs in a flat arch, convex to the left and forward, giving off branches and diminishing in caliber. Fig. II 87, 109, 110, III 76—80, 82. Its branches are:

a) The *inferior pancreatico-duodenal* arises behind the pancreas and runs to the inferior portion of the duodenum and the head of the pancreas, anastomosing with the corresponding superior artery (see p. 87). Fig. 76—78.

b) The *intestinal arteries*, about 15 moderately strong branches, arise from the convex side of the arch formed by the artery and pass to the entire length of the mesenterial intestine, forming arched and plexiform anastomoses before entering the intestine. Fig. 78, 79.

c) The *ileo-colic* moderately strong, arises from the concavity of the arterial arch below its middle, runs towards the ileo-caecal angle and divides into an ascending branch that anastomoses with the right colic and a descending branch which anastomoses with the terminal branches of the artery. It gives off the *appendicular artery* to the vermiform appendix. Fig. 78.

d) The *right colic* artery, a strong branch, arises also from the concavity of the main artery, but above the preceding, and passes to the ascending and transverse colons, dividing into ascending and descending branches which anastomose respectively with the middle colic and the ileo-colic. Fig. 78.

e) The *middle colic* artery, a strong branch arising higher up than the preceding from the concavity of the main stem, runs in the transverse mesocolon and anastomoses by a short right branch with the right colic and by a longer left branch with the left colic from the inferior mesenteric artery. Fig. 78, 79.

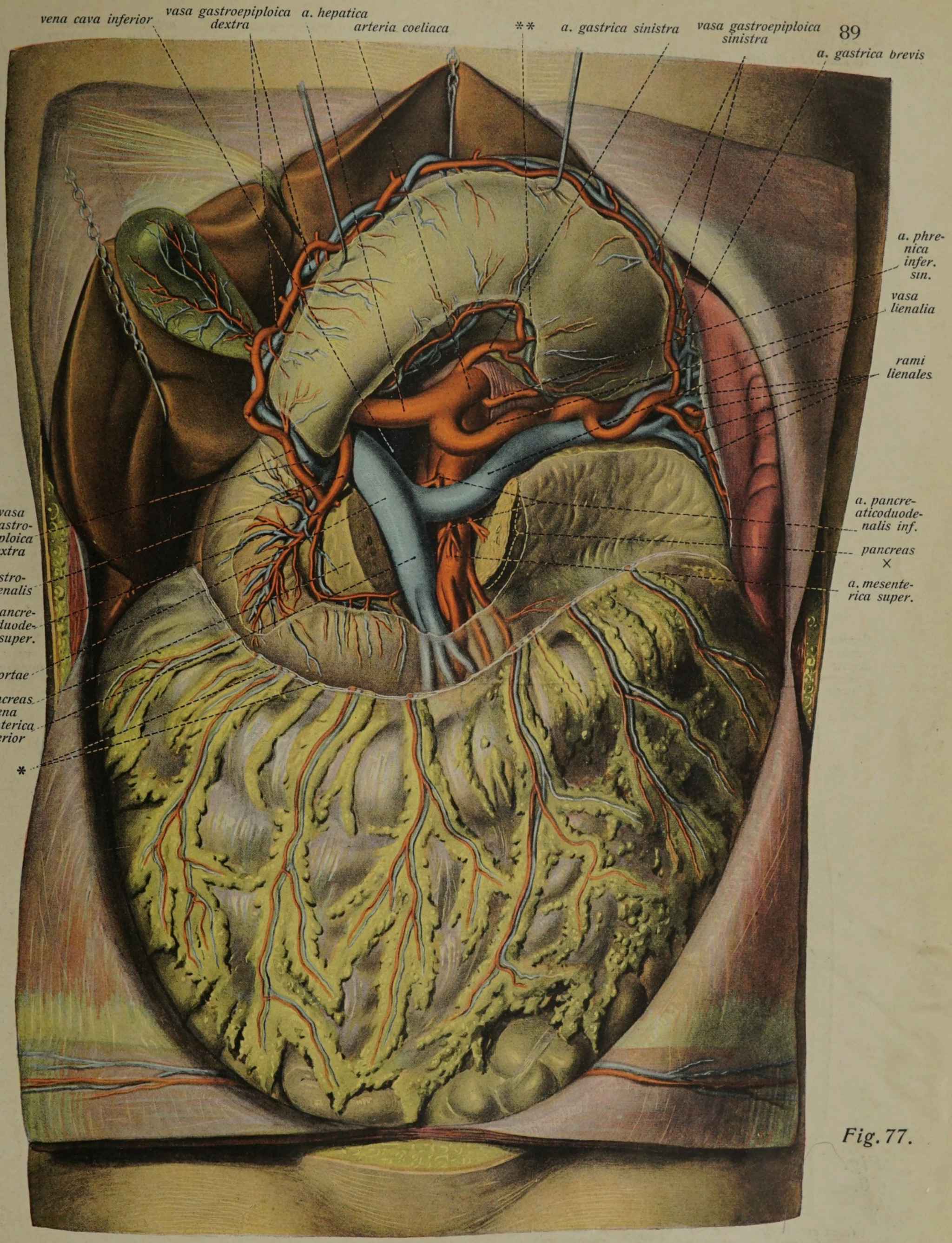
vena cava inferior
vasa gastroepiploica dextra
a. hepatica
arteria coeliaca
**
a. gastrica sinistra
vasa gastroepiploica sinistra
a. gastrica brevis
a. phrenica infer. sin.
vasa lienalia
rami lienales
a. pancreaticoduodenalis inf.
pancreas
×
a. mesenterica super.
vasa gastroepiploica dextra
gastroduodenalis
a. pancreaticoduodenalis super.
a portae
pancreas
vena mesenterica superior
*

Fig. 77.

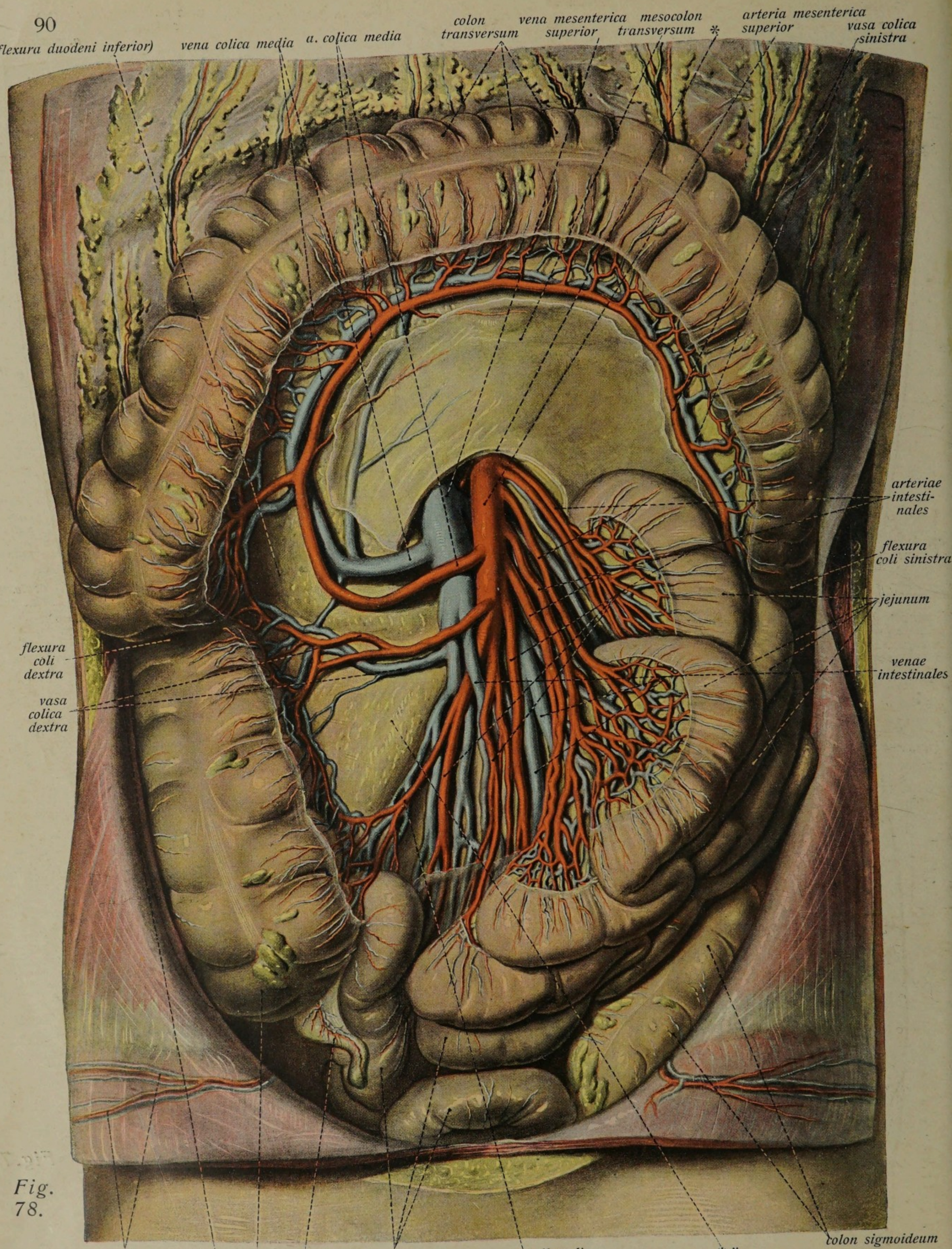
(flexura duodeni inferior)
vena colica media
a. colica media
colon transversum
vena mesenterica superior
mesocolon transversum
*
arteria mesenterica superior
vasa colica sinistra
arteriae intesti-nales
flexura coli sinistra
jejunum
venae intestinales
flexura coli dextra
vasa colica dextra
(vasa epigastrica inferiora)
colon ascendens
caecum
processus vermiformis
ileum
art. ileocolica
**
colon sigmoideum

Fig. 78.

The Abdominal Blood Vessels. (Cont.)

Fig. 78. The superior mesenteric artery and vein. (1/2)

The transverse colon with the great omentum is reflected upwards, the coils of the small intestine are drawn aside, the ascending mesocolon is completely and the transverse mesocolon partly removed; the right layer of the mesentery is removed. * = cut edge of the transverse mesocolon. ** = retro-peritoneal fat in the region of the ascending mesocolon.

The Abdominal Aorta. (Cont. from p. 87, 88.)

3. The *inferior mesenteric artery* arises below the origin of the renal arteries, some distance below the origin of the superior mesenteric. It runs behind the parietal peritoneum of the descending mesocolon downwards and to the left. Fig. II 109, 110, III 79, 80, 82. Its branches are:

a) The *left colic* to the left portion of the transverse colon, anastomosing with the middle colic, and to the descending colon, anastomosing with the following. Fig. 79.

b) The *sigmoid arteries* to the sigmoid colon. Fig. 79.

c) The *superior haemorrhoidal*, the terminal branch, passes from the region of the promontory to the upper and middle portions of the rectum. Fig. 79, 84, 85.

The Paired Visceral Branches of the Abdominal Aorta.

4. The *right* and *left middle suprarenal* arteries arise at about the level of the superior mesenteric and pass to the suprarenal bodies. Fig. 80.

5. The *right* and *left renal* arteries arise below the superior mesenteric and pass to the hilus of the kidneys after giving off *inferior suprarenal* arteries. Fig. 80.

6. The *right* and *left internal spermatic* arteries run as the *testicular* arteries in the male to the testes and as the *ovarian* arteries in the female to the ovaries. They arise from the anterior surface of the aorta just below the renal arteries and run downwards behind the parietal peritoneum, crossing the ureters at an acute angle in front of the Psoas. In the male they pass through the inguinal canals and the spermatic cords; in the female they pass to the pelvis and into the broad ligament (see p. 104) Fig. 80, 82, 83.

The Portal Vein. Fig. II 76, 77, III 3, 76, 77.

The *portal vein* is a short and large venous trunk that is formed by the union of the *superior mesenteric* and *splenic (lienal) veins*, behind the neck of the pancreas. It continues in the region of the pancreatic notch the course of the former, enters the hepato-duodenal ligament at the upper border of the pancreas, lying behind the hepatic artery and the bile duct (Fig. II 81), and divides into two branches which enter the porta of the liver. It is the afferent vessel of the hepatic circulation and carries to the liver the venous blood from all the unpaired organs of the abdomen; i. e. from the digestive tract, including the liver and pancreas, and from the spleen, since the *inferior mesenteric vein* opens into the splenic (lienal) vein or more rarely into the superior mesenteric; within the liver substance the capillaries of the hepatic artery also pass into the roots of the portal vein.

The Abdominal Blood Vessels. (Cont.)

Fig. 79. The inferior mesenteric artery and vein. (1/2)

Preparation as in Fig. 78 except that the coils of intestine are displaced to the right, the branching of the inferior mesenteric vessels is exposed by removing the parietal peritoneum in the region of the descending mesocolon and cutting out portions of the pancreas and the transverse mesocolon. * (on the artery) = abdominal aorta. ** = bifurcation of abdominal aorta. *** = cut edges of the transverse mesocolon. + = the promontory. *+ = inferior pancreatico-duodenal artery (the branches to the pancreas are cut off).

II. The Parietal Branches of the Abdominal Aorta (all paired).

1. The *inferior phrenic* artery arises from the anterior surface of the aorta immediately below the diaphragm. It gives off a *superior suprarenal* branch and ramifies on the under surface of the diaphragm. Fig. 76, 77, 80.

2. The *lumbar* arteries I—IV arise from the posterior surface of the aorta and, continuing the series of the intercostal arteries, run over the bodies of the lumbar vertebrae, the tendinous arches of origin of the Psoas bridging over them. They pass laterally between the bundles of the Quadratus lumborum to the anterior abdominal muscles. The fourth artery runs along the upper border of the ilium and partly on the Iliacus. Posterior branches pass to the skin and muscles of the lumbar region and send *spinal* branches to the spinal cord. Fig. 80.

The continuation of the abdominal aorta, beyond its division into the two terminal common iliac arteries (see p. 96), is the **middle sacral artery.** This arises at the point of bifurcation of the abdominal aorta and continues in its direction, running downwards in the median line over the body of the fifth lumbar vertebra and the pelvic surface of the sacrum. In front of the tip of the coccyx it terminates in a vascular knot, the *glomus coccygeum*. In addition to numerous small branches to the neighboring muscles and bones (transverse branches on the sacrum that anastomose with the lateral sacral arteries) it gives off the paired *lowest lumbar* arteries, which, much weaker than the fourth pair, run over the body of the fifth lumbar vertebra to supply the Psoas and Iliacus, anastomosing with the iliolumbars. Fig. 80, 82, 88.

The Vena Cava Inferior (see p. 103).

The *inferior vena cava* is formed by the confluence of the two *common iliac veins* in front of the fibrocartilage between the 4th and 5th lumbar vertebrae. It runs upwards on the right side of the abdominal aorta and in close relation to it, but before it passes through the diaphragm it comes to lie in the fossa for the vena cava on the under surface of the liver and parts company with the aorta. In addition to its two roots it receives the upper four pairs of *lumbar* veins, the *right internal spermatic*, the two *renal veins* and, shortly before it passes through the diaphragm, the *hepatic* veins. Fig. II 75, 77, 110, III 80, 82, 83.

The *lowest lumbar veins* open into the *middle sacral vein* and this into the left common iliac; this passes over the middle sacral vessels, but behind the right common iliac artery. The *left renal vein* receives the left internal spermatic and crosses in front of the aorta. Fig. 82.

---

vasa colica media

* * * flexura duodenojejunalis

vena mesenterica superior

colon transversum

*+ art. mesenterica superior

vena lienalis

pancreas ×

* * *

vasa colica sinistra

ren sinister

flexura coli sinistra

vena mesenterica inferior

arteria mesenterica inferior

colon descendens

a. colica sinistra

vasa sigmoidea

colon sigmoideum

* *

vasa intestinalia

Fig. 79.

vasa epigastrica inferiora

intestinum mesenteriale

radix mesenterii

+ a. haemorrh. superior

v. haemorrhoidalis superior

rectum

colon sigmoideum

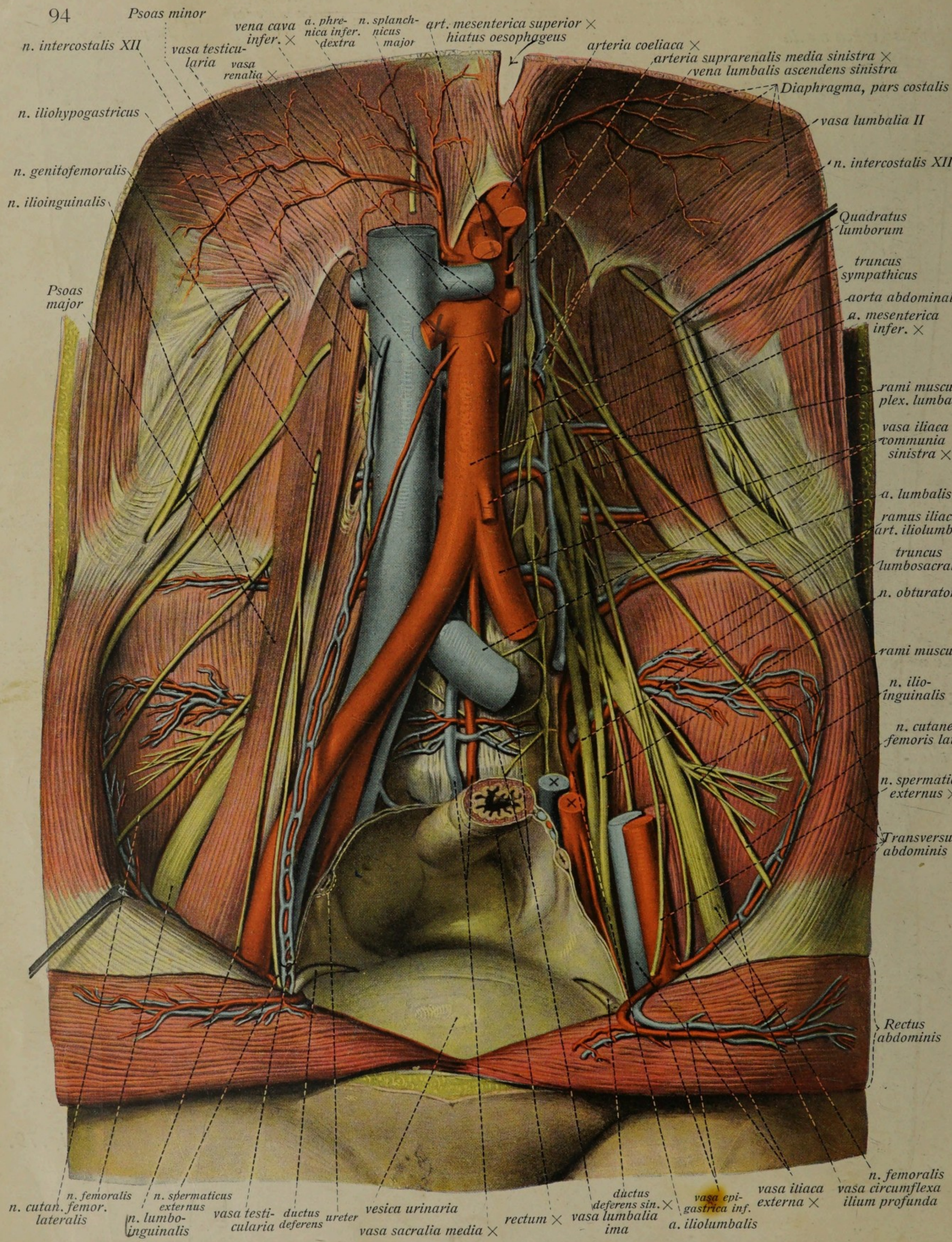
Psoas minor
n. intercostalis XII
vena cava infer. ×
a. phrenica infer. dextra
n. splanchnicus major
art. mesenterica superior ×
hiatus oesophageus
arteria coeliaca ×
arteria suprarenalis media sinistra ×
vena lumbalis ascendens sinistra
vasa testicularia
vasa renalia ×
Diaphragma, pars costalis
n. iliohypogastricus
vasa lumbalia II
n. genitofemoralis
n. intercostalis XII
n. ilioinguinalis
Quadratus lumborum
truncus sympathicus
Psoas major
aorta abdominalis
a. mesenterica infer. ×
rami muscul. plex. lumbalis
vasa iliaca communia sinistra ×
a. lumbalis IV
ramus iliacus art. iliolumbalis
truncus lumbosacralis
n. obturatorius
rami muscular.
n. ilio-inguinalis
n. cutaneus femoris lateral.
n. spermaticus externus ×
Transversus abdominis
Rectus abdominis
n. femoralis
vasa circumflexa ilium profunda
vasa iliaca externa ×
vasa epigastrica inf.
ductus deferens sin. ×
vasa lumbalia ima
a. iliolumbalis
rectum ×
vesica urinaria
vasa sacralia media ×
ureter
ductus deferens
vasa testicularia
n. spermaticus externus
n. femoralis
n. cutan. femor. lateralis
n. lumbo-inguinalis

Fig. 80.

The Abdominal Blood Vessels and Nerves.

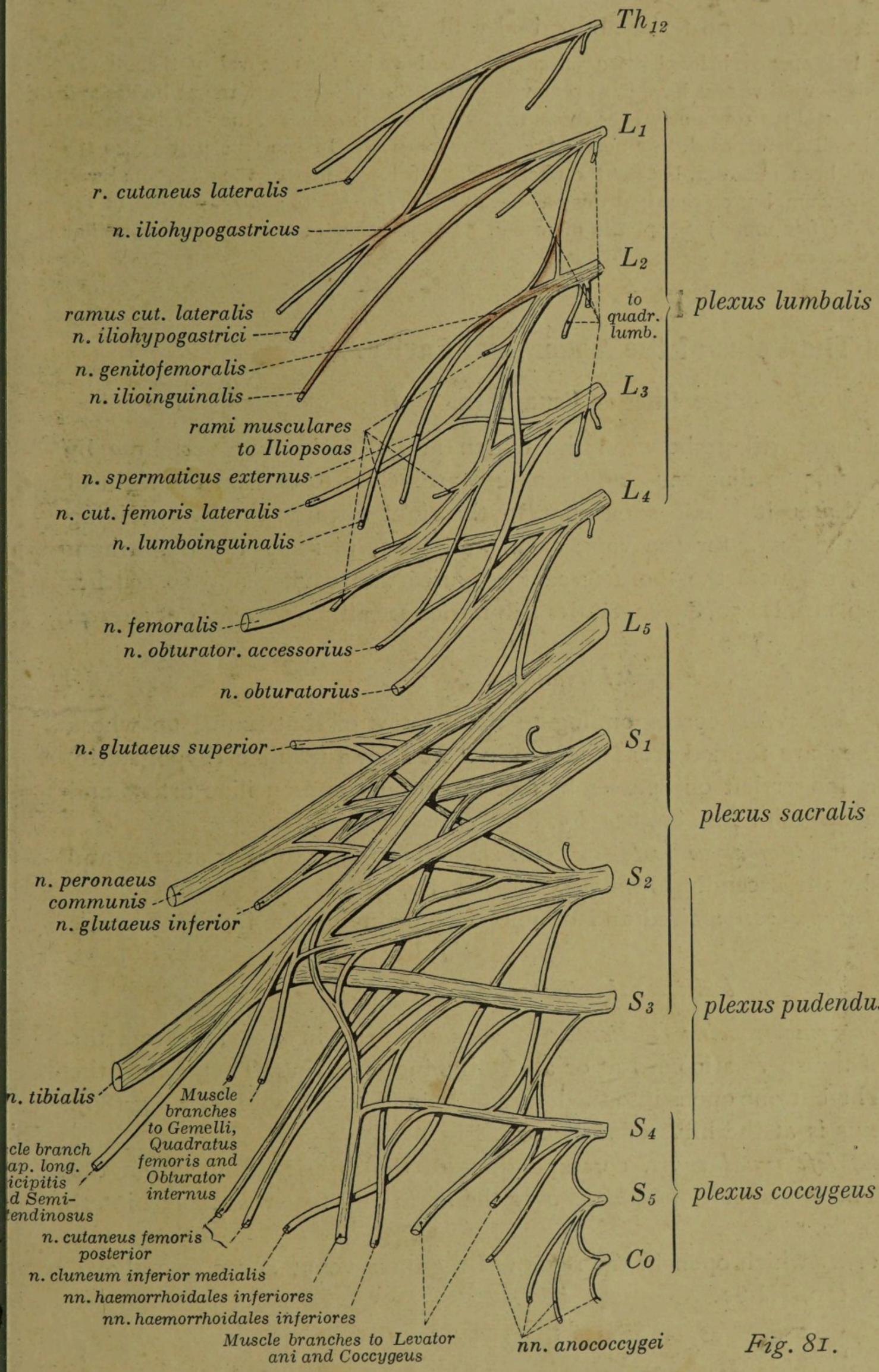

Fig. 81.

Fig. 80. The blood vessels of the posterior abdominal wall and the nerves of the lumbar plexus. (1/2)

All the abdominal viscera are removed and the unpaired branches of the aorta and the renal arteries cut. On the left, portions of the common iliac vessels and their branches have been removed and the Psoas has been dissected away to show the lumbar plexus. On the right only the peritoneum and the fascia transversalis have been removed. The stump of the right renal artery has been drawn out from behind the inferior vena cava.

Fig. 81. Schema of the lumbo-sacral, pudendal and coccygeal plexus (after P. Eisler)

The Lumbar Plexus (Fig. 80, 81—83, 118)

The Blood Vessels of the posterior Abdominal Wall.

Fig. 82. The blood vessels of the posterior abdominal wall. (2/3)

The abdominal cavity is opened, below by two reflected flaps, above by the removal of the anterior and lateral walls. All the abdominal viscera have been removed except the kidneys, suprarenal bodies and ureters. By removing the parietal peritoneum and the fascia transversalis the muscles of the anterior surface of the posterior abdominal wall are exposed. The nerves are not represented. In the true pelvis also the peritoneum and fascia have been removed, but not the viscera. The left lower flap of the abdominal wall still retains its parietal peritoneum, but on the right this has been partly removed to show a portion of the rectus abdominis muscle. * (after ureter) = spindle of ureter, ** = junction of the two common iliac veins to form the inferior vena cava.

The Veins of the Abdominal Cavity.[1])

The Inferior Vena Cava

arises in front of the fibrocartilage between the fourth and fifth lumbar vertebrae by the union of the two common iliac veins and runs upwards close to and on the right of the abdominal aorta. Later it bends somewhat to the right towards the liver, joining its inferior surface in the fossa for the vena cava, and then, piercing the diaphragm (foramen venae cavae), it enters the thoracic cavity (pericardial cavity) and so reaches the heart. Fig. II 76, 109, 110, III 76, 80, 82, 83. Its tributaries are either *parietal* or *visceral*.

a. Parietal tributaries.

1. The *common iliac veins*, corresponding to the arteries of that name, on whose right side they lie. They are formed from the external and internal iliac (hypogastric) veins (see p. 111). The longer left one passes behind the right common iliac artery and receives the middle sacral vein. Fig. 80, 83—85, 88.

2. The *right* and *left lumbar veins I—IV*, corresponding to the lumbar arteries and united on either side by the ascending lumbar vein. Fig. 80, 82.

3. The *inferior phrenic vein* paired and double, accompanying the inferior phrenic artery.

b. Visceral tributaries.

1. The *internal spermatic veins (testicular or ovarian)* arise in the male from the pampiniform plexus of the spermatic cord at or above the inguinal ring. They follow the course of the artery. The left one opens into the left renal vein. Fig. II 109, III 82, 83, (86). In the female the plexus is at the hilus of the ovary. Fig. 85.

2. The *right* and *left renal veins*, corresponding to the arteries, come from the hilus of the kidneys. The longer left one passes over the aorta and receives the left internal spermatic. Fig. 80, 82.

3. The *hepatic veins* which open in the region of the fossa venae cavae (see above, Liver). Fig. II 75, 109, 110, III 82.

---

[1]) For the portal vein see p. 91.

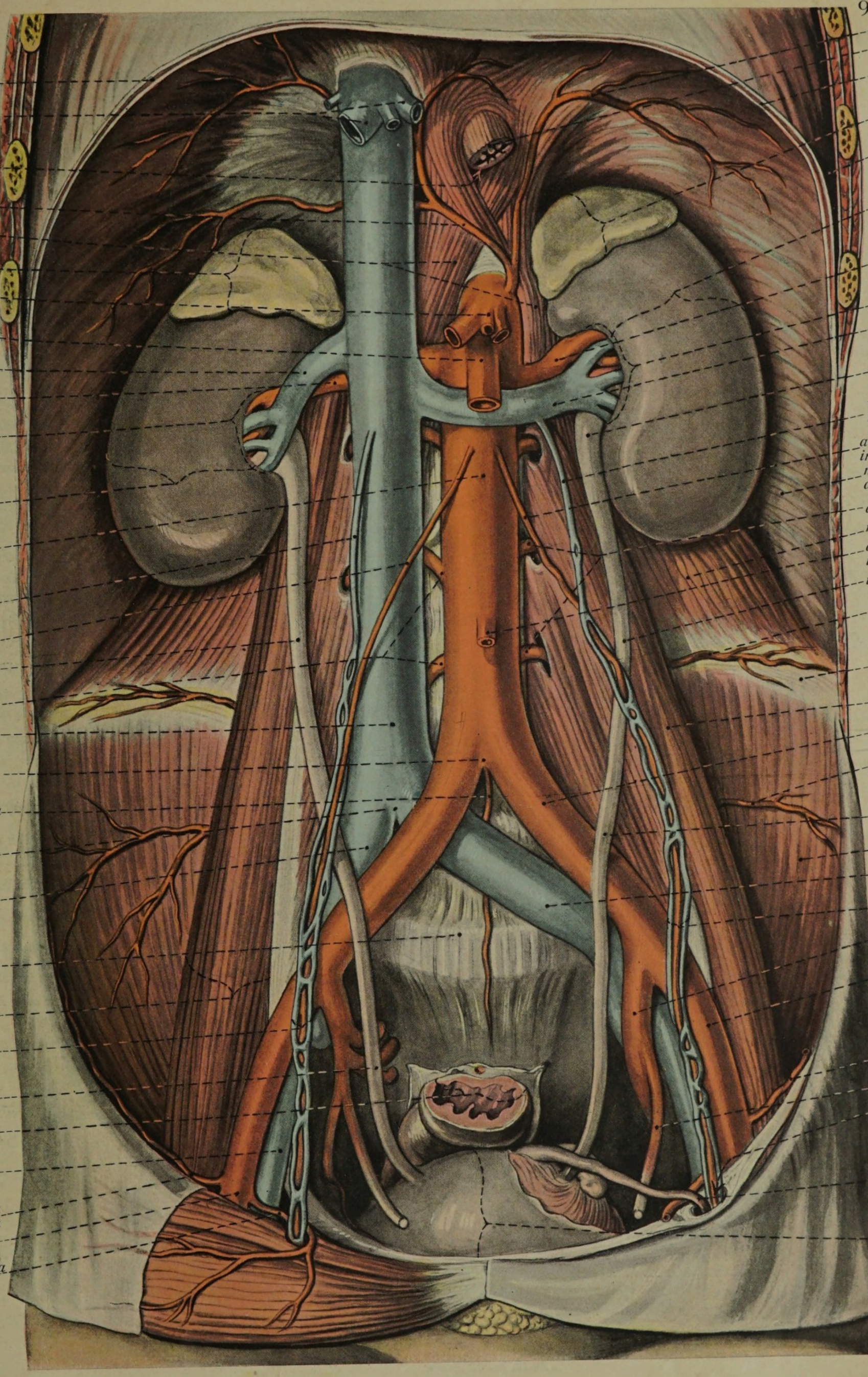

*phragma ×
epaticae ×
oesophageus
aphragmatis
phrenica inf.
rs lumbalis
phragmatis
suprarenalis
dextra
coeliaca ×
nesenterica
superior
vena renalis
dextra
art. renalis
dextra
s renis dextra
ren dexter
rta abdomin.
a spermatica
terna dextra
t. spermatica
terna dextra
ureter dexter
rtt. lumbales
na cava infer.
rcatio aortae
acralis media
* *
vena iliaca
munis dextra
montorium
psoas major
a spermatica
interna
ureter dexter
pars pelvina)
rectum
vena iliaca
ext. dextra
t.circumflexa
ilium dextra
iliaca ext. d.
ia epigastrica
inferior*

*art. phrenica inf.
oesophagus ×
diaphragma ×
glandula supra-
renalis sinistra
sinus phrenico-
costalis
ren sinister
arteria renalis
sinistra
hilus renis sin.
vena renalis sinistra
pelvis renalis
vena spermatica
interna sinistra
arter. spermatica
interna sinistra
m. tranversus
abdominis
arteriae lumbales
m. quadratus lumb.
art. mesenterica
inf. ×
ureter sinister
art. lumbalis IV
crista iliaca
m. psoas major
art. iliaca comm.
ram. iliacus art.
iliolumbalis
ureter *
m. iliacus
vena iliaca comm.
vasa spermatica
interna
art. hypogastrica
art. iliaca ext.
art. circumflexa
ilium profunda
art. umbilicalis
anulus inguinalis
internus
ductus deferens
vesica urinaria*

Fig. 82.

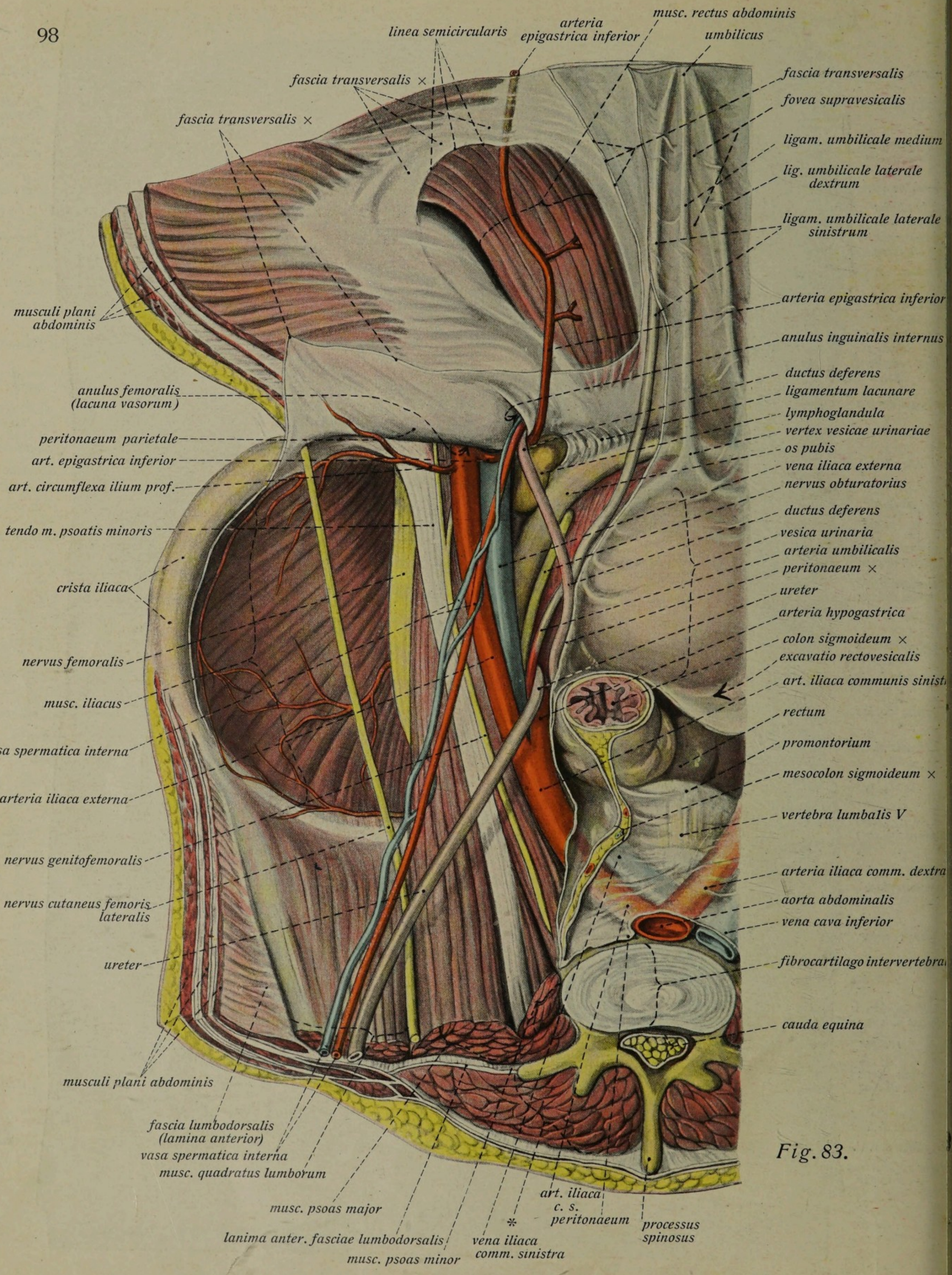
linea semicircularis
arteria epigastrica inferior
musc. rectus abdominis
umbilicus
fascia transversalis ×
fascia transversalis ×
fascia transversalis
fovea supravesicalis
ligam. umbilicale medium
lig. umbilicale laterale dextrum
ligam. umbilicale laterale sinistrum
musculi plani abdominis
arteria epigastrica inferior
anulus inguinalis internus
ductus deferens
ligamentum lacunare
lymphoglandula
vertex vesicae urinariae
os pubis
vena iliaca externa
nervus obturatorius
ductus deferens
vesica urinaria
arteria umbilicalis
peritonaeum ×
ureter
arteria hypogastrica
colon sigmoideum ×
excavatio rectovesicalis
art. iliaca communis sinist
rectum
promontorium
mesocolon sigmoideum ×
vertebra lumbalis V
arteria iliaca comm. dextra
aorta abdominalis
vena cava inferior
fibrocartilago intervertebra
cauda equina
anulus femoralis (lacuna vasorum)
peritonaeum parietale
art. epigastrica inferior
art. circumflexa ilium prof.
tendo m. psoatis minoris
crista iliaca
nervus femoralis
musc. iliacus
vasa spermatica interna
arteria iliaca externa
nervus genitofemoralis
nervus cutaneus femoris lateralis
ureter
musculi plani abdominis
fascia lumbodorsalis (lamina anterior)
vasa spermatica interna
musc. quadratus lumborum
musc. psoas major
lanima anter. fasciae lumbodorsalis
musc. psoas minor
art. iliaca c. s.
peritonaeum
*
vena iliaca comm. sinistra
processus spinosus

Fig. 83.

The Blood Vessels and Nerves of the posterior Abdominal Wall.

Fig. 83. Vessels and nerves of the lower portion of the anterior surface of the posterior and the posterior surface of the anterior abdominal wall. (In part from Schultze-Lubosch.) (2/3)

The antero-lateral abdominal wall is separated from the ilium along the iliac crest. The viscera, except those of the true pelvis, are removed as is also the peritoneum from the false pelvis, except in the regions of the femoral and inguinal rings. The fibrocartilage between the third and fourth lumbar vertebrae has been cut through and, at the same level, the musculature of the posterior abdominal wall. The thin portion of the posterior layer of the sheath of the Rectus that is below the linea semicircularis has been removed.

* = Transverse section of the long dorsal musculature.

The Lumbar Plexus. (Fig. 80, 81—83, 118)

The lumbar plexus is formed by the anastomoses of the anterior branches of the 1—4 lumbar nerves and lies partly behind the Psoas and partly between its bundles. In addition to muscular branches to the Quadratus lumborum and the Psoas it gives origin to the following nerves:

1. The *iliohypogastric nerve*, rather strong, a mixed nerve from L_1, passes through the Psoas and in front of the Quadratus lumborum over the inner surface of the Transversus, piercing this muscle above the iliac crest to continue its course between the Transversus and the Obliquus. In addition to muscular branches to the flat abdominal muscles it gives off a *lateral cutaneous branch* to the skin of the lateral hip region and an *anterior cutaneous branch* to the skin in the region of the inguinal ring. Fig. 80, 91, 93, (101).

2. The *ilio-inguinal nerve*, rather weak and inconstant, is a mixed nerve from the first lumbar. It traverses the Psoas, passes over the Iliacus and, like the preceding, pierces the Transversus. It supplies the abdominal muscles and passes through the inguinal canal to the skin of the mons pubis and of the external genitals as the *anterior scrotal (labial) nerve*. Fig. 80, 86, 91.

3. The *genito-femoral nerve*, rather weak, is formed from the second lumbar. It passes through the Psoas muscle and is continued downwards on its anterior surface to divide at a variable level into its terminal branches. Fig. 80, 83.

a) The *lumbo-inguinal*, sensory, see p. 112.

b) The *external spermatic*, mainly motor. It passes through the inguinal canal and is supplied in the spermatic cord to the Cremaster. Fig. 80, 91.

4. The *lateral femoral cutaneous nerve* is a rather strong, sensory nerve from the second and third lumbar. It traverses the Psoas, passes over the Iliacus to the neighbourhood of the anterior superior spine of the ilium, immediately below which it passes to the skin of the thigh. Fig. 80, 83 (see p. 112).

5. The *femoral nerve* is very strong and mixed, from the second, third and fourth lumbar. It runs in the groove between the Psoas and Iliacus, supplying both muscles, to the inguinal (Poupart's) ligament, beneath which it passes through the lacuna musculorum with the Iliopsoas. Fig. 80, 83 (see p. 119).

6. The *obturator nerve*, moderately strong and mixed, from the second, third and fourth lumbar, is the only nerve of the plexus that appears on the medial border of the Psoas. It runs downward and forward on the lateral wall of the pelvis and passes through the obturator canal with the obturator vessels. Fig. 80, 83, 88 (see p. 119).

The Blood Vessels and Nerves of the Pelvis.

Fig. 84. The blood vessels of the male genitalia, profile view. ($^2/_3$)

The left half of the pelvis has been almost entirely cut away by a sagittal section and the vessels passing to the rectum and genitalia from the left side have been cut. The peritoneum has been removed except where it covers the abdominal wall. × = left ureter cut shortly before its entrance into the bladder. ×× = left ductus deferens.

The Arteries of the posterior abdominal Wall.

(Continued from p. 92)

The Common Iliac Artery

is a strong vessel resulting from the bifurcation of the abdominal aorta. Situated at first in front of the body of the (fourth and) fifth lumbar vertebra, it runs for about 5 or 6 cm along the medial border of the Psoas, being crossed by the ureter, and divides into its two terminal branches without giving off any other branches of even moderate size. Fig. 80, 82, 83, 88.

I. The **external iliac artery** runs on the medial border of the Psoas as the direct continuation of the common iliac to the inguinal (Poupart's) ligament, where it passes directly into the femoral artery (see p. 116). Shortly before entering the lacuna vasorum, beneath the inguinal ligament, it gives off two branches. Fig. 80, 82—85, 88, 95.

1. The *deep circumflex iliac* passes at first behind the inguinal ligament and then backwards along the crest of the ilium, on the upper border of the Iliacus. It supplies the adjacent muscles and anastomoses with the ilio-lumbar from the hypogastric artery and with the fourth lumbar. Fig. 80, 82—85, 95, 96.

2. The *inferior (deep) epigastric* first runs for a short distance medially towards the lacunar ligament, is crossed by the ductus deferens and then runs obliquely upwards between the transversalis fascia and the parietal peritoneum, forming the epigastric fold (see Fig. II 111). It then passes above the symphysis upon the posterior surface of the Rectus abdominis, pierces its sheath and runs upwards between its bundles, branching as it goes, to form manifold anastomoses with the branches of the superior epigastric from the internal mammary (see p. 31). Fig. 80, 82—84. Two branches are given off near its origin.

a) A *pubic* branch, which runs behind the lacunar ligament and branches on the posterior surface of the pubic symphysis. An *obturator* branch anastomoses with the pubic branch of the obturator artery (Fig. 88) and occasionally allows of an abnormal origin for the latter, (the so-called arcus or corona mortis).

b) An *external spermatic* which runs through the inguinal canal to the spermatic cord. Fig. 80, 88.

Fig. 84.

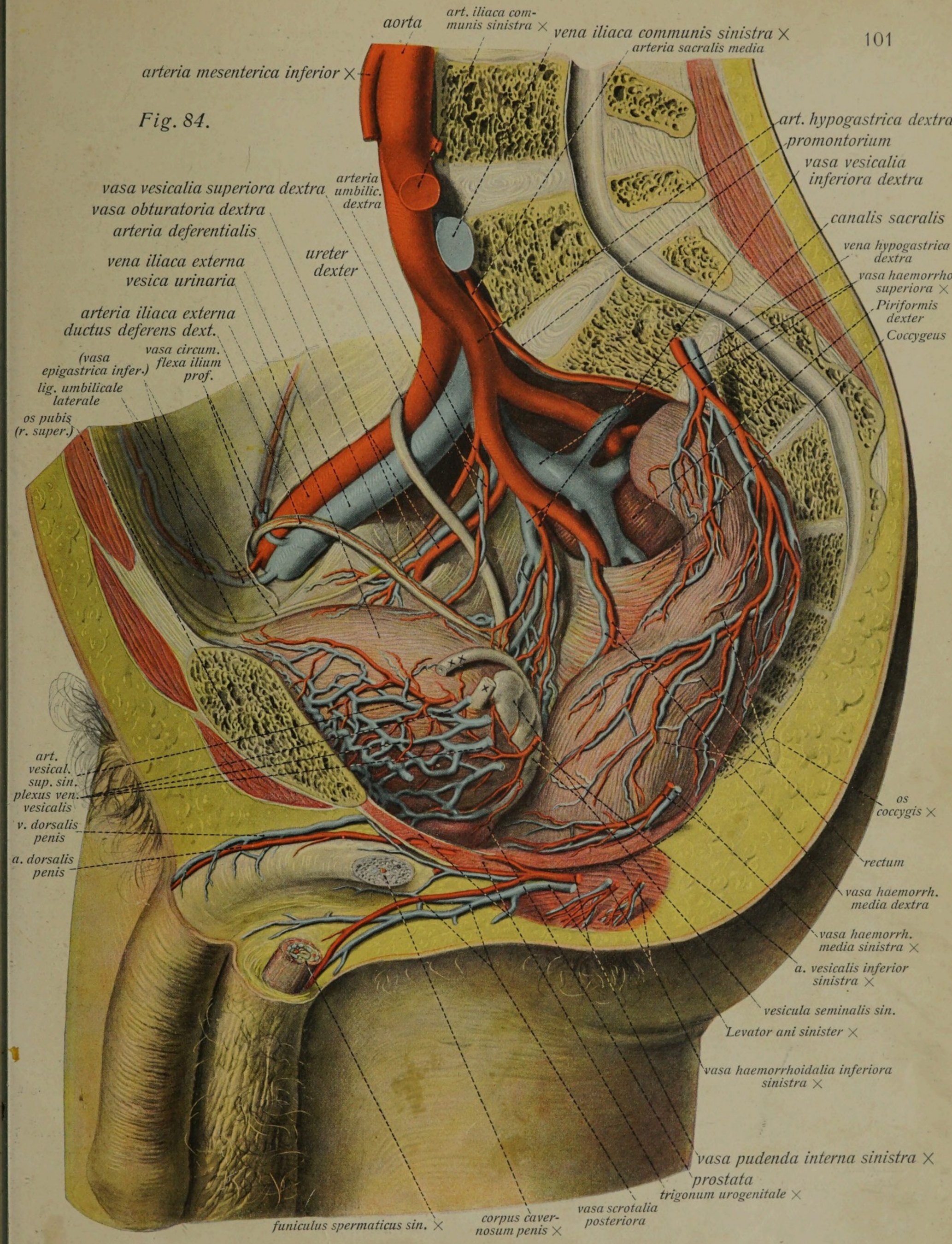
aorta
art. iliaca communis sinistra ×
vena iliaca communis sinistra ×
arteria mesenterica inferior ×
arteria sacralis media
art. hypogastrica dextra
promontorium
vasa vesicalia inferiora dextra
canalis sacralis
vena hypogastrica dextra
vasa haemorrhoid. superiora ×
Piriformis dexter
Coccygeus
vasa vesicalia superiora dextra
vasa obturatoria dextra
arteria deferentialis
vena iliaca externa
vesica urinaria
arteria iliaca externa
ductus deferens dext.
arteria umbilic. dextra
ureter dexter
vasa circum. flexa ilium prof.
(vasa epigastrica infer.)
lig. umbilicale laterale
os pubis (r. super.)
art. vesical. sup. sin.
plexus ven. vesicalis
v. dorsalis penis
a. dorsalis penis
os coccygis ×
rectum
vasa haemorrh. media dextra
vasa haemorrh. media sinistra ×
a. vesicalis inferior sinistra ×
vesicula seminalis sin.
Levator ani sinister ×
vasa haemorrhoidalia inferiora sinistra ×
vasa pudenda interna sinistra ×
prostata
trigonum urogenitale ×
vasa scrotalia posteriora
corpus cavernosum penis ×
funiculus spermaticus sin. ×

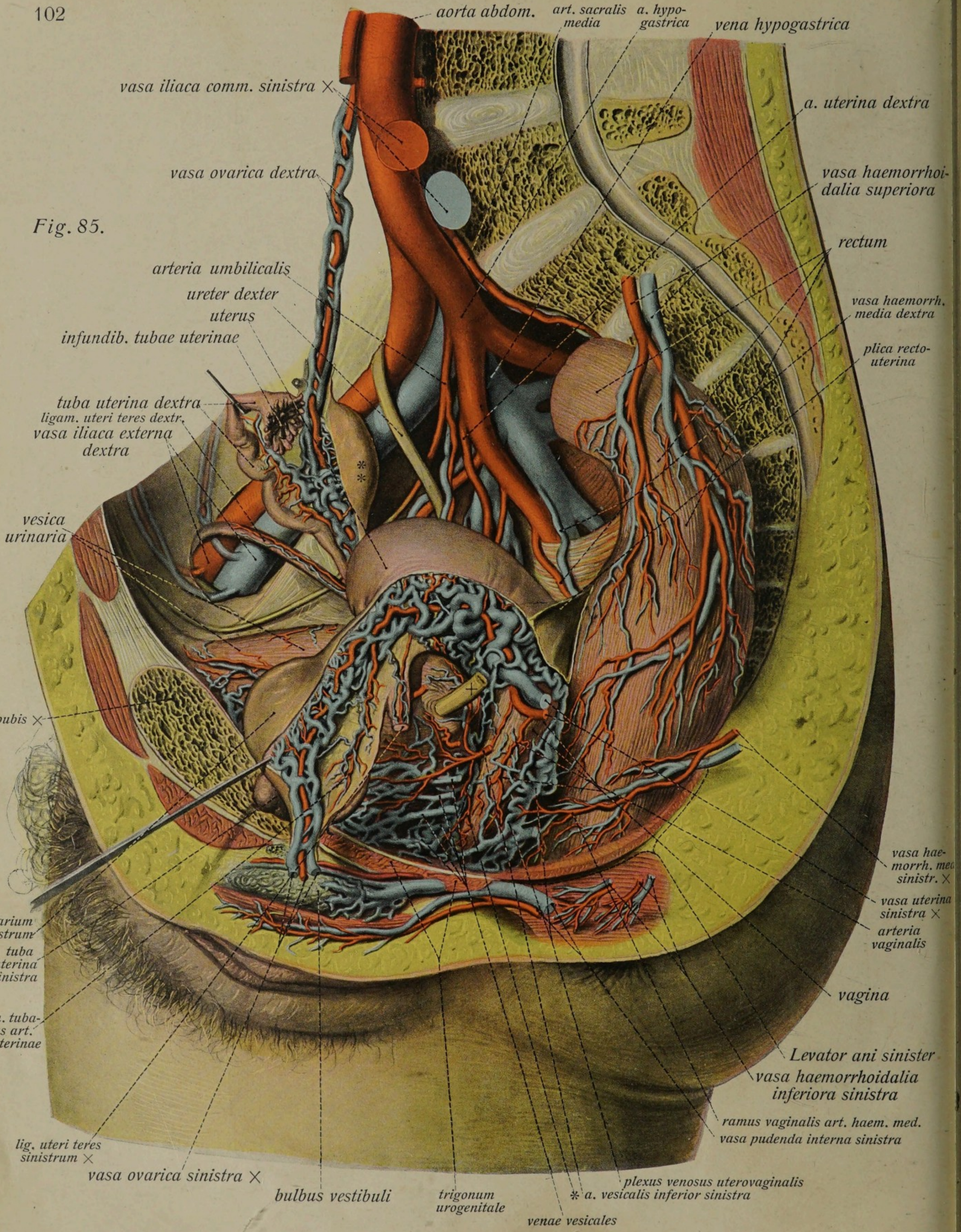
aorta abdom.
art. sacralis media
a. hypogastrica
vena hypogastrica
vasa iliaca comm. sinistra
a. uterina dextra
vasa ovarica dextra
vasa haemorrhoidalia superiora
rectum
arteria umbilicalis
ureter dexter
uterus
infundib. tubae uterinae
vasa haemorrh. media dextra
plica rectouterina
tuba uterina dextra
ligam. uteri teres dextr.
vasa iliaca externa dextra
vesica urinaria
os pubis
vasa haemorrh. media sinistr.
vasa uterina sinistra
arteria vaginalis
ovarium sinistrum
tuba uterina sinistra
vagina
ram. tubarius art. uterinae
Levator ani sinister
vasa haemorrhoidalia inferiora sinistra
ramus vaginalis art. haem. med.
vasa pudenda interna sinistra
lig. uteri teres sinistrum
vasa ovarica sinistra
bulbus vestibuli
trigonum urogenitale
plexus venosus uterovaginalis
a. vesicalis inferior sinistra
venae vesicales

Fig. 85.

The Blood Vessels and Nerves of the Pelvis.

Fig. 85. The blood vessels of the female genitalia from the left side. ($^2/_3$)
Preparation as in figure 84. The left ovary and tuba uterina are drawn downwards and forwards, those of the right side upwards. * = vaginal branches of the inferior vesical artery. ** = right ovary. + = left ureter cut shortly above its entrance into the bladder.

II. The Internal Iliac (Hypogastric) Artery

(Cont. from p. 92, 100)

from its origin from the common iliac bends at once downwards on the lateral wall of the pelvis and begins to branch, forming, as a rule, two large trunks, an anterior and a posterior. Fig. 80, 82, 84, 88. Its branches may be classified as visceral, passing to the pelvic organs, and parietal, passing to the pelvic walls; the former arise almost always from the anterior trunk, the latter usually from the posterior, but occasionally from the anterior.

a) **Visceral branches** (from the anterior trunk):

1. The *umbilical artery* is functional throughout its entire length only until birth. In the fetus (Fig. 2) it is the largest branch of the common iliac and runs along the bladder to the anterior abdominal wall and to the umbilicus, carrying blood to the placenta. After birth the portion between the bladder and the umbilicus becomes converted into the lateral vesical ligament, while the proximal portion as far as the bladder remains pervious and gives off the *superior vesical arteries* to the sides and vertex of the bladder. Fig. 82—84, 88.

2. The *inferior vesical artery*, moderately large, passes forward and medially to the fundus of the bladder; in the male also to the seminal vesicles and prostate and in the female (Fig. 85, 87) to the vagina. Fig. 84, 85, 87.

3a. The *deferential artery* in the male, a small artery, occasionally arising directly from the internal iliac, more usually from the preceding, runs along the ductus deferens to the abdominal inguinal ring and through the inguinal canal, included in the spermatic cord, to the testis. Fig. 84, 88.

3b. The *uterine artery* in the female is large and runs medially on the floor of the pelvis towards the cervix of the uterus. It passes between the two layers of the broad ligament to the lateral surface of the cervix, supplying it, and then passes upwards along the body of the uterus to the fundus. Fig. 85, 87. In addition to branches to the uterus it gives off:

α) The *vaginal artery* to the vagina. Fig. 85, 87.

β) The *ovarian branch* which runs in the broad ligament to the hilus of the ovary and anastomoses with the ovarian artery. Fig. 85, 87.

γ) The *tubar* branch runs in the mesosalpinx along the tuba uterina, supplies this and the lig. teres. Fig. 87.

The Blood Vessels and Nerves of the Genitalia.

Fig. 86. The vessels and nerves of the penis, spermatic cord and scrotum, from in front. (2/3)
From the penis the skin and fascia have been largely removed; the coverings of the right spermatic cord have been divided to show the vessels of the cord.

Fig. 87. The arteries of the female internal genitalia, from behind. (2/3)
The lower part of the broad ligament is removed, the left ovarian ligament is cut and the peritoneum of the mesosalpinx is divided along the vessels.

Internal Iliac (Hypogastric) Artery.

(Continued from p. 103)

4. The *middle haemorrhoidal artery* may also arise from the following. It is rather small and arises just above the floor of the pelvis to pass to the lower part of the rectum, sending branches to adjacent parts (floor of pelvis, seminal vesicles, vagina). It anastomoses with the superior haemorrhoidal from the inferior mesenteric. Fig. 84—86.

5. The *internal pudendal artery*, the terminal branch of the anterior trunk, is strong and gives off both visceral and parietal branches. It leaves the pelvis by the great sciatic foramen below the Piriformis and curves at once around the posterior surface of the sacro-spinous ligament to pass through the lesser sciatic foramen to the lateral wall of the ischio-rectal fossa. It then runs along the inferior ramus of the ischium to divide into its terminal branches at the anterior border of the Sphincter ani externus. Fig. 84—90. Its branches are:

a) The *inferior haemorrhoidal*, usually 2—3 small branches to the skin around the anus, the anal portion of the rectum and the Sphincter ani externus, Fig. 89, 90.

b) The *perineal* artery, moderately strong, runs through the fat of the ischio-rectal fossa downwards, forwards and medially and, passing above the Transversus perinei superficialis, is supplied to the skin and muscles of the perineum. Its terminal branches are the *posterior scrotal* arteries (*labial* in the female), which supply the posterior surface of the scrotum or the labia majora. Fig. 89, 90.

c) The *artery of the penis*, the terminal branch, is the direct prolongation of the main stem along the inferior ramus of the ischium. It pierces the urogenital trigone and runs forward in the groove between the Bulbo-cavernosus and Ischio-cavernosus to below the pubic symphysis, where it divides into two terminal branches. Fig. 89. In the female it is the *artery of the clitoris* and is correspondingly weaker. Fig. 90. Its branches are:

α) The *urethral* to the Bulbo-cavernosus.

β) The *artery of the bulb* to the bulb of the urethral corpus cavernosum. Fig. 89.

γ) The *deep artery of the penis*, the deep terminal branch, passes to the corpus cavernosum of the penis and runs to its anterior extremity.

δ) The *dorsal artery of the penis*, the superficial terminal branch, runs with a corresponding vein (unpaired) below the fascia, along the dorsum penis to the posterior surface of the glans, sending branches to the neighbouring parts (skin, corpora cavernosa). Fig. 84, 86.

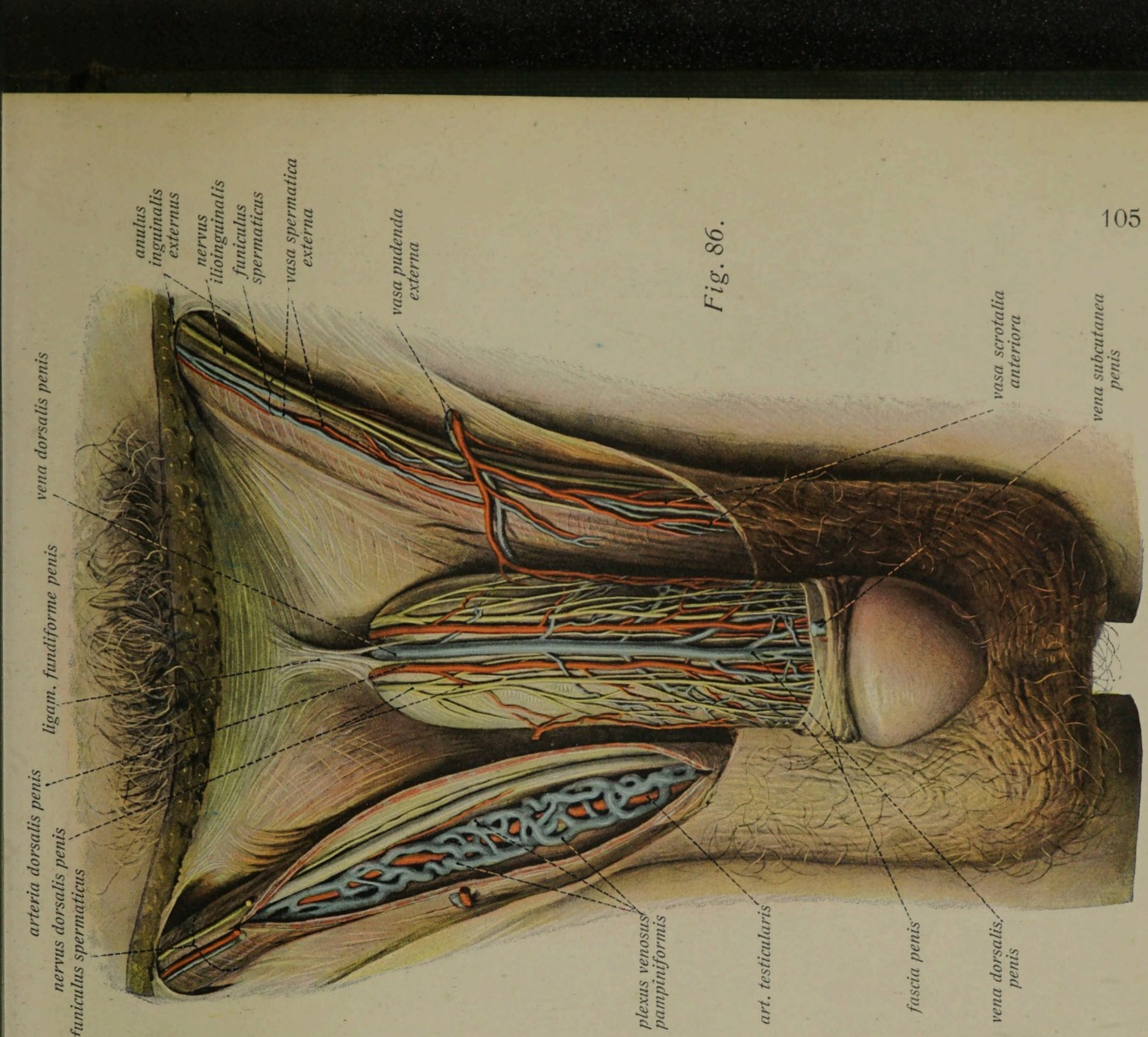
anulus inguinalis externus
nervus ilioinguinalis
funiculus spermaticus
vasa spermatica externa
vasa pudenda externa
vena dorsalis penis
ligam. fundiformе penis
arteria dorsalis penis
nervus dorsalis penis
funiculus spermaticus
vasa scrotalia anteriora
vena subcutanea penis
plexus venosus pampiniformis
art. testicularis
fascia penis
vena dorsalis, penis

Fig. 86.

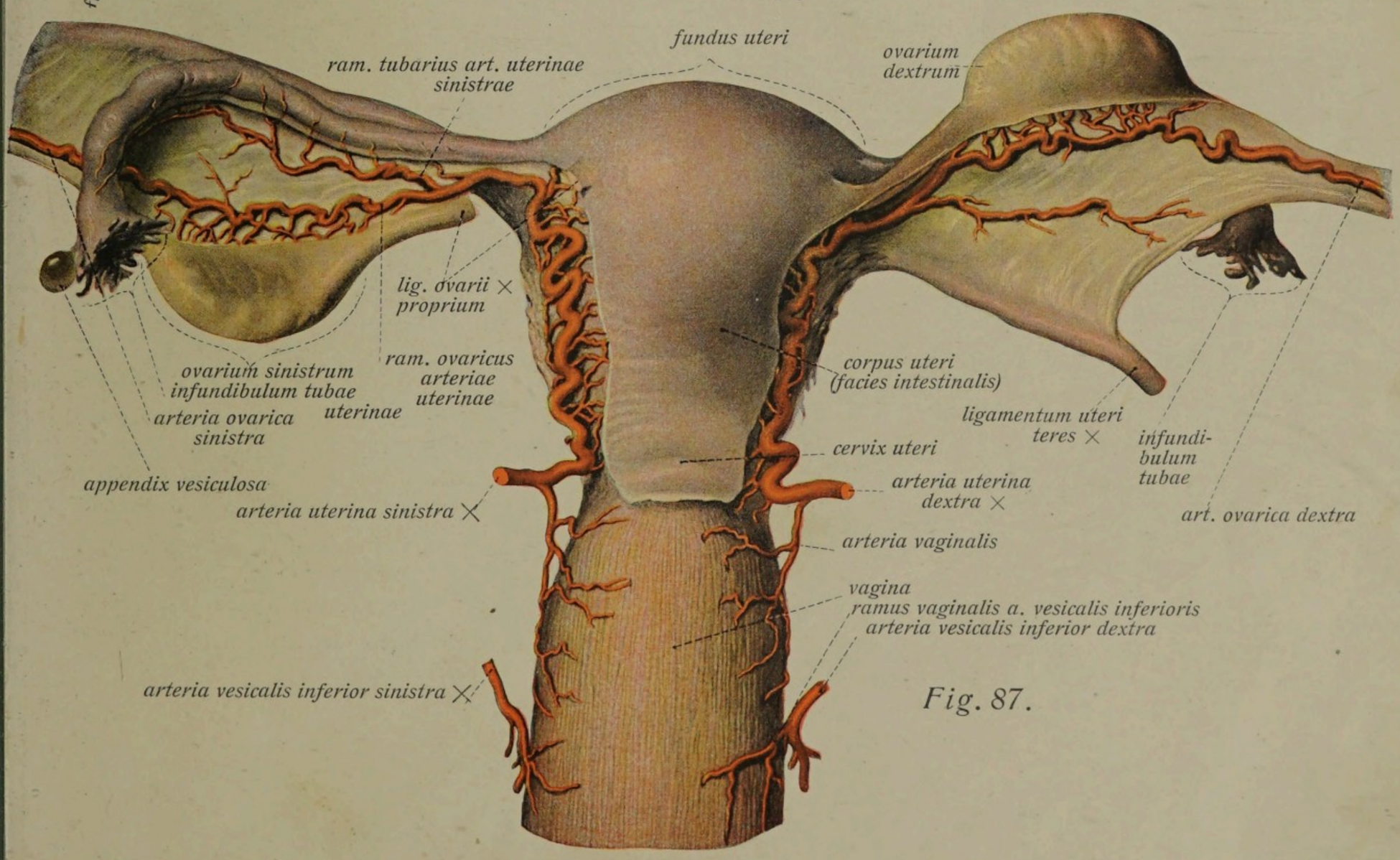
fundus uteri
ram. tubarius art. uterinae sinistrae
ovarium dextrum
lig. ovarii proprium
ram. ovaricus arteriae uterinae
ovarium sinistrum
infundibulum tubae
arteria ovarica sinistra
uterinae
corpus uteri (facies intestinalis)
ligamentum uteri teres
infundibulum tubae
cervix uteri
appendix vesiculosa
arteria uterina dextra
arteria uterina sinistra
art. ovarica dextra
arteria vaginalis
vagina
ramus vaginalis a. vesicalis inferioris
arteria vesicalis inferior dextra
arteria vesicalis inferior sinistra

Fig. 87.

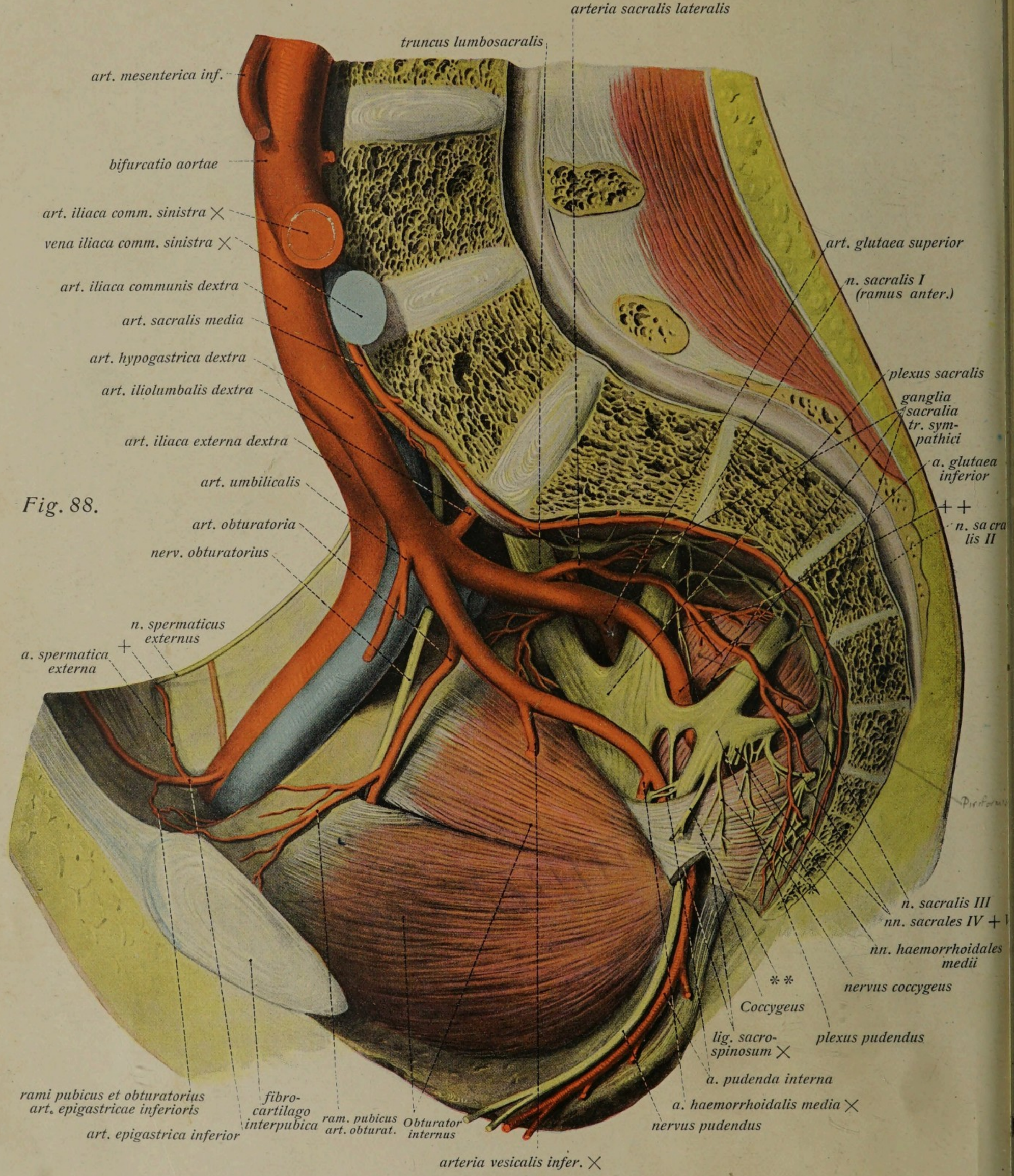
arteria sacralis lateralis
truncus lumbosacralis
art. mesenterica inf.
bifurcatio aortae
art. iliaca comm. sinistra ×
vena iliaca comm. sinistra ×
art. iliaca communis dextra
art. sacralis media
art. hypogastrica dextra
art. iliolumbalis dextra
art. iliaca externa dextra
art. umbilicalis
art. obturatoria
nerv. obturatorius
n. spermaticus externus
a. spermatica externa +
art. glutaea superior
n. sacralis I (ramus anter.)
plexus sacralis
ganglia sacralia tr. sympathici
a. glutaea inferior
++
n. sacralis II
n. sacralis III
nn. sacrales IV + V
nn. haemorrhoidales medii
**
nervus coccygeus
Coccygeus
lig. sacrospinosum ×
plexus pudendus
a. pudenda interna
a. haemorrhoidalis media ×
nervus pudendus
rami pubicus et obturatorius art. epigastricae inferioris
art. epigastrica inferior
fibrocartilago interpubica
ram. pubicus art. obturat.
Obturator internus
arteria vesicalis infer. ×

Fig. 88.

The Blood Vessels and Nerves of the Pelvis. (Cont.)

Fig. 88. The parietal blood vessels and nerves of the pelvis, from the left. (2/3)]
The pelvis is divided in the median line and the pelvic viscera are removed. * = branches to Coccygeus. ** = branch to the Levator ani, cut. + = position of the abdominal inguinal ring. ++ = branches to the Piriformis.

The Internal Iliac (Hypogastric) Artery.

(Cont. from p. 104)

b) **Parietal branches** for the most part from the posterior trunk, but in part from the anterior.

1. The *ilio-lumbar*, rather strong, arises from the internal iliac (hypogastric) and passes backwards and laterally behind the Psoas towards the iliac fossa to divide into an *iliac* and a *lumbar* branch. The latter goes to the adjacent muscles, corresponding to the posterior branches of the lumbar arteries; the former continues the direction of the main stem to the Iliacus, anastomosing with the deep circumflex iliac and the fourth lumbar. Fig. 80, 82, 86.

2. The *lateral sacral*, moderately strong and often double (superior and inferior), passes downwards and medially on the lateral part of the pelvic surface of the sacrum, parallel to and anastomosing with the middle sacral. It supplies the adjacent muscles and sends *spinal* branches to the sacral canal. Fig. 88.

3. The *obturator artery* is the only parietal branch that frequently arises from the anterior trunk of the internal iliac (hypogastric). It courses with the obturator nerve along the upper border of the lateral wall of the pelvis, giving off small branches and the *pubic* branch, which anastomoses with the pubic branch of the inferior epigastric (by this anastomosis, in about 30% of cases, the obturator artery arises from the inferior epigastric, see p. 90). The artery then passes through the obturator canal and divides in the thigh into an *anterior* and *posterior* branch, which supply the Adductors, behaving like the obturator nerve, but not extending so far downwards. Fig. 84, 88, 96, 97.

4. and 5. The *superior* and *inferior gluteal* arteries (see p. 123).

2. The External Iliac Vein

begins in the lacuna vasorum as the direct continuation of the femoral vein. It passes upwards medial to and behind the femoral artery to form the common iliac vein (see p. 96), anterior to the sacro-iliac articulation. Fig. 80, 82—85. It usually receives only two tributaries, which may open together.

1. The *inferior epigastric* which accompanies the inferior epigastric artery; it is at first double, but becomes single near its termination. Fig. 78, 80, 84, 85.

2. The *deep circumflex iliac* behaves like the preceding to its corresponding artery. Fig. 78, 84, 85.

The Nerves and Blood Vessels of the Perineum.

Fig. 89. The nerves and blood vessels of the male perineum. (2/3)
The superficial perineal musculature is exposed and the fat is removed from the ischio-rectal fossa. On the left the Transversus perinei superficialis and the urogenital diaphragm are divided and the Ischio-cavernosus drawn laterally * = point of division of the internal pudendal artery into the perineal artery and the artery of the penis.

The Pudendal Plexus.

A rather weak plexus formed principally by the 3rd. and 4th. sacral nerves. It is closely associated with the sacral plexus (see p. 120) and, like this, is situated in front of the origin of the Piriformis. Fig. 88. The following nerves arise from it.

1. The **middle haemorrhoidal nerves,** several small nerves that unite with the sympathetic hypogastric plexus and go to the rectum and the Levator ani. Fig. 88.

2. The **inferior vesical nerves** pass to the lower part of the bladder.

3. The **medial inferior cluneal nerve** pierces the sacro-tuberous ligament and curves around the medial border of the Glutaeus maximus to supply the skin of the gluteal region. Fig. 89, 90.

4. The **pudendal nerve,** the principal and terminal branch of the plexus, accompanies the internal pudendal artery (see p. 104) and terminates as the nerve of the penis (clitoris). Fig. 88—90. Its branches are:

a) The *inferior haemorrhoidal,* several rather strong branches to the Sphincter ani externus and the skin around the anus. Fig. 89, 90.

b) The *perineal nerve,* rather strong, runs superficially through the ischio-rectal fossa, accompanying the perineal artery (see p. 104). It sends branches to the anterior part of the Sphincter ani externus and to the perineal muscles (Transversus perinei and Bulbo-cavernosus) and ends in the *posterior scrotal (labial)* nerves to the posterior surface of the scrotum or the labia majora. Fig. 89, 90.

c) The *dorsal nerve of the penis,* the rather strong terminal branch (in the female the much smaller *nerve to the clitoris),* accompanies the dorsal artery of the penis, supplies the Ischio-cavernosus, passes to the dorsum of the penis, where it lies lateral to the dorsal artery, and supplies the penis as far as the glans and prepuce. Fig. 86.

The Coccygeal Plexus.

By far the smallest nerve plexus in the body, is formed by the last sacral and the coccygeal nerve. It is closely associated with the pudendal plexus and is connected with the coccygeal sympathetic ganglion. Fig. 88. In addition to branches to the Coccygeus, only four or five *anococcygeal nerves* arise from the plexus, these passing to the skin behind the tip of the coccyx. Fig. 88—90.

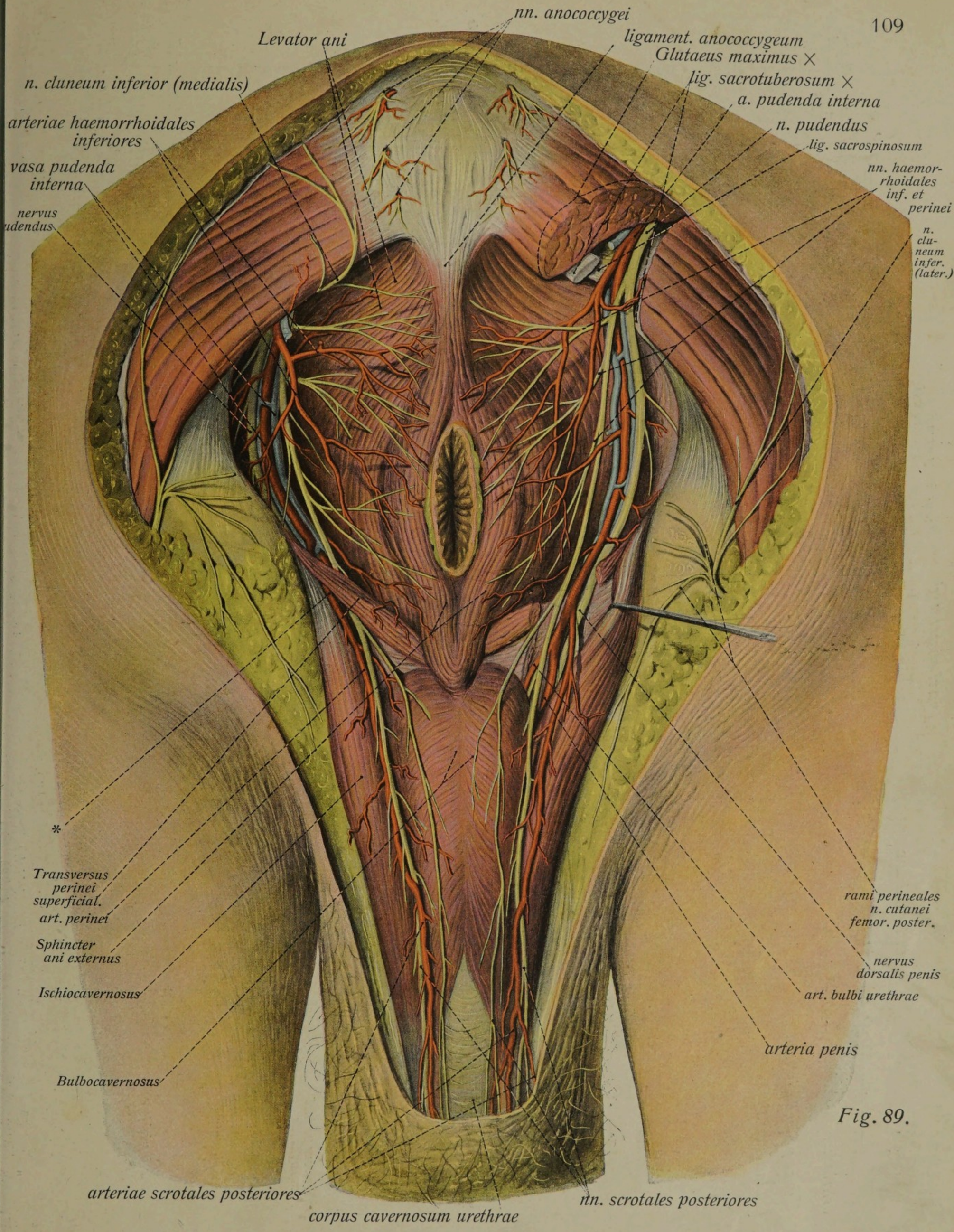
nn. anococcygei
Levator ani
ligament. anococcygeum
Glutaeus maximus ×
lig. sacrotuberosum ×
a. pudenda interna
n. pudendus
lig. sacrospinosum
n. cluneum inferior (medialis)
arteriae haemorrhoidales inferiores
vasa pudenda interna
nervus udendus
nn. haemorrhoidales inf. et perinei
n. cluneum infer. (later.)
*
Transversus perinei superficial.
art. perinei
Sphincter ani externus
Ischiocavernosus
Bulbocavernosus
rami perineales n. cutanei femor. poster.
nervus dorsalis penis
art. bulbi urethrae
arteria penis
arteriae scrotales posteriores
corpus cavernosum urethrae
nn. scrotales posteriores

Fig. 89.

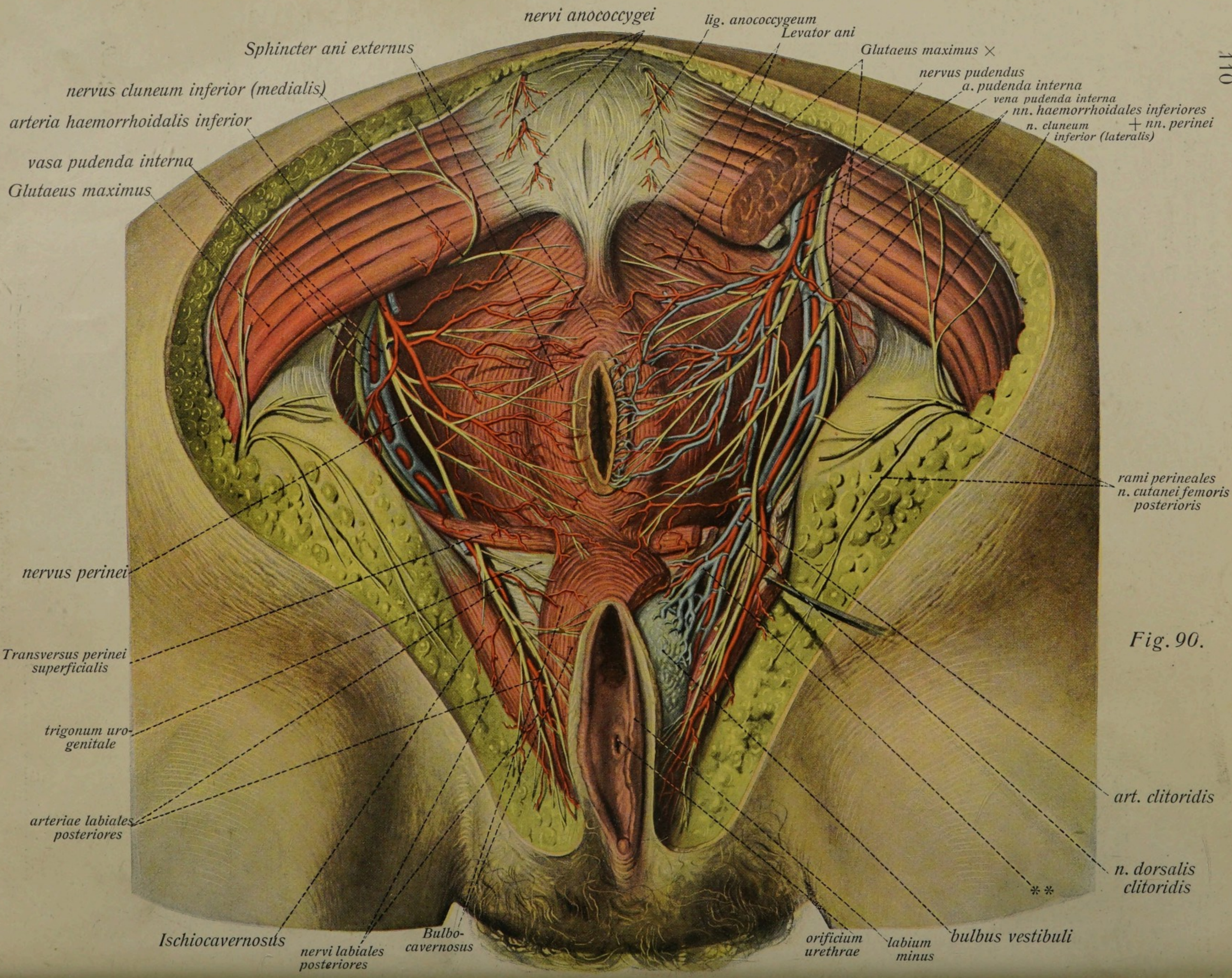

Fig. 90.

Fig. 90. The nerves and blood vessels of the female perineum. (2/3) On the right the Bulbo-cavernosus is partly removed and the bulbus vestibuli exposed. The Transversus perinei superficialis is cut and the urogenital diaphragm divided. ** = roots of the internal pudendal vein from the bulbus vestibuli.

The Nerves and Blood Vessels of the Perineum. (Cont.)

The Veins of the Pelvis.

I. The Internal Iliac (Hypogastric) Vein

a short thick trunk that lies behind the artery of the same name and is formed from veins which correspond to the branches of the artery, although characterized by a tendency to form plexuses, a condition especially marked in the true pelvis. Fig. 80, 84, 85. Its tributaries run singly or doubly (gluteal veins) with the branches of the artery (Fig. 80, 83, 84, 101). The following frequently anastomosing plexuses open into the vein.

1. The *anterior sacral plexus*, small, formed by the lateral and middle sacral veins.

2. The *haemorrhoidal plexus* in the wall of the rectum, drains for the most part also into the portal vein through the superior haemorrhoidal vein. Fig. 84, 85.

3. The *vesical plexus* in the walls and fundus of the bladder, drains by several vesical veins into the internal iliac. Fig. 84, 85.

4. The *utero-vaginal plexus* in the female, in the broad ligament on either side of the uterus as well as in the walls of the vagina, is connected with the pampiniform plexus and drains principally by the uterine veins into the internal iliac. Fig. 85.

5. The *pudendal plexus* lies chiefly between the base of the bladder and the pubic symphysis and in the male is formed principally by the dorsal vein of the penis. This is an unpaired vein lying in the median line of the dorsum of the penis; it arises at the glans, passes proximally between the two dorsal arteries of the penis, receiving branches at an acute angle. It passes beneath the symphysis, between the arcuate and transverse ligaments, and enters the plexus. Fig. 86.

6. The *internal pudendal vein* corresponds in its course to the internal pudendal artery. It may be double or plexiform in parts of its course and is also connected with the pudendal plexus. Fig. 89, 90. Its roots correspond in general with the branches of the artery *(posterior scrotal or labial, inferior haemorrhoidal, deep veins of the penis (clitoris), vein of the urethral vestibular bulb, etc.)*. Fig. 84, 85, 89, 90.

Fig. 90. The nerves and blood vessels of the female perineum. (2/3) On the right the Bulbo-cavernosus is partly removed and the bulbus vestibuli exposed. The Transversus perinei superficialis is cut and the urogenital diaphragm divided. ** = roots of the internal pudendal vein from the bulbus vestibuli.

The Nerves and Blood Vessels of the Lower Extremity.

Fig. 91. The superficial nerves, arteries and veins of the anterior surface of the thigh. (1/3)
Fig. 92. The superficial nerves and veins of the medial surface of the lower leg. (1/3)
* = connection with deep veins. ** = connection with the small saphenous vein.

The Superficial Veins of the Leg.

1. The *great saphenous vein*, the largest superficial vein in the body, arises on the dorsum of the foot from the dorsal venous rete and from the medial end of the dorsal venous arch. It receives some veins from the plantar region and then passes up the medial surface of the lower leg and the thigh, inclining towards the anterior surface in the upper third of its course. It passes over the falciform border of the fascia lata and empties into the femoral vein. On its way it receives numerous branches, those of the thigh being the larger, and just before its termination it receives the *superficial epigastric* and *superficial circumflex iliac veins* and usually also the *external pudendals*. Fig. I 312, III 91, 92, 94, 108.

2. The *small saphenous vein* arises on the lateral side of the dorsum of the foot. It ascends behind the lateral malleolus on the posterior surface of the lower leg and, in the groove between the two heads of the Gastrocnemius, it pierces the fascia to open into the popliteal vein in the popliteal fossa. Before its termination it receives a vein from above, the *femoro-popliteal*, and by this and other anastomoses is brought into connection with the great saphenous. It is also connected with the deep veins of the lower leg by a strong branch. Fig. 91, 94, 108.

The Cutaneous Nerves of the Upper and Lower Leg.

The cutaneous nerves of the leg come mainly from the lumbar plexus (the anterior surface of the thigh, and, by the saphenous nerve, the lower leg to the foot) and sacral plexus (posterior surface of the thigh, the lower leg and foot); only to a small extent from the pudendal plexus and from the posterior branches of the lumbar and sacral nerves.

I. *From the lumbar plexus* (see p. 95).

1. The *lumbo-inguinal nerve* from the genito-femoral, pierces the fascia lata near the fossa ovalis and supplies the skin in that region. Fig. 91.

2. The *lateral femoral cutaneous* passes through the fascia immediately beneath the anterior superior spine of the ilium and supplies the skin of the lateral surface and lateral part of the anterior surface of the thigh. Fig. 80, 91, 93.

3. The *anterior femoral cutaneous* two or three in number, pierce the fascia lata in the upper and middle thirds of the thigh and supply the skin of its anterior surface as far down as the knee. Fig. 91.

4. The *cutaneous branch of the obturator* pierces the fascia lata, usually as several fine twigs, below the middle of the thigh. It frequently anastomoses with the preceding and supplies the medial surface of the lower half of the thigh. Fig. 91, 96.

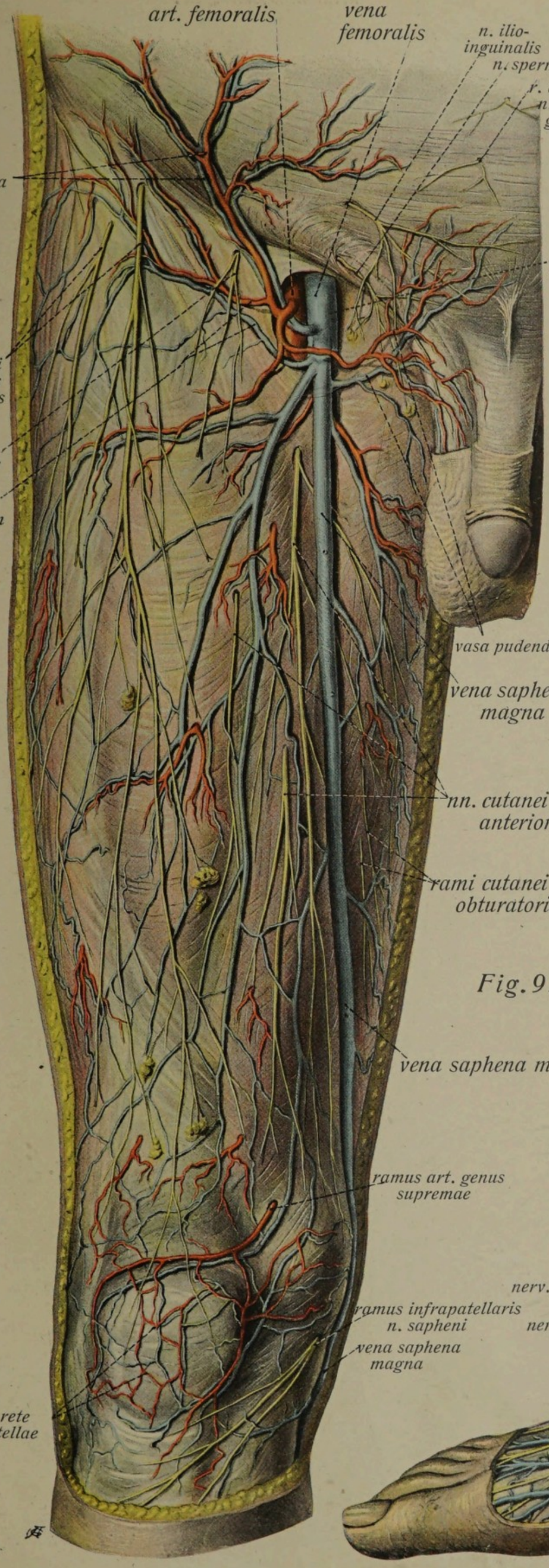
art. femoralis
vena femoralis
n. ilio-inguinalis
n. spermaticus ext.
r. cutan. ant. n. iliohypo-gastrici
fossa ovalis
vasa pudenda externa
vena saphena magna
nn. cutanei femoris anteriores
rami cutanei nervi obturatorii
vena saphena magna
ramus art. genus supremae
ramus infrapatellaris n. sapheni
vena saphena magna
rete patellae

Fig. 91.

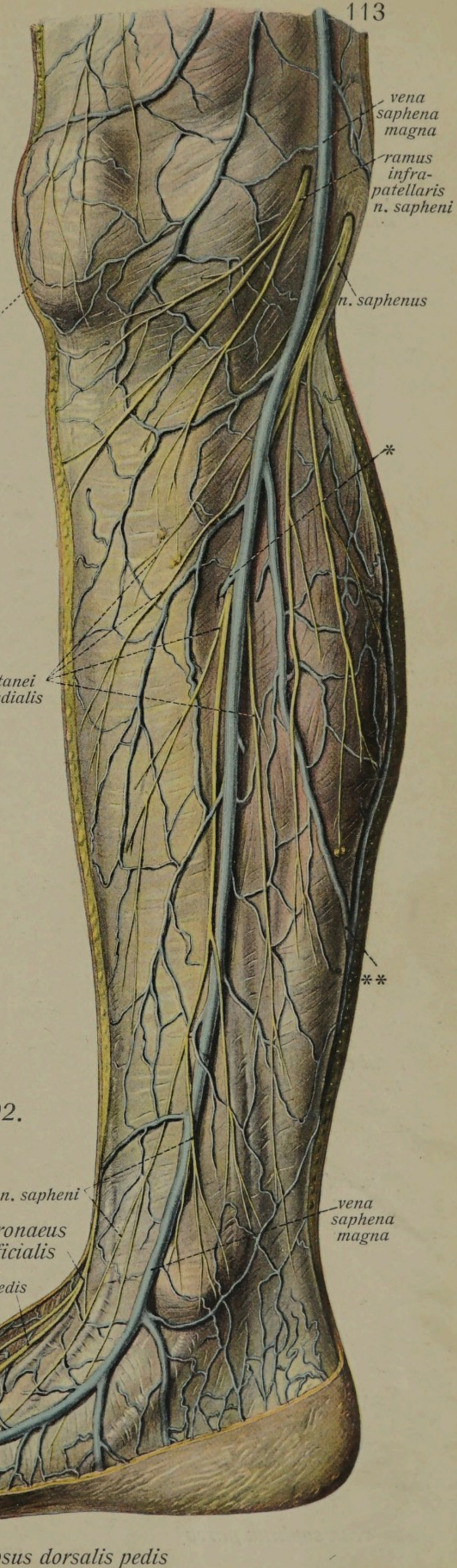
vena saphena magna
ramus infra-patellaris n. sapheni
n. saphenus
patella
nervi cutanei cruris medialis
rami terminales n. sapheni
n. peronaeus superficialis
nerv. cutaneus dorsalis pedis medialis
nerv. cutan. dorsal. pedis inter-medius
vena saphena magna
arcus venosus dorsalis pedis

Fig. 92.

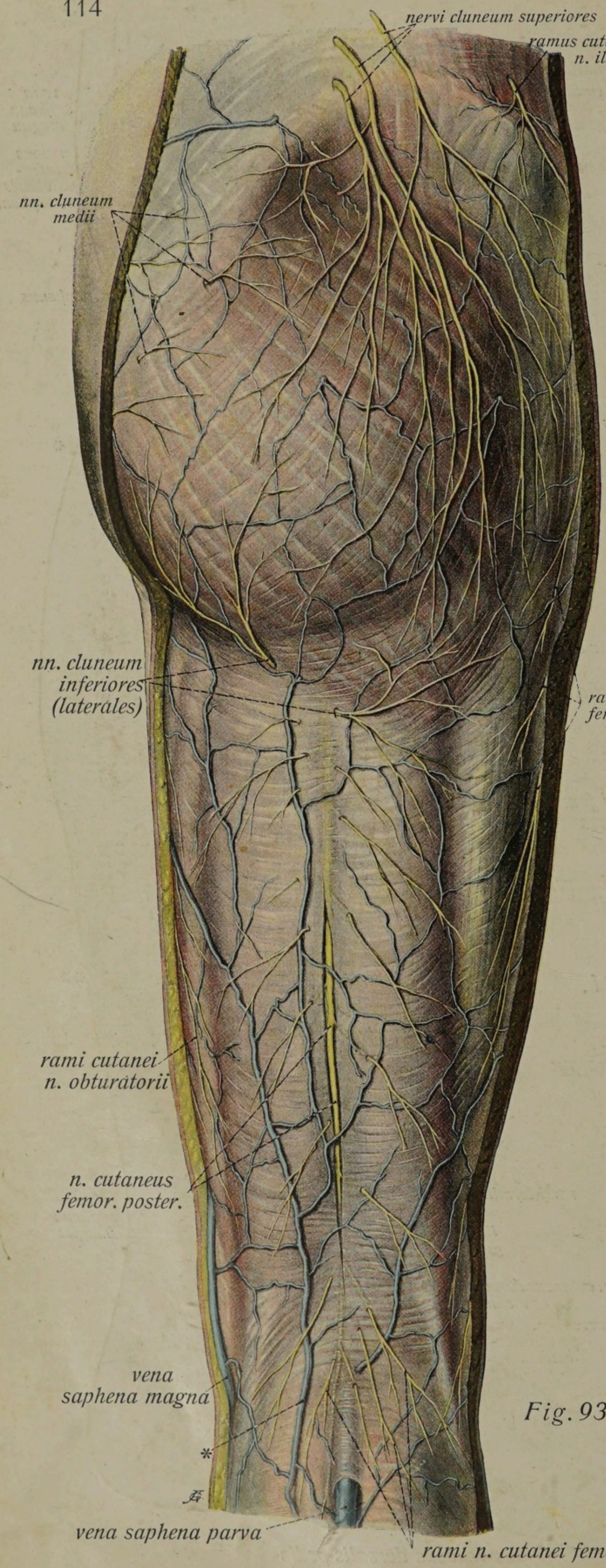
nervi cluneum superiores
ramus cutaneus lateralis n. iliohypogastrici
nn. cluneum medii
nn. cluneum inferiores (laterales)
rami cutanei n. obturatorii
n. cutaneus femor. poster.
vena saphena magna
vena saphena parva
rami n. cutanei femoris poster.

Fig. 93.

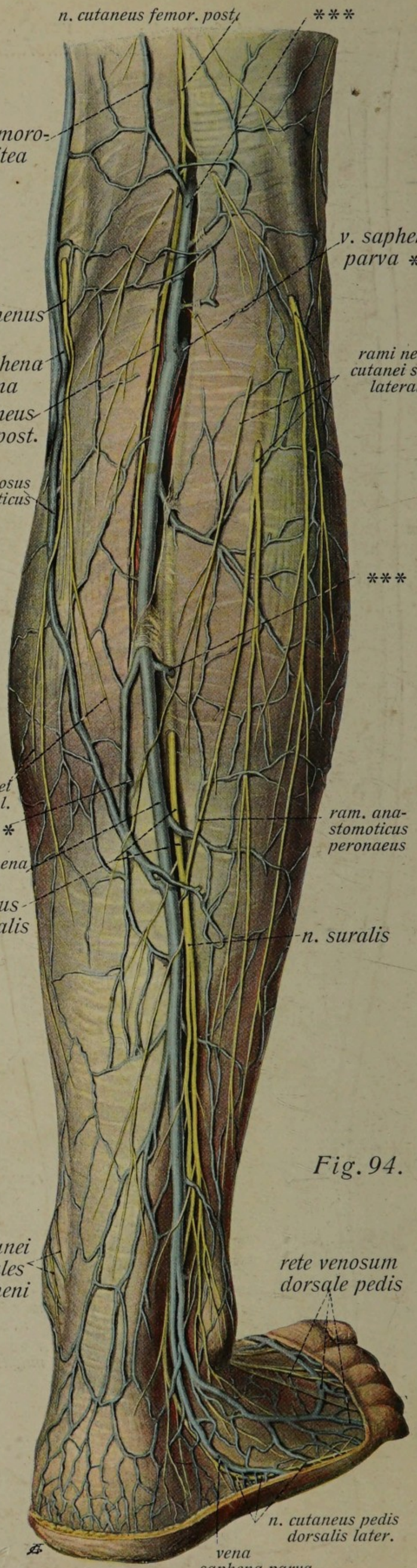
n. cutaneus femor. post.
***
vena femoro-poplitea
v. saphena parva **
nervus saphenus
vena saphena magna
n. cutaneus femoris post.
rami nervi cutanei surae lateralis
ramus venosus anastomoticus
***
rami n. cutanei femor. lateralis
nervi cutanei cruris medial.
***
ram. anastomoticus peronaeus
vena saphena parva
n. cutaneus surae medialis
n. suralis
rami cutanei cruris mediales nervi sapheni
rete venosum dorsale pedis
n. cutaneus pedis dorsalis later.
vena saphena parva

Fig. 94.

nervus femoris
nervus femoris lateralis
ligam. inguinale
arteria circumfl. ilium profunda
nervus femoralis
arteria profunda femoris
Tensor fasciae latae
arteria femoralis
Rectus femoris
Sartorius
Vastus lateralis
Vastus medialis
ram. musculo-articu
art. genus supre
rete patell
Fig. 95
ligam.

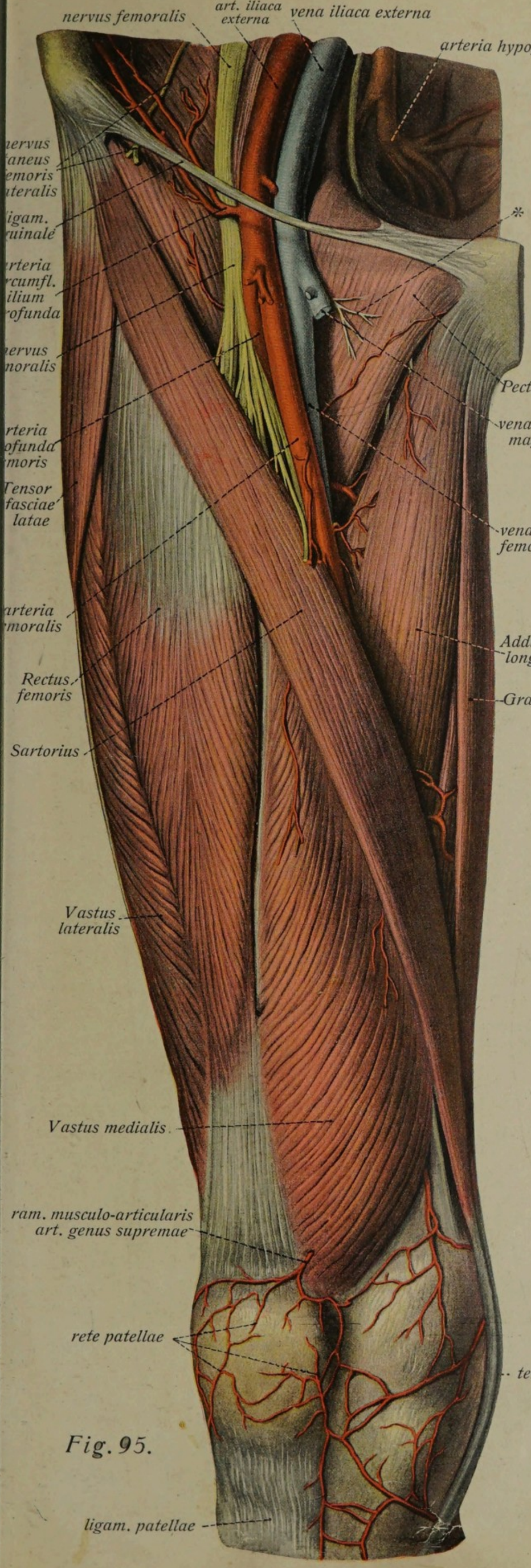
nervus femoralis
art. iliaca externa
vena iliaca externa
arteria hypogastrica
nervus cutaneus femoris lateralis
ligam. inguinale
arteria circumfl. ilium profunda
nervus femoralis
arteria profunda femoris
Tensor fasciae latae
arteria femoralis
Rectus femoris
Sartorius
Vastus lateralis
Vastus medialis
ram. musculo-articularis art. genus supremae
rete patellae
ligam. patellae
Pectineus
vena saphena magna ×
Sartorius ×
vena femoralis
Adductor longus
Gracilis
a. profunda femoris
r. descendens art. circumfl. later.

Fig. 95.

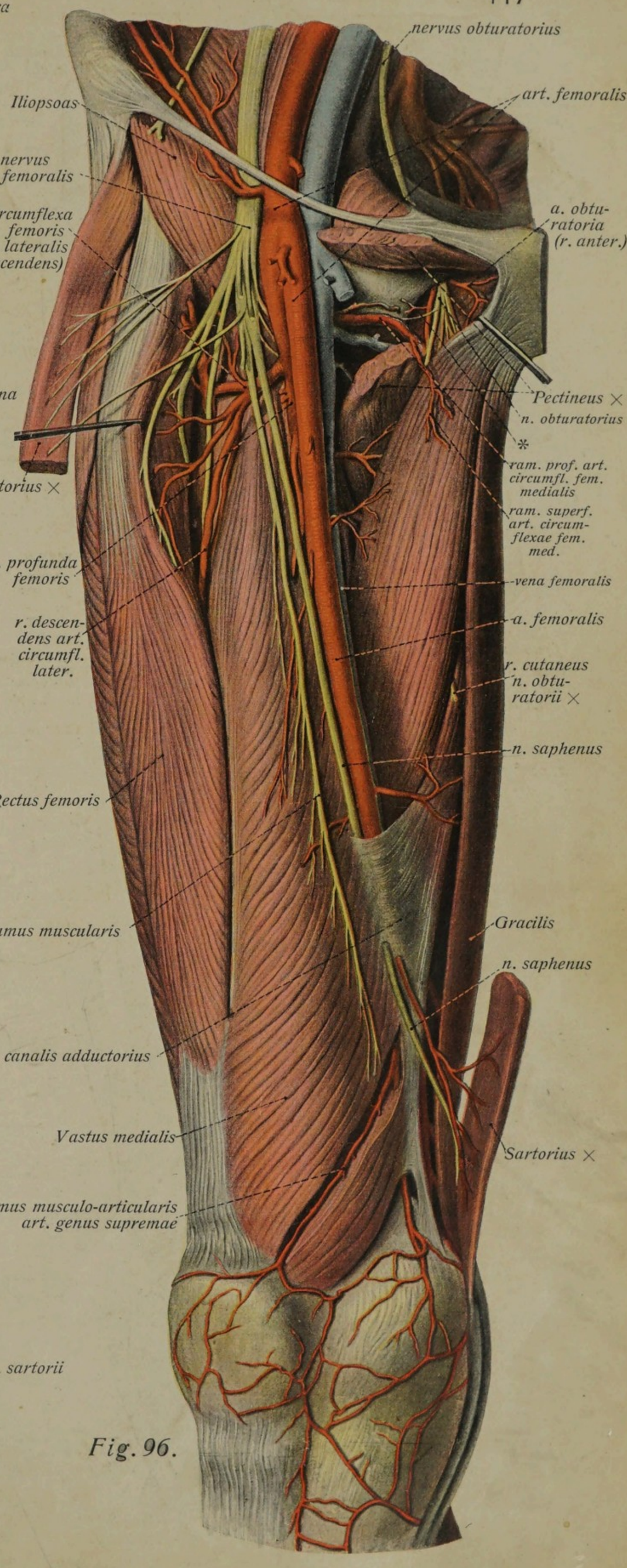
nervus obturatorius
art. femoralis
Iliopsoas
nervus femoralis
a. circumflexa femoris lateralis (r. ascendens)
a. obturatoria (r. anter.)
Pectineus ×
n. obturatorius
ram. prof. art. circumfl. fem. medialis
ram. superf. art. circumflexae fem. med.
vena femoralis
a. femoralis
r. cutaneus n. obturatorii ×
n. saphenus
Rectus femoris
ramus muscularis
Gracilis
n. saphenus
canalis adductorius
Vastus medialis
Sartorius ×
ramus musculo-articularis art. genus supremae

Fig. 96.

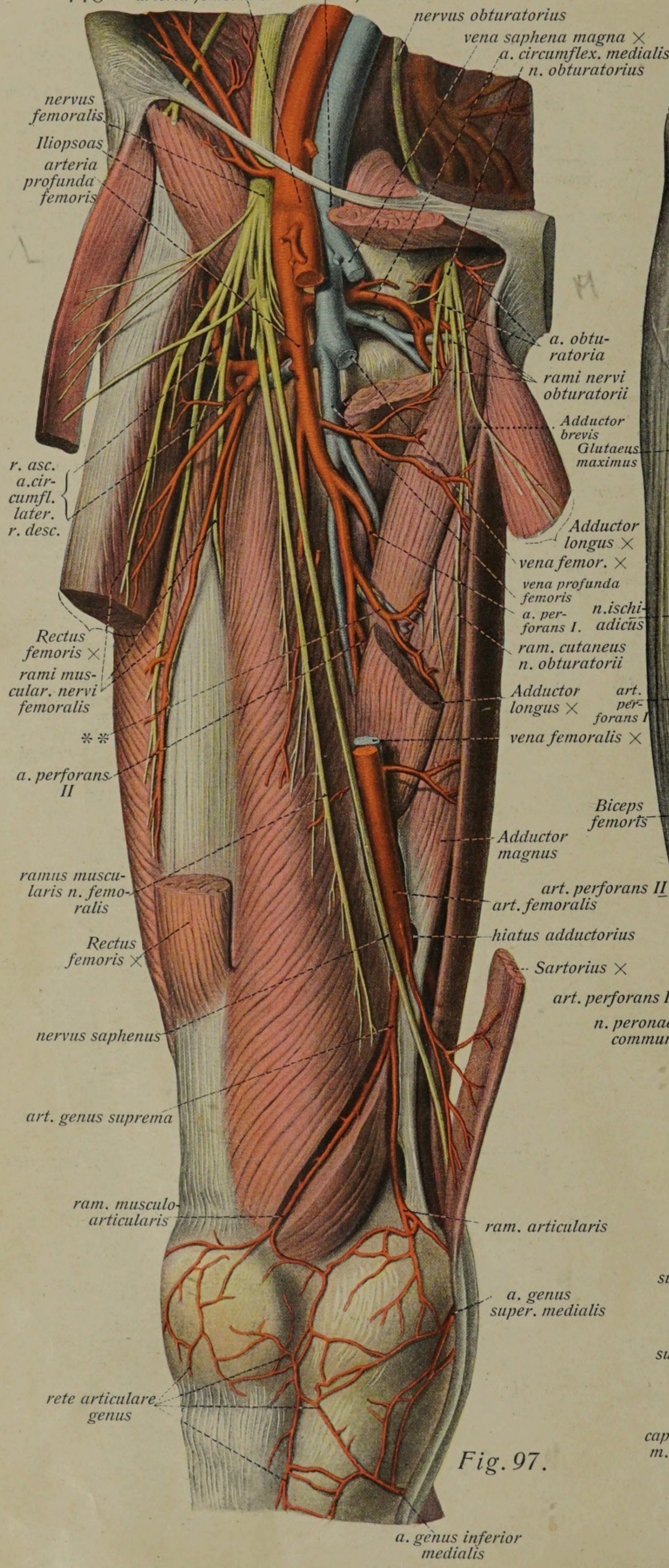
arteria femoralis
vena femoralis
nervus obturatorius
vena saphena magna ×
a. circumflex. medialis
n. obturatorius
nervus femoralis
Iliopsoas
arteria profunda femoris
a. obtu-ratoria
rami nervi obturatorii
Adductor brevis
Glutaeus maximus
r. asc. a.cir-cumfl. later.
r. desc.
Adductor longus ×
vena femor. ×
vena profunda femoris
a. per-forans I.
n.ischi-adicus
ram. cutaneus n. obturatorii
Rectus femoris ×
rami mus-cular. nervi femoralis
Adductor longus ×
art. per-forans I
vena femoralis ×
* *
a. perforans II
Biceps femoris
Adductor magnus
n. tibialis
ramus muscu-laris n. femo-ralis
art. perforans II
art. femoralis
Semitendinosus
Rectus femoris ×
hiatus adductorius
hiatus adductorius
Sartorius ×
art. perforans III
n. peronaeus communis
nervus saphenus
Gracilis
art. genus suprema
Semimem-branosus
art. poplitea
ram. musculo-articularis
ram. articularis
Sartorius
n. cutaneus surae lateralis
vena poplitea
art. genus superior medialis
a. genus super. medialis
n. cutaneus surae medialis
rami ad. m. gastrocn.
n. suralis
caput mediale m. gastrocn.
rete articulare genus
caput laterale m. gastrocn.
a. genus inferior medialis
nn. cutanei clunium superiores
nn. cutanei clunium inferiores
n. cutaneus femoris posterior

Fig. 97.

Fig. 98.

The Nerves and Blood Vessels of the Lower Extremity. (Cont.)

Fig. 97. The nerves and blood vessels of the front of the thigh, deep layer. (1/3)
Preparation as in Fig. 96, but the Rectus femoris and Adductor longus are also cut. ** = stronger muscular branch of the deep femoral artery.

Fig. 98. The superficial layer of the gluteal region and of the posterior surface of the thigh (from Schultze-Lubosch, Topographische Anatomie). (1/3)
The fascia is removed except over the gluteal region; the Biceps femoris is drawn aside to expose the sciatic nerve.

The Femoral Nerve

formed from the lumbar plexus (see p. 99), passes with the Ilio-psoas through the lacuna musculorum, lying lateral to the artery and separated from it by the deep layer of the fascia lata (ilio-pectineal fascia). Below the inguinal (Poupart's) ligament it divides into:

1. The *anterior cutaneous* branches (see p. 112); 2. *Muscular* branches to the Pectineus, Sartorius and Quadriceps; 3. the *saphenous* nerve, the terminal branch (see p. 115). Fig. 82, 95—97.

The Obturator Nerve

formed from the lumbar plexus (see p. 99), passes through the obturator canal, giving branches to both the Obturator muscles. In the thigh it branches into:

1. An *anterior* branch, stronger than the following, runs downwards between the Adductor brevis and magnus, supplies the Gracilis, Adductor longus and brevis and gives off a cutaneous branch (see p. 112).

2. A *posterior* branch, runs downwards between the Obturator externus and the Adductor magnus and minimus and supplies these muscles. Fig. 80, 95—97.

The Obturator Artery

from the internal iliac (hypogastric) (see p. 107), is relatively much weaker than the nerve. Like this it divides, after it has passed through the obturator canal, into an *anterior* and a *posterior* branch, which supply the Adductors. The posterior anastomoses with the medial femoral circumflex. Fig. 84, 96, 97.

The Femoral Vein

is the continuation of the popliteal vein (see p. 123). In the lower part of its course, in the Adductor canal, it lies behind the artery, but passes medially as it ascends and in the region of the fossa ovalis and below the inguinal ligament it is medial to the artery. It receives the *deep femoral* vein, the great saphenous (see p. 112) and usually a number of small branches corresponding to the branches of the femoral artery. These last are double as is also the deep femoral, though this usually becomes single before its termination. Fig. 95—97.

The Nerves and Blood Vessels of the Lower Extremity. (Cont.)

Fig. 99. The nerves and blood vessels of the back of the thigh, superficial layer. (1/3)
Only the fascia is removed. * = connection of the small saphenous vein with branches of the deep femoral vein.

Fig. 100. The nerves and blood vessels of the back of the thigh, deep layer, and of the hip, middle layer. (1/3)
The Glutaeus maximus is divided and reflected, also the long head of the Biceps.
* = connection of the small saphenous with the deep veins of the thigh.
** = long head of the Biceps cut.

The Sacral Plexus.

The *sacral plexus* (see p. 95 and Fig. 81) is a broad flat cord which passes through the great sciatic notch and divides into the following branches.

1. The *superior gluteal* nerve runs with the superior gluteal artery through the great sciatic foramen above the Piriformis and supplies the Glutaeus medius and minimus, the Tensor fasciae latae and usually also the Piriformis. Fig. 101.

2. The *inferior gluteal* nerve accompanies the inferior gluteal artery through the sciatic foramen below the Piriformis, and supplies the Glutaeus maximus. Fig. 100, 101.

3. The *posterior femoral cutaneous* nerve also passes below the Piriformis (see p. 115).

4. *Muscular* branches to the Gemelli and Quadratus femoris; they may also come from the following. Fig. 101.

5. The *sciatic (ischiadic)* nerve is much the strongest branch of the plexus, indeed, the largest nerve in the body. It passes through the great sciatic foramen below the Piriformis and lies at first beneath the Glutaeus maximus, resting on the Obturator internus, Gemelli, Quadratus femoris and Adductor minimus. It then passes beneath the long head of the Biceps and comes to lie between this and the Semitendinosus. At about the middle of the thigh or even higher it divides into its terminal branches, the *tibial* and the weaker *common peroneal* nerves. In the thigh it gives off branches to the flexor muscles and to the Adductor magnus. (Cont. on p. 124 and 127.) Fig. 99, 100, 101.

The Popliteal Artery.

This is the direct continuation of the femoral artery (see p. 116) and begins at the adductor hiatus. It ends in the popliteal canal, where it divides into its terminal branches. It runs through the middle of the popliteal fossa, resting on the femur and the posterior surface of the knee joint, and somewhat medial to the vein. It passes between the two heads of the Gastrocnemius, over the posterior surface of the Popliteus and under the popliteal arch of the Soleus, and then divides into the anterior and posterior tibial arteries. Fig. 100, 102—105, 107. Its branches are:

1. The *lateral superior artery of the knee* runs forwards around the lateral condyle of the femur, between the bone and the tendon of the Biceps, to the adjacent muscles and to the articular rete of the knee. Fig. 102, 106, 107.

2. The *medial superior artery of the knee* arises at the same level as the preceding and runs medially above the medial epicondyle of the femur, between the bone and the tendons of the Semitendinosus, Semimembranosus, Gracilis, and Sartorius, to the rete of the knee. Fig. 97, 102, 107.

3. The *middle artery of the knee* arises in the lower part of the popliteal fossa from the anterior surface of the artery and passes to the knee joint. Fig. 107.

4. The *sural* arteries, muscular branches for the Triceps surae, partly deep between the heads of the muscles and partly superficial between the Gastrocnemius and the skin. Fig. 97, 102, 107.

---

nervi cluneum medii
fascia glutaea (Glutaeus medius)
Glutaeus maximus
nervi cluneum inferiores (laterales) ×
Glutaeus maximus
Vastus lateralis
Gracilis
Semimembranosus
n. cutaneus femoris posterior ×
Biceps femoris
Semitendinosus
nervus tibialis
nervus peronaeus communis
Semimembranosus
art. poplitea
vena poplitea
vena saphena parva
*
n. cutaneus surae lateralis
tendo m. bicipitis femoris
Gastrocnemius
n. cutaneus surae medialis
vena saphena parva

Fig. 99.

arteria glutaea inferior
n. glutaeus inferior
vasa pudenda intern. + nervus pudendus
nervus cutaneus femoris posterior ×
rami art. circumflexae femoris medialis
rami musculares nervi tibialis
nerv. ischiadicus
caput longum Bicipitis ×
Semitendinosus
Semimembranosus
nervus tibialis
vena poplitea
arteria poplitea
nervus tibialis
v. saphena parva
nervus cutaneus surae med.
art. glutaea superior ramus superficialis
Glutaeus medialis
Piriformis
Obturator internus cum gemellis
Glutaeus maximus
rete trochanter-icum
Quadratus femoris
Adductor minimus
a. perforans I
Adductor magnus
a. perforans II
r. muscular. n. peronaei
**
a. perforans III
caput breve Bicipitis
n. peronaeus communis
*
nerv. cutaneus surae lateralis

Fig. 100.

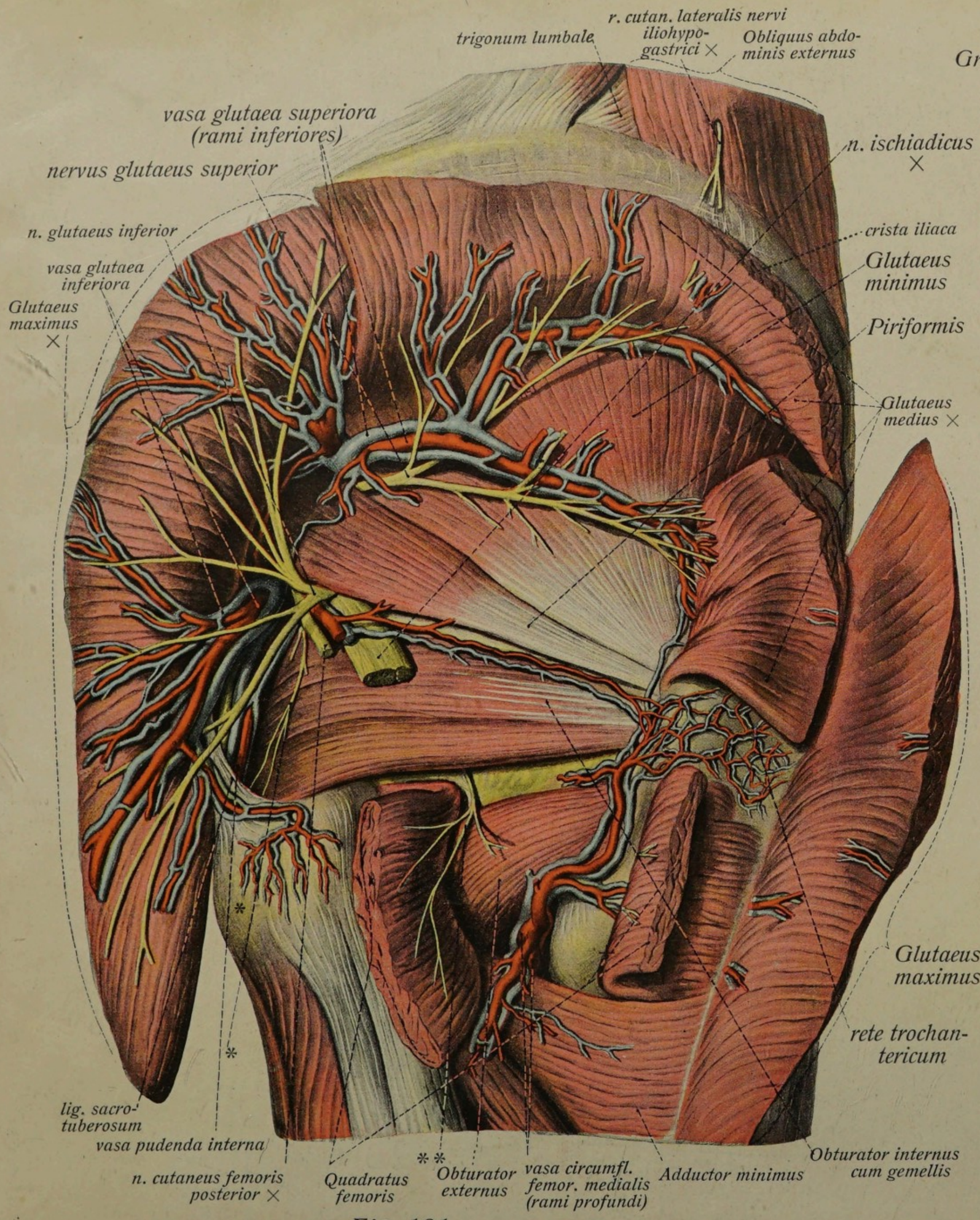

Fig. 101.

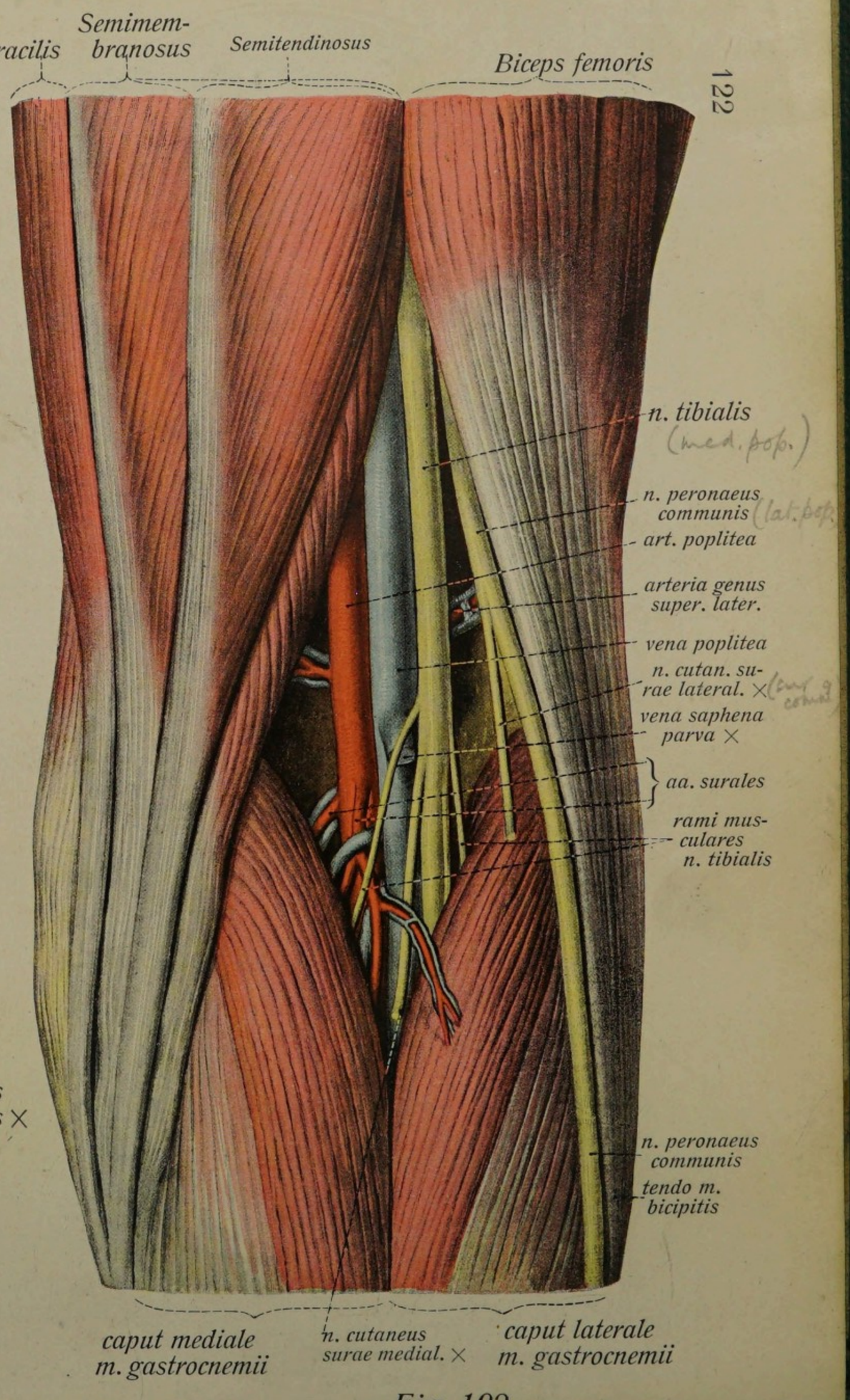

Fig. 102.

Fig. 101. The nerves and blood vessels of the posterior region of the hip, deep layer. (1/2)
The Glutaeus maximus, Glutaeus minimus and Quadratus femoris are cut, and also the sciatic nerve. * = muscular branch to the Gemelli. ** = to the Quadratus femoris. + (on the Figure) = the lesser trochanter. * (on the Figure) = tuberosity of the ischium.

The Nerves and Blood Vessels of the Lower Extremity. (Cont.)

The Popliteal Artery. (Cont.)

5. The *lateral inferior artery of the knee* arises just below the popliteal fossa, under cover of the lateral head of the Gastrocnemius, and curves around the lateral condyle of the tibia, behind the origin of the Popliteus, to the adjacent muscles and to the rete of the knee. Fig. 107.

6. The *medial inferior artery of the knee* arises opposite the preceding under cover of the medial head of the Gastrocnemius. It passes on the upper border of the Popliteus around the medial condyle of the tibia to the adjacent muscles and the rete of the knee. Fig. 102—105, 107.

7. The *posterior tibial* artery, see p. 124.

8. The *anterior tibial* artery, see p. 127.

Branches of the internal iliac (hypogastric) artery. (Cont. from p. 107.)

1. The *superior gluteal* artery, usually the termination of the posterior trunk of the internal iliac. It passes through the great sciatic foramen above the Piriformis, and divides into a *superior* and an *inferior* branch. The former runs between the Glutaeus maximus and medius and supplies chiefly the upper part of the former; the inferior branch runs between the Glutaeus medius and minimus and is supplied to these two muscles. The artery anastomoses with the inferior gluteal and with the deep branch of the medial femoral circumflex. Fig. 88, 100, 101.

2. The *inferior gluteal* artery passes through the great sciatic foramen below the Piriformis. It lies under cover of the Glutaeus maximus and supplies the lower part of this, as well as the Gemelli, the Quadratus femoris and the skin of the gluteal region. It anastomoses with the preceding and with the deep branch of the medial femoral circumflex. A long slender branch is the *a. comitans nervi ischiadici*. Fig. 88, 100, 101.

The Trochanteric rete

a small network situated on the great trochanter of the femur, under cover of the Glutaeus maximus. It is formed by fine branches of both the gluteal arteries and of the deep branch of the medial circumflex femoral. Occasionally branches of other arteries, the lateral femoral circumflex, the first perforating, participate. Fig. 100, 101.

The Popliteal Vein

follows the course of the popliteal artery through the popliteal fossa, lying behind and somewhat lateral to it. It is double in the lower part of its course, this double portion having origin from the doubled anterior and posterior tibial veins. Fig. 102—104.

Fig. 101. The nerves and blood vessels of the posterior region of the hip, deep layer. (1/2)
The Glutaeus maximus, Glutaeus minimus and Quadratus femoris are cut, and also the sciatic nerve. * = muscular branch to the Gemelli. ** = to the Quadratus femoris. + (on the Figure) = the lesser trochanter. * (on the Figure) = tuberosity of the ischium.

Fig. 102. The nerves and blood vessels of the popliteal fossa, superficial layer. (2/3)

The Nerves and Blood Vessels of the Lower Extremity. (Cont.)

Fig. 103. The nerves and blood vessels of the back of the lower leg, superficial layer. (1/3)
The Gastrocnemius is divided and reflected.

Fig. 104. The nerves and blood vessels of the back of the lower leg, middle layer. (1/3)
Preparation as in Fig. 103, but the Soleus is also divided and drawn aside.

The Tibial Nerve (see p. 120)

arises in the thigh by the division of the sciatic nerve. It passes vertically through the popliteal fossa, behind and lateral to the popliteal vessels. It enters the popliteal canal with them and runs on the lateral side of the posterior tibial artery, at first between the Soleus and the deep flexors, and then under the laciniate ligament behind the medial malleolus to the foot, where it divides into its terminal branches. Fig. 100, 102—105. Its branches are:

1. *Muscular* branches to the Popliteus, Triceps surae, and the three deep Flexors. Fig. 103—105.

2. The *medial sural cutaneous*, see p. 115.

3. The *medial calcaneal* arise a short distance above the division of the nerve into its terminal branches. They supply the skin of the medial side of the foot and the posterior part of the plantar region. Fig. 111.

4. and 5. The *medial* and *lateral plantar* nerves, see p. 132.

The posterior tibial artery (see p. 120)

arises in the popliteal canal, as the stronger terminal branch of the popliteal artery. It passes downwards with the tibial nerve (see above) between the Soleus and the deep Flexors (Tibialis posterior and Flexor digitorum), and, in the lower third of the leg, passes out from under the medial border of the Soleus and comes to lie beneath the fascia. It then runs behind the medial malleolus under the laciniate ligament to the sole of the foot, where it divides into its terminal branches, the *medial* and *lateral plantar* arteries (see p. 131). Fig. 104, 105, 107, (111—113). In addition to *muscular* branches and the *nutrient* artery to the tibia its branches are:

1. The *fibular branch* to the muscles at the upper end of the fibula and to the rete of the knee (not shown). Fig. 105.

2. The *peroneal artery* arises from the upper part of the artery and runs downwards, almost parallel to it, between the Tibialis posterior and the Flexor hallucis longus. Then, covered by the latter, it continues downwards on the posterior surface of the interosseous membrane (no nerve accompanying it!). Fig. 104, 105. In addition to *muscular* branches and a *nutrient* artery to the fibula it gives off:

a) A *perforating* branch which passes through the interosseous membrane and then downwards on its anterior surface to end in the lateral malleolar rete. Fig. 106.

b) A *communicating* branch to the posterior tibial. It passes transversely above the ankle joint. Fig. 105.

c) The *lateral posterior malleolar* usually one of the terminal branches; to the lateral malleolar rete. Fig. 105.

d) *Lateral calcaneal* branches, also terminal branches, to the calcaneal rete. Fig. 105.

3. The *medial posterior malleolar* passes between the tendons and the bone to the medial malleolar rete. Fig. 105.

4. *Middle calcaneal* branches to the calcaneal rete. Fig. 105.

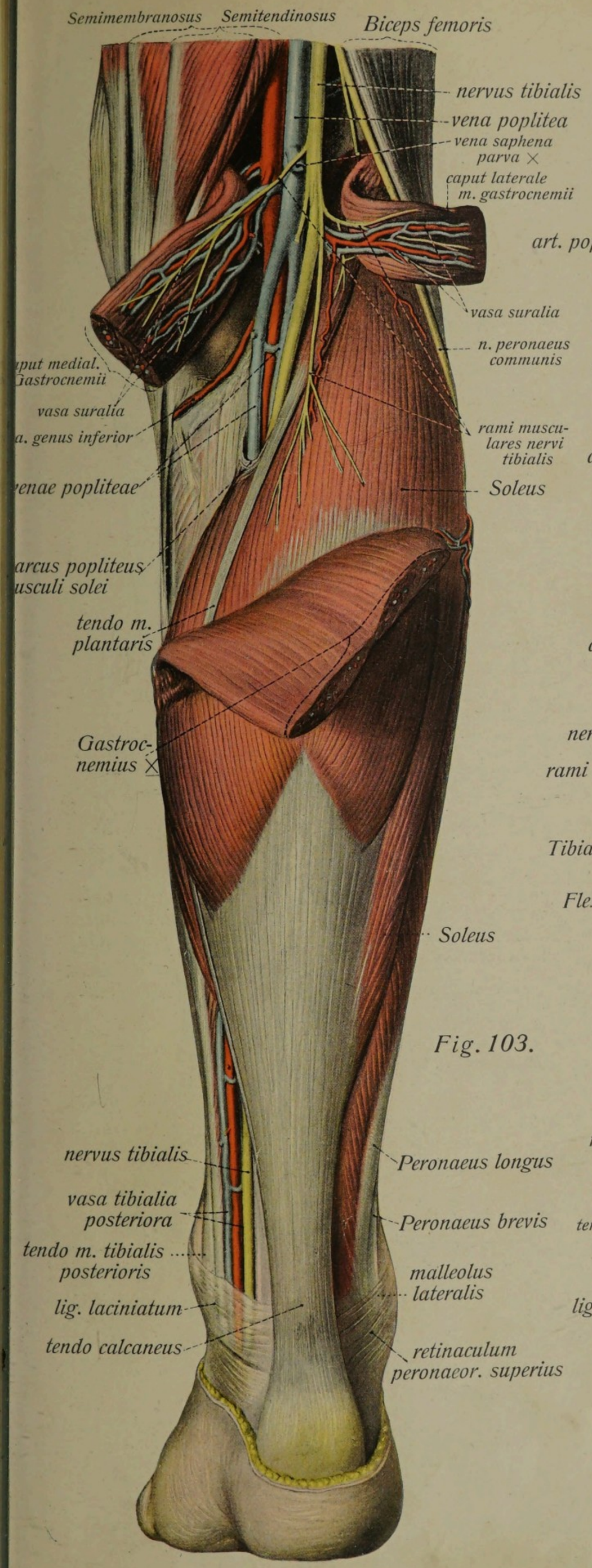

Fig. 103.

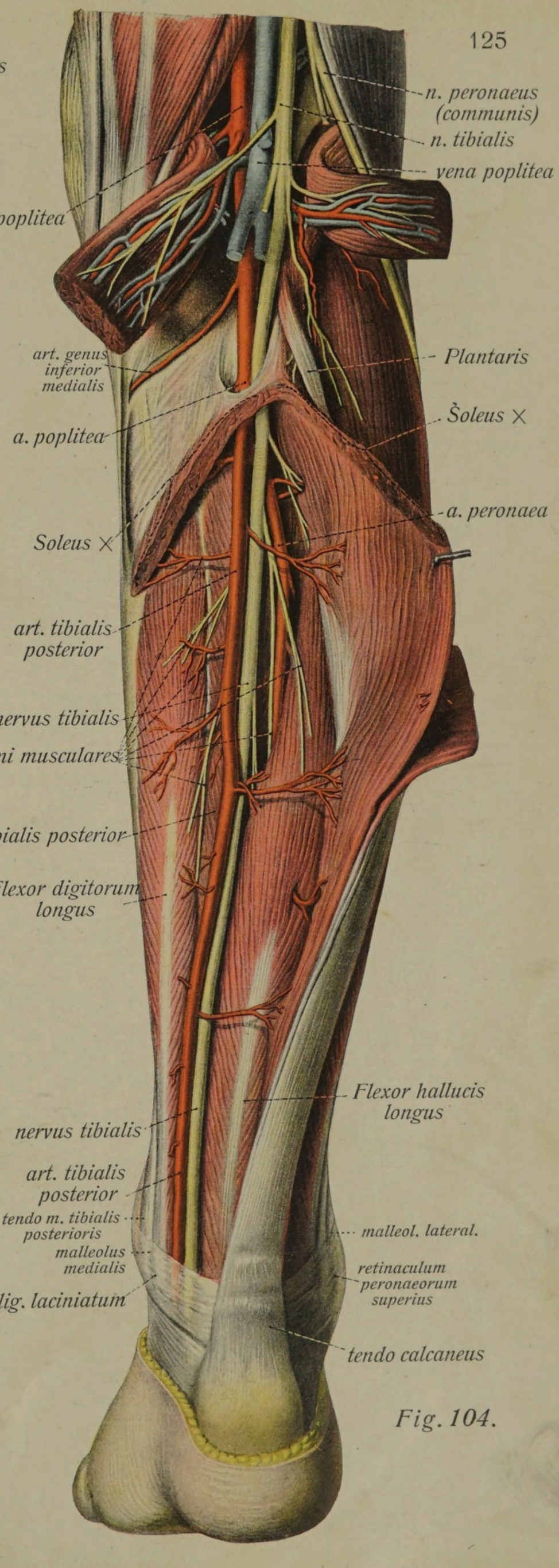

Fig. 104.

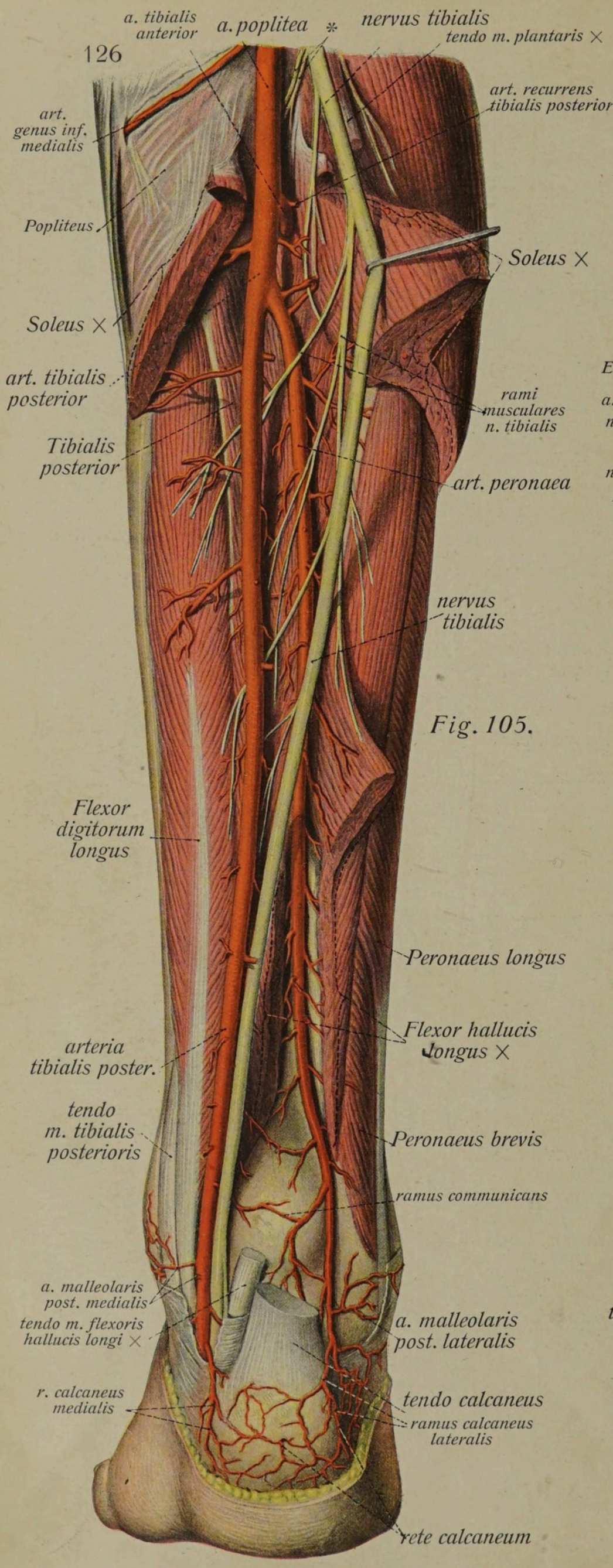

Fig. 105.

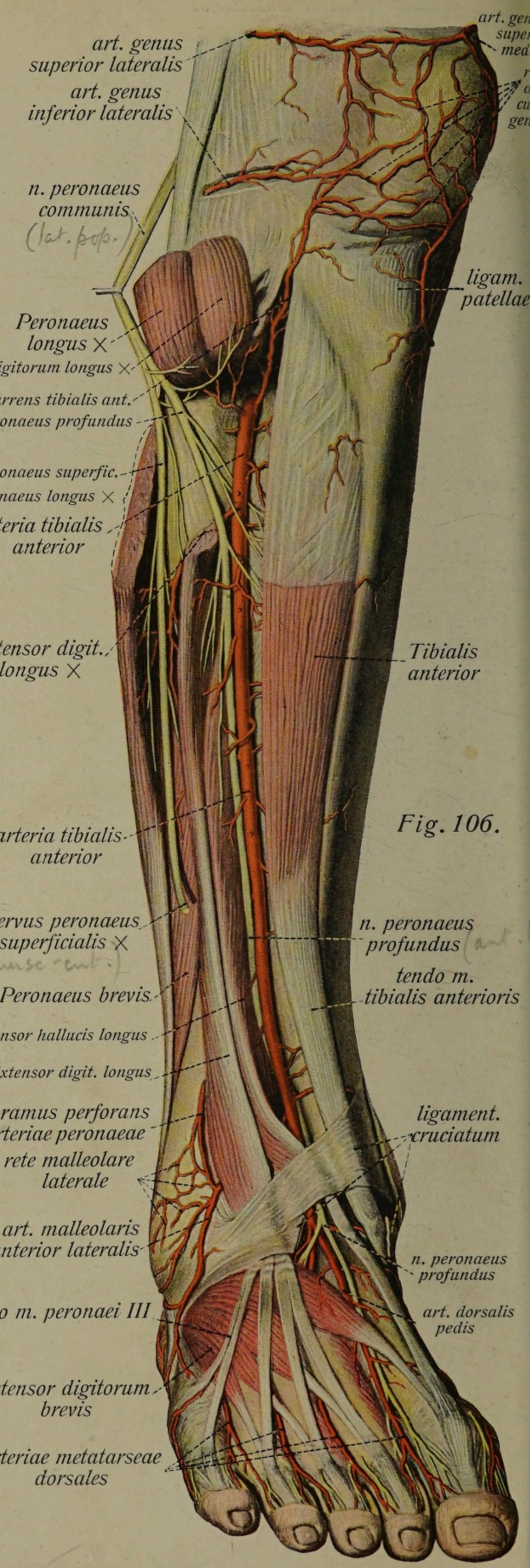

Fig. 106.

The Nerves and Blood Vessels of the Lower Extremity. (Cont.)

Fig. 105. The nerves and blood vessels of the back of the lower leg, deep layer. (1/3)
Preparation as in Fig. 104, except that the popliteal canal is opened and a portion of the lower part of the Flexor hallucis longus is cut out. The tibial nerve is drawn aside. * = muscular branch.

Fig. 106. The nerves and blood vessels of the front of the lower leg and dorsum of the foot. (1/3)
The Peroneus longus and Extensor digitorum longus are cut to show the division of the common peroneal nerve. The Extensor hallucis longus and the peroneal nerve are drawn aside and one limb of the cruciate ligament is removed.

The Anterior Tibial Artery (see p. 120)

immediately after its origin from the popliteal artery passes between the tibia and fibula and runs downwards on the anterior surface of the interosseous membrane. It lies at first between the Tibialis anterior and the Extensor digitorum longus, and, lower down, between the Tibialis and the Extensor hallucis longus, accompanying the deep peroneal nerve. It passes under the cruciate ligament, resting on the bone and the capsule of the ankle joint, and on the dorsum of the foot is known as the dorsal pedal artery (see p. 131). Fig. 105, 106, 110. In addition to muscular branches to the Extensors and in part to the Peronei, it gives off:

1. The *posterior tibial recurrent*, small and inconstant, arising from the artery at its origin or even from the popliteal, ascends to the upper lateral part of the calf and to the rete of the knee. Fig. 105.

2. The *anterior tibial recurrent* arises immediately after the artery has reached the anterior surface of the interosseous membrane. It pierces the origins of the Extensor digitorum longus and the Tibialis anterior, and runs upwards to the rete of the knee. Fig. 106.

3. The *lateral anterior malleolar* passes behind the tendons of the Extensor digitorum longus and the Peronaeus tertius to the lateral malleolar rete. It anastomoses with the perforating branch of the peroneal. Fig. 106, 110.

4. The *medial anterior malleolar* passes behind the tendons of the Extensor hallucis longus and Tibialis anterior to the medial malleolar rete. Fig. 110.

The Common Peroneal Nerve

runs from its origin (see p. 120) along the lateral border of the popliteal fossa, that is to say along the Biceps femoris, to the head of the fibula. It curves forward around this, covered by the origin of the Peronaeus longus, and divides into its terminal branches. Fig. 100, 102, 106, 108. It gives off the following branches:

1. *Muscular* branches to the short head of the Biceps. Fig. 100.

2. The *lateral sural cutaneous* and the *peroneal anastomotic*, see p. 115.

3. The *deep peroneal* (anterior tibial), one of the terminal branches, passes under the origin of the Extensor digitorum longus to the lateral side of the anterior tibial artery, accompanying this to the foot. Fig. 106, 108, 110. In its course it gives branches to the long Extensors, the Peronaeus tertius and the Tibialis anterior. On the foot it divides into two branches. The lateral branch is chiefly motor and goes to the Extensores digitorum and hallucis brevis (also sensory twigs to the ankle joint); the medial branch accompanies the first dorsal metatarsal artery in the interval between the great and second toes, and gives sensory *dorsal digital* branches to the adjacent digital surfaces.

The Nerves and Blood Vessels of the Lower Extremity. (Cont.)

Fig. 107. The arteries of the popliteal fossa. (1/2) The two heads of the Gastrocnemius and the Soleus are cut and a portion of the Biceps and of the Semimembranosus is removed.

Fig. 108. The superficial veins and nerves of the dorsum of the foot. (2/3)
* = anastomosis with the deep veins. ** = terminal branch of the saphenous nerve.

Fig. 109. The nerves and arteries of the second toe, from the side. (1/1)

The Common Peroneal Nerve. (Cont. from p. 127.)

4. The *superficial peroneal (musculo-cutaneous)* runs between the two heads of the Peronaeus longus and passes downwards on the Peronaeus brevis. In the lower third of the lower leg it pierces the fascia over the Extensor digitorum and divides into its terminal branches. Fig. 106, 108. Its branches are:

a) *Muscular* branches for both Peronaei. Fig. 106.

b) The *medial dorsal pedal cutaneous* makes connections with the saphenous nerve and with the sensory terminal branch of the deep peroneal (see p. 115 and 127), and supplies the skin of the medial side of the dorsum of the foot. Fig. 106, 108.

c) The *intermediate dorsal pedal cutaneous* unites with the lateral dorsal cutaneous (see p. 115) and supplies the lateral side of the dorsum of the foot. Fig. 108.

The Arterial Retia of the Lower Limb.

1. The *trochanteric rete* (see p. 123).

2. The *rete of the knee (rete genus)* lies on the anterior and lateral surfaces of the knee joint. The most superficial anastomoses form the *patellar rete*. The following arteries contribute to the rete of the knee: a) from above: 1. the highest artery of the knee from the femoral, 2. the lateral and medial superior arteries of the knee from the popliteal; b) from below: 1. the middle artery of the knee from the popliteal, 2. the lateral and medial inferior arteries of the knee from the popliteal, 3. the anterior tibial recurrent from the anterior tibial, 4. the posterior tibial recurrent from the anterior tibial, 5. the fibular from the posterior tibial. Fig. 95—97, 107.

3. The *lateral malleolar rete* is situated superficially over the lateral malleolus and is formed by the lateral anterior malleolar from the anterior tibial, the lateral posterior malleolar from the peroneal, the perforating of the peroneal and the lateral tarsal from the dorsal pedal. Fig. 106, 110.

4. The *medial malleolar rete* over the medial malleolus is formed by the medial anterior malleolar from the anterior tibial, the medial posterior malleolar from the posterior tibial and the middle tarsals from the dorsal pedal. Fig. 106.

5. The *calcaneal rete* is superficial over the calcaneal tuberosity. It is formed by the lateral calcaneal of the peroneal, the medial calcaneal from the posterior tibial and is also connected by numerous anastomoses with the malleolar retia. Fig. 112, 113.

6. The *dorsal pedal rete* is situated over the proximal tarsal bones and the articular capsules. It is formed by: 1. the arcuate artery (see p. 131), 2. the lateral tarsal, and 3. the medial tarsals. Fig. 110.

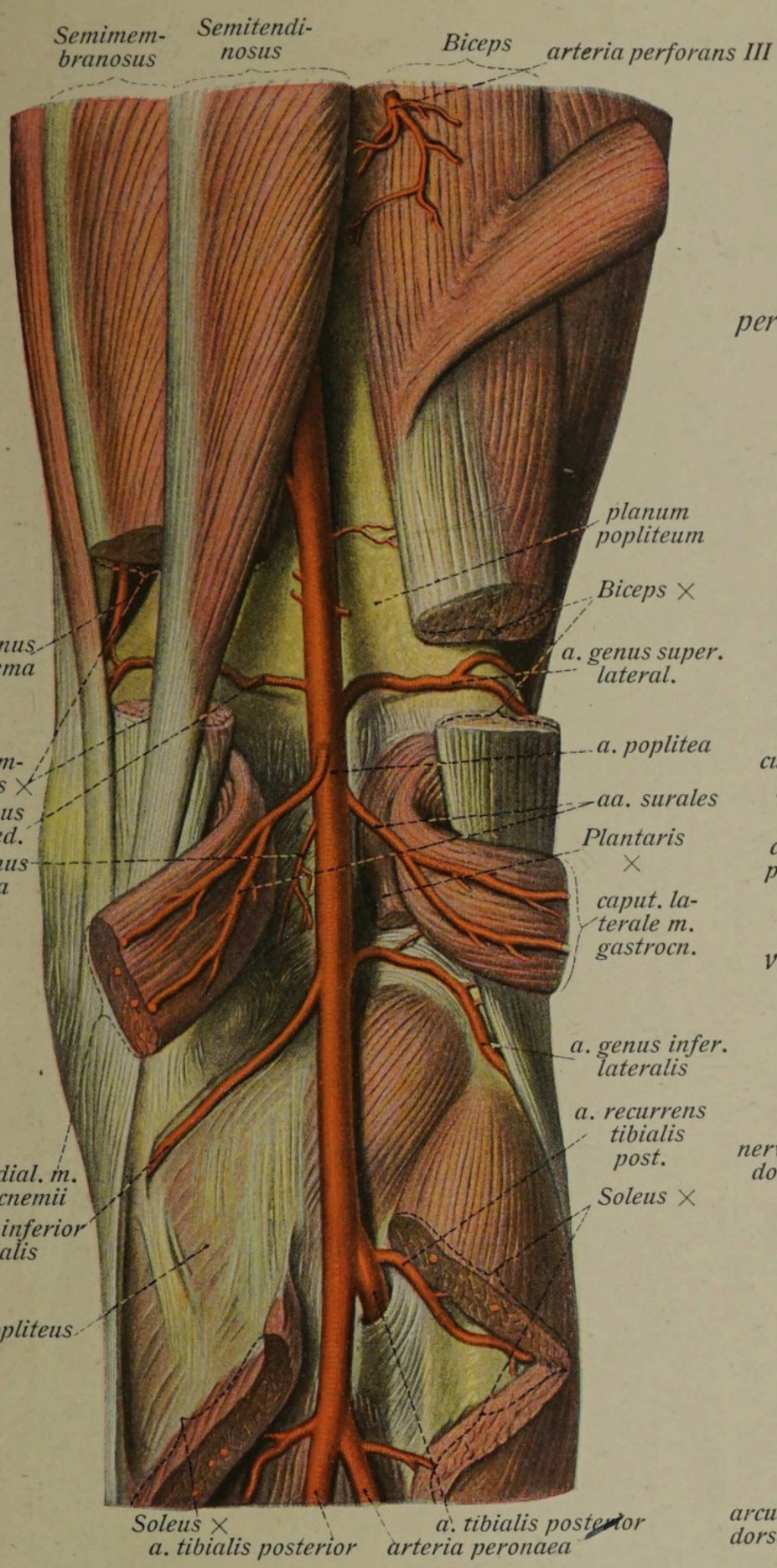

Fig. 107.

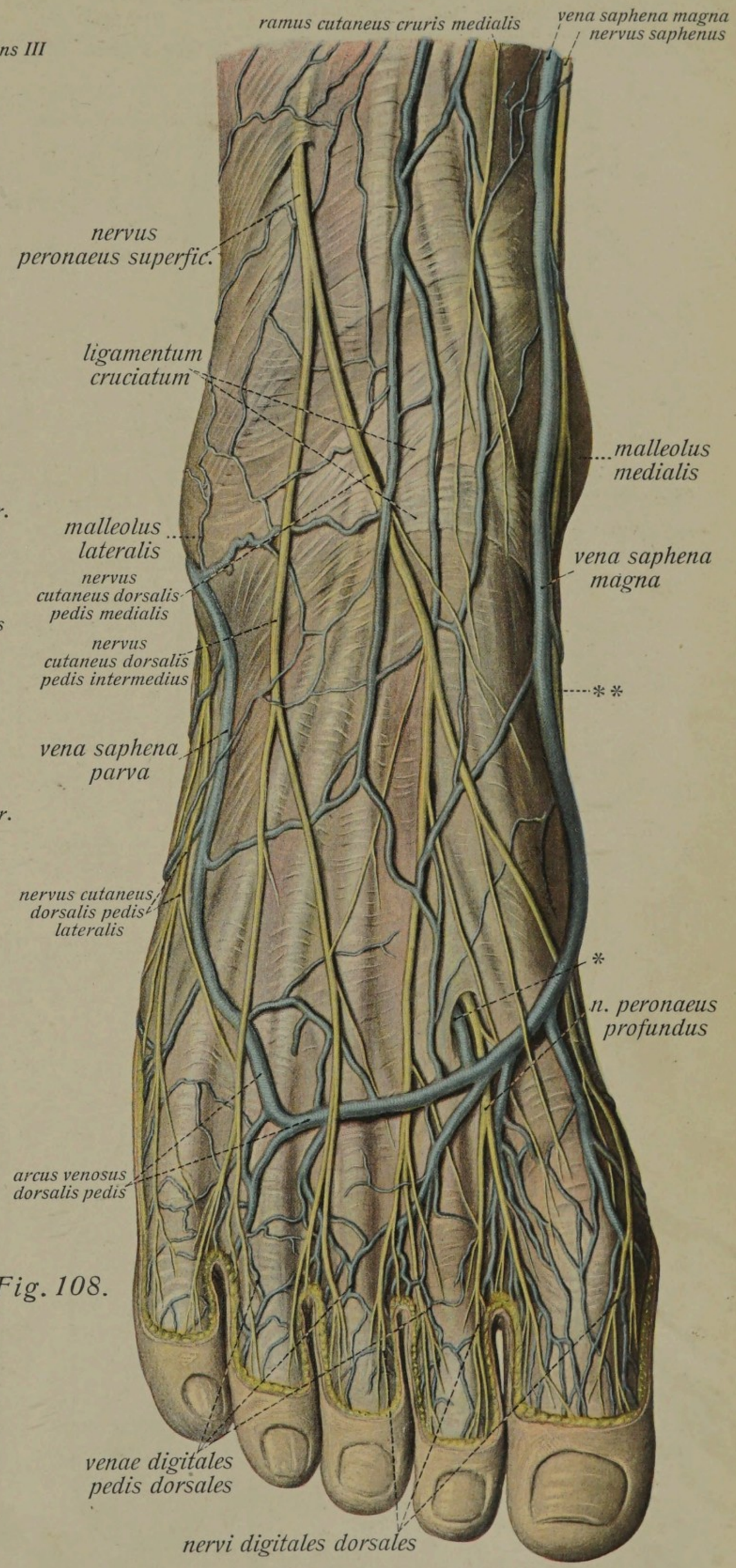

Fig. 108.

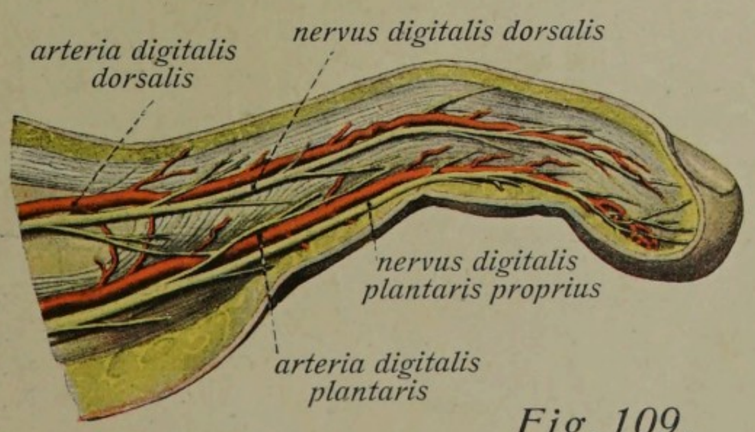

Fig. 109.

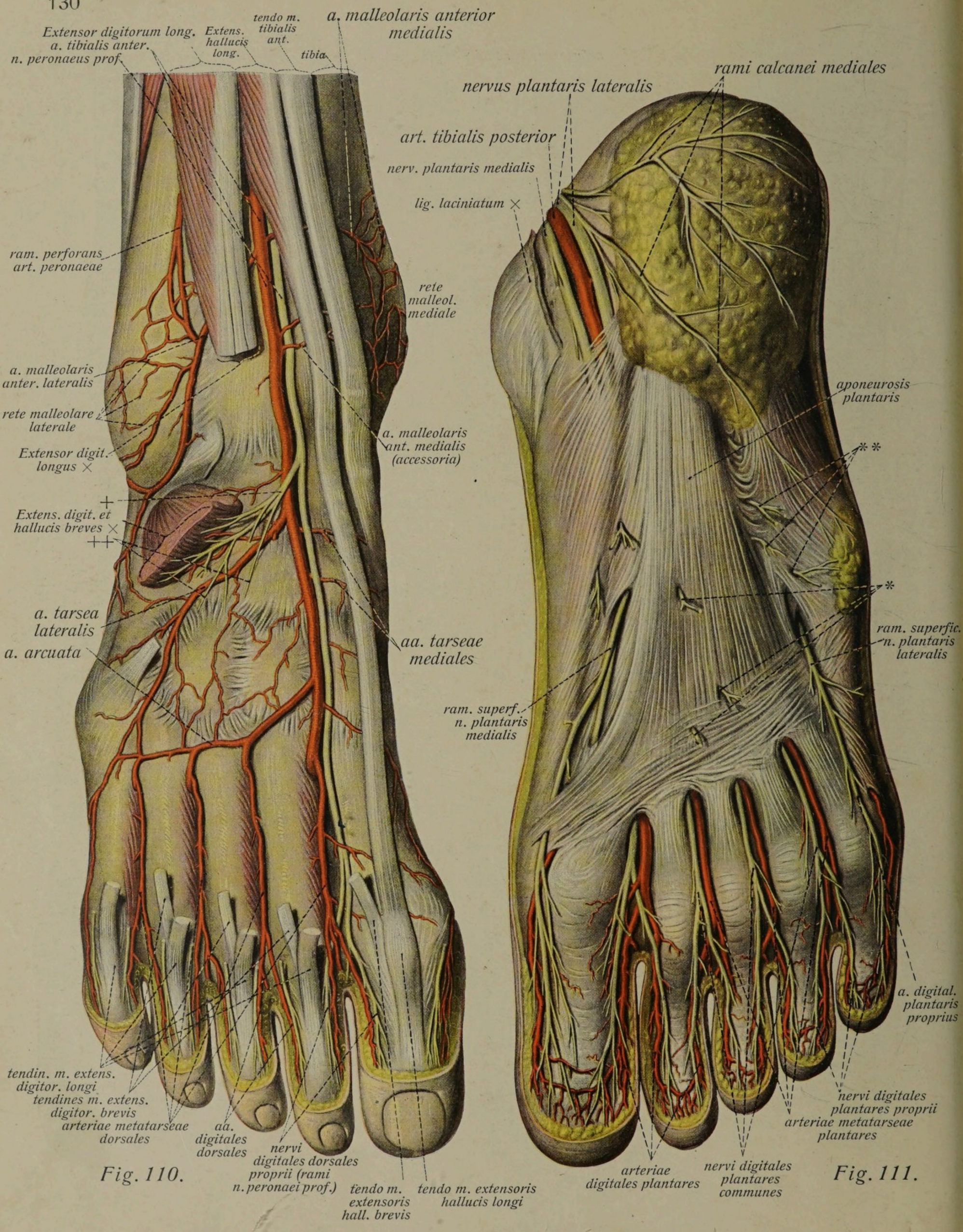
Extensor digitorum long.
a. tibialis anter.
n. peronaeus prof.
Extens. hallucis long.
tendo m. tibialis ant.
tibia
a. malleolaris anterior medialis
ram. perforans art. peronaeae
rete malleol. mediale
a. malleolaris anter. lateralis
rete malleolare laterale
Extensor digit. longus ×
Extens. digit. et hallucis breves ×
a. tarsea lateralis
a. arcuata
a. malleolaris ant. medialis (accessoria)
aa. tarseae mediales
ram. superf. n. plantaris medialis
tendin. m. extens. digitor. longi
tendines m. extens. digitor. brevis
arteriae metatarseae dorsales
aa. digitales dorsales
nervi digitales dorsales proprii (rami n. peronaei prof.)
tendo m. extensoris hall. brevis
tendo m. extensoris hallucis longi
Fig. 110.
rami calcanei mediales
nervus plantaris lateralis
art. tibialis posterior
nerv. plantaris medialis
lig. laciniatum ×
aponeurosis plantaris
ram. superfic. n. plantaris lateralis
a. digital. plantaris proprius
nervi digitales plantares proprii
arteriae metatarseae plantares
arteriae digitales plantares
nervi digitales plantares communes
Fig. 111.

The Nerves and Blood Vessels of the Lower Extremity. (Cont.)

Fig. 110. The nerves and blood vessels of the dorsum of the foot, deep layer. (2/3)
The cruciate ligament is removed and the greater part of the following muscles: Extensor digitorum longus, Extensor digitorum brevis, Extensor hallucis brevis. The superficial nerves are removed down to the toes. + = lateral (motor) terminal branch of the deep peroneal nerve. ++ = articular branches.

Fig. 111. The superficial nerves and arteries of the sole of the foot. (2/3)
The laciniate ligament is divided. * = plantar cutaneous branch of the medial plantar nerve. ** = plantar cutaneous branches of the lateral plantar nerve.

The Dorsal Pedal Artery (see p. 127)

is the direct continuation of the anterior tibial artery. It passes upon the dorsum of the foot between the tendons of the Extensor hallucis longus and the Extensor digitorum longus and, resting on the dorsal surfaces of the tarsal bones, takes a straight course to the first intermetatarsal space. Here it divides into its two terminal branches. Fig. 106, 110. Its branches are:

1. The *lateral tarsal* runs under the Extensor digitorum brevis to the lateral border of the tarsus, where it partly passes to the lateral malleolar rete (see p. 128) and partly to the arcuate artery. Fig. 110.

2. The *medial tarsals* 2—3 weak branches to the medial border of the foot and to the medial malleolar rete (see p. 128).

3. The *arcuate artery* arches across the metatarsal bones, close to the tarso-metatarsal articulations, to the lateral border of the foot. With the preceding it forms the *dorsal pedal rete* and in addition to small muscular branches gives off the *dorsal metatarsals II—IV*, which divide into the dorsal digital arteries. Fig. 106, 110.

4. The *dorsal metatarsal I*, the weaker terminal branch, gives off the three medial dorsal digital arteries. Fig. 110.

5. The *deep plantar*, the stronger terminal branch, passes to the sole of the foot through the first intermetatarsal space, and forms the plantar arch with the deep branch of the lateral plantar. Fig. 110, 113.

The Terminal Branches of the Posterior Tibial Artery.

(See p. 124)

1. The *medial plantar* arises by the division of the posterior tibial artery in the posterior part of the foot, below the sustentaculum tali. At first it is covered by the Abductor hallucis and gives off a *superficial* branch, which passes through the plantar aponeurosis to the skin, and ends as the medial plantar digital artery of the great toe, and a *deep* branch running between the Abductor and the Flexor hallucis in the medial plantar groove, and anastomosing with the first plantar metatarsal. Fig. 111—113.

2. The *lateral plantar* is the stronger terminal branch and runs toward the lateral side of the foot between the Flexor digitorum brevis and the Quadratus plantae. In the lateral plantar groove it gives off a superficial branch, which, after giving off muscular branches, becomes the lateral plantar digital of the little toe, while the main stem passes deeply between the oblique head of the Adductor hallucis and the Interossei to form the plantar arch (see p. 132). Fig. 112, 113.

The Nerves and Blood Vessels of the Lower Extremity. (Cont.)

Fig. 112. The nerves and blood vessels of the sole of the foot, middle layer. (2/3)
The Abductor hallucis is divided and the Flexor brevis digitorum with the plantar aponeurosis is for the most part removed. * = branch to the Flexor digitorum brevis. ** = branch to the Quadratus plantae. *** = cutaneous branch, cut.

Fig. 113. The nerves and blood vessels of the sole of the foot, deep layer. (2/3)
Preparation as in Fig. 112, but the tendon of the Flexor hallucis longus, the Quadratus plantae and the tendons of the Flexor digitorum longus, the oblique head of the Adductor hallucis and the medial plantar nerve are also cut.

The Plantar arch

is formed by the anastomosis of the lateral plantar (see p. 131) with the deep plantar branch of the dorsal pedal. Occasionally the distal end of the medial plantar also takes part in the anastomosis (see p. 131). It is convex forward and lies between the plantar Interossei and the oblique head of the Adductor hallucis. In addition to muscular branches it gives off four *plantar metatarsal* arteries, each of which divides into two plantar digitals. Fig. 113.

The Medial Plantar Nerve

arises below the medial malleolus by the division of the tibial nerve (see p. 124) and, on entering the sole of the foot, lies medial to the terminal part of the posterior tibial artery. It then accompanies the medial plantar artery under cover of the Abductor hallucis, and runs between the Flexor digitorum brevis and the Quadratus plantae toward the toes. Fig. 111—113. In addition to small branches to the skin of the sole it gives off:

1. *Muscular* branches to the Abductor hallucis, Flexor digitorum brevis, Flexor hallucis brevis and a variable number of Lumbricals. Fig. 112, 113.

2. Three *common plantar digitals*, which accompany the plantar metatarsal arteries, pierce the plantar aponeurosis in the interspaces between the four medial toes, and divide into six *proper plantar digitals*. Fig. 112, 113.

3. A *proper plantar digital* for the medial side of the great toe. Fig. 112, 113

The Lateral Plantar Nerve (see p. 124),

the second terminal branch of the tibial nerve in the sole of the foot, accompanies the lateral plantar artery, lying on its medial side, and passes between the Flexor digitorum brevis and the Quadratus plantae. In the lateral plantar groove it divides into its terminal branches. Fig. 112, 113. In addition to small cutaneous branches to the skin of the sole its branches are:

1. *Muscular* branches for the Quadratus plantae, one or more Lumbricals and the Abductor digiti V. Fig. 113.

2. A *superficial* branch, mainly sensory, supplies the skin of the sole by small twigs and gives off the *common plantar digital IV* and the *proper plantar digital* for the lateral side of the little toe. The former divides into two *proper plantar digitals* for the adjacent sides of the fourth and fifth toes. Fig. 112, 113.

3. A *deep* branch, chiefly motor, accompanies the plantar arch and supplies the Flexor and Opponens digiti V. the Adductor hallucis and the Interossei. Fig. 113.

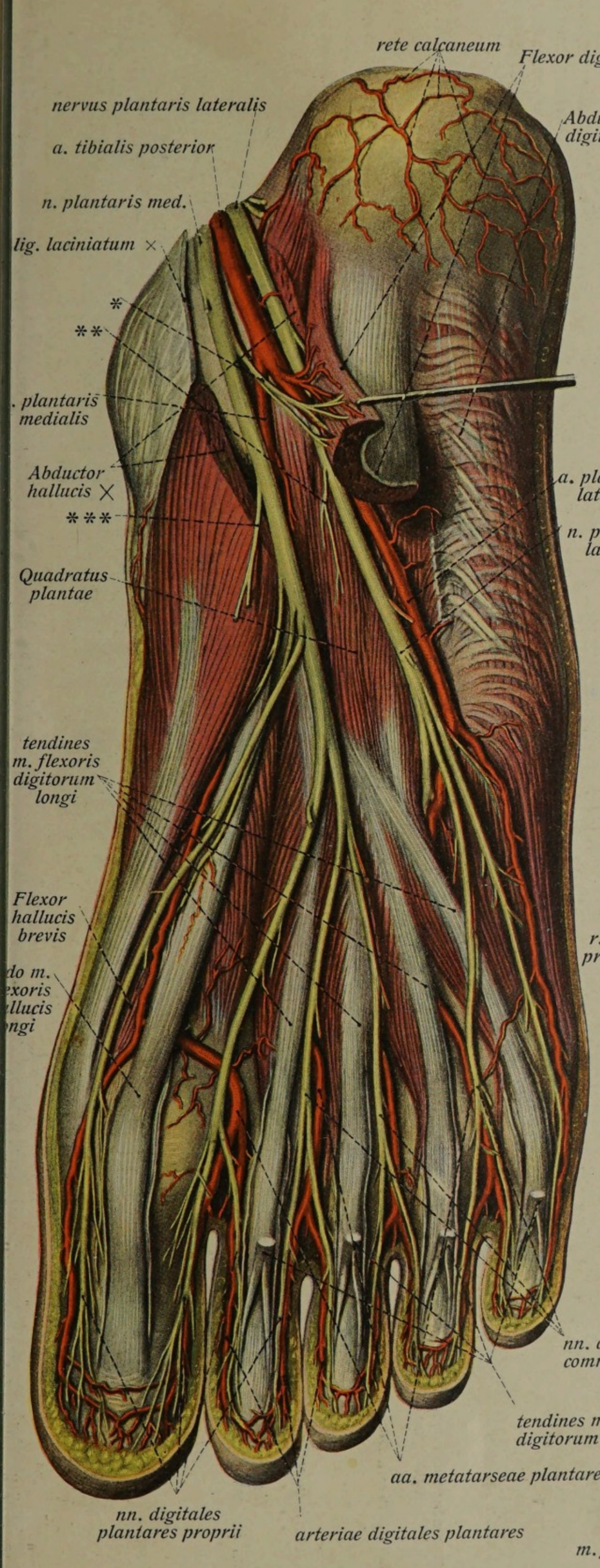

Fig. 112.

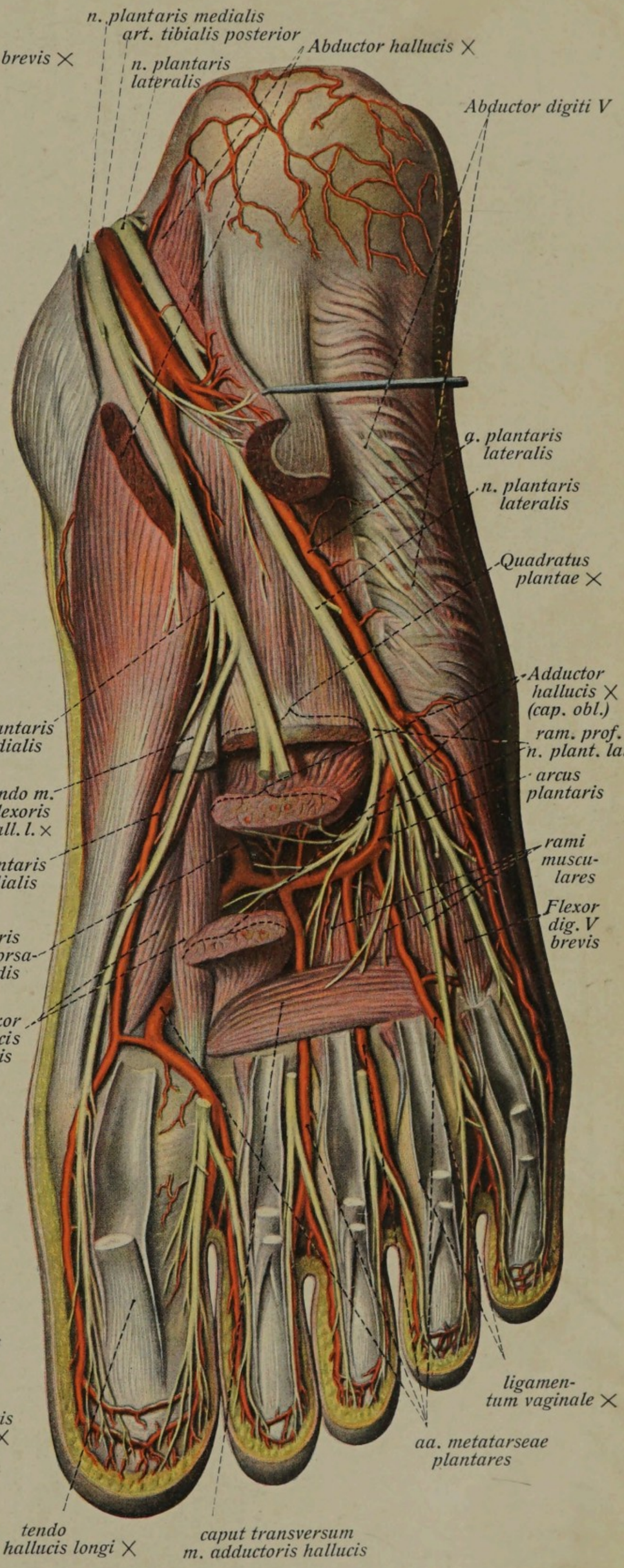

Fig. 113.

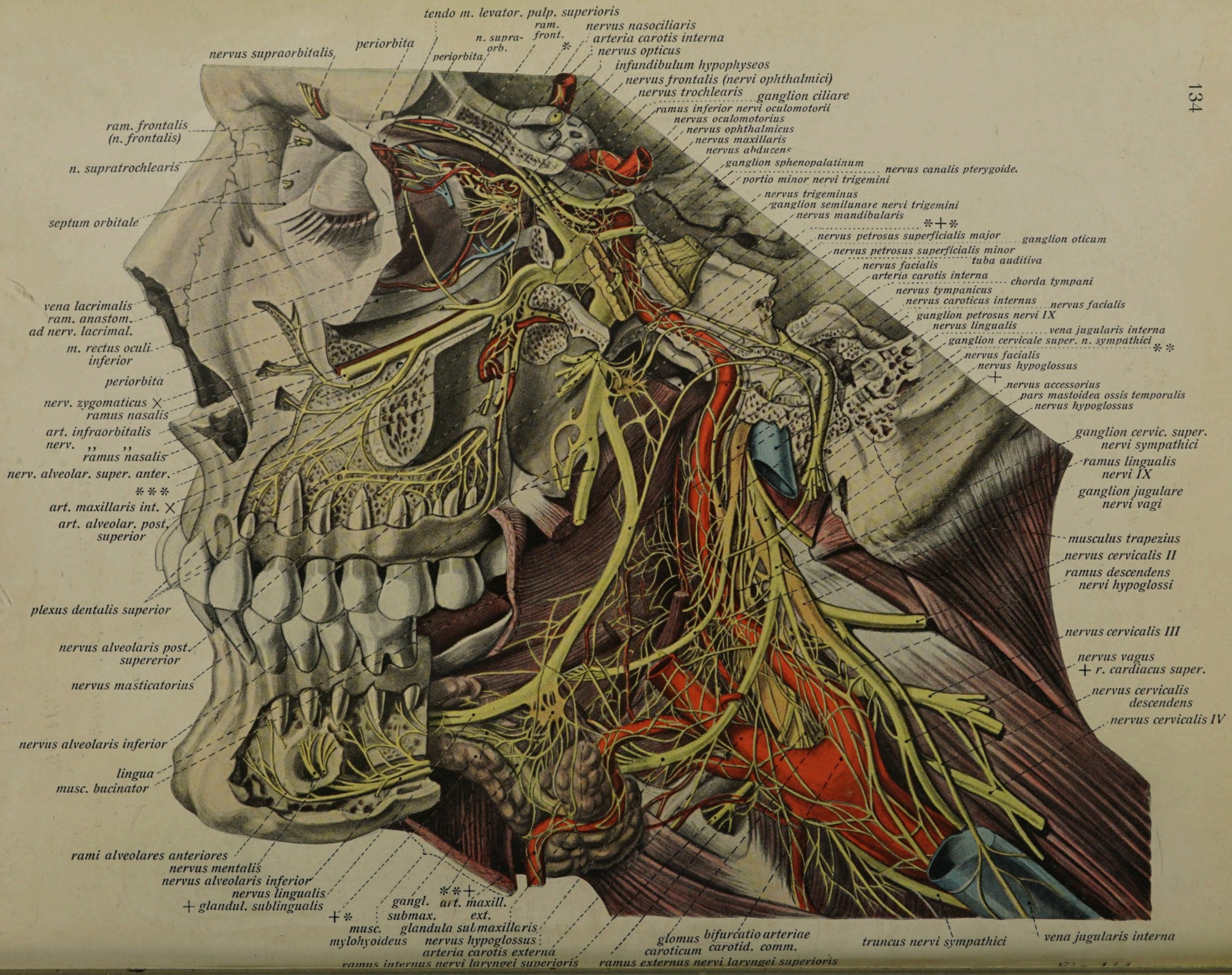

Fig. 114. The cranial portion of the sympathetic nervous system (somewhat enlarged) with some of the cranial and cervical cerebrospinal nerves. (After Braeucker.) The cranial cavity has been opened and the brain removed. The skin and facial musculature is completely removed and the orbit opened from the lateral side; the base of the skull is cut away up to the foramen rotundum and the temporal bone cut along the facial canal. Only the

The Sympathetic Nervous System.

The Sympathetic Nervous System is a second nervous system, largely independent of the cerebrospinal system and differing from it, in addition to many other points, in the lack of a definite central organ, its nerve cells occurring throughout its peripheral distribution, even in the walls of many organs. For the chief distribution of the sympathetic system is to the viscera. It has a paired arrangement, consisting of a cord-like structure, the *sympathetic trunk*, situated on either side of the vertebral column or on either side of the median line in front of the column (and therefore ventral to the spinal cord). Each trunk consists of a series of segmental ganglia, the *ganglia of the sympathetic trunk*, and cord-like *interganglionic rami*, composed essentially of nerve fibers and connecting the individual ganglia. The number of ganglia is always smaller than that of the vertebrae, especially in the cervical region. The trunk extends through the entire length of the vertebral column; it is wanting in the cranial region, but extends to the anterior surface of the coccyx.

The trunk and its ganglia are connected with the spinal nerves by connections (often double) termed *rami communicantes*. They permit an exchange of fibers between the cerebrospinal and sympathetic systems and contain the *praeganglionic fibers*[1]) from the spinal cord. These are less constant and occur less regularly in the cervical than in the thoracic and abdominal portions of the system.

The peripheral plexuses of the system take origin from the sympathetic trunk. Since the system innervates the musculature of the blood-vessels as well as that of the intestine, a part of the peripheral distribution is to these, plexuses, often finely meshed, surrounding the vessels. Only exceptionally do distinct nerves, such as are found in the cerebrospinal system, occur; they have a grey or greyish color.

Cervical, thoracic, abdominal and pelvic portions of the system may be distinguished. The peripheral plexuses in the head region might also be regarded as a cranial portion; they arise, however, from the upper part of the cervical portion of the sympathetic trunk and do not, therefore, constitute an independent portion of the system. Fig. 72, 80, 114—118.

---

[1]) The only direct connections between the two systems.

Fig. 114. The cranial portion of the sympathetic nervous system (somewhat at enlarged) with some of the cranial and cervical cerebrospinal nerves. (After Braeucker.) The cranial cavity has been opened and the brain removed. The skin and facial musculature is completely removed and the orbit opened from the lateral side; the base of the skull is cut away up to the foramen rotundum and the temporal bone cut along the facial canal. Only the anterior part of the mandible is retained; the zygomatic bone and arch, with the muscles of mastication, are removed and also parts of the maxilla. In the orbit, in addition to the nerves to the orbital muscles, branches of trigeminus I are shown and some branches of trigeminus II; of trigeminus III only the lingual nerve is fully retained. In the neck, by the removal of the Sternomastoideus and the internal jugular vein, the glossopharyngeal-vagus and hypoglossal nerves are shown. * = lacrimal artery. ** = palatine nerve. + = anastomotic branch to glossopharyngeal nerve. *+* = part of submaxillary gland above the Mylohyoideus. *+** = wall of carotid canal. **+ = submaxillary duct.

Fig. 115. The lower cervical and upper thoracic portions of the sympathetic nervous system, together with the vagus nerve. (1/1) (After Braeucker.)

In the neck the superficial muscles and the blood-vessels, except the upper part of the common carotid artery, have been removed. The vagus nerve is drawn somewhat forward in order to expose the cervical portion of the sympathetic trunk. In the thorax the wall has been removed up to the vertebral column and the posterior parts of the ribs. The (right) lung is reflected so as to show the oesophagus throughout its whole length; the great vessels are cut away up to the origin of the innominate artery and a part of the superior vena cava.
1 after ansa subclavia indicates its posterior and 2 its anterior limb.

The Cervical Portion.

The cervical portion of the sympathetic trunk possesses as a rule, only three ganglia. It passes downwards behind the common carotid artery, resting on the Longus colli; it itself gives off no branches. The ganglia connect with the cervical nerves by grey rami communicantes.

1. The **superior cervical ganglion** is a large spindle-shaped ganglion, forming the upper end of the sympathetic trunk. It lies medial to the vagus and hypoglossal nerves at the level of the (first) second to the third cervical vertebrae. Fig. 18, 72, 114. It gives off the following branches:

a) Connecting branches to the upper cervical nerves, to the nodose ganglion of the vagus (*jugular nerve)* and to the glossopharyngeal nerve. Fig. 72, 114.

b) The *internal carotid nerve* is the continuation of the sympathetic trunk into the head and accompanies the internal carotid artery through the petrous portion of the temporal bone, forming the *internal carotid plexus* and, during its course through the cavernous sinus, the *cavernous plexus*. It sends the *caroticotympanic nerves* (Fig. 69) to the tympanic plexus, the *deep petrosal nerve* to the spheno-palatine ganglion (see p. 76 and Fig. 114) and *sympathetic roots* to the ciliary ganglion. Fig. 61, 62, 114.

c) The *external carotid plexus* extends along the artery and its branches. The *external maxillary plexus* supplies the *sympathetic root* to the submaxillary ganglion and the *middle meningeal plexus* branches to the otic ganglion. Fig. 114.

d) The *laryngo-pharyngeal branches* run obliquely downwards and medially to the pharyngeal plexus and to the superior laryngeal nerve. Fig. 72, 114.

e) The *superior cardiac nerve* arises from the lower end of the ganglion. It runs beside the trunk, behind the common carotid artery, frequently connected in a plexiform manner with the cardiac branches of the vagus nerve (see p. 139). Fig. 72.

2. The **middle cervical ganglion** is usually small and inconstant. It is situated on the upper surface of the inferior thyreoid artery and gives off the *middle cardiac nerve*, which passes to the cardiac plexus along the subclavian artery. Fig. 72, 115, 117.

3. The **inferior cervical ganglion,** usually much larger than the preceding, lies immediately above the first thoracic ganglion, behind the subclavian artery on the upper border of the neck of the first rib. It gives off the *inferior cardiac nerve* to the cardiac plexus. It has a double connection with the superior thoracic ganglion that lies close below it, a shorter posterior and a longer anterior one forming a sort of sling around the subclavian artery, the *ansa subclavia*. It gives rami communicantes, often relatively long and slender, to the lower cervical nerves. Fig. 115, 117.

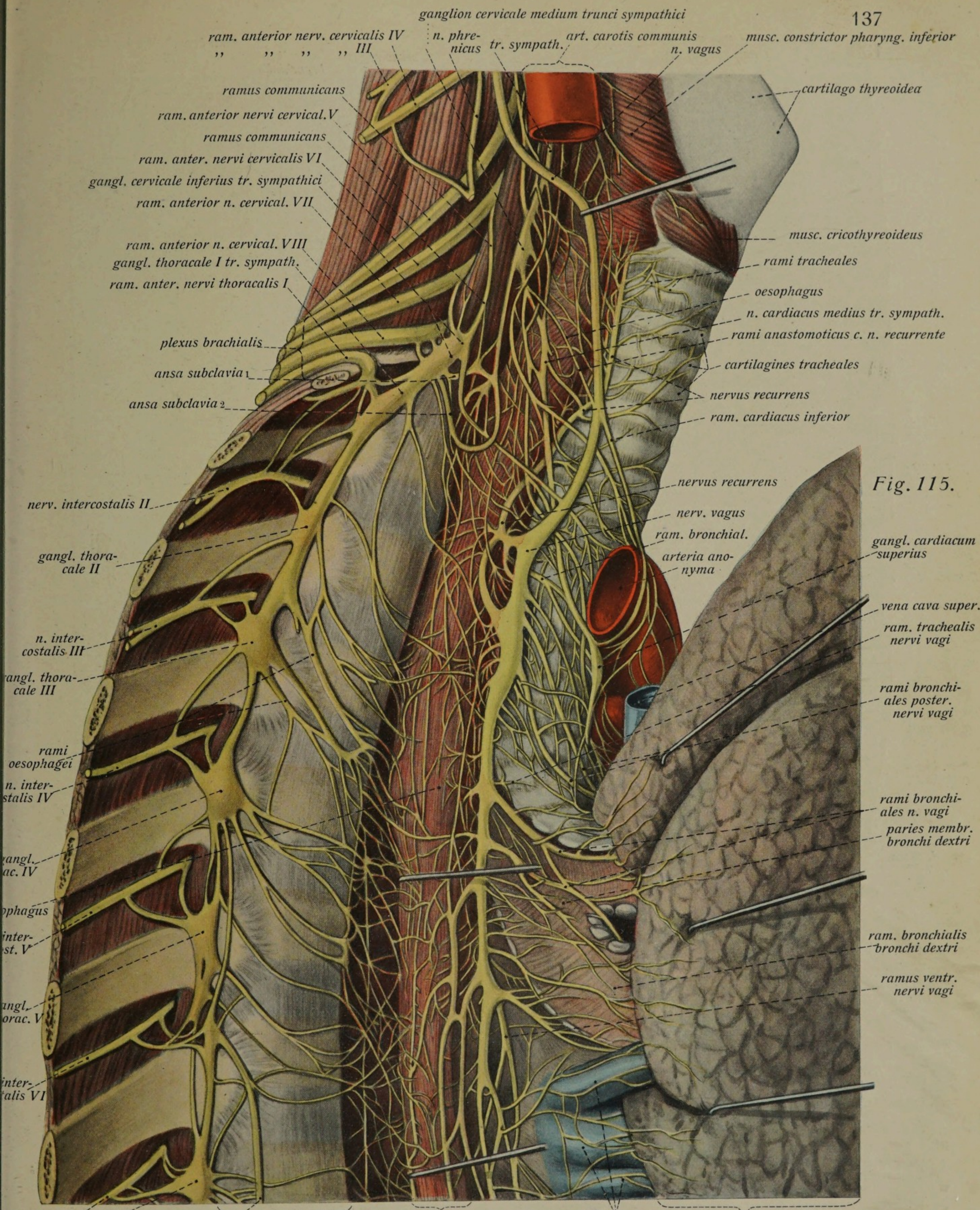
ganglion cervicale medium trunci sympathici
ram. anterior nerv. cervicalis IV
,, ,, ,, ,, III
n. phrenicus
tr. sympath.
art. carotis communis
n. vagus
musc. constrictor pharyng. inferior
cartilago thyreoidea
ramus communicans
ram. anterior nervi cervical. V
ramus communicans
ram. anter. nervi cervicalis VI
gangl. cervicale inferius tr. sympathici
ram. anterior n. cervical. VII
ram. anterior n. cervical. VIII
gangl. thoracale I tr. sympath.
ram. anter. nervi thoracalis I
musc. cricothyreoideus
rami tracheales
oesophagus
n. cardiacus medius tr. sympath.
rami anastomoticus c. n. recurrente
cartilagines tracheales
nervus recurrens
ram. cardiacus inferior
plexus brachialis
ansa subclavia 1
ansa subclavia 2
nervus recurrens
nerv. vagus
ram. bronchial.
arteria anonyma
nerv. intercostalis II
gangl. thoracale II
n. intercostalis III
gangl. thoracale III
rami oesophagei
n. intercostalis IV
gangl. thoracale IV
oesophagus
n. intercostalis V
gangl. thoracale V
n. intercostalis VI
gangl. cardiacum superius
vena cava super.
ram. trachealis nervi vagi
rami bronchiales poster. nervi vagi
rami bronchiales n. vagi
paries membr. bronchi dextri
ram. bronchialis bronchi dextri
ramus ventr. nervi vagi
n. intercostales VII
gangl. thor. VII
n. splanchnicus major (radix. prima)
columna vertebralis
oesophagus
venae pulmonales
pulmo

Fig. 115.

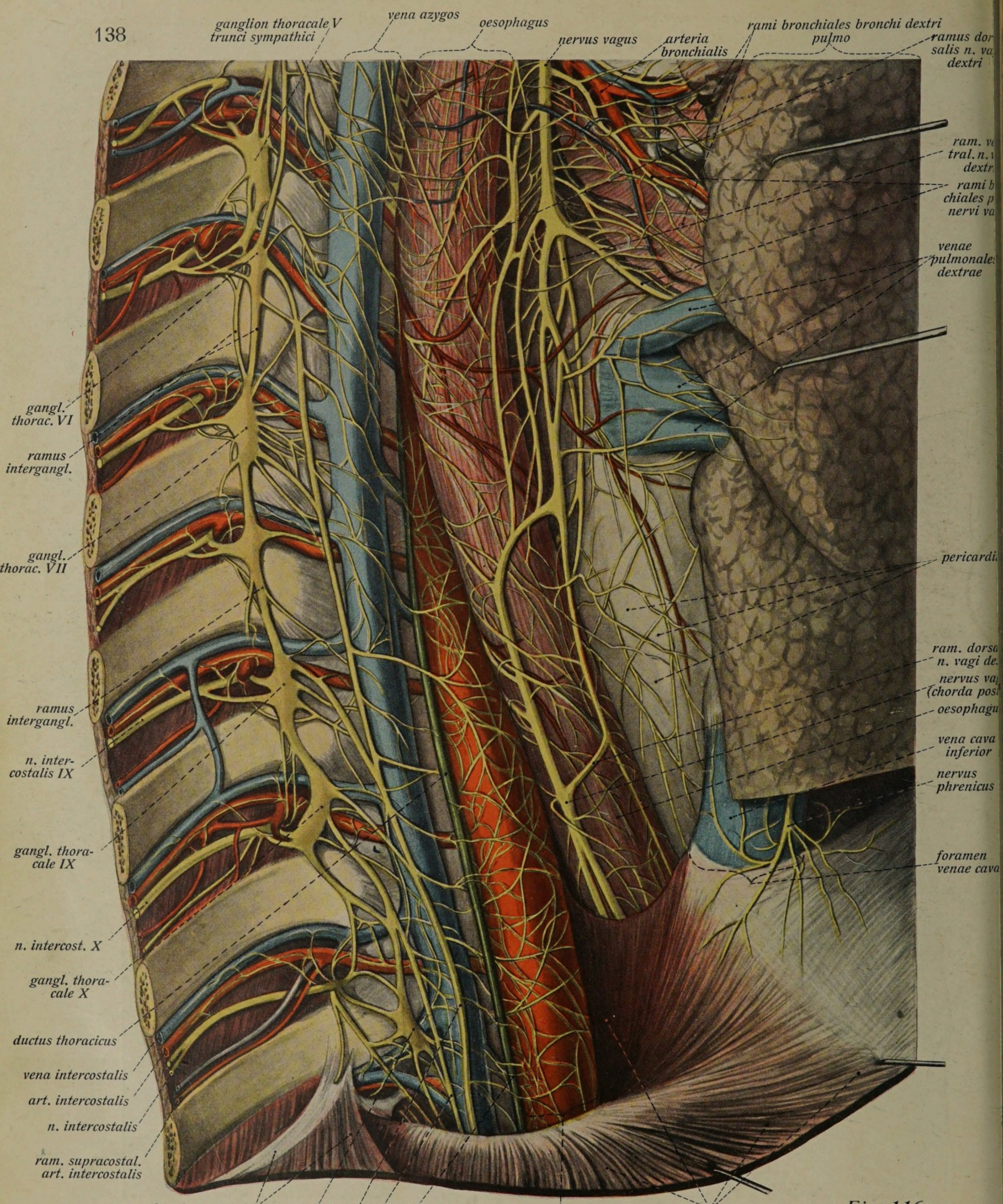
ganglion thoracale V trunci sympathici
vena azygos
oesophagus
nervus vagus
arteria bronchialis
rami bronchiales bronchi dextri
pulmo
ramus dor salis n. va dextri
ram. v tral. n. dextr
rami b chiales p nervi va
venae pulmonale dextrae
gangl. thorac. VI
ramus intergangl.
gangl. thorac. VII
ramus intergangl.
n. inter- costalis IX
gangl. thora- cale IX
n. intercost. X
gangl. thora- cale X
ductus thoracicus
vena intercostalis
art. intercostalis
n. intercostalis
ram. supracostal. art. intercostalis
pericardi
ram. dorsa n. vagi de
nervus va (chorda pos
oesophagu
vena cava inferior
nervus phrenicus
foramen venae cava
Quadratus lumb.
*
nervus splanchnicus major
ductus thoracicus
n. splanchnicus minor
aorta thoracalis descendens
diaphragma

Fig. 116.

The Sympathetic Nervous System. (Cont.)

Fig. 116. The lower thoracic portion of the sympathetic nervous system, together with the vagus nerve. (1/1) (After Braeucker.)

The figure follows immediately on Fig. 115, the preparation differing only in that the vena azygos and the descending thoracic aorta are retained and the thoracic duct (green) is shown. * = thoracic ganglion XI of the sympathetic trunk.

The Thoracic Portion.

In addition to the partly sympathetic cardiac plexus (see p. 84), this consists of 11—12 flattened elongated *thoracic ganglia* lying in front of the heads of the ribs and united by short broad portions of the sympathetic trunk. The upper and lower ganglia are the largest. They are united with the thoracic nerves by rami communicantes, which are frequently double, and send out numerous twigs of variable strength to the descending thoracic aorta, the oesophagus, the pericardium and other structures (vessels, etc.) of the mediastinum; these are termed *mediastinal rami*. Those passing to the oesophagus make plentiful anastomoses with the thoracic portion of the vagus nerve. Some mediastinal rami also take origin from the splanchnic nerves (see below).

The most important branches of the thoracic portion of the sympathetic trunk are the *splanchnic nerves*, two long and strong nerves, similar to those of the cerebrospinal system. They consist of a distinctly stronger upper and a weaker lower nerve and they pass to the abdominal cavity. Fig. 18, 22, 115—118.

1. The *great splanchnic nerve* arises by a variable number of roots, usually from the 5th and 6th to the 9th (10th) thoracic ganglion, and runs medially and downwards over the lateral and anterior surfaces of the lower thoracic vertebrae. It passes through the diaphragm between the medial and intermediate crura of the lumbar portion to the coeliac ganglion, situated in the abdominal cavity (see below).

2. The *lesser splanchnic nerve* arises from the lower two thoracic ganglia and runs parallel and lateral to the great splanchnic. It pierces the lateral part of the lumbar portion of the diaphragm and goes mainly to the renal plexus. Fig. 18, 22, 116—118.

The Abdominal and Pelvic Portions

consist of 4—5 *lumbar ganglia*, 4 (or 5) *sacral ganglia* and the *coccygeal ganglion*, and furthermore of the great plexuses of the abdomen and pelvis.

1. The *lumbar ganglia* lie, with the connecting trunk, on the medial border of the Psoas and the lateral part of the anterior surfaces of the bodies of the lumbar vertebrae. They are smaller than the lower thoracic ganglia and are connected with the ganglia of the opposite trunk by transverse branches, that pass behind the aorta and inferior vena cava, and, further, by rami communicantes, with the lumbar nerves and the hypogastric plexus. Fig. 18, 80, 118.

2. The *sacral ganglia* converge and diminish in size downwards and lie on the pelvic surface of the sacrum. They give communicating branches to the sacral nerves, to the hypogastric plexus and the pelvic plexuses and are connected with those of the other side by transverse branches. Fig. 118.

3. The *coccygeal ganglion*, small and unpaired, is situated on the coccyx and is the end of the trunks. It is very variable in position and size. Fig. 118.

The Sympathetic Nervous System. (Cont.)

Fig. 117. The thoracic portion of the sympathetic trunk and the thoracic and abdominal portions of the vagus nerves. (1/3)

The anterior thoracic wall is removed by a frontal section; the veins are excised and of the arteries only the aorta and some of its branches are retained. The thoracic viscera up to the main bronchi and the abdominal viscera, except the stomach, have been removed.

The abdominal and pelvic sympathetic plexuses.

(Continued from page 139)

1. The *coeliac plexus*, unpaired, the largest sympathetic plexus in the body, lies on the anterior wall of the abdominal aorta, surrounding the origin of the coeliac artery and extending laterally upon the lumbar portions of the diaphragm. It consists principally of the paired semilunar *coeliac ganglia*, which receive the great splanchnic nerves, and of the *superior mesenteric ganglion*, situated behind the origin of the superior mesenteric artery. Fig. 118.

2. The *renal plexus*, paired, connected with the preceding by numerous branches and receiving the lesser splanchnic nerves. It lies along the renal artery and passes with this to the kidney, sending a prolongation *(suprarenal plexus)* to the suprarenal bodies. Fig. 118.

3. The *superior mesenteric plexus* passes out from the lower part of the coeliac plexus along the superior mesenteric artery. Fig. 118.

4. The *inferior mesenteric plexus* along the artery of the same name and its branches to the large intestine and rectum. Fig. 118.

5. The *hypogastric plexus*, connected with the preceding at its origin, passes from the bifurcation of the aorta downwards over the last lumbar vertebra and the promontory into the pelvis, to form there the paired visceral plexuses *(middle haemorrhoidal, prostatic, utero-vaginal, vesical*, etc.). Fig. 118.

6. The *spermatic plexus* (internus), paired and weak, along the internal spermatic artery to the ovary or testis. Fig. 118.

The thoracic portion of the Vagus Nerve. (See p. 84)

The vagus nerve passes through the upper thoracic aperture into the thoracic cavity, where it lies at first, as in the neck, along the common carotid artery on each side (on the right eventually along the innominate artery). The first strong branch given off in its course through the thoracic cavity is the *recurrent nerve* (see p. 84). Since on the left this curves around the aortic arch and on the right around the right subclavian artery, its origin is much deeper on the left than on the right.

The vagus stem on each side now approaches the hilus of the lung, into which it sends numerous strong twigs, which pass along the larger bronchi and so reach the substance of the lung along with bronchial sympathetic rami. Much finer but more numerous twigs from both vagi supply the middle part of the thoracic portion of the oesophagus, again with extensive anastomoses with the mediastinal rami of the sympathetic system. Below the level of the hilus of the lung the vagus ceases as a distinct stem, breaking up into anastomosing cords, the *chordae oesophageae*, which form a network on the wall of the oesophagus, supplying it and passing with it through the diaphragm. The anterior chorda is formed principally from the left vagus stem and the posterior chorda mainly from the right. In the abdominal cavity the identity of the two stems is preserved only in the innervation of the stomach, and there only approximately; then the vagus fibers so mingle with those of the sympathetic nerves that an anatomical separation of them is impossible.

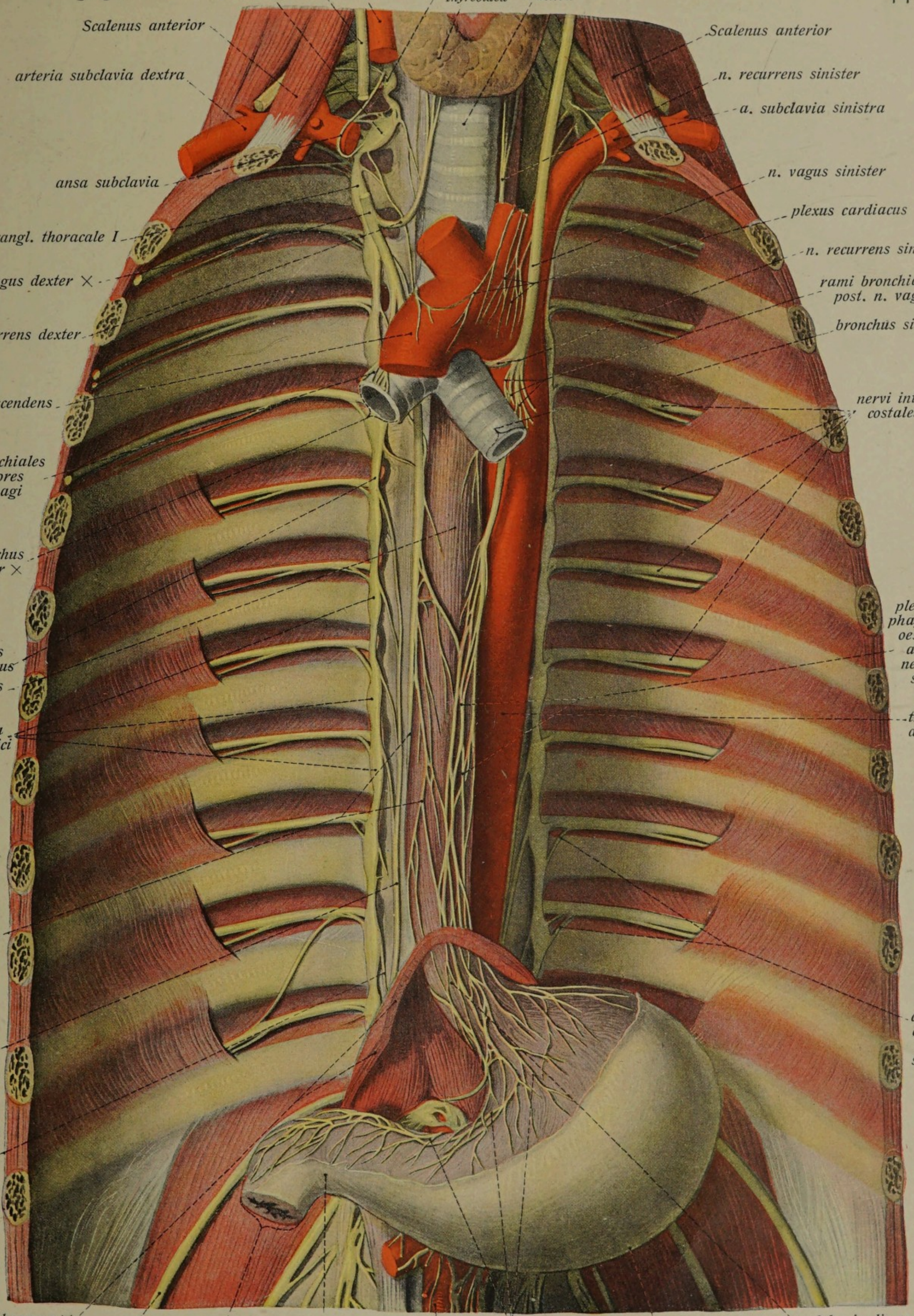
nervus vagus dext. ×
a. carotis communis ×
ganglion cervicale medium
ganglion cervicale inferius
glandula thyreoidea
trachea
Scalenus anterior
arteria subclavia dextra
ansa subclavia
gangl. thoracale I
n. vagus dexter ×
n. recurrens dexter
aorta ascendens
ami bronchiales posteriores nervi vagi
bronchus dexter ×
truncus sympathicus
esophagus
ganglia thoracalia sympathici
orda sophagea osterior rvi vagi dextri
splanch- us major
splanch- s minor
Diaphragma ×
n. intercostalis XII
duodenum ×
pylorus
aorta abdominalis
plexus gastricus anterior n. vagi
ventriculus
pars abdominalis oesophagi
Scalenus anterior
n. recurrens sinister
a. subclavia sinistra
n. vagus sinister
plexus cardiacus
n. recurrens sinister
rami bronchiales post. n. vagi
bronchus sinister ×
nervi inter- costales
plexus oeso- phageus (chorda oesophagea anterior) nervi vagi sinistri
aorta thoracalis descendens
rami communi- cantes nervi sympath.

Fig. 117.

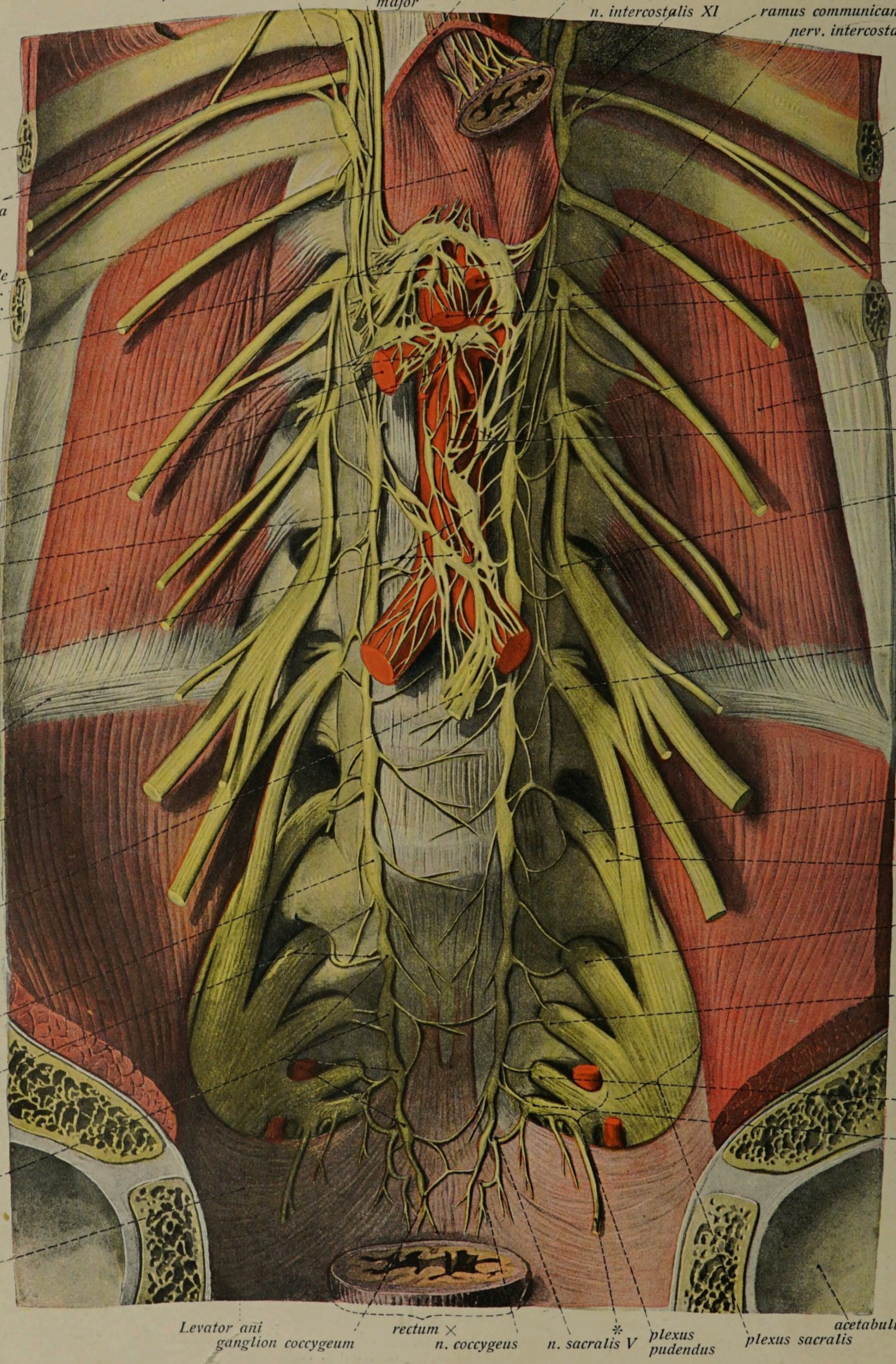
nervus splanchnicus minor
n. splanchnicus major
Diaphragma × cardia × + pars abdomin. oesophagi (+ nn. vagi)
n. intercostalis XI
ramus communicans
nerv. intercostalis XII
costa XI ×
ganglia thoracalia
crus mediale part. lumb. Diaphragm.
costa XII ×
ganglia coeliaca (plexus coeliacus)
plexus renalis
arteria renalis ×
ganglion mesentericum superius
truncus sympathicus
Quadratus lumborum
plexus mesentericus inferior
crista iliaca
Iliacus
plexus hypogastricus ×
ganglion lumbale
rami communicantes
ganglia sacralia
Coccygeus
costa XI ×
a. coeliaca ×
n. lumbalis I
a. mesenteric superior ×
nerv. lumbalis II
Quadratus lumborum
plexus aortic abdominalis
n. lumbalis III (ram. anterio
n. lumbalis IV (ram. anterior)
nervus lumbalis V
truncus lumbo-sacralis
nervus sacralis I (ram. anterior
nervus sacralis II (ram. anterior
nervus sacralis III
nervus sacralis IV (ram. anterior)
Levator ani
ganglion coccygeum
rectum ×
n. coccygeus
n. sacralis V
plexus pudendus
plexus sacralis
acetabulum

Fig. 118.

The Sympathetic Nervous System.

Fig. 118. The abdominal and pelvic portions of the sympathetic trunk. (2/3)
The anterior abdominal and pelvic walls have been cut away and the lumbar plexus exposed by removing the Psoas major; the aorta is retained as far as its bifurcation.
* = visceral branches of the pudendal plexus.

The Central Nervous System.

This consists of two portions, very different in form; the brain (*encephalon*), more or less spherical and contained in the cranial cavity, and the spinal cord (*medulla spinalis*), cylindrical in form and contained within the vertebral canal.

The Spinal Cord.

The spinal cord is almost cylindrical and begins in the region of the decussation of the pyramids, where it is directly continuous with the medulla oblongata. It traverses the vertebral canal to the level of the first lumbar vertebra, giving origin to the roots of the spinal nerves, 8 cervical, 12 thoracic, 5 lumbar, 5 sacral and the coccygeal. In the cervical region it shows a *cervical enlargement* and in the lumbar region a *lumbar enlargement*, being much smaller and distinctly cylindrical in the interval between these. The lower end of the lumbar enlargement tapers to a short cone, the *conus medullaris*, from which a long slender filament, the *filum terminale*, extends to the end of the sacral canal; it, however, does not contain any nerve tissue. Throughout all the cervical region and in the lumbar enlargement the transverse section of the cord is transversely elliptical. A small, but deep median groove, the *anterior median fissure*, traverses the entire length of the anterior surface, and, corresponding to this, on the posterior surface is a shallow groove, the *posterior median sulcus*. On either side are two other grooves, the *anterior* and *posterior lateral sulci*, formed by the attachments of the roots of the spinal nerves. In the cervical region there is, in addition, a *posterior intermediate sulcus* between the posterior median and posterior lateral sulci. Fig. 120—129.

The portion of the spinal cord on either side between the anterior median fissure and the anterior lateral sulcus is termed the *anterior funiculus*, that between the anterior and posterior lateral sulci the *lateral funiculus*, and that between the posterior lateral and median sulci (and the *posterior median septum* which continues the sulcus into the substance of the cord) is the *posterior funiculus*. In the cervical region especially the last is divided by the posterior intermediate sulcus (and the septum that continues it) into two portions, the medial *fasciculus gracilis* (*column of Goll*) and the lateral *fasciculus cuneatus* (*column of Burdach*). The division of the anterior and lateral funiculi into different fasciculi is not evident on the surface of the cord, but the fibres forming the anterior funiculus may be divided into the *anterior fasciculus proprius (ground bundle)* and a small group of fibres bounding the anterior median fissure, the *anterior cerebro-spinal fasciculus (direct pyramidal tract)*. The lateral funiculus is composed of the *lateral cerebro-spinal fasciculus (crossed pyramidal tract)*, the *cerebello-spinal fasciculus (lateral cerebellar tract)*, the *superficial anterolateral fasciculus (Gower's tract)* and the *lateral fasciculus proprius (ground bundle)*. (See Fig. 125, 126.)

The Central Nervous System. (Cont.)

The Spinal Cord. (Cont.)

Fig. 119. The entire central nervous system of a newborn child. (3/4)
Viewed from behind. The skin and dorsal muscles have been removed; the vertebral arches have been cut away and also the greater part of the vault of the skull. The membranes of the brain and cord have been removed.

The grey substance of the spinal cord is in the interior and consists of two symmetrical portions connected by a small bridge of grey matter, in which is the *central canal*. In front of the canal is an *anterior grey commissure* and behind it a *posterior grey commissure*; the former is separated from the floor of the anterior median fissure by a small bundle of crossed fibres, the *anterior white commissure*. Each half of the grey substance has a large anterior enlargement, the *anterior column (horn)*, and a more slender *posterior column (horn)*, the apex of the latter extending to the surface of the cord. In some parts of the spinal cord there is a lateral projection, the *lateral column (horn)* which, as the *reticular formation*, gradually passes into the white substance. Fig. 131—134.

The **spinal nerves** that arise from the cord possess motor *anterior roots* and sensory *posterior roots*. The root filaments *(fila radicularia)* of the anterior roots arise in the anterior column and, separating the anterior and lateral funiculi, come to the surface in the anterior lateral sulcus. The posterior roots arise from the *spinal ganglia*, situated lateral to the spinal cord, and pass into the cord along the posterior lateral sulcus. Lateral to the ganglia the two roots unite to form a mixed *spinal nerve*, which promptly divides into a weak *posterior* and a stronger *anterior ramus*. The middle and lower spinal nerves leave the cord very obliquely in order to reach their respective intervertebral foramina. Consequently in the lower part of the cord, where the lumbar and sacral nerves arise in immediate succession, there is formed a thick mass of almost parallel nerve stems, the so-called *cauda equina*, in the centre of which is the filum terminale. Fig. 127—130.

The Spinal Meninges.

The spinal cord is enclosed within the same membranes as the brain (see p. 152), but the *spinal dura mater* differs from the cerebral in that it is not fused with the periosteum, but is separated from it by fat tissue and venous plexuses; it also encloses the cauda equina in the sacral canal. The *arachnoid* lies on the inner surface of the dura mater, separated from it by the slit-like *subdural cavity*. The *pia mater*, on the other hand, lies directly upon the surface of the spinal cord, conveys blood vessels to it and sends septa into its substance; in the anterior median fissure it forms a duplicature. It reaches to the end of the cauda equina. In the intervals between successive nerve roots it sends, in the frontal direction, prolongations to the inner surface of the arachnoid, the *denticulate ligament*; this is wanting between the closely associated nerve roots of the cauda equina. In addition, finer strands and plates of connective tissue unite the pia mater and arachnoid, traversing the *subarachnoid cavity* and the cerebro-spinal fluid that it contains; in the middle portion of the cord these fibrous bands thicken in the region of the posterior medial sulcus to form the *subarachnoid septum*. Fig. 120—122, 124, 130.

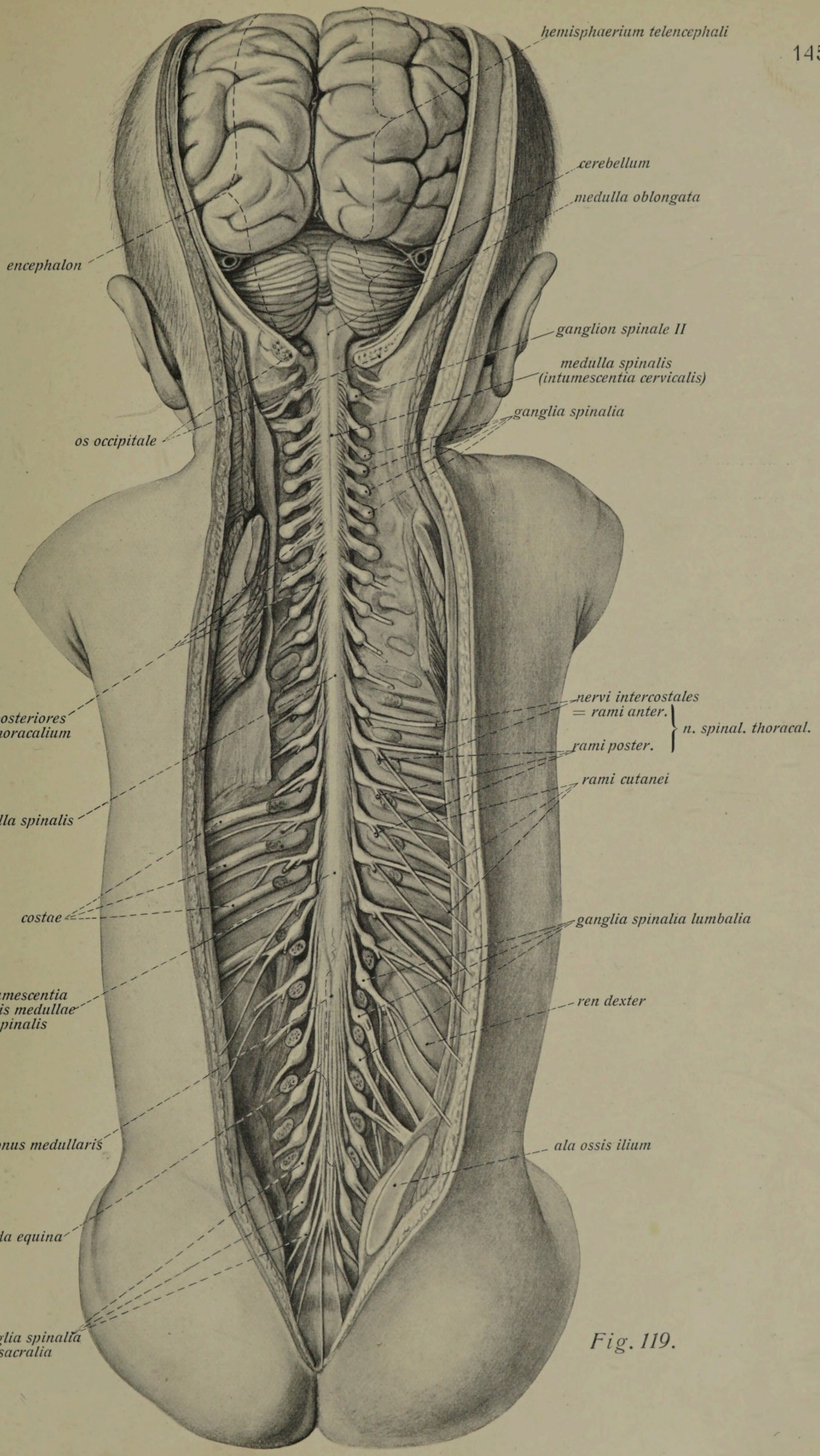
hemisphaerium telencephali
cerebellum
medulla oblongata
encephalon
ganglion spinale II
medulla spinalis
(intumescentia cervicalis)
ganglia spinalia
os occipitale
radices posteriores
nervorum thoracalium
nervi intercostales
= rami anter.
rami poster.
n. spinal. thoracal.
rami cutanei
medulla spinalis
costae
ganglia spinalia lumbalia
intumescentia
lumbalis medullae
spinalis
ren dexter
conus medullaris
ala ossis ilium
cauda equina
ganglia spinalia
sacralia

Fig. 119.

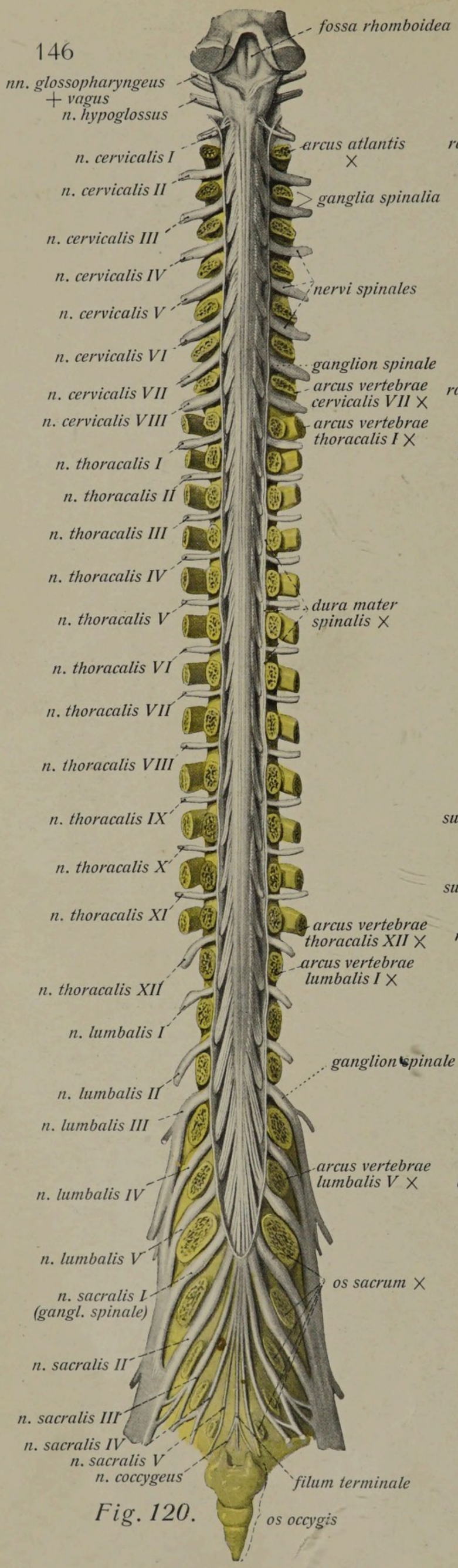

Fig. 120.

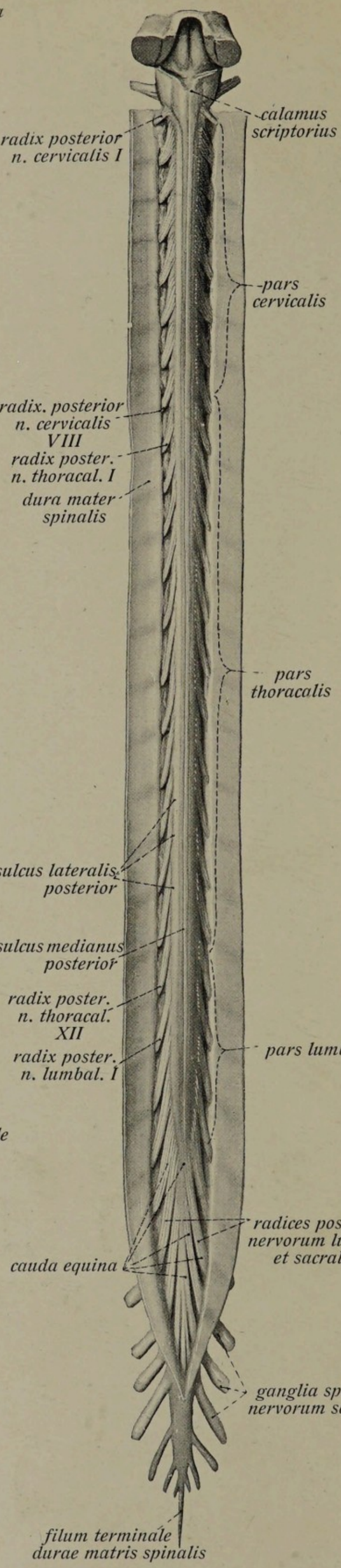

Fig. 121.

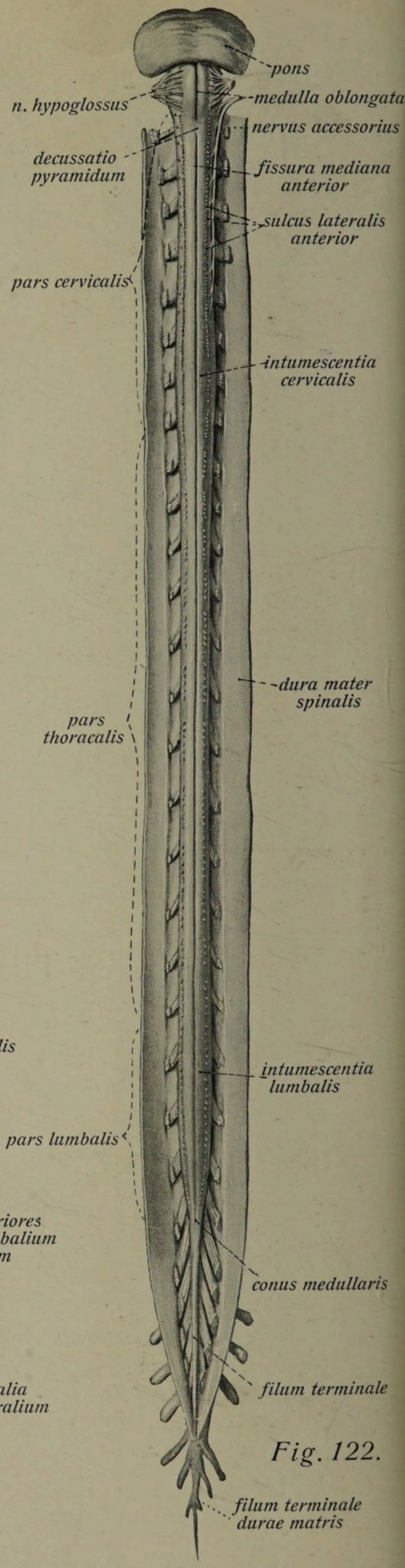

Fig. 122.

The Spinal Cord. (Cont.)

Fig. 120. The spinal cord in the vertebral canal, the vertebral arches and the dura mater being removed. (1/4)

Fig. 121. The spinal cord and the nerve roots from behind. (1/4)
The dura mater is opened.

Fig. 122. The spinal cord from in front. (1/4)
The anterior roots are cut close to their origin from the cord.

Fig. 123. Schema of the principal fibre tracts in the spinal cord.
Motor cells and fibres red; posterior roots with collaterals and posterior funicular fibres blue; tract cells black. The arrows indicate the direction of the tracts.

Fig. 124. Schema of the spinal meninges.
The dura mater blue, arachnoid and pia mater red. The spinal cord and nerve roots are schematic.

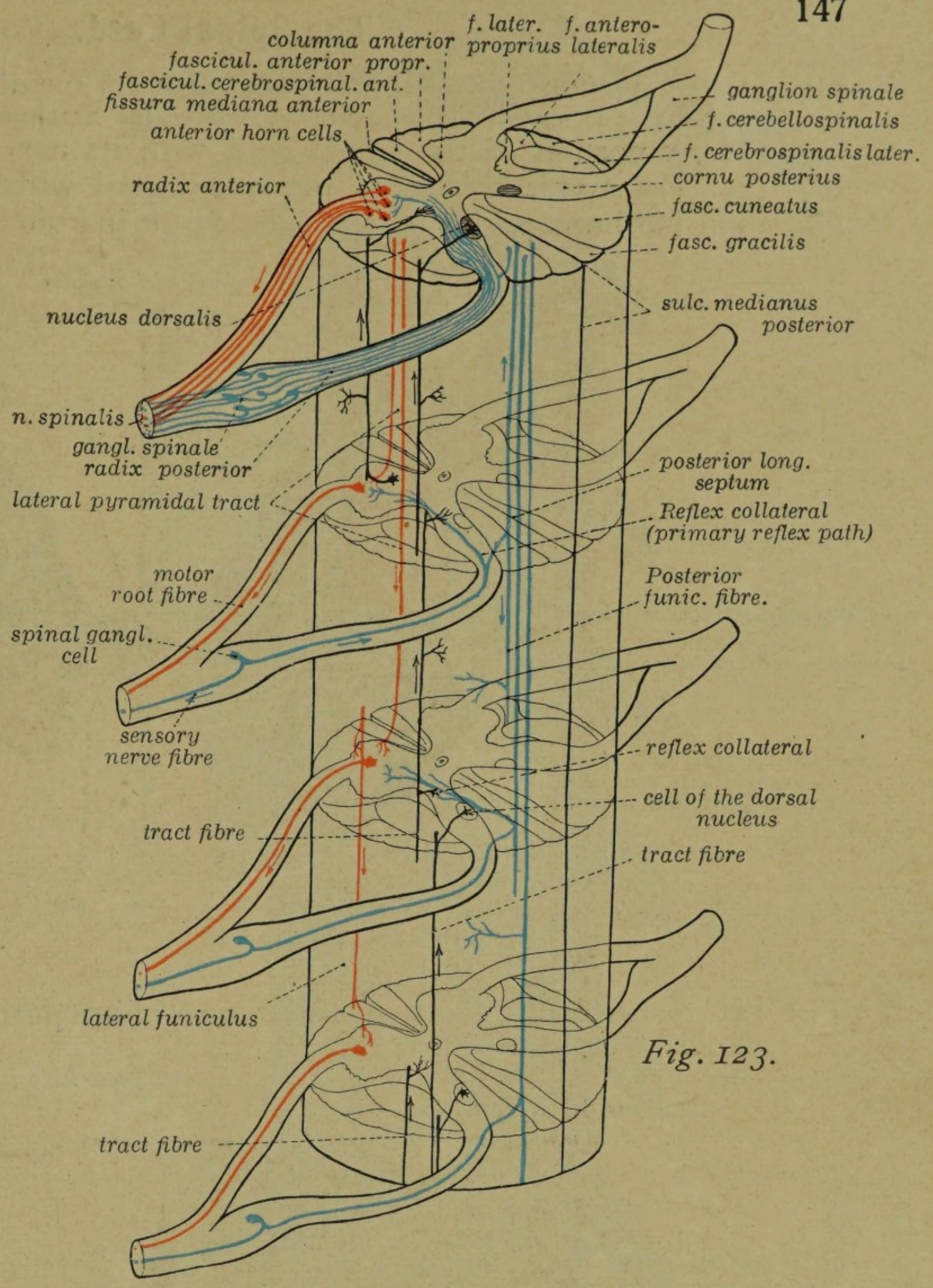

Fig. 123.

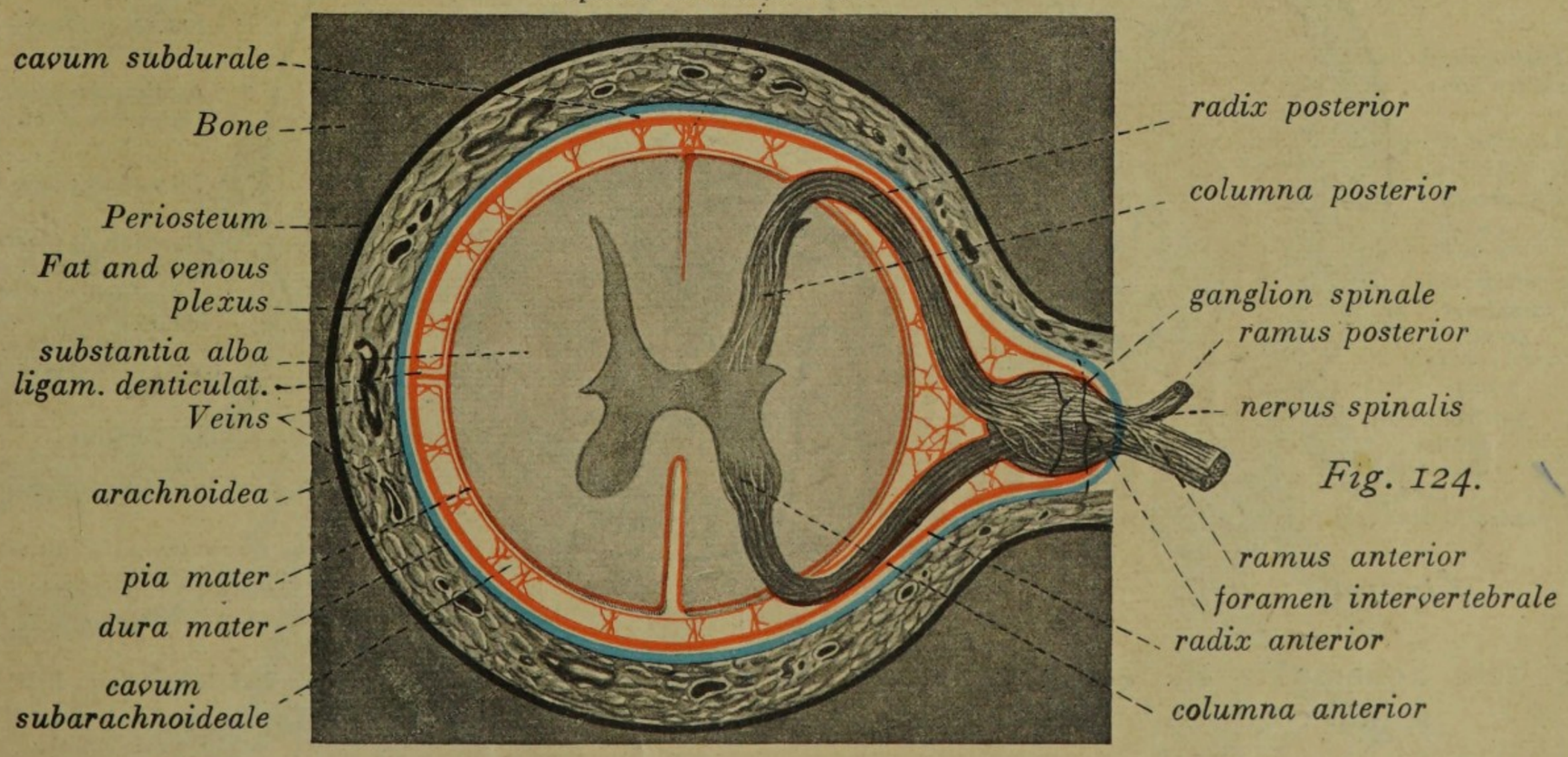

Fig. 124.

The Spinal Cord. (Cont.)

Fig. 127. A portion of the spinal cord with its membranes from behind. (1/4) The dura mater is shown unopened below, above the arachnoid is removed.
Fig. 128. A portion of the spinal cord with its nerve roots, from in front. (1/4)
Fig. 129. Transverse section of the spinal cord with the two spinal ganglia. (1/4)
Fig. 130. The lower part of the spinal cord from in front. (1/4) The dura mater is opened lengthwise.

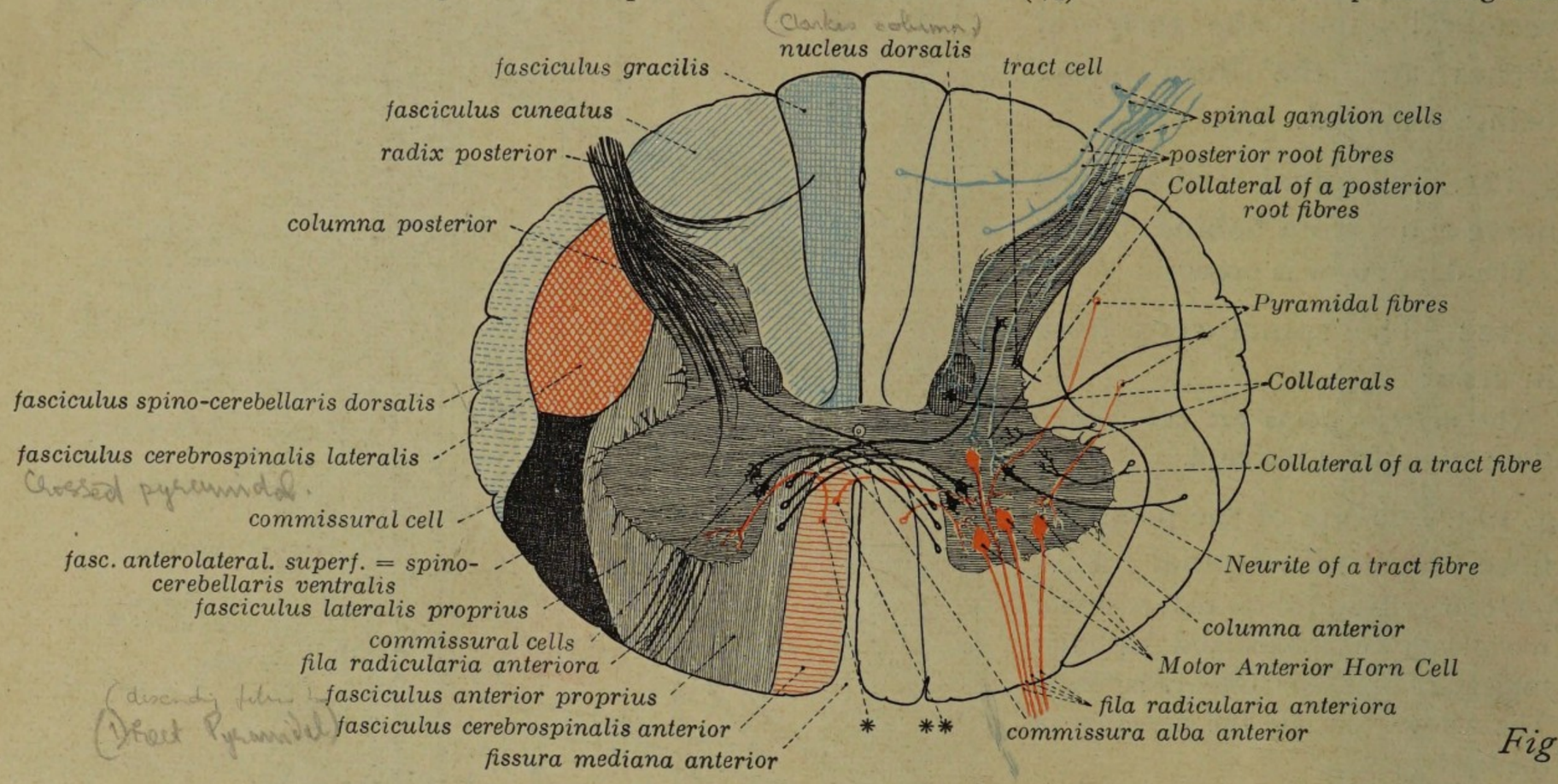

Fig. 125.

Fig. 125. Schema of the principal tracts and fibre paths in the spinal cord. (For explanation see p. 151.)

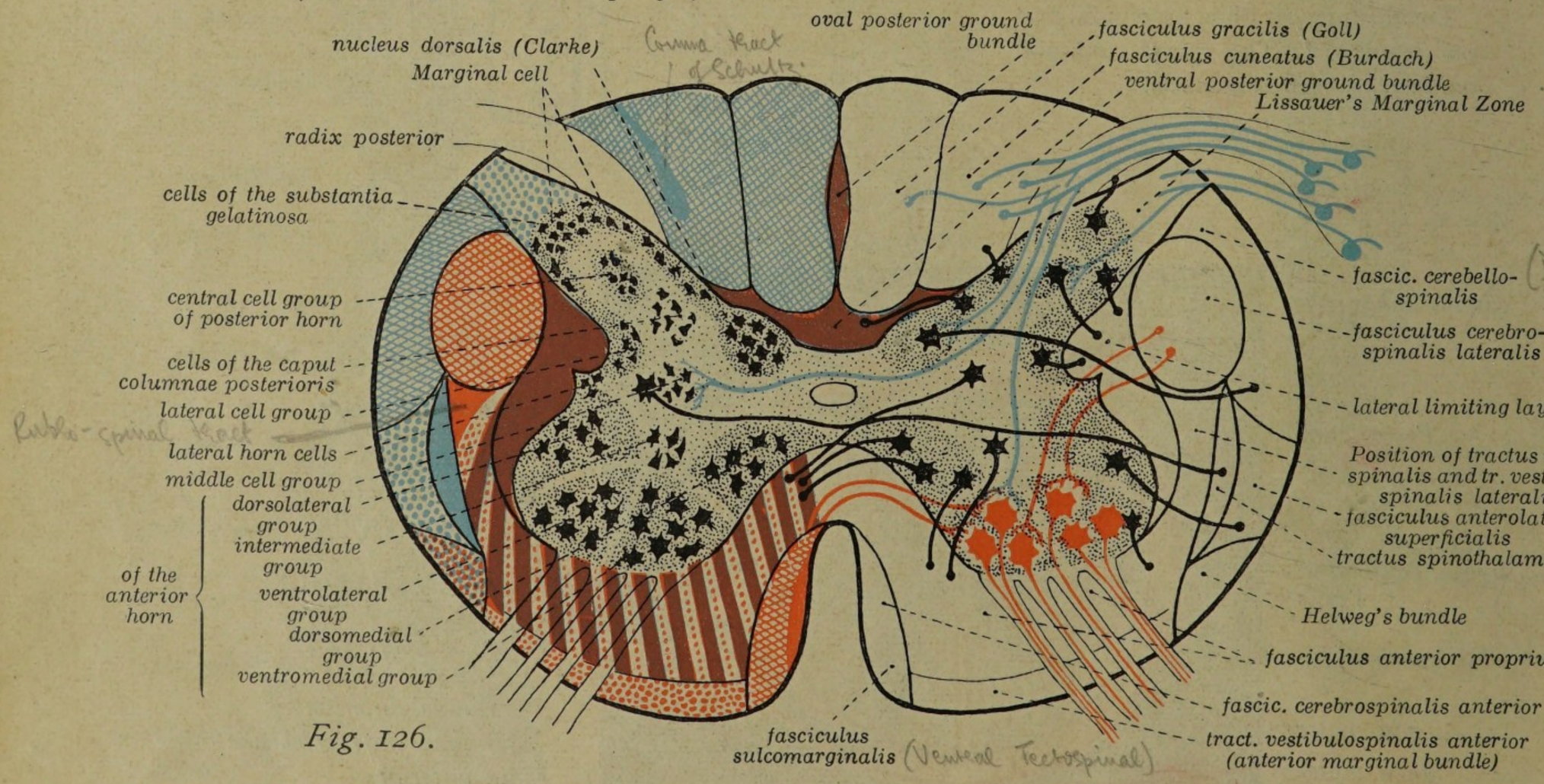

Fig. 126.

Fig. 126. Schema of the arrangement of the conducting paths in the funiculi of the spinal cord, and the topography of the grey substance. (For explanation see p. 151.)

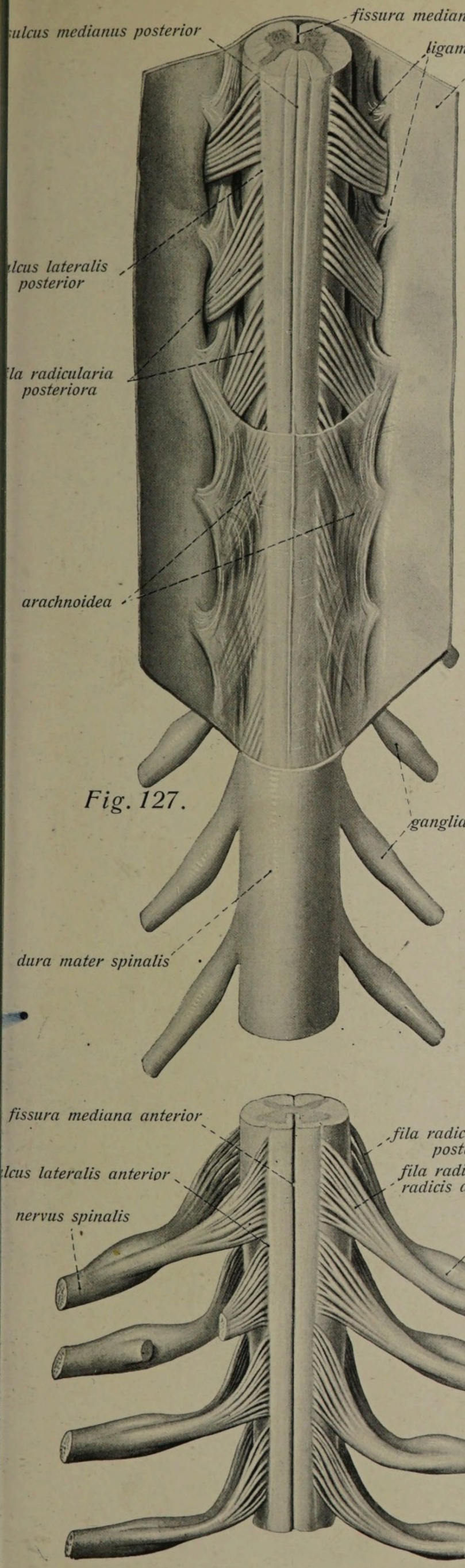

Fig. 127.

Fig. 128.

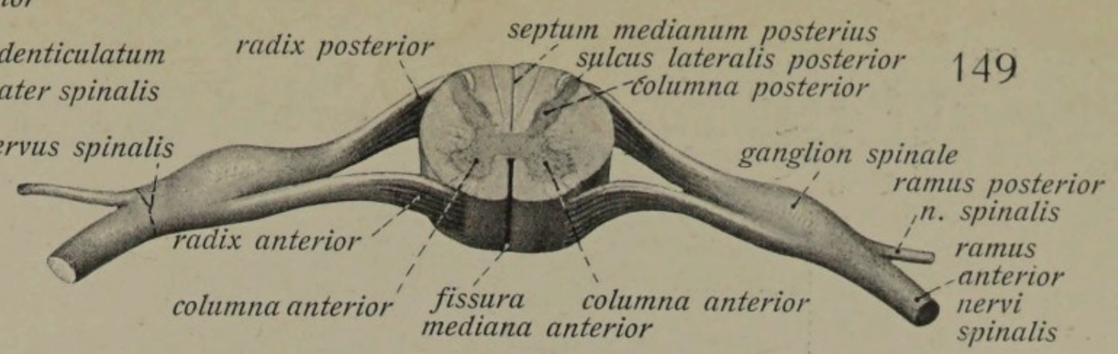

Fig. 129.

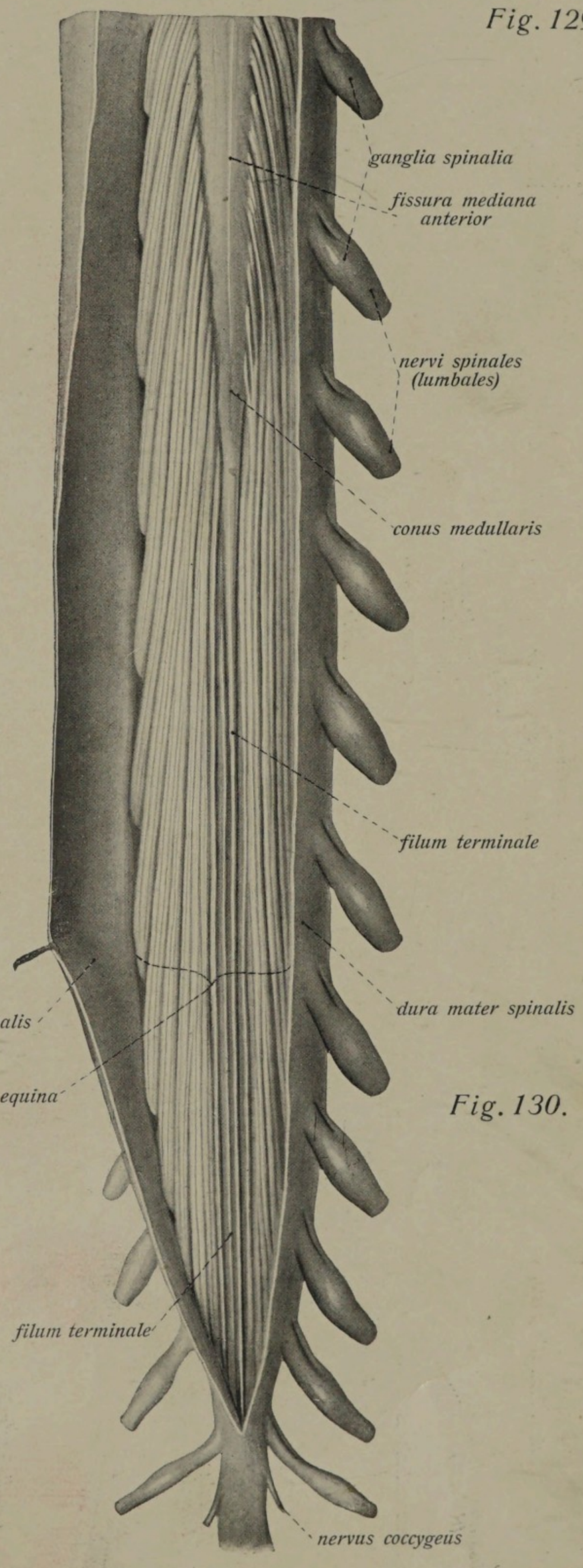

Fig. 130.

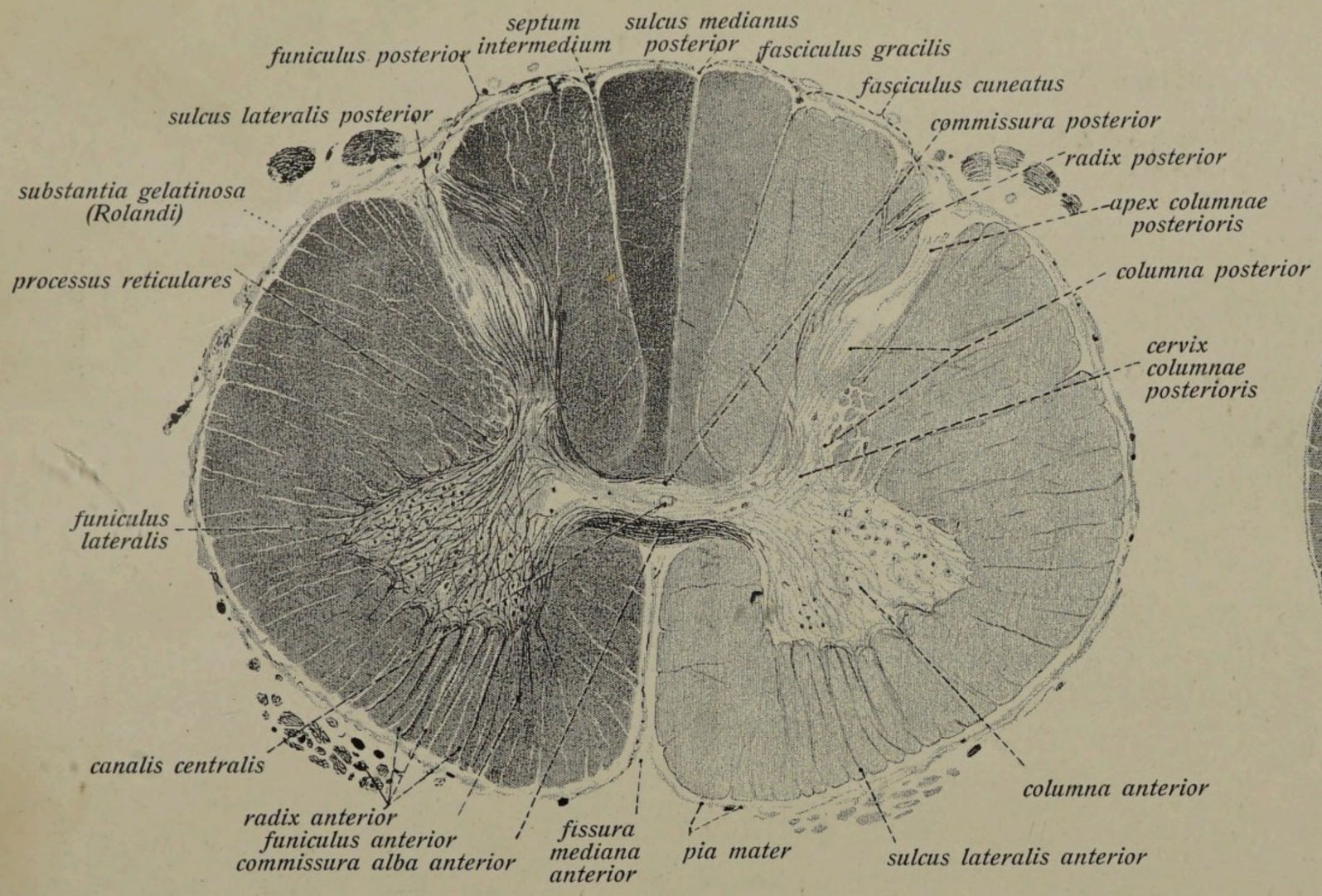

Fig. 131.

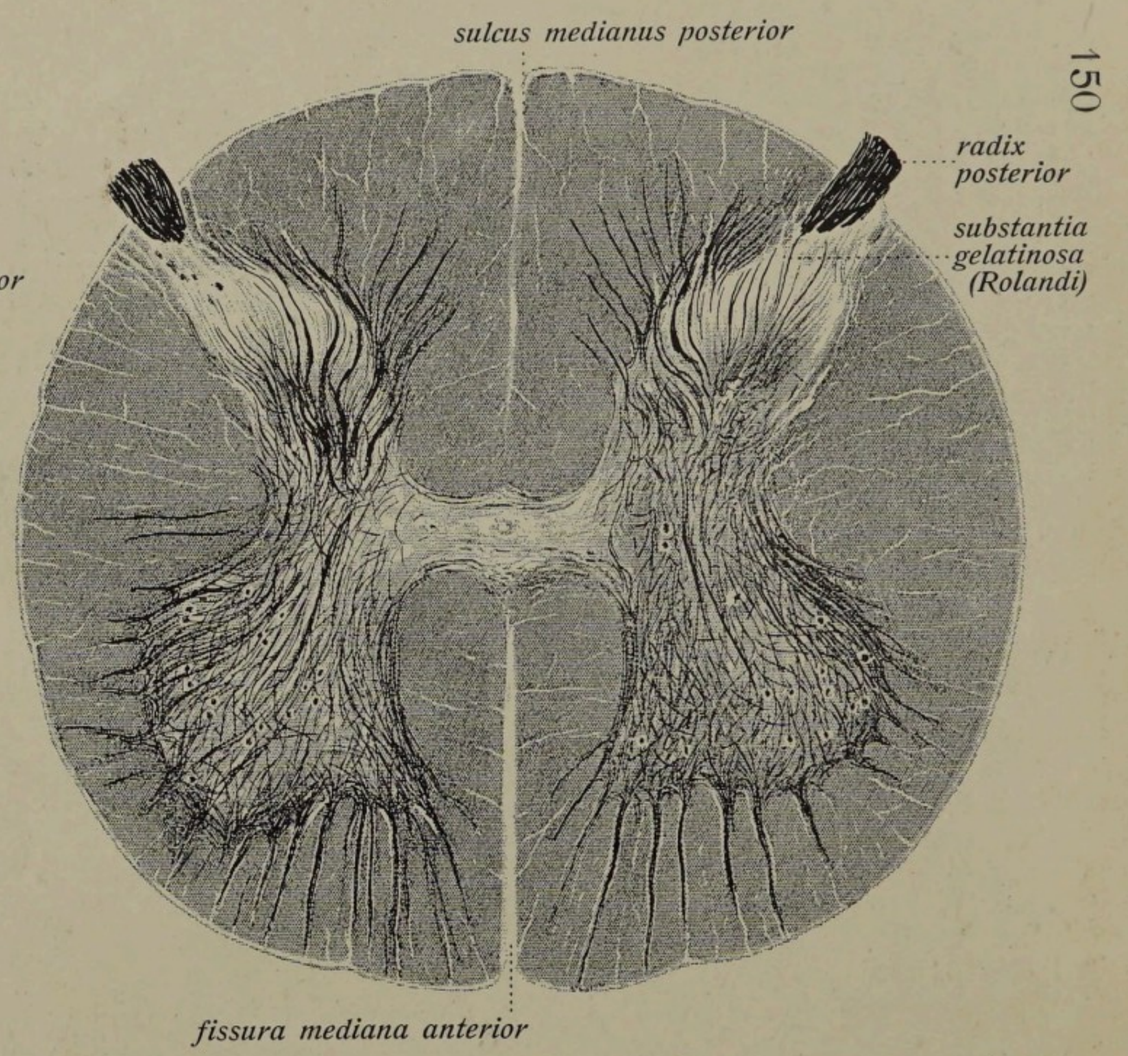

Fig. 133.

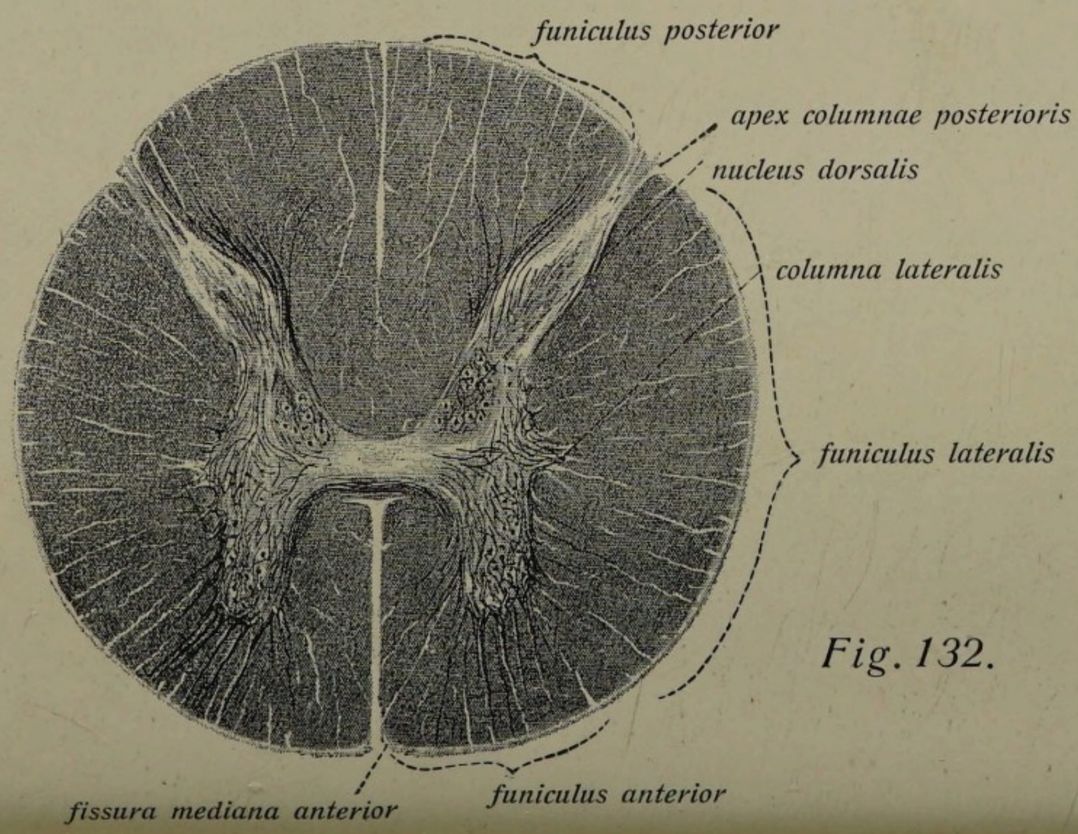

Fig. 132.

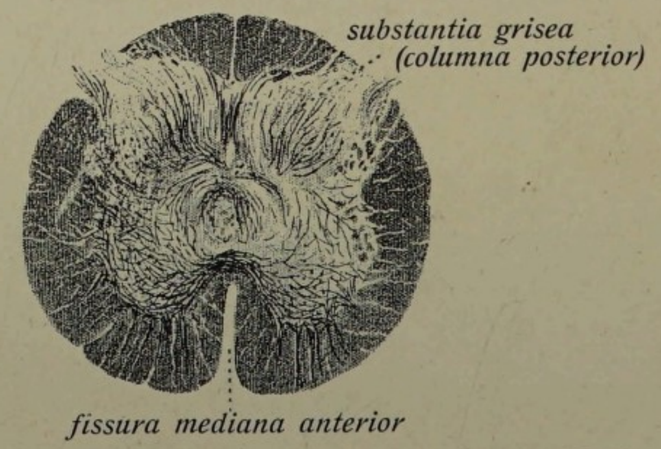

Fig. 134.

Fig. 131—134. Transverse sections of the spinal cord at the level of the cervical enlargement (131), the thoracic region (132), the lumbar enlargement (133) and the conus medullaris (134). Enlargement 8 : 1.

The Spinal Cord. (Cont.)

Explanations for Fig. 125 and 126 (p. 148).

In 125 red denotes the pyramidal tracts with their collaterals, nerve cells and root fibers. * = direct. ** = crossed pyramidal tract; blue denotes the posterior root fibers with their collaterals and, in addition, the column of Goll (crosshatched), the column of Burdach (striated) and the dorsal spinocerebellar tract (stippled).

In 126 Grey substance: On the left the grouping of the cells is shown; on the right the motor root fibres are red, the sensory are blue and the tract fibre cells black.

White substance: on the right the principal conducting paths are outlined; on the left ascending paths are blue, descending red; intrinsic fibres violet. The solid blue in the blue cross hatched posterior funiculus is the comma bundle; the solid red between dotted and cross hatched red in the lateral funiculus is the rubro-spinal tract.

The Conducting Paths in the Spinal Cord.

According to their course three groups of conducting paths may be recognized in the spinal cord: 1. descending from the brain to the cord, 2. ascending from the cord to the brain and 3. beginning and ending in the cord. Only the first two groups are localized in definite areas of the three funiculi; the fibres of the last group, especially in the anterior and lateral funiculi, lie between those of the other groups.

1. *Descending paths*. The largest of these is the *pyramidal* tract which begins in the central gyri of the cerebral cortex and passes thence to the motor cells of the anterior horns (the central portion of the motor pathway). The chief mass of the fibres forms a compact bundle, the *lateral cerebro-spinal fasciculus (crossed pyramidal tract)*, in the posterior part of the lateral funiculus, while a smaller bundle, the *anterior cerebro-spinal fasciculus (direct pyramidal tract)*, lies in the medial portion of the anterior funiculus. In addition to the pyramidal tract, fibres pass down from the region of the quadrigemina, both from the grey substance of these and from the red nucleus; the former lie chiefly in the anterior funiculus close to the median fissure and form the *sulco-marginal fasciculus* (*ventral tectospinal tract*), some lying also in the lateral funiculus (*lateral tectospinal tract*). The fibres from the red nucleus form the *rubrospinal fasciculus* (Monakow) and are situated in the lateral funiculus. Here too is the *lateral vestibulo-spinal tract* from the vestibular nucleus of Deiters in the pons, while the main portion of this path, the *anterior vestibulo-spinal tract*, forms the marginal bundle of the anterior funiculus. Finally, this funiculus also contains the descending *medial longitudinal fasciculus*. Fig. 124, 126.

2. *Ascending paths*. These lie principally in the posterior funiculus, some smaller bundles also in the lateral. The posterior funiculi are formed by the sensory neurites of the spinal ganglion cells, the medial fasciculus gracilis containing chiefly fibres from the lower half of the body, while the lateral fasciculus cuneatus contains those from the upper half. The fibres pass upwards to the nuclei of the clava and of the cuneate tubercle. The most important ascending tract of the lateral funiculus is the *spino-cerebellar fasciculus*, whose principal part (Flechsig's bundle) takes origin from the cells of the dorsal nucleus, while a more anterior portion, that also arises from the cells of the cord, is termed the *dorsal spinocerebellar* (*Gower's*) tract. Finally fibres also pass from the (contralateral) cells of the cord to the thalamus, the *spino-thalamic* tract. The course of the fibres in Helweg's bundle is still uncertain (*spino-olivary tract?*). Fig. 124, 126.

Above T7.

Fig. 131—134. Transverse sections of the spinal cord at the level of the cervical enlargement (131), the thoracic region (132), the lumbar enlargement (133) and the conus medullaris (134). Enlargement 8: 1.

The Cerebral Meninges.

Fig. 135. The dura mater of the brain, its arteries and blood sinuses, the veins of the orbit and the roots of the 12 cranial nerves. (1/1)

The left orbit is opened by the removal of its roof, the superficial muscles and nerves of the orbit are removed to show the arrangement of the veins; on the right the tentorium cerebelli is removed, the terminal portion of the transverse sinus is opened and the dura mater is divided over the issuing nerves and the middle meningeal artery. * = the meningeal nerve and its anastomosis with the spinosal nerve. ** = cut edge of the tentorium.

The Cerebral Dura Mater

covers the inner surface of the skull, blending by its outer layer with the periosteum and penetrating for a distance into some of the bony canals for the exit of nerves, such as the internal acoustic pore or the facial canal. The most important structures of the dura mater are:

1. The *diaphragma sellae*, a sheet covering the hypophyseal fossa and the hypophysis contained therein. Fig. 135, 136.

2. The *falx cerebri* a median sickle-shaped plate projecting into the longitudinal cerebral fissure. It arises in front, where it is low, from the crista galli, above from the frontal crest and the margins of the sagittal groove, and, behind, where it is much broader, it is attached to the tentorium cerebelli. Its lower free edge lies (especially behind) immediately above the upper surface of the corpus callosum. Fig. 135, 136, 140, 141, 143.

3. The *tentorium cerebelli* arises on each side from the upper border of the pyramid of the temporal bone and from the upper border of the transverse groove in the occipital bone. It covers, like a roof, the posterior cranial fossa, leaving only an opening, the *tentorial notch* (converted into a foramen by the sphenoid bone anteriorly), for the passage of the brain stem. It is interposed between the cerebellum and the cerebrum, is convex above and concave below and has attached to it in the median line the posterior edge of the falx cerebri. Fig. 135, 136, 140, 141.

4. The *falx cerebelli* arises from the internal occipital crest and projects into the posterior cerebellar notch, being attached above to the under surface of the tentorium. Fig. 136.

The Sinuses of the Dura Mater.

These lie between the layers of the dura mater, usually in special grooves on the bones. They carry the blood from the cranial cavity and the brain and orbit to the internal jugular vein. Fig. 135—137, 139, 140, 143. They are:

1. The *transverse sinus*, the largest of all, lies in the transverse and sigmoid grooves. It begins at the internal occipital protuberance in the *confluens sinuum*, in which most of the dural sinuses unite, and runs thence, receiving the inferior cerebral veins, along the line of attachment of the tentorium and, finally, to the jugular foramen, where it opens into the bulb of the internal jugular vein. At the confluens sinuum it is connected with the superior sagittal sinus, (which usually opens partly or as a whole into the right transverse sinus), the occipital and straight sinuses and, in addition, it receives the superior petrosal sinuses and occasionally, just before opening into the internal jugular, the inferior petrosal. Fig. 135, 136, 140, 141.

2. The *superior sagittal sinus* runs in the sagittal groove on the vault of the cranium, along the line of attachment of the falx cerebri. It begins at the foramen caecum, where it anastomoses with the veins of the nose, becomes larger posteriorly by the reception of the superior cerebral veins and opens at the confluens sinuum usually into the right transverse sinus. Fig. 135, 136, 137, 140, 141.

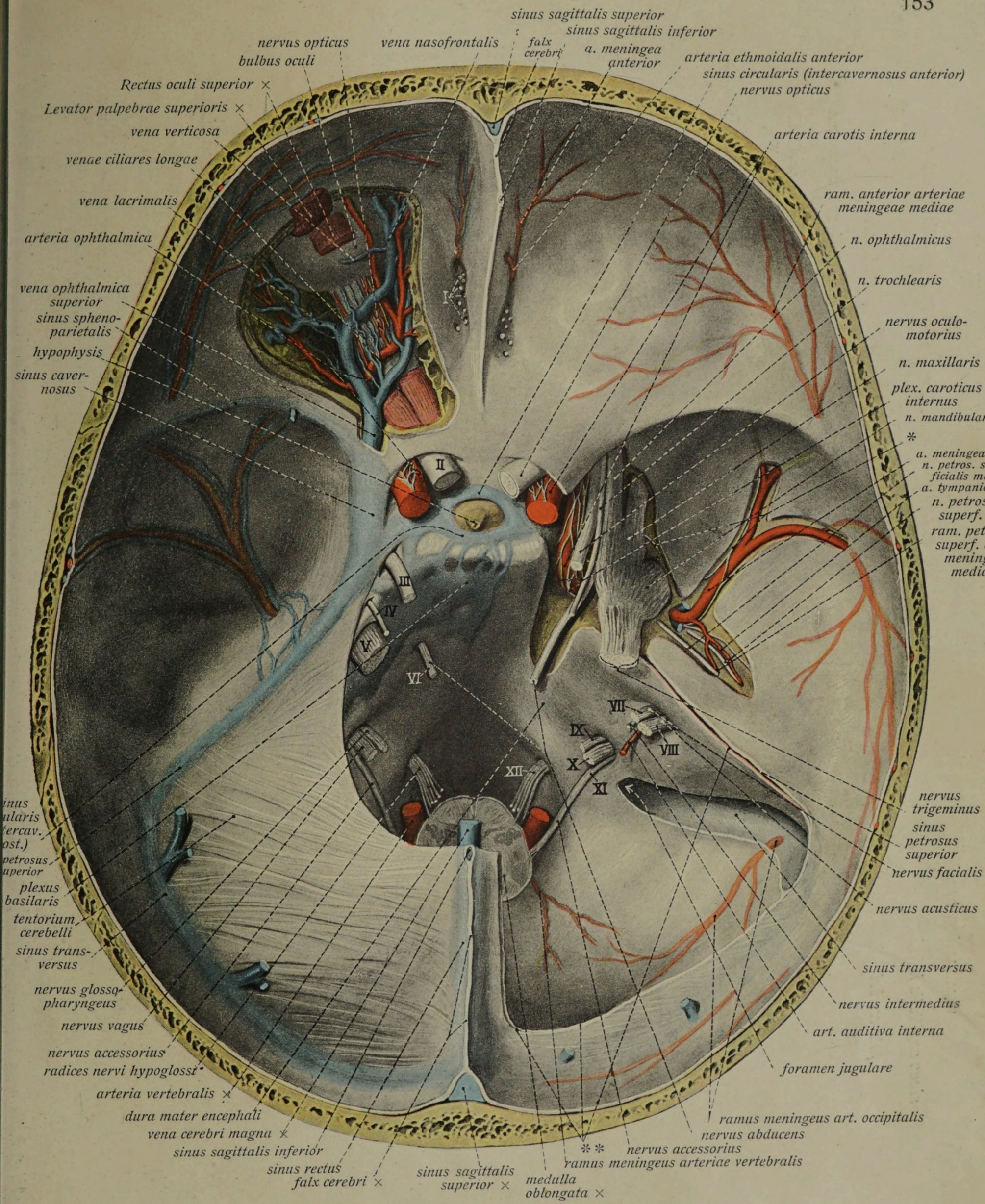
sinus sagittalis superior
sinus sagittalis inferior
nervus opticus
bulbus oculi
vena nasofrontalis
falx cerebri
a. meningea anterior
arteria ethmoidalis anterior
sinus circularis (intercavernosus anterior)
nervus opticus
Rectus oculi superior ×
Levator palpebrae superioris ×
vena verticosa
venae ciliares longae
vena lacrimalis
arteria ophthalmica
arteria carotis interna
ram. anterior arteriae meningeae mediae
n. ophthalmicus
n. trochlearis
vena ophthalmica superior
sinus sphenoparietalis
hypophysis
sinus cavernosus
nervus oculomotorius
n. maxillaris
plex. caroticus internus
n. mandibularis
*
a. meningea media
n. petros. superficialis major
a. tympanic. super.
n. petrosus superf. min.
ram. petros. superf. art. meningeae mediae
II
III
IV
V
VI
VII
VIII
IX
X
XI
XII
nervus trigeminus
sinus petrosus superior
nervus facialis
nervus acusticus
sinus transversus
nervus intermedius
art. auditiva interna
foramen jugulare
ramus meningeus art. occipitalis
nervus abducens
** nervus accessorius
ramus meningeus arteriae vertebralis
sinus sagittalis superior ×
medulla oblongata ×
sinus rectus
falx cerebri ×
sinus sagittalis inferior
vena cerebri magna ×
dura mater encephali
arteria vertebralis ×
nervus accessorius
radices nervi hypoglossi
nervus vagus
nervus glossopharyngeus
sinus transversus
tentorium cerebelli
plexus basilaris
petrosus superior
sinus cavernosus (post.)

Fig. 135.

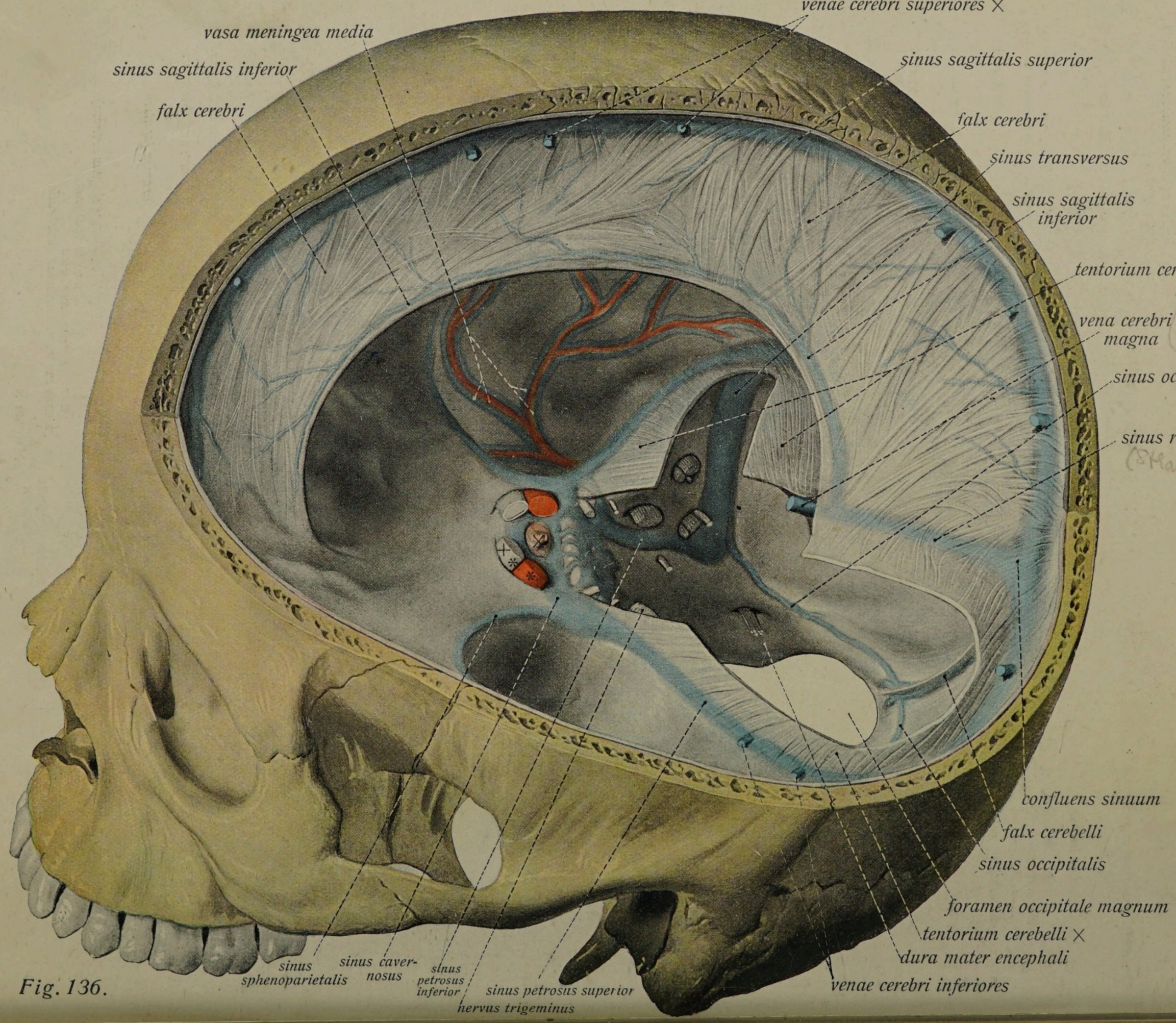

Fig. 136.

Fig. 136. The dura mater and its sinuses, from the side and above. (1/1) The skull is divided horizontally almost to the middle line and then sagittally; the brain is removed, but the hypophysis is left in position in the sella turcica. On the left a large and on the right a smaller portion of the tentorium is removed. The veins are blue, the arteries red, the nerves white. * = internal carotid artery. + = hypophysis. +* = optic nerve.

The Cerebral Dura Mater. (Cont.)

The Sinuses of the Dura Mater. (Cont. from p. 152.)

3. The *straight sinus* lies along the attachment of the falx cerebri to the tentorium. In addition to the following it receives the great cerebral vein, being its direct continuation; it opens into the confluens sinuum. Fig. 135, 136, 141.

4. The *inferior sagittal sinus* runs in the lower edge of the falx cerebri and opens into the preceding. Fig. 136, 141.

5. The *inferior petrosal sinus* lies in the inferior petrosal groove and unites the cavernous sinus with the bulb of the internal jugular vein. This is the only sinus that does not regularly open directly into the transverse. Fig. 135, 136.

6. The *superior petrosal sinus* lies in the superior petrosal groove, along the origin of the tentorium. It connects the cavernous sinus with the transverse. Fig. 135, 136.

7. The *cavernous sinus* at the sides of the sella turcica, encloses the internal carotid artery and the abducens nerve (see p. 72 and 167). It receives the superior ophthalmic vein (see below), the middle cerebral vein and the *spheno-parietal sinus* and forms the *circular sinus*, by transverse branches passing in front of and behind the hypophysis. Its blood flows into the internal jugular vein or transverse sinus, through the petrosal sinuses. In the wall of the sinus run the oculomotor, trochlear and ophthalmic nerves and in part also the maxillary nerve. Numerous connective tissue strands traverse the sinus and are attached to the wall of the internal carotid artery; they give the sinus its "cavernous" appearance. Fig. 135, 136, 139.

8. Smaller sinuses are: the *occipital sinus* at the foramen magnum and in the falx cerebelli; the *basilar plexus* on the clivus; and the *spheno-parietal sinus* on the lower border of the lesser wing of the sphenoid. Fig. 135, 136.

Tributaries of the Sinuses of the Dura Mater.

I. The Orbital Veins.

1. The *superior ophthalmic vein*, the chief vein of the orbit, corresponds in general to the ophthalmic artery. It is formed by the *naso-frontal*, the *ethmoidal*, the *lacrimal*, the *ciliary* (including the *retinal ciliary*) and smaller veins of the orbit, and opens into the cavernous sinus through the superior orbital fissure. Fig. 135.

2. The *inferior ophthalmic vein* lies deeply and on the floor of the orbit, and opens into the preceding near the superior orbital fissure, consequently passing, indirectly, into the cavernous sinus. Through the inferior orbital fissure there occasionally pass small anastomoses to the pterygoid plexus and to the anterior facial vein.

Fig. 136. The dura mater and its sinuses, from the side and above. (1/1) The skull is divided horizontally almost to the middle line and then sagittally; the brain is removed, but the hypophysis is left in position in the sella turcica. On the left a large and on the right a smaller portion of the tentorium is removed. The veins are blue, the arteries red, the nerves white. * = internal carotid artery. + = hypophysis. +* = optic nerve.

The Blood Vessels of the Dura Mater and of the Brain.

Fig. 137. The superior sagittal sinus and the lateral lacunae; the veins and arteries of the brain, from above. (1/1)
A portion of the dura mater is retained along the superior sagittal sinus, the sinus itself is opened and also a lateral lacuna on the right. * = openings of veins into sinus.

Fig. 138. The course of the internal carotid artery at the sides of the sella turcica. (1/1)
1. after the name of the artery denotes its emergence from the foramen lacerum. 2. its S-shaped bend beside the sella turcica; 3. its passage upon the brain.

Fig. 139. A frontal section through the cavernous sinus. (3/1)

Tributaries of the Sinuses of the Dura Mater. (Cont. from p. 152 and 155.)

II. The *internal auditory vein*, the small vein of the internal ear that passes through the internal auditory opening into the cranial cavity, and pours its blood into the inferior petrosal sinus.

III. The veins of the dura mater. The blood from these to a small extent flows through the meningeal veins to the pterygoid plexus.

IV. The *diploic veins* see p. 159.

V. The *emissary veins*. These run partly through the entire thickness of the flat bones of the skull, partly through the external tables into the diploë (external emissaries), and partly through the internal table from the diploë into anastomotic veins of the cranial cavity, whose number and development varies greatly. Their passageways also permit the entrance of arterial branches into the cranial cavity. The principal emissary veins are the mastoid, condyloid, parietal and the vein of the foramen caecum.

Through the emissaries the diploic veins (see p. 159), or, if the emissaries traverse the entire thickness of the skull bones, the external veins, are connected with the sinuses of the dura mater.

The Meningeal Arteries.

1. The *middle meningeal artery* arises from the internal maxillary (see p. 72) and runs through the foramen spinosum into the skull cavity. It gives off the *superficial petrosal* branch that passes with the nerve of the same name to the facial canal, where it anastomoses with the stylo-mastoid artery, while another branch, the *superior tympanic*, follows the course of the lesser superficial petrosal nerve to the tympanic cavity. The main stem of the artery, accompanied by doubled *meningeal veins*, runs in the meningeal grooves of the skull bones to the vertex, dividing into an *anterior* and a *posterior* branch. Fig. 60, 66, 67, 135, 136.

2. The *anterior meningeal artery*, from the anterior ethmoidal, is distributed to the anterior cranial fossa. Fig. 60, 135.

3. The *posterior meningeal artery*, from the ascending pharyngeal, is distributed to the region about the jugular foramen. Fig. 135.

4. The *meningeal branch* of the occipital passes through the mastoid foramen. Fig. 135.

5. The *meningeal branch* of the vertebral is distributed to the region about the foramen magnum. Fig. 135.

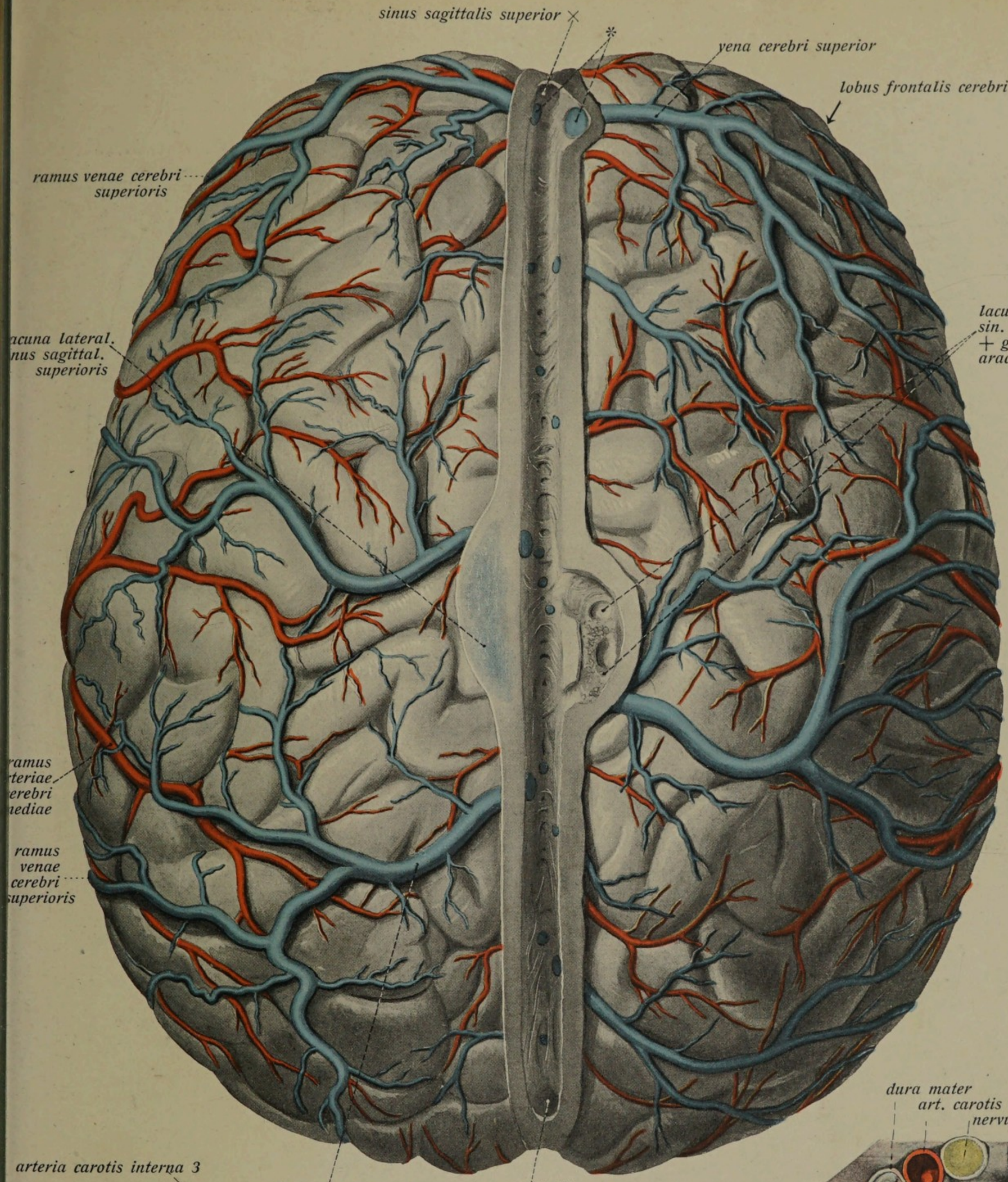

Fig. 137.

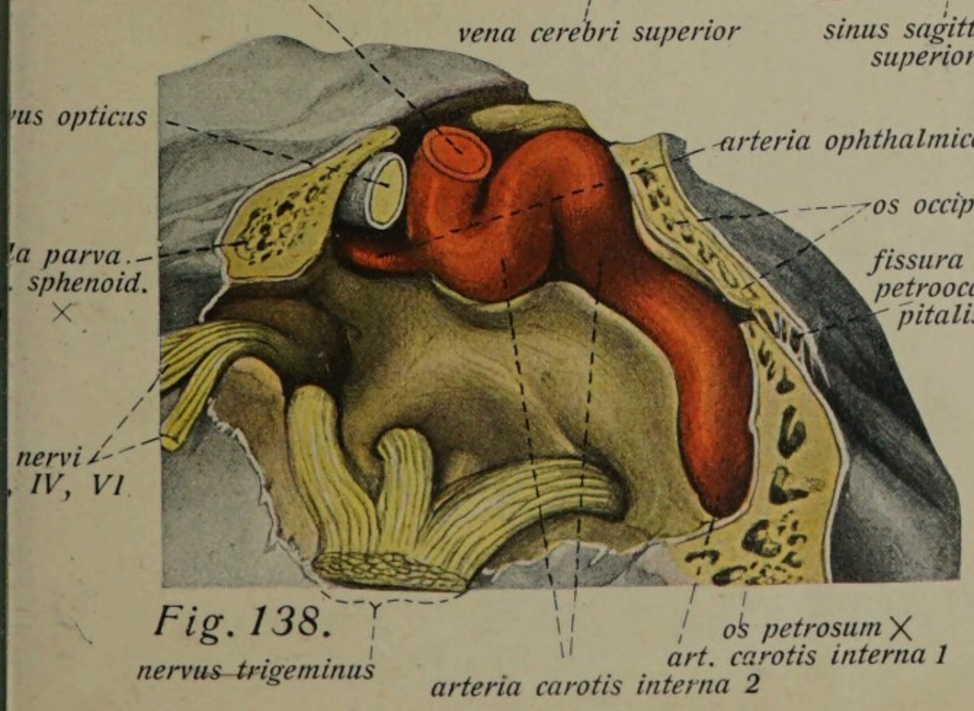

Fig. 138.

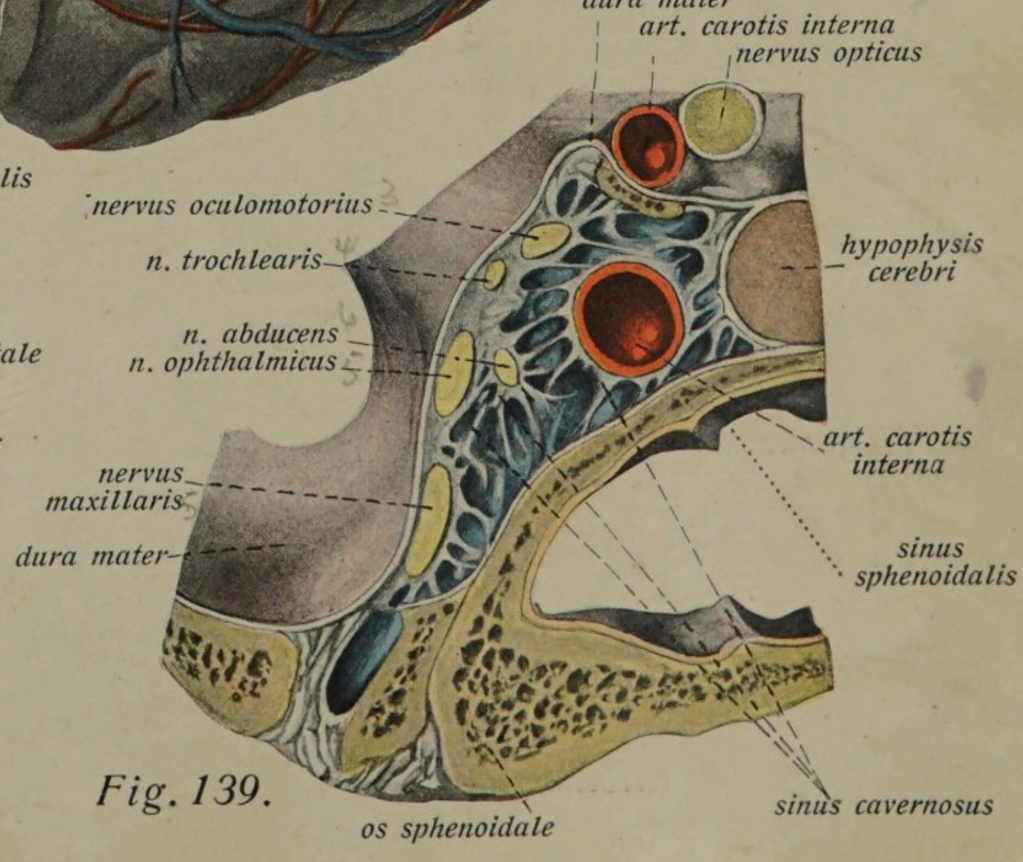

Fig. 139.

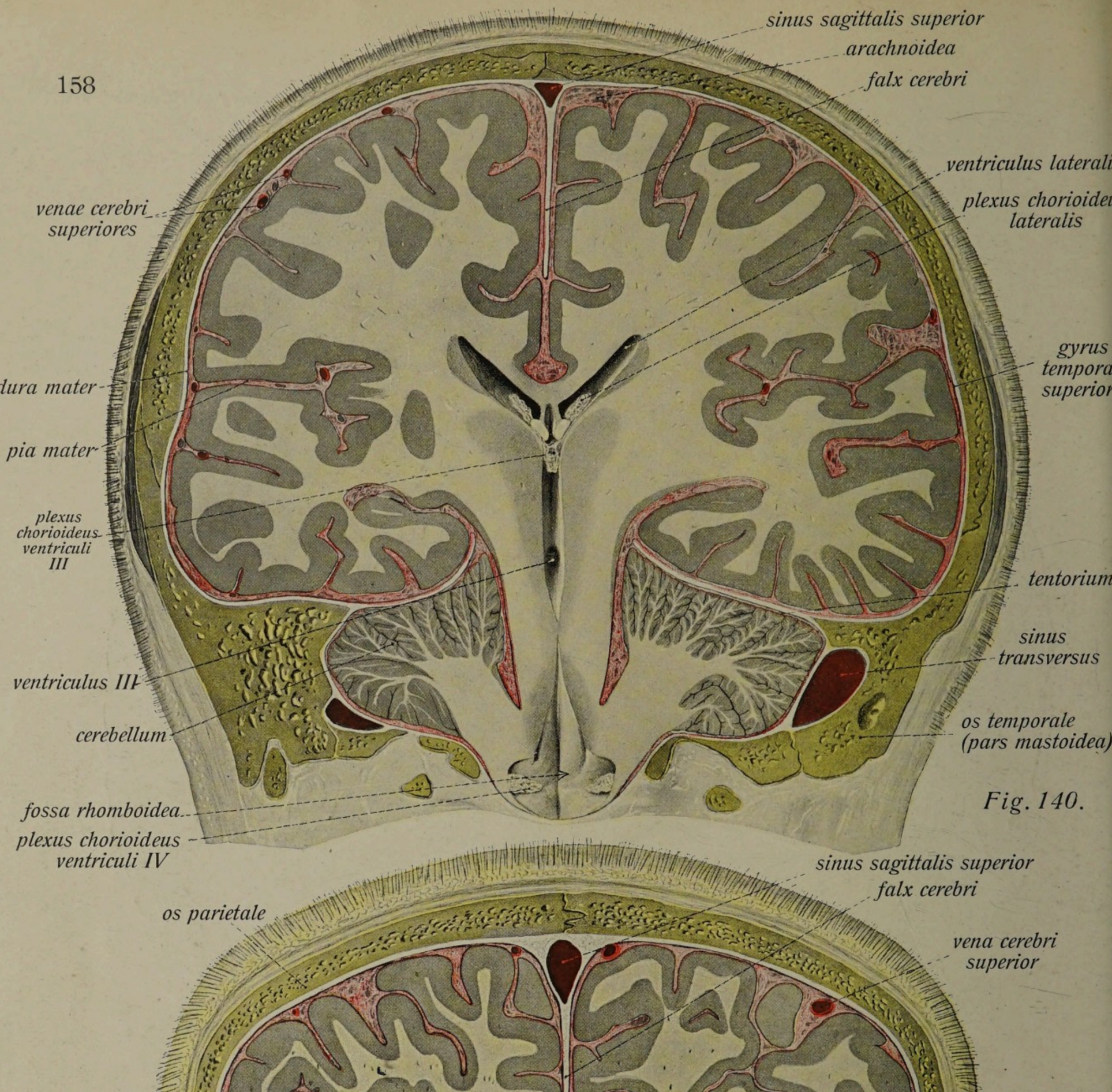

Fig. 140.

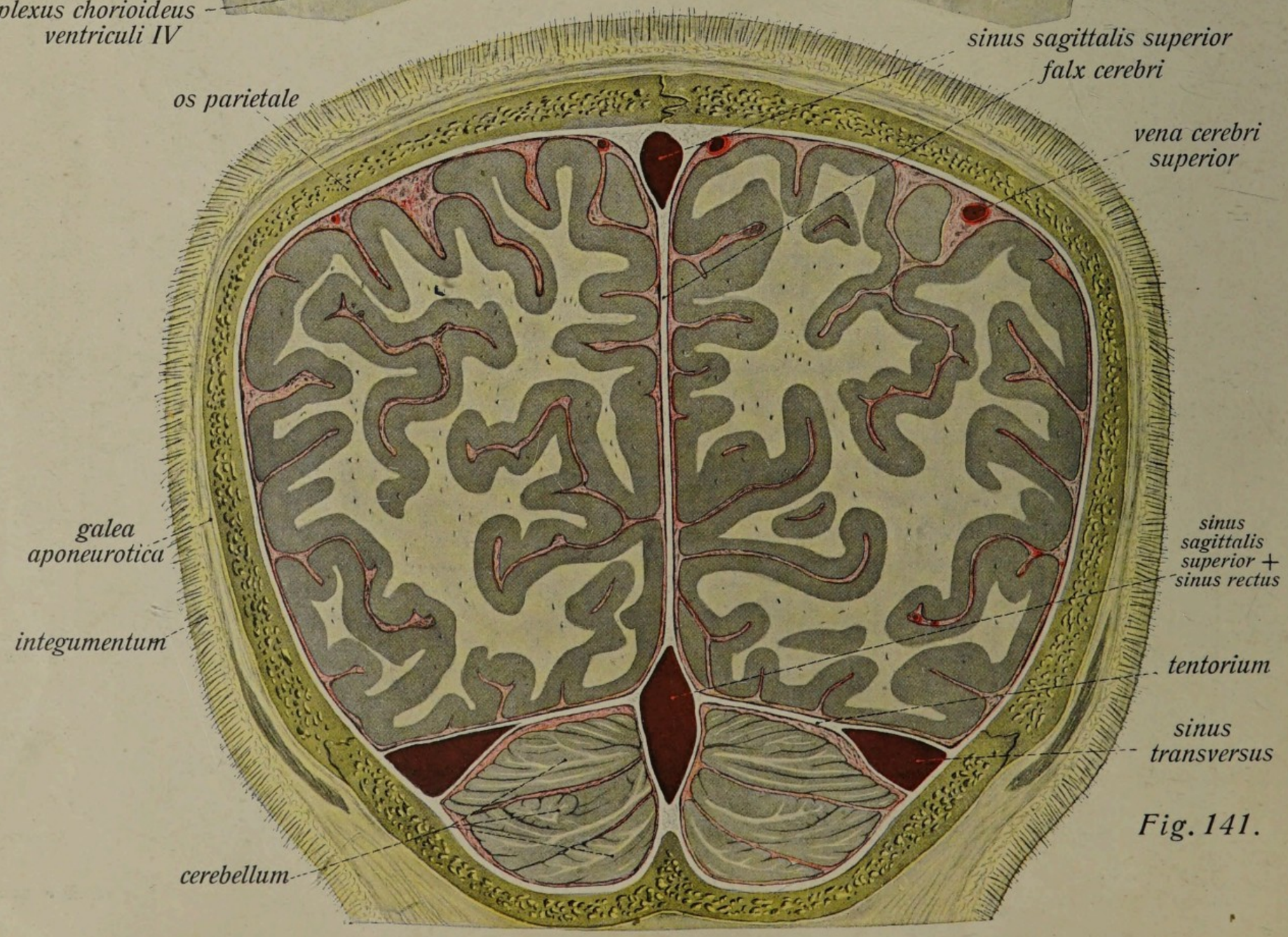

Fig. 141.

The Cranial Arachnoid and Pia Mater.

Fig. 140. A frontal section through the head at the anterior part of the sagittal suture. (2/3) The dura mater is white, the pia mater red.

Fig. 141. A frontal section through the head at the posterior quarter of the sagittal suture. (2/3) The dura mater is white, the pia mater red.

Fig. 142.

Fig. 142. The diploic veins of the vault of the skull, exposed by removing the outer table of the bones.

The Cranial Arachnoid and Pia Mater. (Cont.)

Fig. 144. The base of the brain, with pia mater and arachnoid; the subarachnoidal cisternae. (4/5)
Arrows are placed in certain of the cisternae; the lower end of the medulla oblongata is cut.

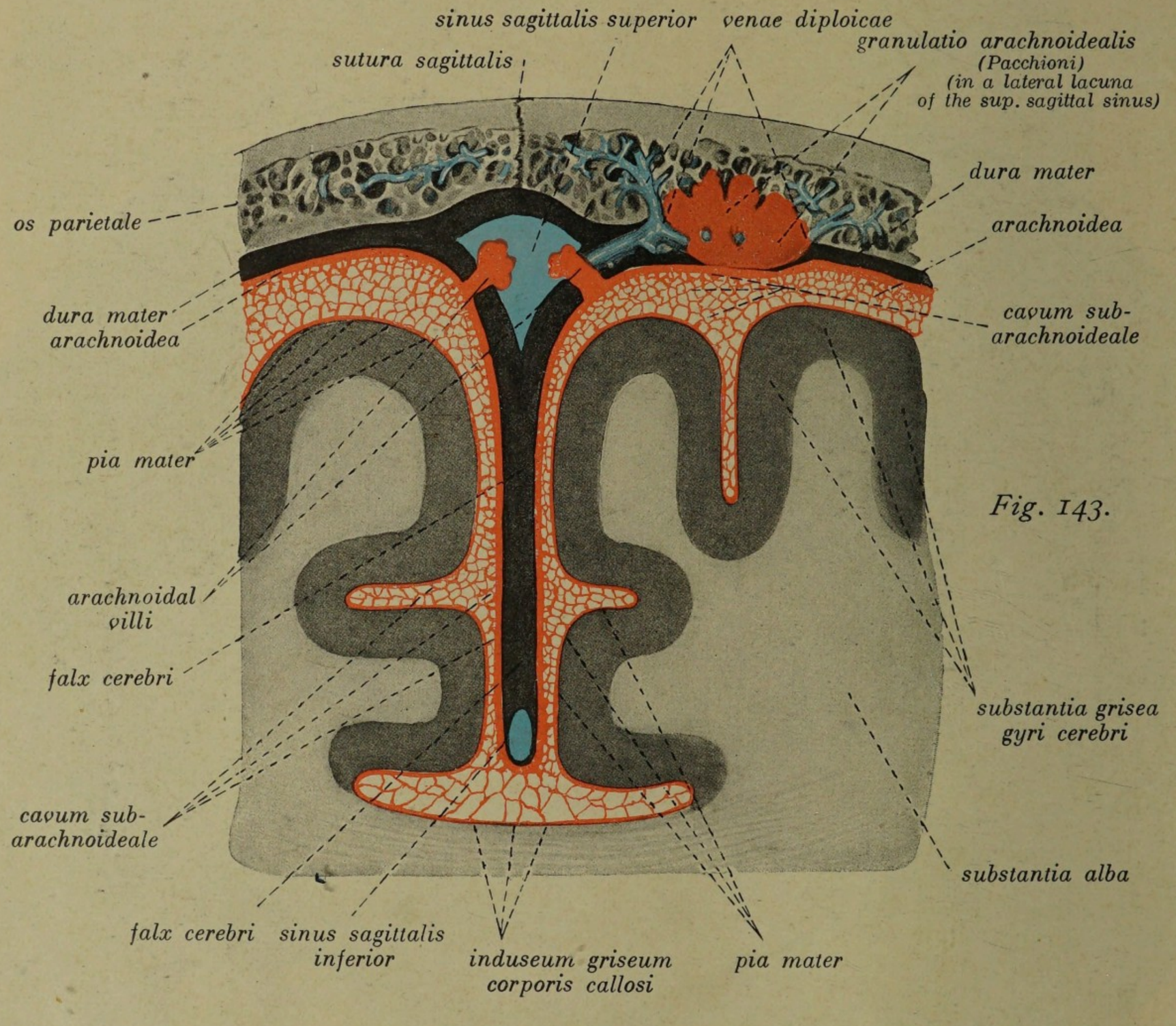

Fig. 143.

Fig. 143. Schema of the cerebral meninges.
The dura materi black, the pia mater and arachnoid red, the veins blue.

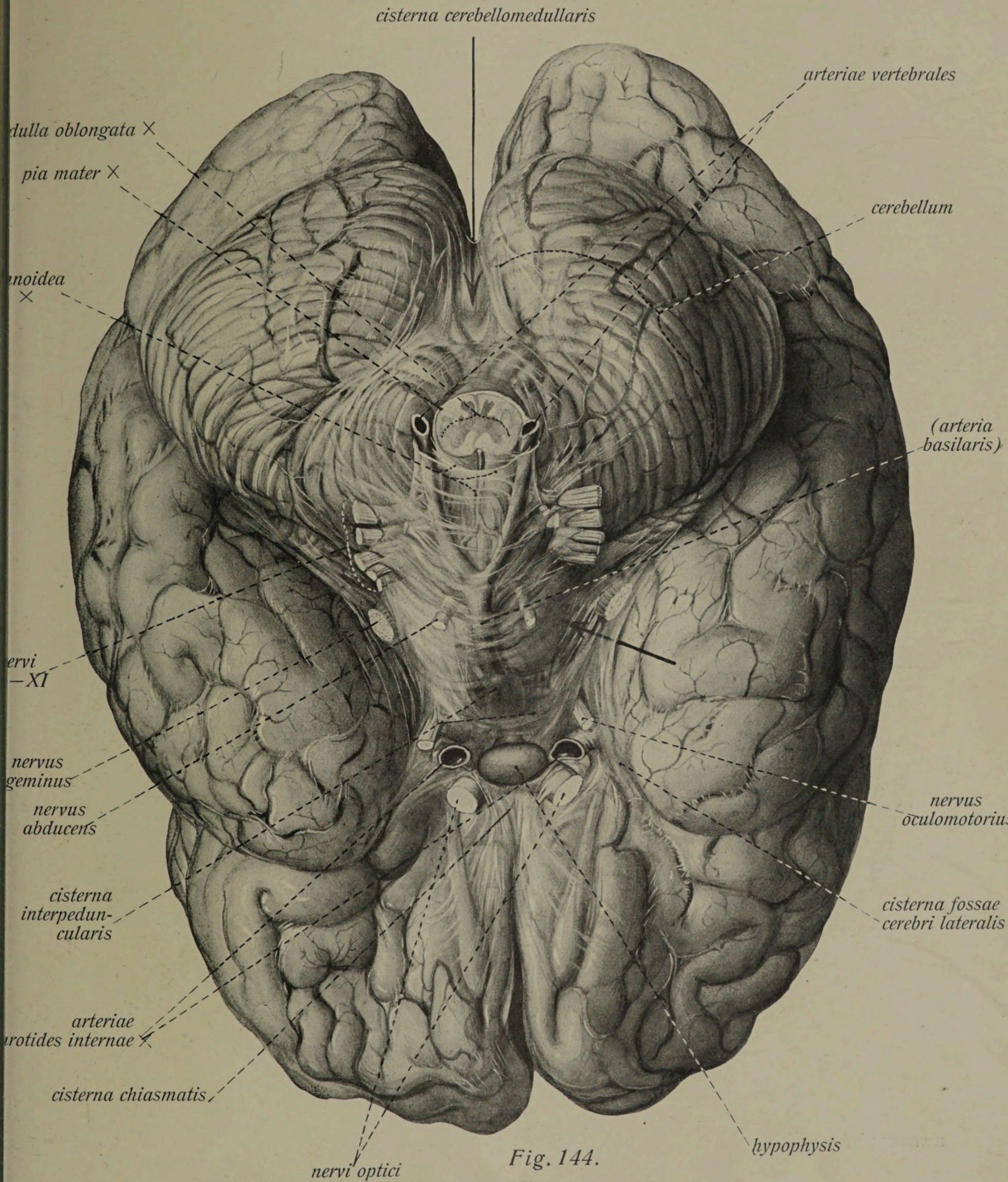
cisterna cerebellomedullaris
arteriae vertebrales
dulla oblongata
pia mater
cerebellum
noidea
(arteria basilaris)
ervi —XI
nervus geminus
nervus abducens
nervus oculomotorius
cisterna interpedun-cularis
cisterna fossae cerebri lateralis
arteriae rotides internae
cisterna chiasmatis
hypophysis
nervi optici

Fig. 144.

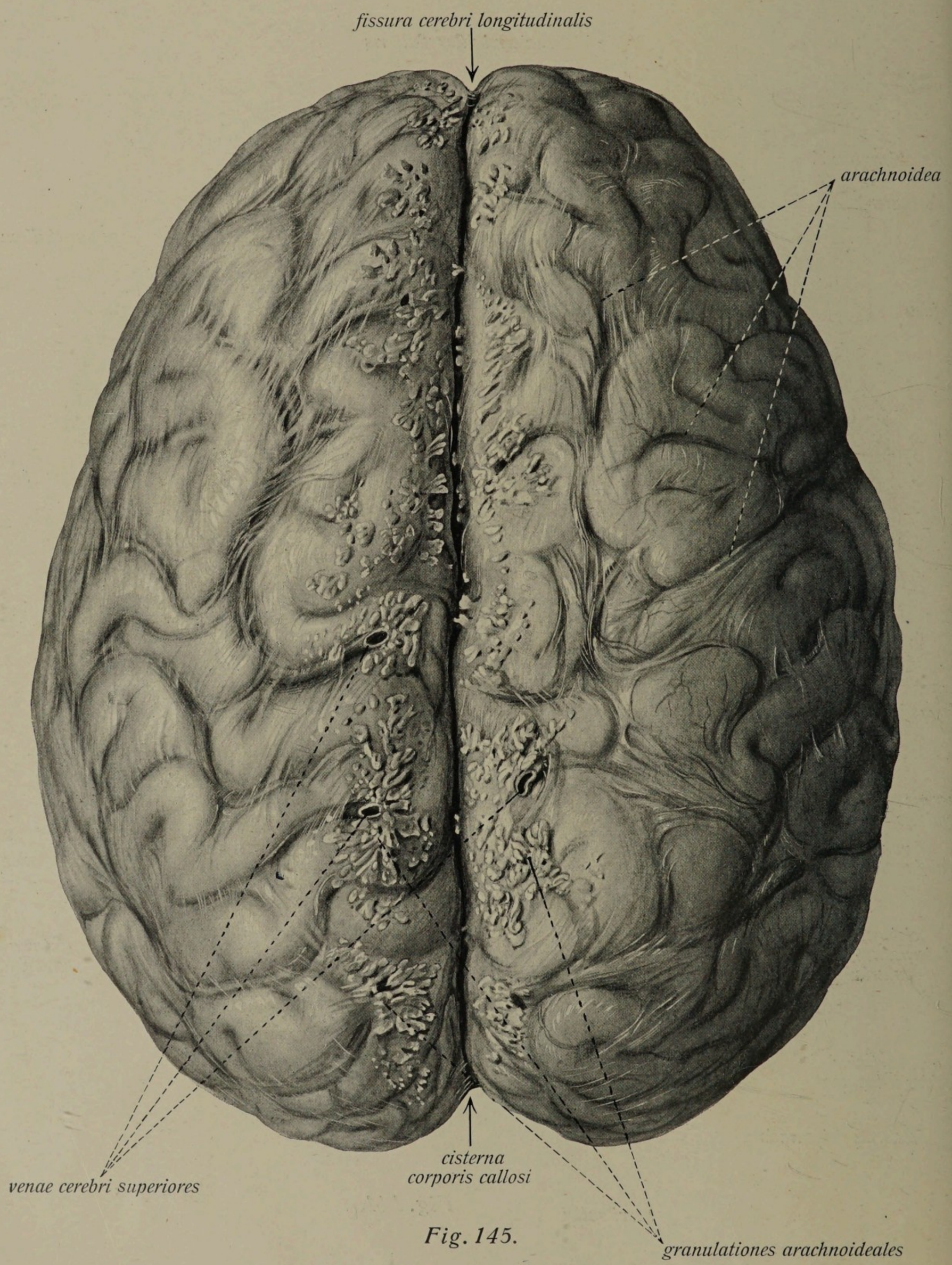
fissura cerebri longitudinalis
arachnoidea
venae cerebri superiores
cisterna
corporis callosi
granulationes arachnoideales

Fig. 145.

The Cranial Arachnoid and Pia Mater. (Cont.)

Fig. 145. The upper surface of the brain with the pia mater and arachnoid. (4/5)

The cranial *pia mater* covers the entire surface of the brain, dipping down into the sulci of the cerebral hemispheres. It is the bearer of the principal blood vessels of the surface of the brain. Special developments of it are the chorioid plexuses (see p. 191) and the telae chorioideae of the third and fourth ventricles (see p. 192). Fig. 140, 141, 143, (190, 191).

The cranial *arachnoid*, like that of the spinal cord, is a non-vascular membrane, closely applied to the dura mater, separated from it, indeed, by little more than a cleftlike space, the *subdural cavity*. On the other hand, between the arachnoid and the pia mater, there is a large *subarachnoid cavity*, filled by the cerebro-spinal fluid, and traversed by numerous connective-tissue strands passing from the pia mater to the arachnoid. Since the arachnoid is associated with the dura rather than the pia mater, it does not follow exactly the surface contours of the brain and does not enter the sulci of the cerebral hemispheres, but enters only those depressions into which the dura mater passes, such as the longitudinal fissure with the falx cerebri, with the tentorium, etc. Fig. 140, 141, 143—145.

At certain places on the base of the brain, where the brain surface is separated to a greater extent than usual from the inner surface of the dura mater, the subarachnoid space is increased to form cavities, the *subarachnoid cisternae*, filled with cerebrospinal fluid. The largest of these are as follow: 1. the *cerebello-medullary cisterna* between the inferior vermis of the cerebellum and the posterior surface of the medulla oblongata, in the region of the vallecula cerebelli (see p. 237); 2. the *chiasmatic cisterna* in the region of the optic chiasma; 3. the *cisterna of the lateral cerebral fossa*, where the arachnoid bridges over the groove so named; 4. the *interpeduncular cisterna* where the arachnoid covers in the interpeduncular fossa; 5. the *cisterna of the great cerebral vein* in the transverse fissure. Fig. 143, 144, 191.

Furthermore, on the convex upper surface of the brain and especially in the neighborhood of the superior sagittal sinus, the arachnoid forms villous outgrowths which penetrate into the sinus or into its lateral lacunae. Usually these villi form dense tufts, the *arachnoidal (Pacchionian) granulations*, which cause a thinning of the dura mater and may even break through it so as to lie in corresponding depressions on the inner surfaces of the bones. Fig. 143, 145.

The Blood Vessels of the Brain.

Fig. 146. The arteries of the base of the brain. (4/5) On the right the tip of the temporal lobe, the cerebellum and the optic nerve have been removed. * = branches of the pons.

The Arteries of the Brain.

Four large arteries pass to the brain, the two *internal carotids* from the common carotids (see p. 67) and the two *vertebrals* from the subclavians (see p. 11); the corresponding arteries of the two sides, as well as the internal carotid and vertebral of the same side, are united at the base of the brain by large anastomoses.

I. The Vertebral Artery (see p. 11 and 15)

passes through the atlanto-occipital membrane (for the earlier part of its course see p. 15) into the skull, where it lies on the lateral surface of the spinal cord and medulla oblongata. It then passes upon the ventral surface and unites with its fellow of the opposite side, opposite the line of junction of the medulla oblongata and pons, to form a single trunk, the *basilar artery*. This passes over the pons in the basilar groove and at its anterior border divides into its terminal branches. Fig. 146, 147.

In addition to the *meningeal branch* (see p. 156) the vertebral gives off the following branches in its cranial portion:

1. The *posterior spinal*, small and variable, often doubled or plexiform, passes downwards on the posterior surface of the spinal cord along the posterior roots of the cervical nerves, to take part in the network formed by the spinal branches of other arteries (see p. 12, 107). Fig. 147.

2. The *anterior spinal* arises on the ventral surface of the medulla and, running downwards, unites at the level of the foramen magnum with its fellow of the opposite side to form a single stem. This runs in front of the anterior median fissure of the cord to the sacral canal, anastomosing with the spinal branches of other arteries (see p. 12, 107). Fig. 146, 147.

3. The *posterior inferior cerebellar* arises on the lateral surface of the medulla oblongata and winds around this towards the under surface of the cerebellum, to which it is distributed. Fig. 146, 147.

II. The Basilar Artery (Fig. 146, 147)

during its course over the pons gives small branches to that structure (Fig. 146) and also the following:

1. The *anterior inferior cerebellar* runs over the posterior part of the pons, in relation to the exits of the acoustic and facial nerves, to supply the anterior portions of the under surface of the cerebellum. Fig. 146, 147.

2. The *internal auditory*, small, accompanies the acoustic nerve to the internal ear. Fig. 146.

3. The *superior cerebellar* arises from the anterior end of the basilar and passes over the anterior part of the pons and along the lateral surfaces of the quadrigeminal lamina, to the dorsal surface of the cerebellum. Fig. 146, 147.

4. The *posterior cerebral*, the strong terminal branch, is separated from the preceding by the root of the oculo-motor nerve. It arches backwards, receiving the posterior communicating branch from the internal carotid, and then winds backwards and upwards to the concave under surfaces of the occipital and temporal lobes. In addition it gives slender branches to the posterior perforated substance, to the quadrigeminal lamina, to the splenium of the corpus callosum and to the chorioid plexus. Fig. 146, 147.

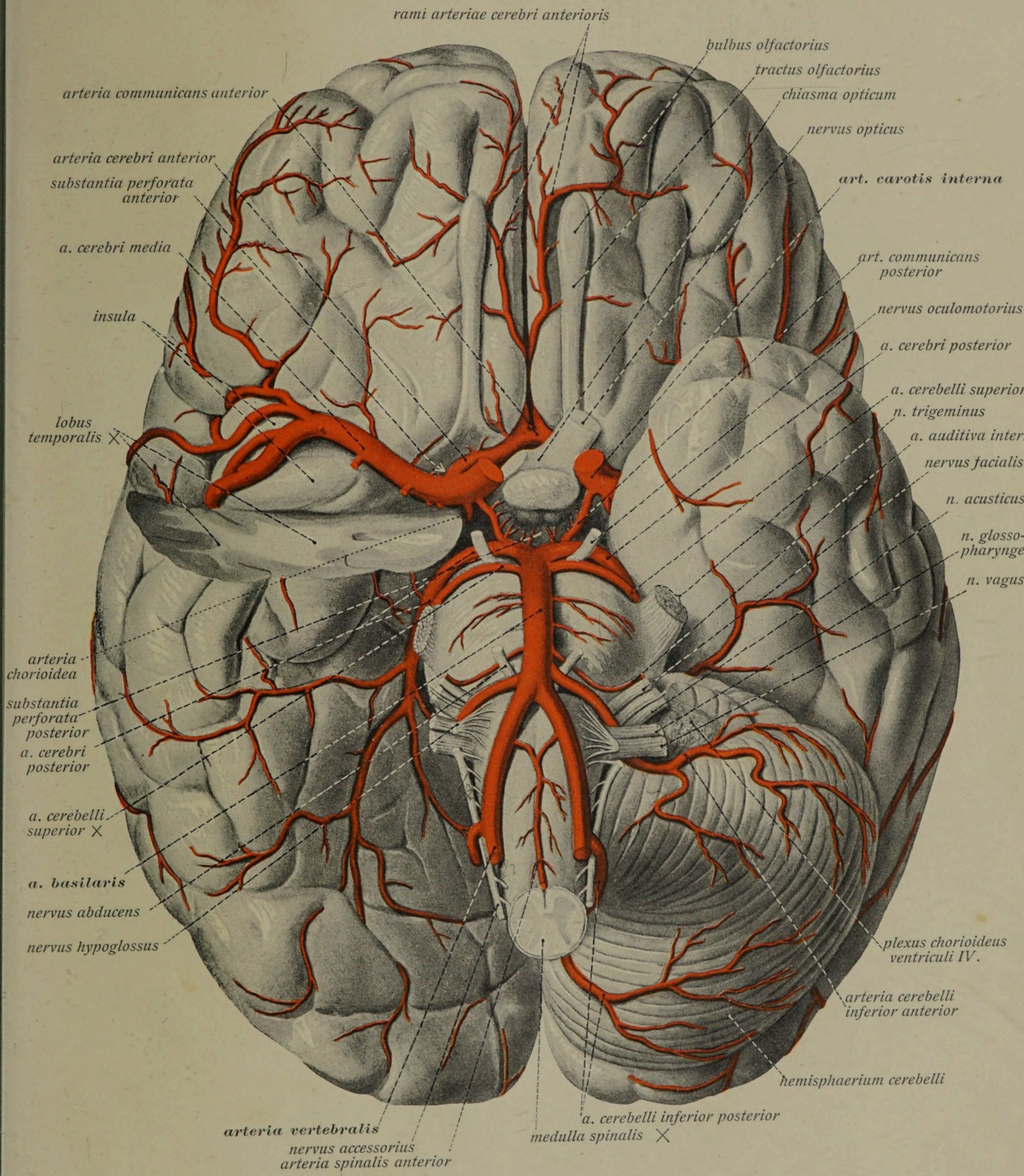
rami arteriae cerebri anterioris
bulbus olfactorius
tractus olfactorius
chiasma opticum
nervus opticus
art. carotis interna
arteria communicans anterior
arteria cerebri anterior
substantia perforata anterior
a. cerebri media
insula
lobus temporalis
art. communicans posterior
nervus oculomotorius
a. cerebri posterior
a. cerebelli superior
n. trigeminus
a. auditiva interna
nervus facialis
n. acusticus
n. glosso-pharyngeus
n. vagus
arteria chorioidea
substantia perforata posterior
a. cerebri posterior
a. cerebelli superior
a. basilaris
nervus abducens
nervus hypoglossus
plexus chorioideus ventriculi IV.
arteria cerebelli inferior anterior
hemisphaerium cerebelli
arteria vertebralis
nervus accessorius
arteria spinalis anterior
a. cerebelli inferior posterior
medulla spinalis

Fig. 146.

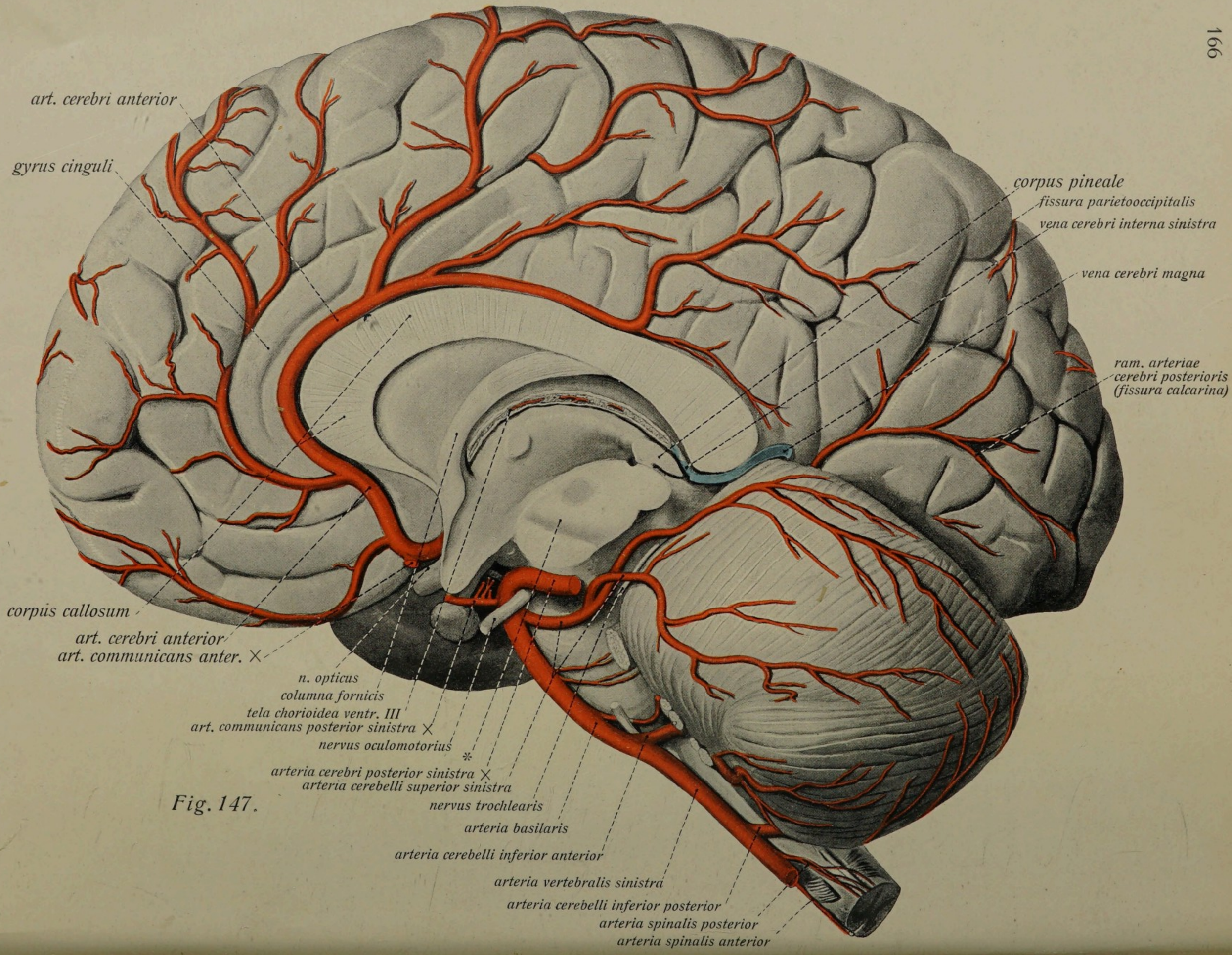

Fig. 147.

Fig. 147. The arteries of the medial surface of the cerebral hemispheres and of the upper surface of the cerebellum. (4/5) The left cerebral hemisphere has been removed by a median section through the corpus callosum, etc. and by an oblique section of the brain stem (*).

The Blood Vessels of the Brain. (Cont. from p. 164.)

III. The Internal Carotid Artery

from its origin from the common carotid runs almost straight up the neck, inclining a little backward, on the lateral wall of the pharynx. It lies anterior to the vagus nerve and the sympathetic trunk, anterior and medial to the internal jugular vein, and passes through the carotid foramen into the carotid canal in the temporal bone. It leaves this at the foramen lacerum and, lying at the side of the sella turcica and enclosed in the cavernous sinus (see p. 155), together with the nerves that pass through the superior orbital fissure, it passes upwards and forwards through the dura mater, and bends vertically upwards under the anterior clinoid process to the brain, thus describing a letter S. Fig. 56—63, 67, 69, 72, 114, 138, 139, 146, 147. Except for a *carotico-tympanic* branch given off in the carotid canal, the artery gives off in the skull only the following branches:

1. The *ophthalmic*, see p. 75.

2. The *posterior communicating* runs past the infundibulum and corpora mamillaria to the posterior cerebral artery (see p. 164). Fig. 146, 147.

3. The *chorioid* passes along the optic tract to the medial side of the hippocampal gyrus and into the inferior cornu of the lateral ventricle to the chorioid plexus. Fig. 146 (not labelled), 163, 164, 166.

4. The *anterior cerebral* passes above and in front of the optic chiasma towards the longitudinal cerebral fissure. Before reaching this it anastomoses with the artery of the opposite side by a short but wide transverse branch, the *anterior communicating*, and then runs in the longitudinal fissure immediately above the corpus callosum to the medial surface of the cerebral hemisphere. Fig. 146, 147. The anterior communicating branch completes the *arterial circle (Circle of Willis)* at the base of the brain.

5. The *middle cerebral*, the largest branch, runs in the lateral cerebral fissure and is distributed to the neighboring gyri of the temporal, frontal and parietal lobes and to the insula. Fig. 146, 147.

The Cerebral Veins.

1. The *superior cerebral veins* for the most part accompany the branches of the anterior and middle cerebral arteries, and open into the superior sagittal sinus, frequently into its lateral lacunae. Fig. 136, 137, 143.

2. The *middle cerebral vein* corresponds to a small part of the middle cerebral artery, and opens into the cavernous sinus.

3. The *inferior cerebral veins*, correspond mainly to the branches of the basal cerebral arteries, and open into the superior petrosal sinuses or into the transverse sinus. Fig. 135, 136.

4. The *superior* and *inferior cerebellar veins* open into the straight and transverse sinuses.

5. The *internal cerebral veins*, situated in the tela chorioidea of the third ventricle, form the large stem, the *great cerebral vein (Galeni)*, which runs through the transverse cerebral fissure to the straight sinus. Fig. 147, 167, 168. They arise from the *chorioid veins*, the *terminal veins* and the *vein of the septum pellucidum*.

Fig. 147. The arteries of the medial surface of the cerebral hemispheres and of the upper surface of the cerebellum. ($^4/_5$) The left cerebral hemisphere has been removed by a median section through the corpus callosum, etc. and by an oblique section of the brain stem (*).

Fig. 148. The base of the brain, showing the emergence of the twelve pairs of cranial nerves. ($^4/_5$) On the left the whole semilunar ganglion is retained. The hypophysis is drawn somewhat backwards, to show the infundibulum. The roman numerals denote the cranial nerves.

The Base of the Brain.

The anterior part of the base of the brain is formed by the frontal lobes of the cerebral hemispheres, separated from one another by the *longitudinal cerebral fissure*. Its mostly concave surface shows *orbital gyri* and *sulci* and, parallel to the longitudinal fissure, the *olfactory sulcus*, in which lies the *olfactory tract* with its terminal *olfactory bulb*, to which branches of the first or olfactory nerve pass from the nasal cavity. The anterior end of the frontal lobe is termed the *frontal pole*.

Behind the longitudinal fissure is a series of structures which form the floor of the third ventricle, the *hypothalamus*. These are the *optic chiasma*, formed by the decussation of the *optic tracts*; from it arise the *optic nerves*. On either side of the chiasma is an area with numerous small openings for blood vessels, the *anterior perforated substance*, at the anterior border of which the olfactory tract arises by several roots. Behind the chiasma is a hollow stalk, the *infundibulum*, at the end of which is the oval *hypophysis*. The infundibulum is attached above to a soft grey mass, the *tuber cinereum*. Behind this, close to the median line, are two small white bodies, the *corpora mamillaria*, and behind these a depression, the *interpeduncular fossa*, between the two cerebral peduncles. From this arises on either side, near the middle line, the third nerve, the *oculo-motor*. The *cerebral peduncles* are masses of white fibers that issue from the pons; they diverge anteriorly and show distinct longitudinal furrows.

On either side of these structures is the anterior end of a *temporal lobe*, whose tip is termed the *temporal pole*; it appears to be bent around like a hook into the *uncus*, which extends forwards to the optic chiasma and largely covers in the brain stem, approaching to within 1 cm. of the median line.

Behind the corpora mamillaria and the interpeduncular fossa is the broad, white surface of the *pons*. In the groove between it and the uncus the fourth nerve, the *trochlear*, comes into view, curving around the brain stem. From the lateral part of the pons the *trigeminal nerve* arises by a broad sensory *portio major* and a smaller motor *portio minor*, which crosses obliquely over the sensory portion. This forms a broad *semilunar (Gasserian) ganglion*, situated between the two layers of the dura mater at the anterior border of the tentorium, close to the cavernous sinus (see Fig. 60).

At the posterior border of the pons, in the groove between it and the medulla oblongata, the sixth nerve, *abducens*, arises close to the median line. At the posterior border of the lateral part of the pons, the *brachium pontis*, passing to the cerebellum, are the origins of the seventh, *facial*, and eighth, *acoustic*, nerves and the *intermediate nerve* lying on the acoustic.

Behind the pons comes the *medulla oblongata*, which passes over into the spinal cord at the *decussation of the pyramids*. From the medulla oblongata arise, between the pyramid and the olive, the root-fibres of the *hypoglossal nerve (XII)* and farther laterally the ninth and tenth nerves, the *glosso-pharyngeal* and *vagus*, while the eleventh, the *accessory*, passes into the skull cavity through the foramen magnum, but receives roots from the medulla oblongata below the vagus.

On either side of the medulla oblongata lie the cerebellar hemispheres and beside and partly behind these the *occipital lobes* of the cerebral hemispheres, with the *occipital poles*.

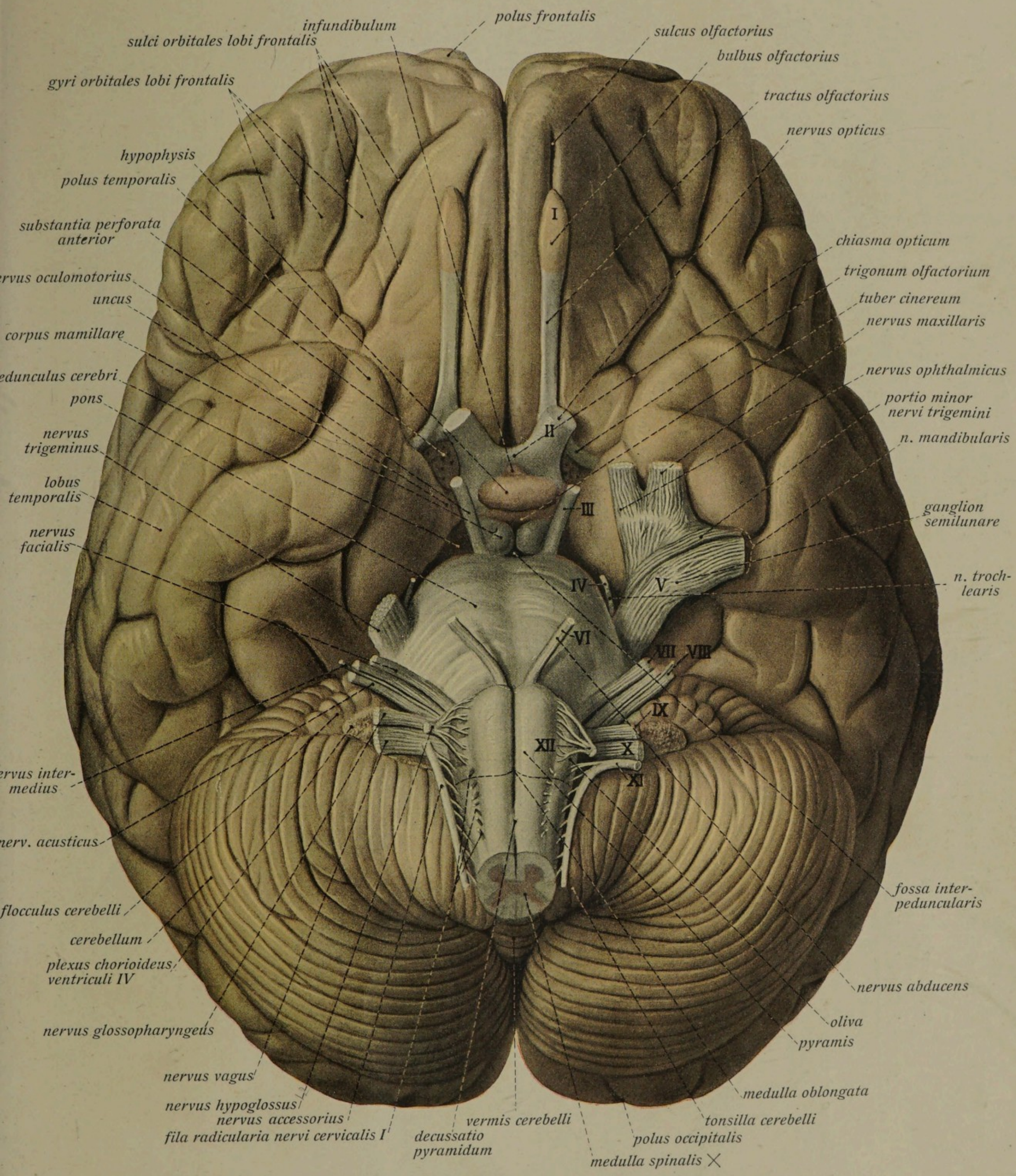
infundibulum
polus frontalis
sulci orbitales lobi frontalis
sulcus olfactorius
bulbus olfactorius
gyri orbitales lobi frontalis
tractus olfactorius
nervus opticus
hypophysis
polus temporalis
substantia perforata anterior
chiasma opticum
trigonum olfactorium
tuber cinereum
nervus maxillaris
nervus ophthalmicus
portio minor nervi trigemini
n. mandibularis
ganglion semilunare
n. trochlearis
uncus
corpus mamillare
pons
nervus trigeminus
lobus temporalis
nervus facialis
fossa interpeduncularis
nervus abducens
oliva
pyramis
medulla oblongata
tonsilla cerebelli
polus occipitalis
vermis cerebelli
decussatio pyramidum
medulla spinalis
nervus hypoglossus
nervus accessorius
fila radicularia nervi cervicalis I
nervus vagus
nervus glossopharyngeus
plexus chorioideus ventriculi IV
cerebellum
flocculus cerebelli
nerv. acusticus
nervus intermedius
I
II
III
IV
V
VI
VII
VIII
IX
X
XI
XII

Fig. 148.

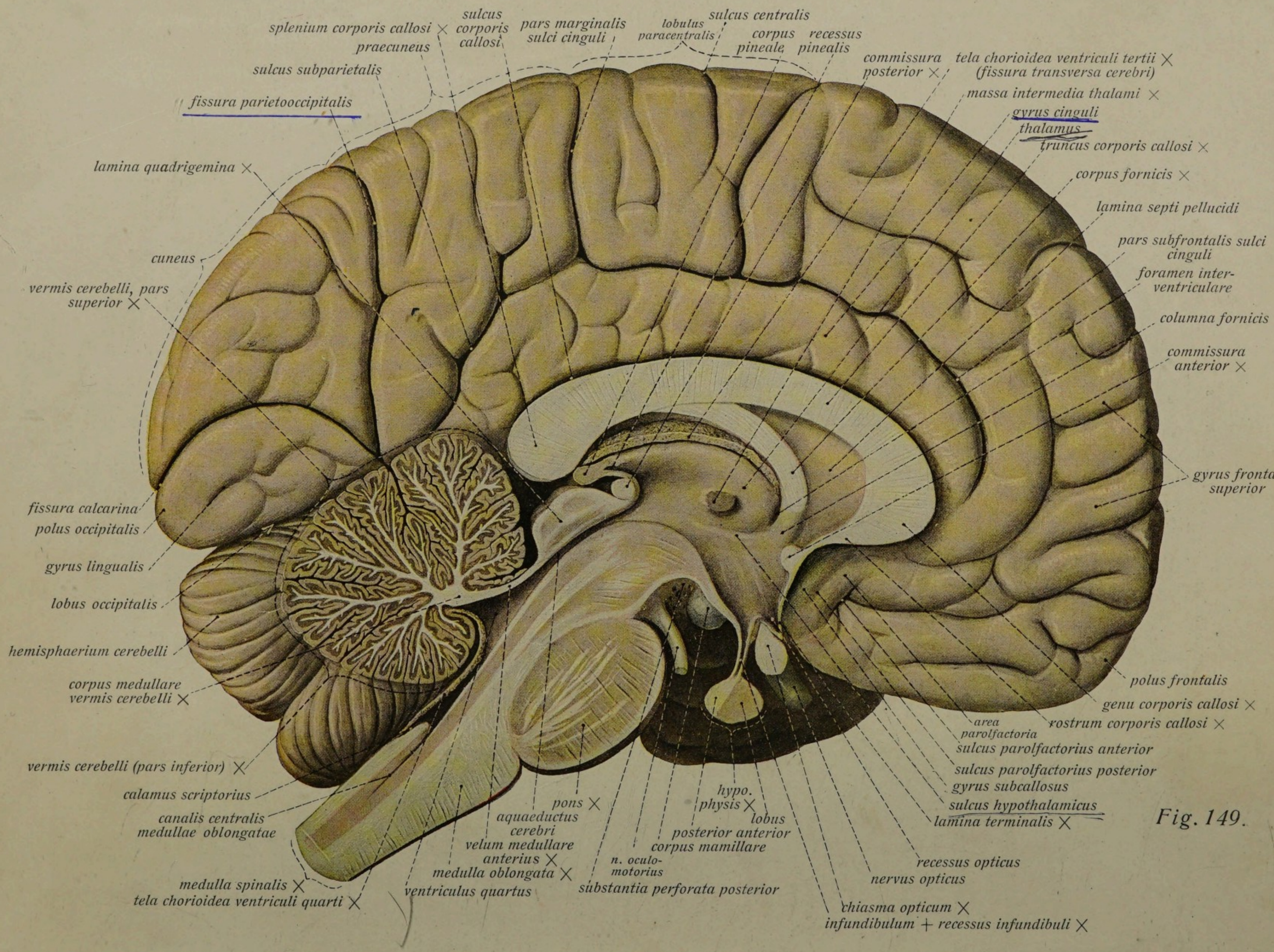
splenium corporis callosi ×
praecuneus
sulcus corporis callosi
pars marginalis sulci cinguli
lobulus paracentralis
sulcus centralis
corpus pineale
recessus pinealis
commissura posterior ×
tela chorioidea ventriculi tertii × (fissura transversa cerebri)
massa intermedia thalami ×
gyrus cinguli
thalamus
truncus corporis callosi ×
corpus fornicis ×
lamina septi pellucidi
pars subfrontalis sulci cinguli
foramen interventriculare
columna fornicis
commissura anterior ×
gyrus frontalis superior
polus frontalis
genu corporis callosi ×
rostrum corporis callosi ×
area parolfactoria
sulcus parolfactorius anterior
sulcus parolfactorius posterior
gyrus subcallosus
sulcus hypothalamicus
lamina terminalis ×
recessus opticus
nervus opticus
chiasma opticum ×
infundibulum + recessus infundibuli ×
hypophysis ×
lobus posterior anterior
corpus mamillare
n. oculomotorius
substantia perforata posterior
pons ×
aquaeductus cerebri
velum medullare anterius ×
medulla oblongata ×
ventriculus quartus
medulla spinalis ×
tela chorioidea ventriculi quarti ×
calamus scriptorius
canalis centralis medullae oblongatae
vermis cerebelli (pars inferior) ×
corpus medullare vermis cerebelli ×
hemisphaerium cerebelli
lobus occipitalis
gyrus lingualis
polus occipitalis
fissura calcarina
vermis cerebelli, pars superior ×
cuneus
lamina quadrigemina ×
fissura parietooccipitalis
sulcus subparietalis

Fig. 149.

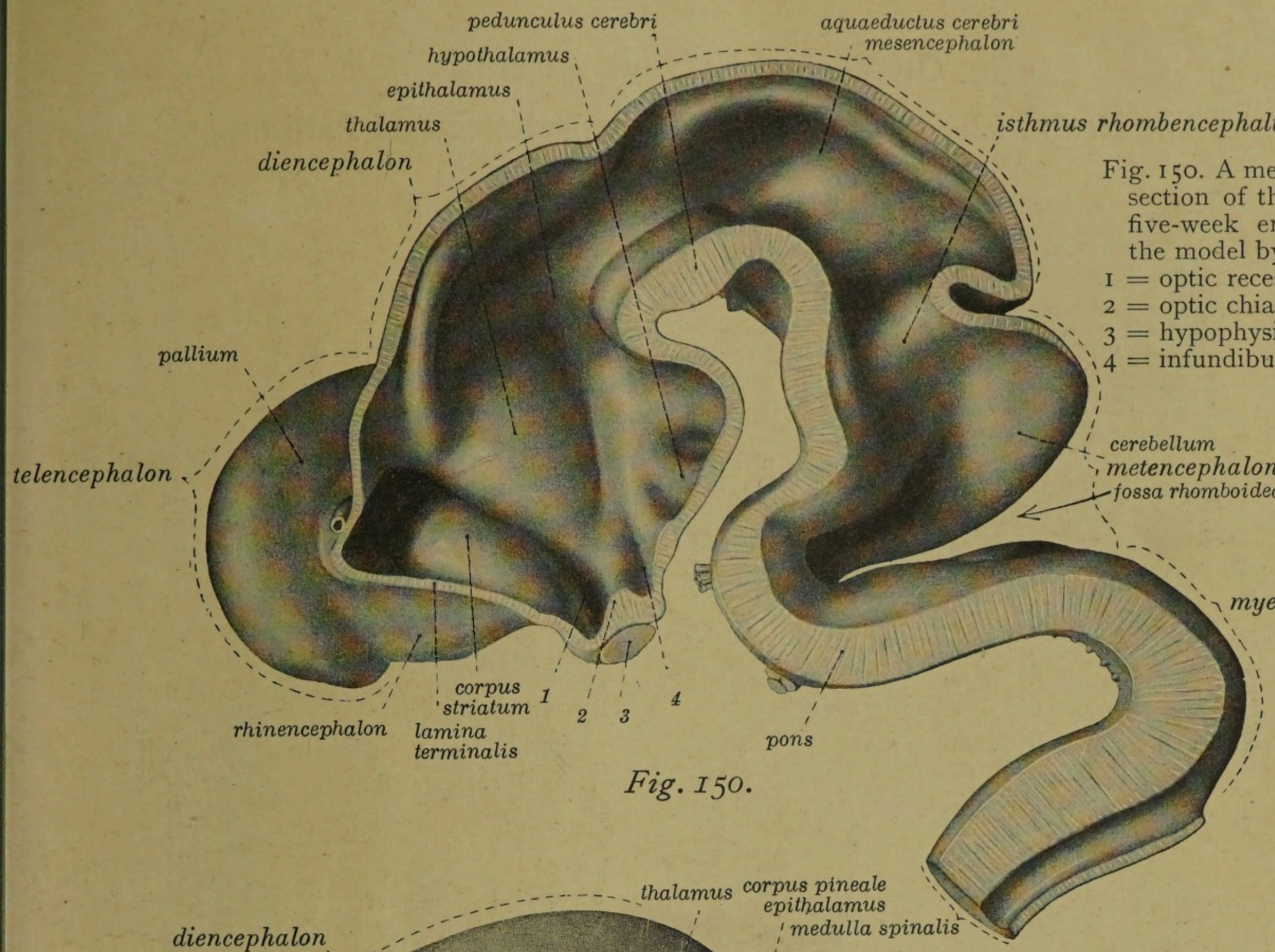

Fig. 150. A median sagittal section of the brain of a five-week embryo (after the model by W. His).
1 = optic recess;
2 = optic chiasma;
3 = hypophysis;
4 = infundibular recess.

Fig. 150.

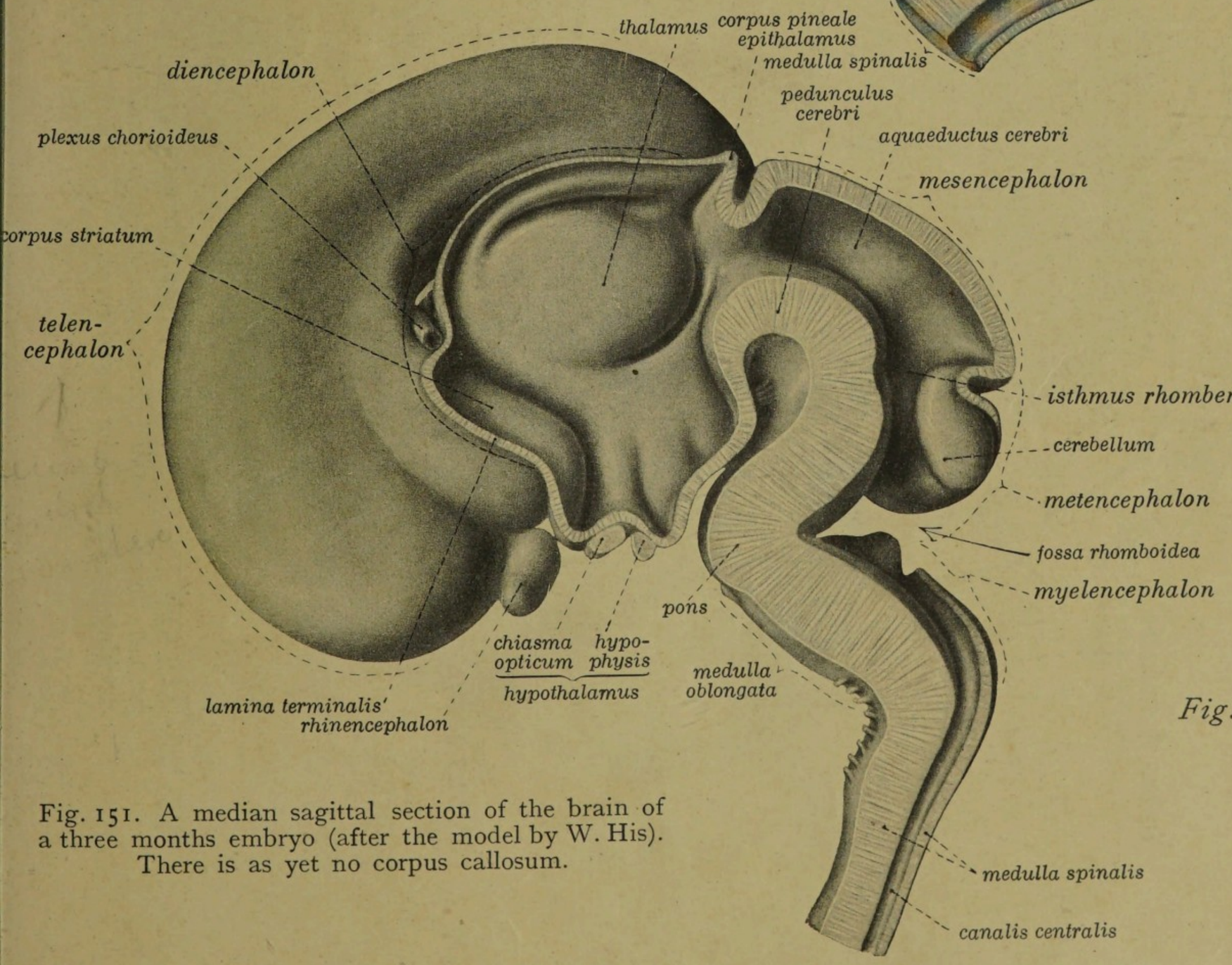

Fig. 151. A median sagittal section of the brain of a three months embryo (after the model by W. His). There is as yet no corpus callosum.

Fig. 151.

The Central Nervous System.

The Brain. (Cont.) The Cerebral Hemispheres and Pallium.

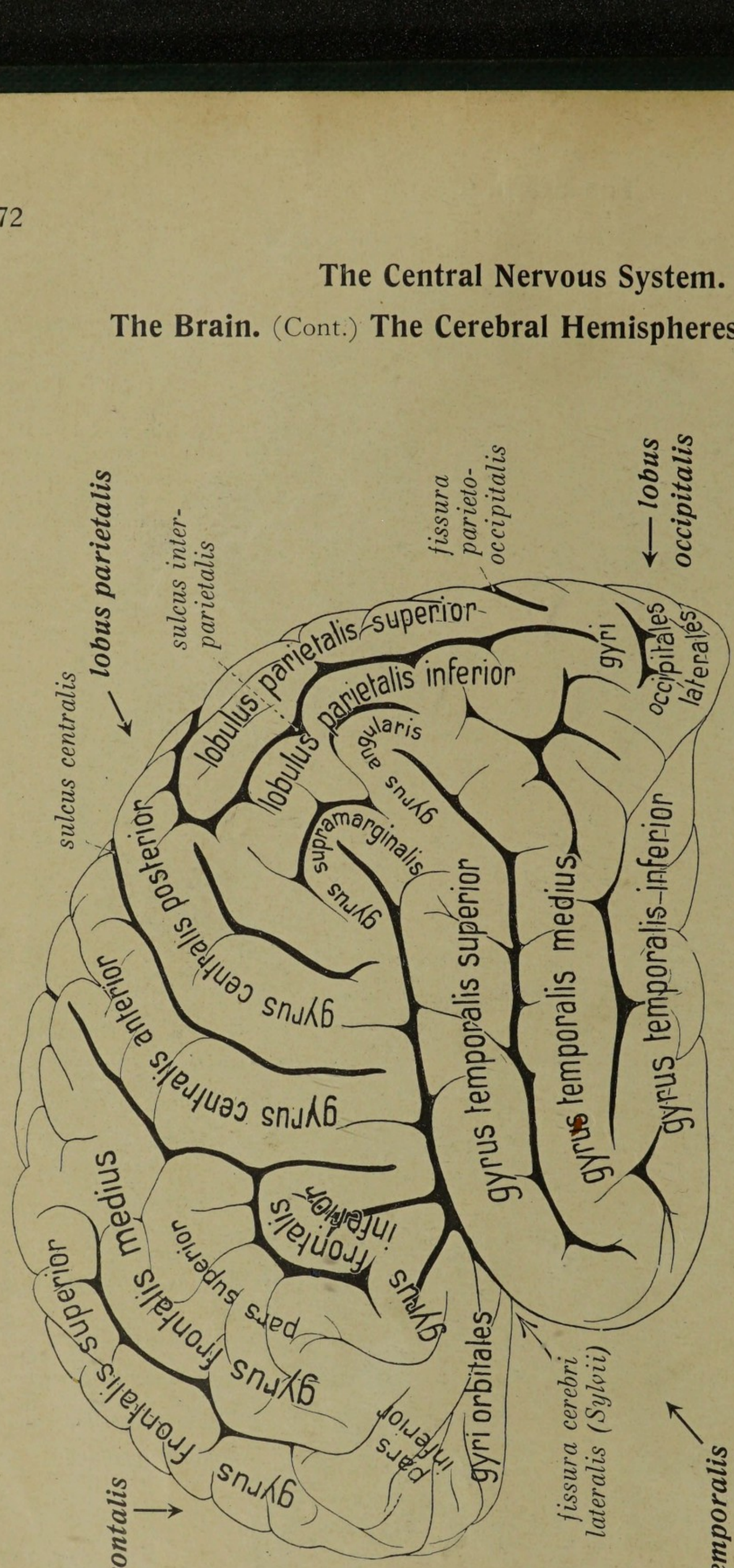

Fig. 152. Explanation of Fig. 153.

Fig. 153. The gyri and sulci of the cerebral hemispheres from the left side. The cerebellum and brain stem have been removed. 1, behind the interparietal sulcus indicates the oblique portion of the sulcus, 2, the transverse limb marking out the posterior central gyrus.

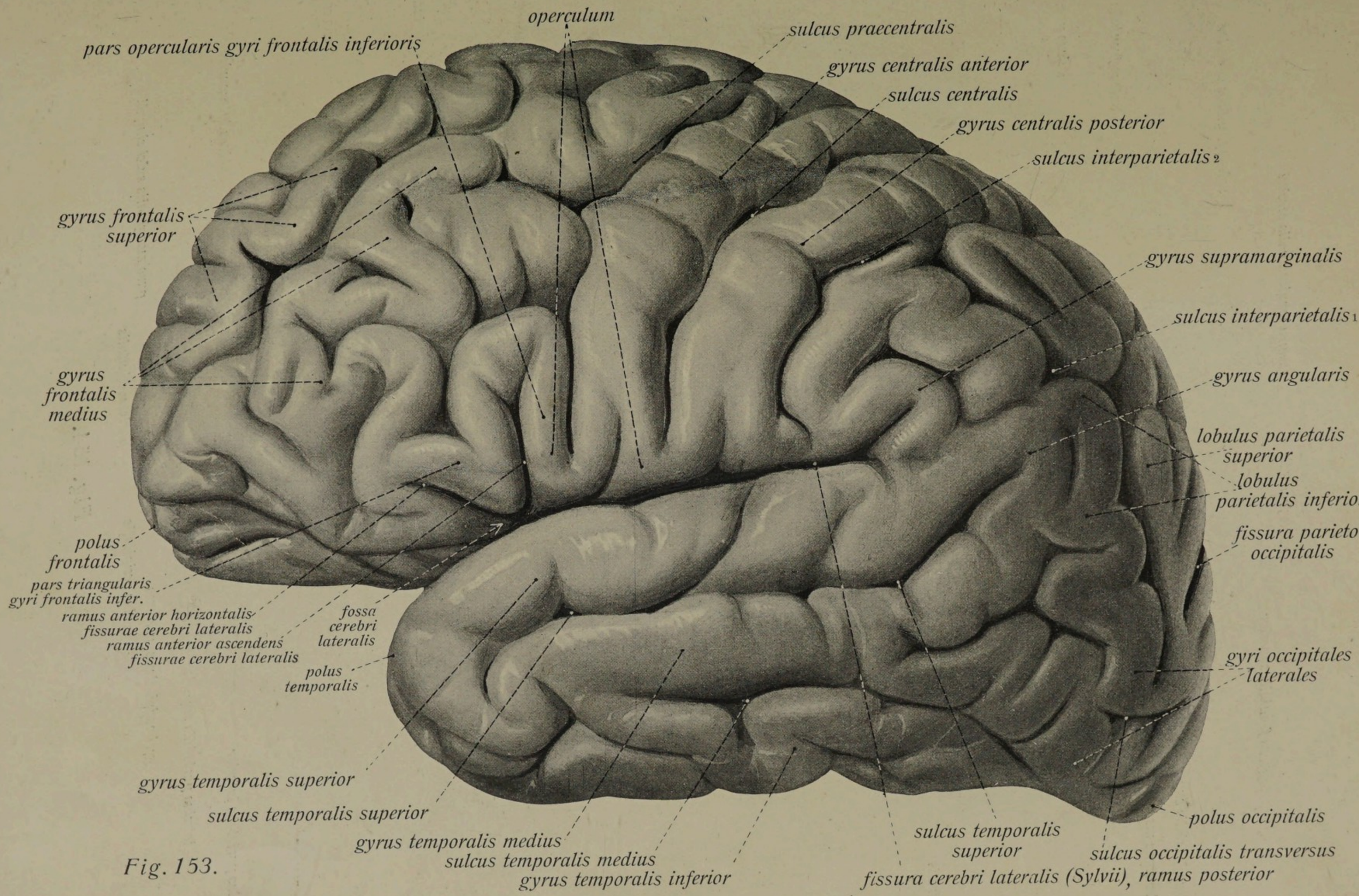
operculum
pars opercularis gyri frontalis inferioris
sulcus praecentralis
gyrus centralis anterior
sulcus centralis
gyrus centralis posterior
sulcus interparietalis 2
gyrus frontalis superior
gyrus supramarginalis
sulcus interparietalis 1
gyrus frontalis medius
gyrus angularis
lobulus parietalis superior
lobulus parietalis inferior
fissura parieto-occipitalis
polus frontalis
pars triangularis gyri frontalis infer.
ramus anterior horizontalis fissurae cerebri lateralis
ramus anterior ascendens fissurae cerebri lateralis
fossa cerebri lateralis
polus temporalis
gyri occipitales laterales
gyrus temporalis superior
sulcus temporalis superior
gyrus temporalis medius
sulcus temporalis medius
gyrus temporalis inferior
sulcus temporalis superior
polus occipitalis
sulcus occipitalis transversus
fissura cerebri lateralis (Sylvii), ramus posterior

Fig. 153.

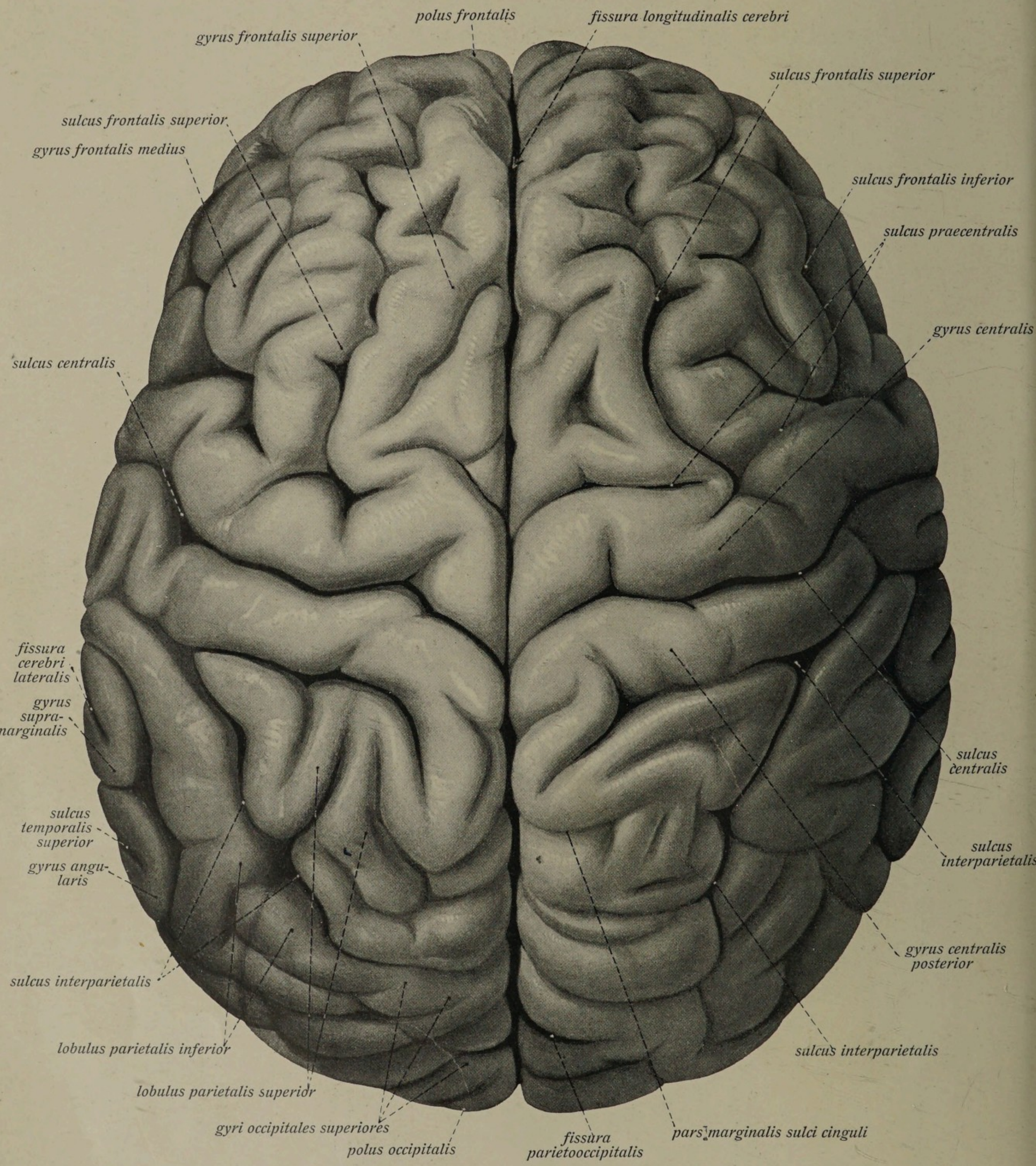
polus frontalis
fissura longitudinalis cerebri
gyrus frontalis superior
sulcus frontalis superior
sulcus frontalis superior
gyrus frontalis medius
sulcus frontalis inferior
sulcus praecentralis
gyrus centralis
sulcus centralis
fissura cerebri lateralis
gyrus supra-marginalis
sulcus centralis
sulcus temporalis superior
gyrus angularis
sulcus interparietalis
gyrus centralis posterior
sulcus interparietalis
lobulus parietalis inferior
sulcus interparietalis
lobulus parietalis superior
gyri occipitales superiores
fissura parietooccipitalis
pars marginalis sulci cinguli
polus occipitalis

Fig. 154.

The Central Nervous System.

The Brain. (Cont.) The Cerebral Hemispheres and Pallium.

Fig. 154. The gyri and sulci of the cerebral hemispheres from above.

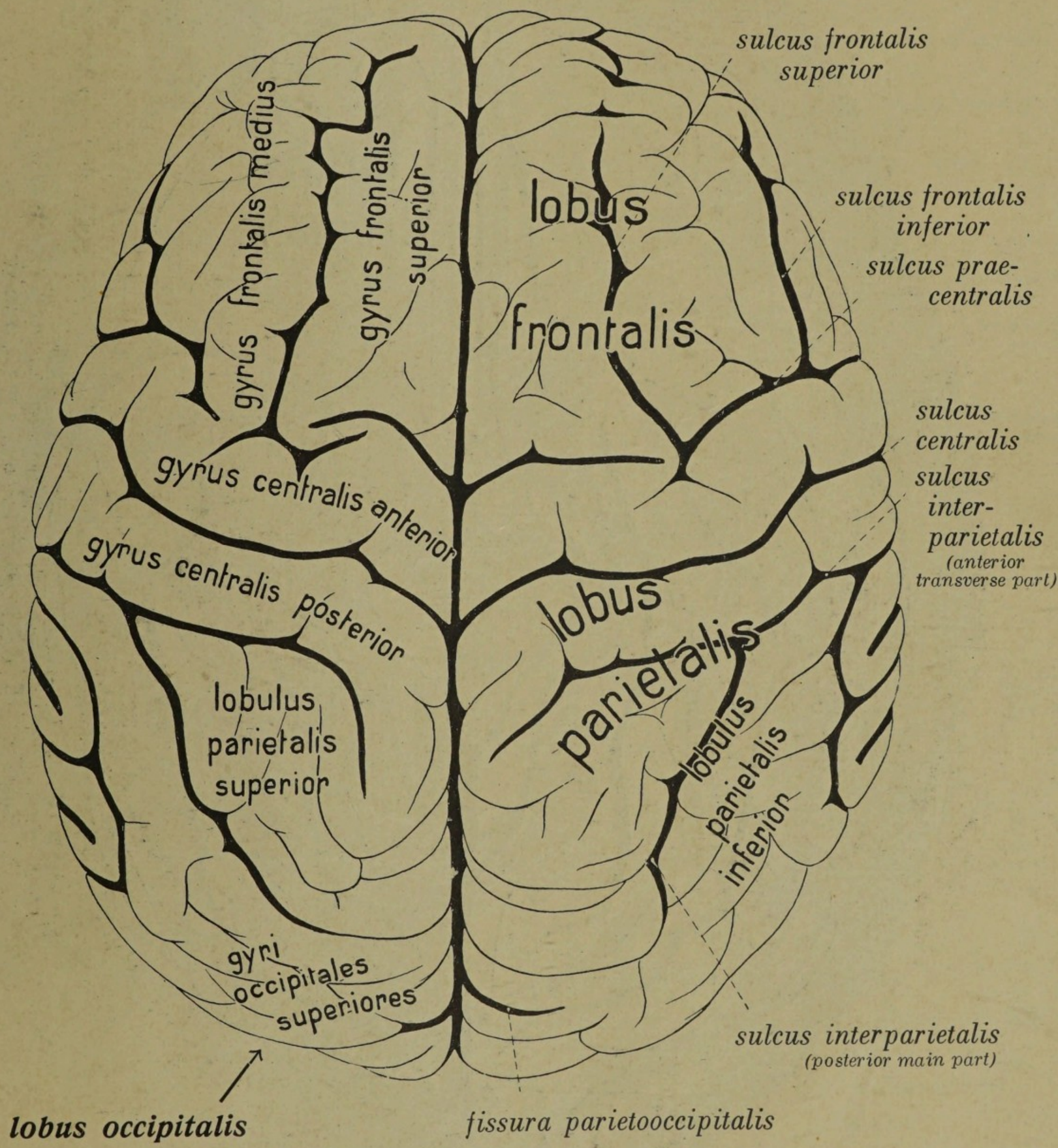

Fig. 155. Explanation of Fig. 154.

The Central Nervous System.

The Brain. (Cont.) The Cerebral Hemispheres and Pallium.

Fig. 157. The gyri and sulci of the cerebral hemispheres from the basal surface.
The brain stem and cerebellum are removed.

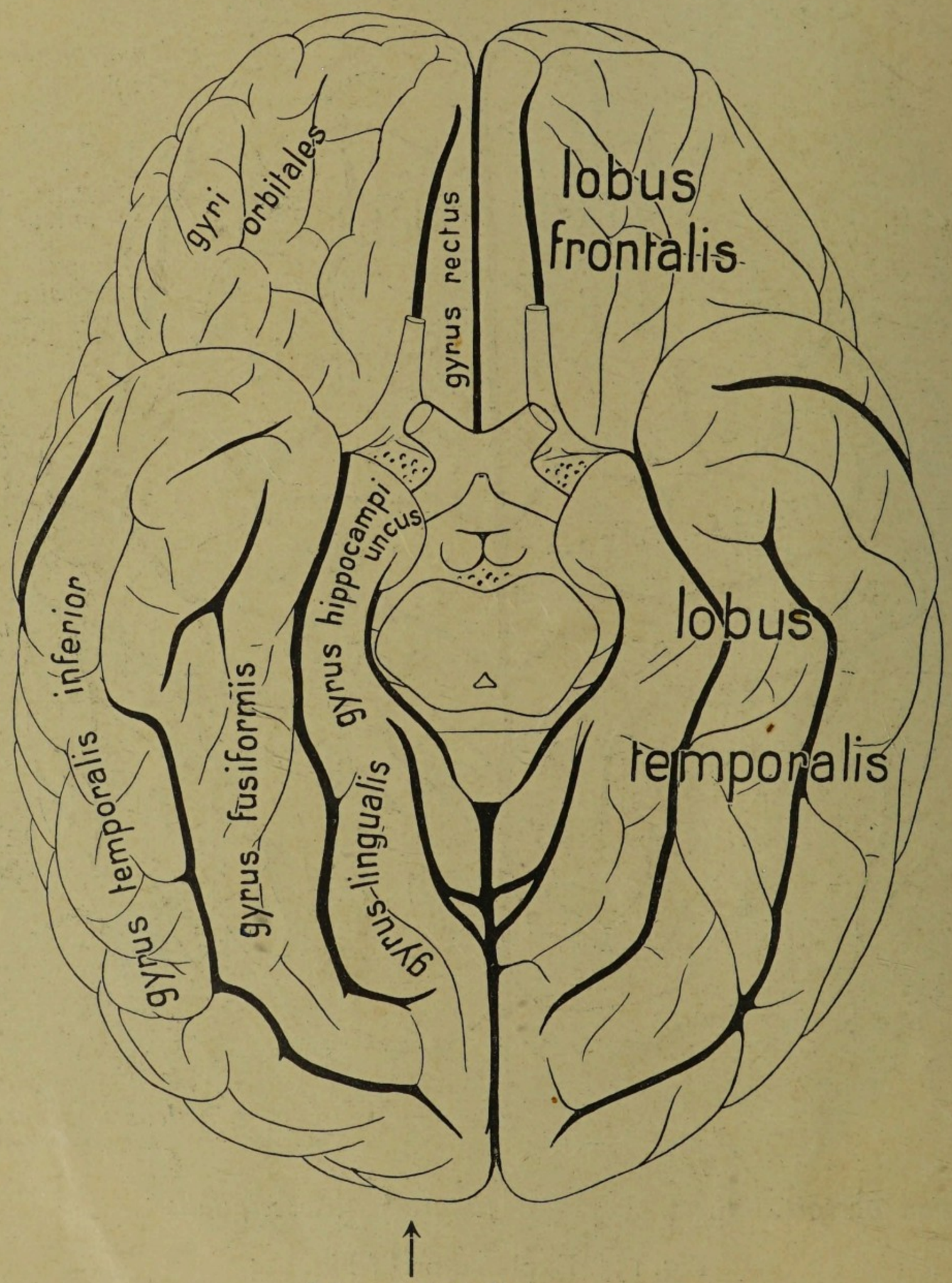

lobus occipitalis

Fig. 156. Explanation of Fig. 157.

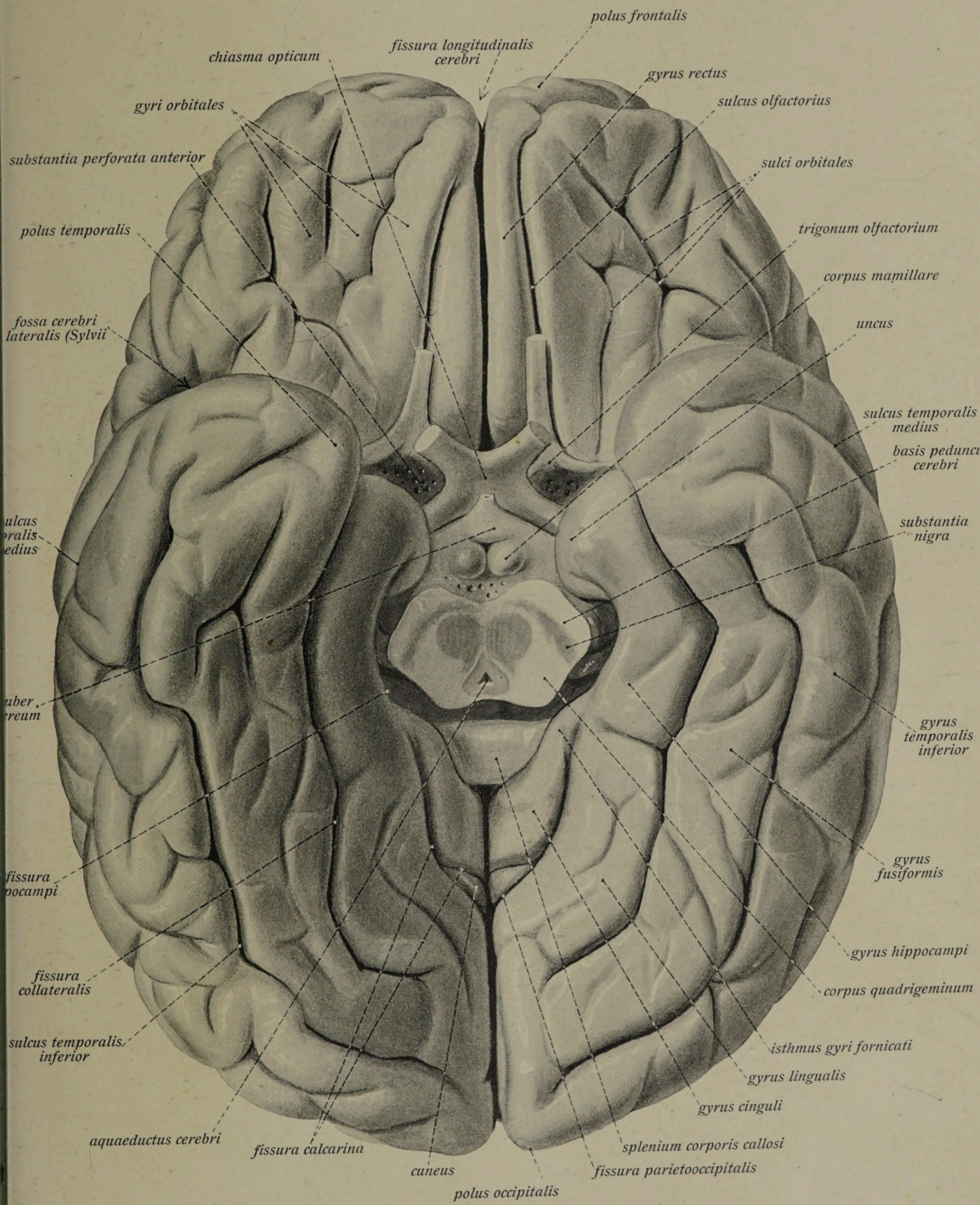
polus frontalis
fissura longitudinalis cerebri
chiasma opticum
gyrus rectus
gyri orbitales
sulcus olfactorius
substantia perforata anterior
sulci orbitales
polus temporalis
trigonum olfactorium
corpus mamillare
fossa cerebri lateralis (Sylvii
uncus
sulcus temporalis medius
basis pedunculi cerebri
substantia nigra
gyrus temporalis inferior
gyrus fusiformis
gyrus hippocampi
corpus quadrigeminum
isthmus gyri fornicati
gyrus lingualis
gyrus cinguli
splenium corporis callosi
fissura parietooccipitalis
polus occipitalis
cuneus
fissura calcarina
aquaeductus cerebri
sulcus temporalis inferior
fissura collateralis

Fig. 157.

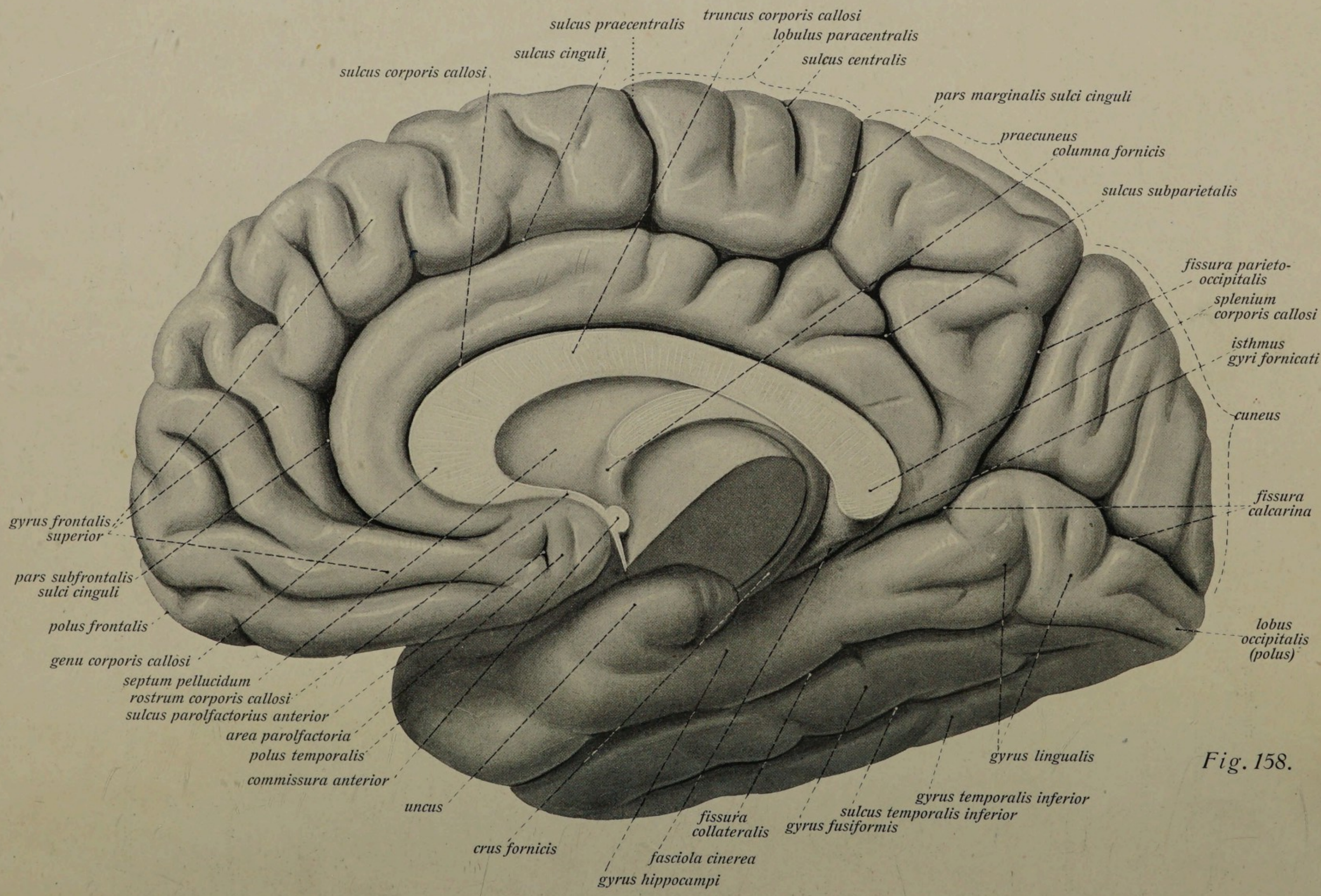

Fig. 158.

Fig. 158. The gyri and sulci of the cerebral hemispheres, the medial surface. The brain is divided in the median line and the brain stem, and cerebellum removed by an oblique cut passing through the thalamus.

Fig. 158. The gyri and sulci of the cerebral hemispheres, the medial surface. The brain is divided in the median line and the brain stem, and cerebellum removed by an oblique cut passing through the thalamus.

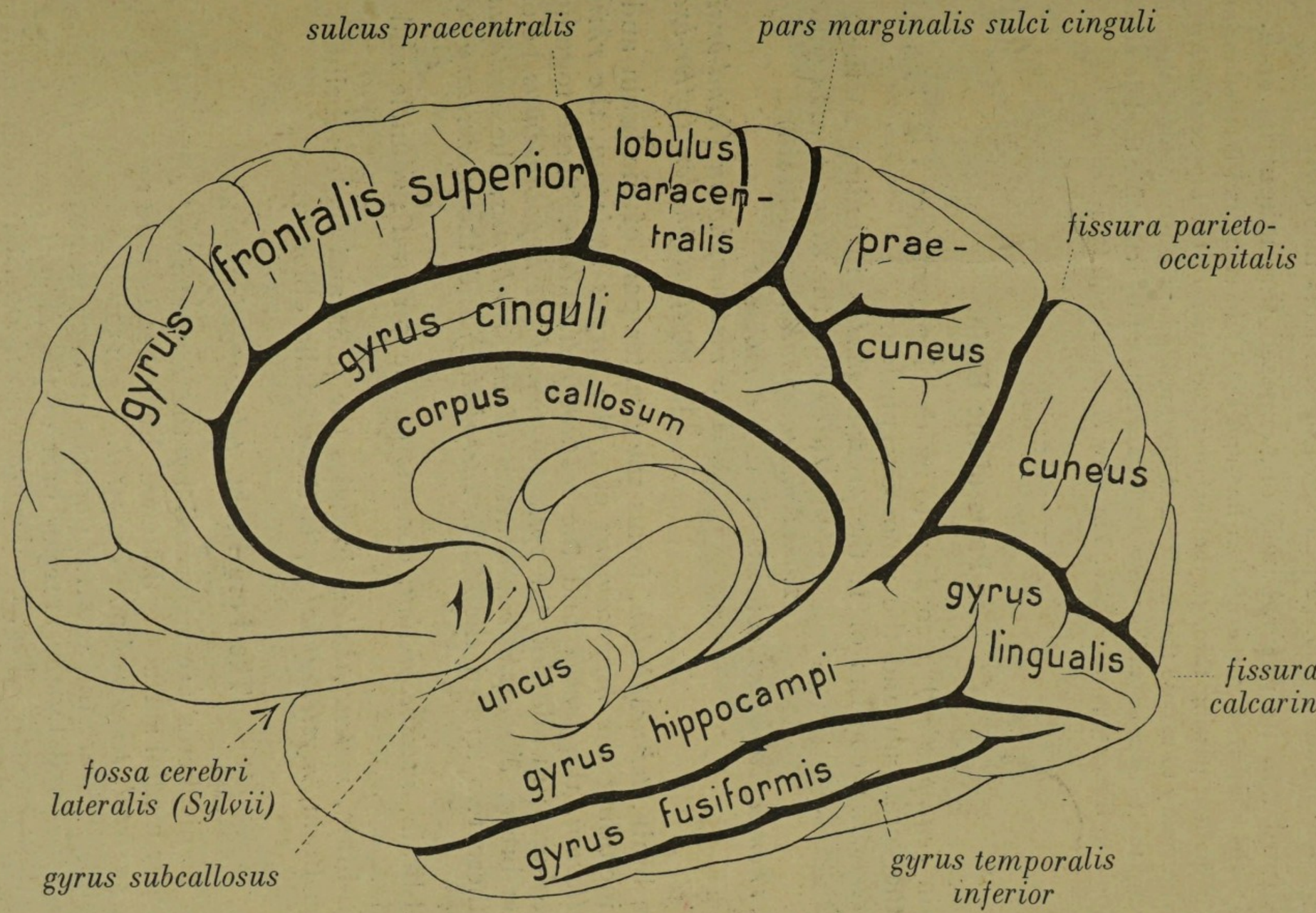

Fig. 159. Explanation of Fig. 158.

The Central Nervous System.

The Brain. (Cont.) The Cerebral Hemispheres.

Fig. 160. The pallium from the right side. The gyri of the insula are exposed by cutting away the portions of the frontal, parietal and temporal lobes that cover them.

Fig. 161. The fornix, in its natural position, exposed throughout its entire length. The brain is divided in the median line and the brain stem and cerebellum are removed by an oblique cut passing through the thalamus; so much of the hippocampal gyrus is removed as is necessary to expose the fimbria and dentate fascia; the pars tecta of the piliars of the fornix and the thalamo-mamillary fasciculus are exposed by removing the lateral wall of the third ventricle to the corpus mamillare. The view is medial and from below.

The Parts of the Brain.

The brain *(encephalon)* according to its development (see Fig. 150, 151), may be divided into the cerebrum and the rhombencephalon.

I. The *cerebrum* consists of 1. the *prosencephalon* including a) the *telencephalon (fore-brain)* and the *diencephalon* (interbrain).
2. *the mesencephalon* (mid-brain)

II. The *rhombencephalon* consists of 1. the *isthmus*
2. The *metencephalon (hind-brain)*
3. The *myelencephalon (after-brain)*

The fore brain, *telencephalon*, forms the greater part of the brain and consists of the *pallium*, including the *hippocampus* etc., the *corpus striatum*, the *rhinencephalon*, the *corpus callosum*, the *fornix* and the *septum pellucidum*. These together form the cerebral hemispheres; in addition the *optic portion of the hypothalamus* belongs to it.

The inter-brain, *diencephalon*, consists of the *thalamus*, the *metathalamus*, the *epithalamus* (these two termed the *thalamencephalon*) and the *mamillary portion of the hypothalamus*.

The mid-brain, *mesencephalon*, consists of the cerebral peduncle and the quadrigeminal lamina.

The hind-brain, *metencephalon*, includes the pons and the cerebellum.

The after-brain, *myelencephalon*, is the medulla oblongata.

The Fore Brain, *telencephalon*.

The two hemispheres are separated by the *longitudinal cerebral fissure* and the falx cerebri. Their medial surface is flattened. Each hemisphere may be divided into four lobes, *frontal*, *parietal*, *temporal* and *occipital*. Fig. 152—159.

The frontal lobes are the anterior portions of each hemisphere, forming its *frontal pole*. They are separated by the anterior part of the *lateral cerebral fissure (fissure of Sylvius)* from the temporal lobes; by the *praecentral sulcus* from the parietal lobes; by the *sulcus cinguli* from the gyrus cinguli; and by the *anterior parolfactory sulcus* from the parolfactory area. Fig. 152—159.

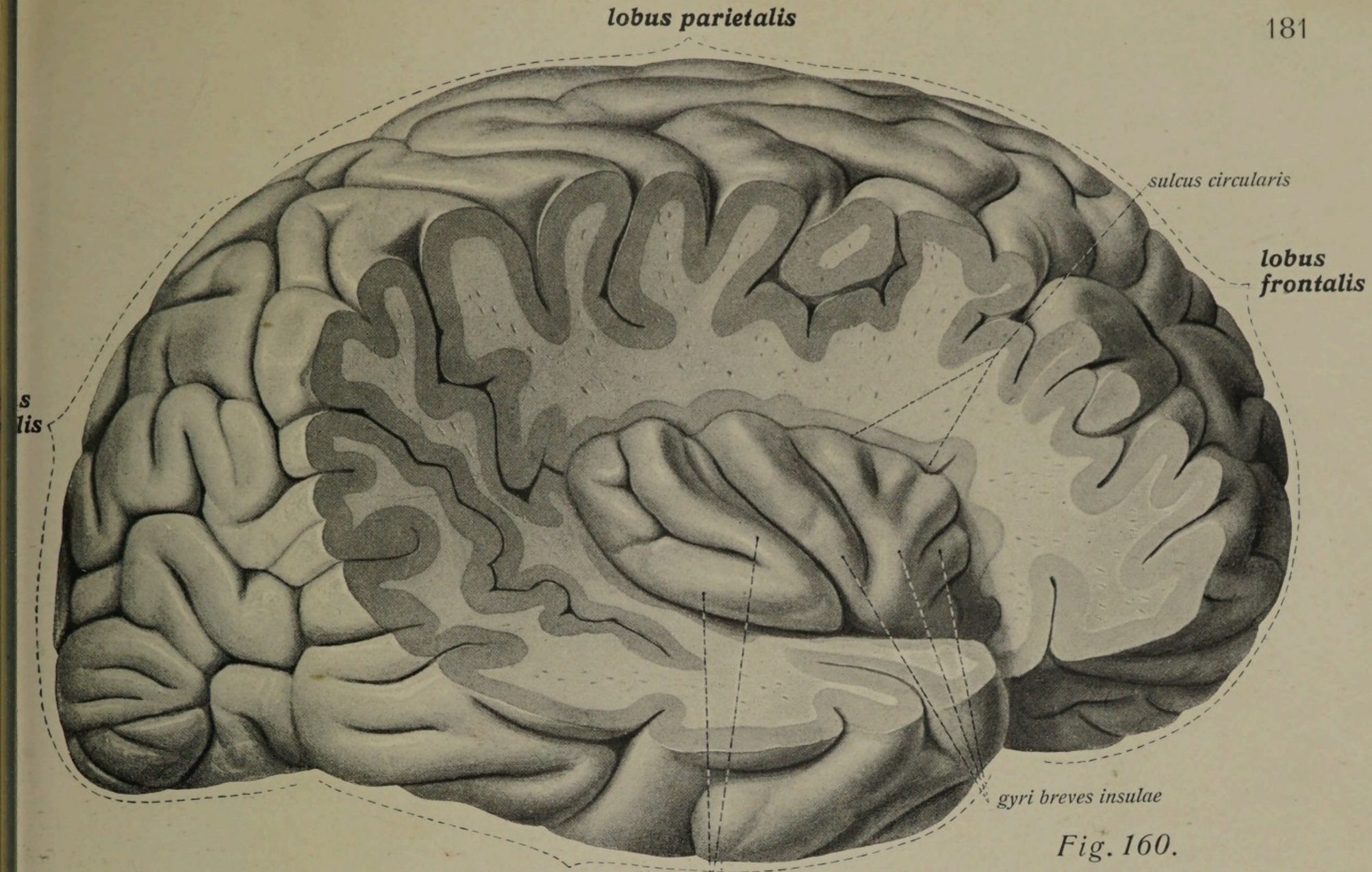

Fig. 160.

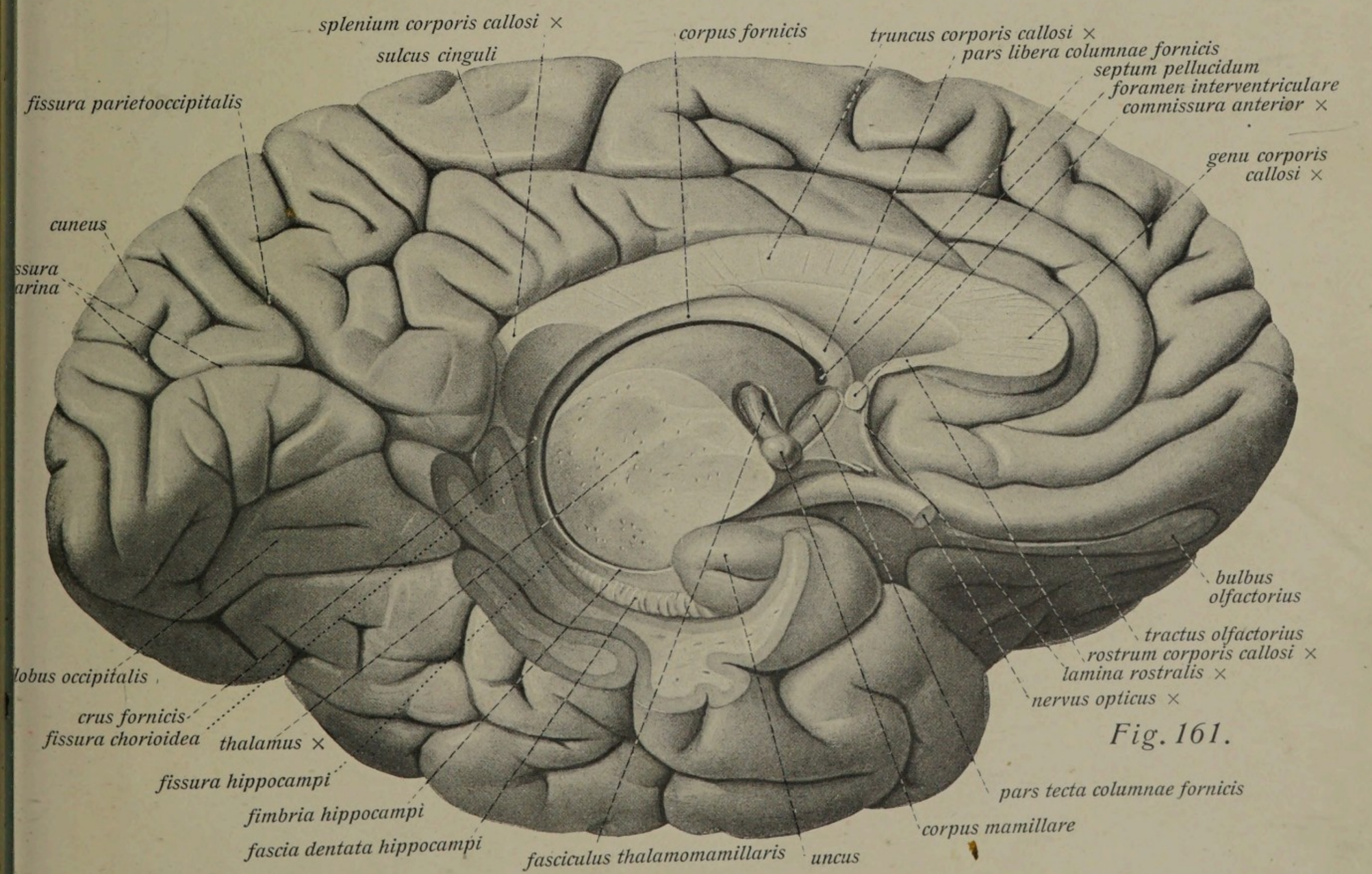

Fig. 161.

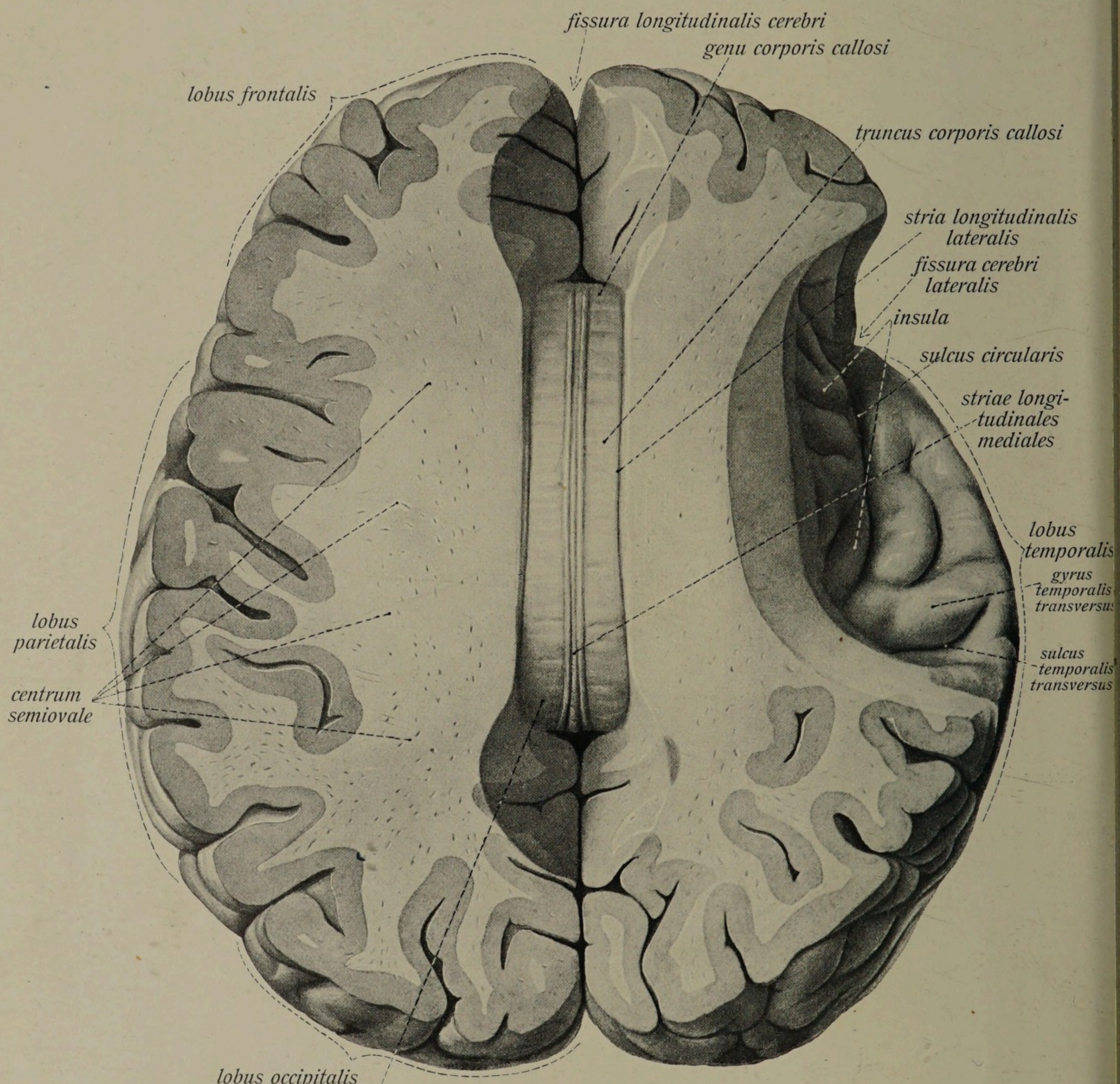
fissura longitudinalis cerebri
genu corporis callosi
lobus frontalis
truncus corporis callosi
stria longitudinalis lateralis
fissura cerebri lateralis
insula
sulcus circularis
striae longitudinales mediales
lobus temporalis
gyrus temporalis transversus
sulcus temporalis transversus
lobus parietalis
centrum semiovale
lobus occipitalis
splenium corporis callosi

Fig. 162.

The Central Nervous System.

The Brain. (Cont.) The Cerebral Hemispheres. (Cont.)

Fig. 162. The corpus callosum from above. The cerebral hemispheres are cut away to the level of the centrum semiovale; on the right the insula is exposed; anteriorly and posteriorly a certain amount of brain tissue has been removed to show the genu and splenium of the corpus callosum.

The **frontal lobe** consists of the *orbital gyri*, the *gyrus rectus*, and the *superior*, *middle* and *inferior frontal gyri*. The last of these is divided by the *anterior horizontal* and *anterior ascending branches* of the lateral cerebral fissure into *opercular*, *triangular* and *orbital* portions. The sulci are the *orbital*, *olfactory*, *superior* and *inferior frontal*. Fig. 152—159.

The **parietal lobe** forms the middle portion of the cerebral hemisphere and is separated from the temporal lobe by the *posterior branch* of the lateral cerebral fissure, from the frontal lobe by the *praecentral sulcus* and from the occipital lobe by the *parieto-occipital fissure*, this last boundary being lacking on the upper surface of the hemisphere. The principal sulcus is the *central sulcus*, the principal gyri the *anterior* and *posterior central*, bounded by the *praecentral* and *interparietal sulci*. These gyri unite on the medial surface of the hemisphere to form the *paracentral lobule*, which is separated from the *praecuneus* by the marginal part of the sulcus cinguli. The praecuneus is separated from the occipital lobe by the *parieto-occipital fissure* and from the gyrus cinguli by the *subparietal sulcus*. The *interparietal sulcus*, behind the posterior central gyrus, separates the *superior* and *inferior parietal lobules*. At the posterior end of the Sylvian (lateral) fissure is the *supramarginal gyrus* and at the end of the superior temporal sulcus, the *angular gyrus*. Fig. 152—159. At the bottom of the Sylvian (lateral) fissure, covered in by the frontal, parietal and temporal lobes, which form its *operculum*, is the *insula*, bounded above and laterally by the *circular sulcus* and below by the *limen insulae*. It has a *long gyrus* and *short gyri*. Fig. 160—162.

The **occipital lobe** forms the posterior part and the *occipital pole* of the cerebral hemisphere. Only on the medial surface is it separated from the parietal lobe by the *parieto-occipital fissure*; elsewhere it passes insensibly into the parietal and temporal lobes. On its medial surface it has the *calcarine fissure*, which, with the parieto-occipital, bounds the triangular *cuneus*. Below the calcarine fissure on the concave surface of the lobe is the *lingual gyrus*, bounded by the *collateral* fissure, and, below this, the *fusiform gyrus*, which belongs mainly to the temporal lobe. On the convex surface of the lobe the *transverse occipital sulcus* separates the *superior occipital gyri* (and *sulci*) from the *lateral occipital gyri* (and *sulci*), irregularly arranged and highly variable convolutions (microgyri). Fig. 152—159.

The **temporal lobe** forms the lower portion of the hemisphere and its *temporal pole*, which is directed forwards and downwards. On the lateral surface it consists of three parallel gyri, the *superior*, *middle* and *inferior*, separated by the *superior* and *middle temporal sulci*. On the concave under surface is the *hippocampal gyrus*, with the *uncus* and the *fusiform gyrus*, the latter being separated from the former by the *collateral fissure* and from the inferior temporal gyrus by the *inferior temporal sulcus*. The hippocampal gyrus is continued by the *isthmus of the gyrus fornicatus* into the *gyrus cinguli*, situated on the medial surface of the frontal and parietal lobes; the gyrus cinguli and the hippocampal gyrus together form the *gyrus fornicatus*. (The gyrus cinguli cannot be assigned either to the frontal or the parietal lobe.) Fig. 152—159.

The Central Nervous System.

The Brain. (Cont.) The Cerebral Hemispheres. (Cont.,

Fig. 163. The corpus callosum and the left lateral ventricle, from above and slightly from the left. Preparation similar to that of Fig. 162, except that the roof of the lateral ventricle has been removed.

The Corpus Callosum.

The *corpus callosum* is a large, flat mass of nerve fibres, which, as a commissure, unites the two hemispheres and forms the floor of the longitudinal fissure. It consists of a principal part, the *trunk*, of a posterior thickened portion termed the *splenium*, which projects over the quadrigeminal plate and forms the upper boundary of the transverse fissure, and of an anterior part, bent upon itself and termed the *genu*. From the genu, which projects forwards and downwards, there is continued backwards a narrow band, the *rostrum*, which passes towards the anterior commissure and thence extends as the *rostral lamina* towards the terminal lamina of the third ventricle. The corpus callosum consists of transverse fibres; on its upper surface there is a thin layer of grey substance which thickens at the median line to form the *medial longitudinal striae* and laterally, to form the *lateral striae*. Beneath the anterior part of the corpus callosum (between the trunk and genu) is the septum pellucidum and further back the fornix. Fig. 149, 161—163, 167, 189, 195—197, 205.

The Fornix.

The *fornix* is a long, strongly arched, bundle of fibres, whose anterior part forms the *columns (pillars) of the fornix*, of which a *pars tecta* and a *pars libera* may be distinguished. The pars tecta lies concealed in the medial wall of the thalamus and runs from the floor of the third ventricle (from a corpus mamillare) to the anterior surface of the anterior commissure. Here it leaves the substance of the thalamus and runs backwards as the pars libera, rapidly approaching its fellow of the opposite side. It here bounds, together with the anterior part of the thalamus, the *interventricular foramen*, and it then passes to the under surface of the corpus callosum, from which it is at first separated by the septum pellucidum. Here the two pillars unite to form the *body* of the fornix and again separate as two flattened bands, the *crura*, fibres passing traversely from one to the other forming the hippocampal commissure. Each crus accompanies the chorioid plexus downwards and laterally into the inferior cornu of the lateral ventricle, united to the plexus by the *taenia fornicis* and forming the *fimbria* of the hippocampus. Thus the fornix fibres connect the hippocampus with the thalamus. Fig. 149, 158, 161, 163—167, 178, 189, 196, 205.

The Septum Pellucidum

lies between the corpus callosum and the pillars of the fornix, attached to both, and separates the anterior cornua of the two lateral ventricles. It consists of two layers between which is a cleft-like cavity, (the so-called fifth ventricle). Fig. 149, 158, 161, 165—167, 178, 188, 189, 195—197, 205.

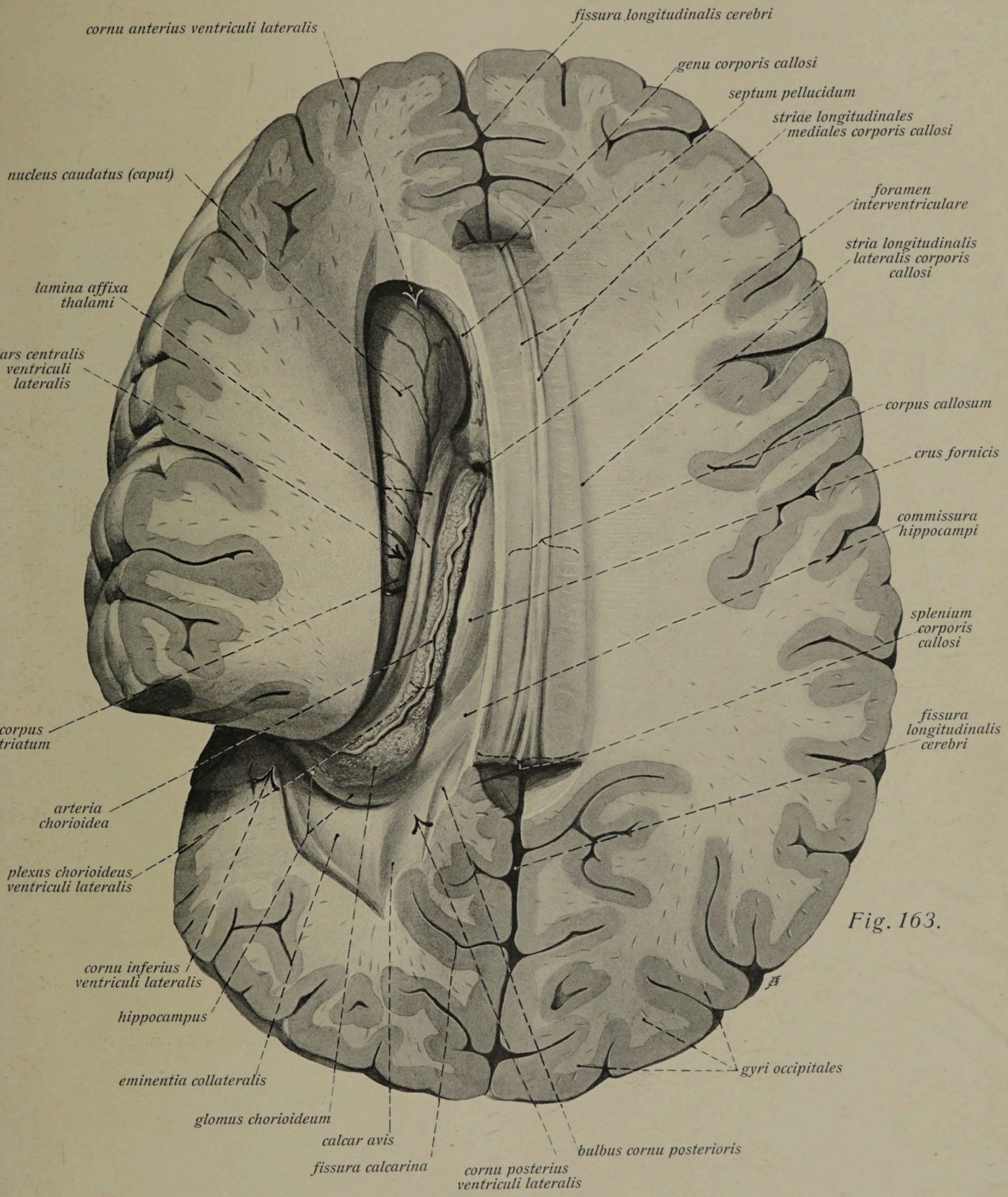
cornu anterius ventriculi lateralis
fissura longitudinalis cerebri
genu corporis callosi
septum pellucidum
striae longitudinales mediales corporis callosi
nucleus caudatus (caput)
foramen interventriculare
stria longitudinalis lateralis corporis callosi
lamina affixa thalami
pars centralis ventriculi lateralis
corpus callosum
crus fornicis
commissura hippocampi
splenium corporis callosi
corpus striatum
fissura longitudinalis cerebri
arteria chorioidea
plexus chorioideus ventriculi lateralis
cornu inferius ventriculi lateralis
hippocampus
eminentia collateralis
glomus chorioideum
calcar avis
fissura calcarina
cornu posterius ventriculi lateralis
bulbus cornu posterioris
gyri occipitales

Fig. 163.

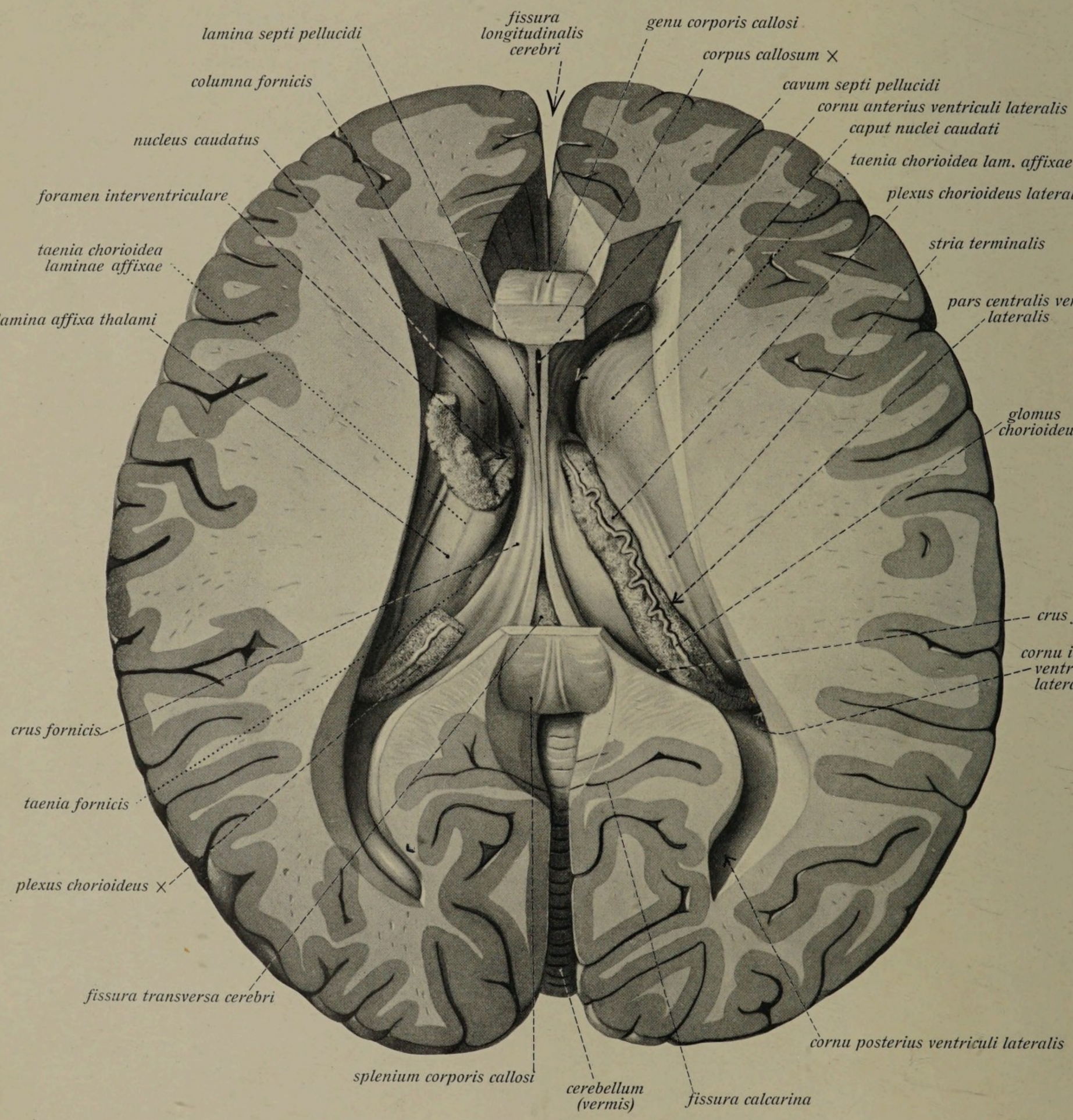
lamina septi pellucidi
fissura longitudinalis cerebri
genu corporis callosi
corpus callosum ×
columna fornicis
cavum septi pellucidi
cornu anterius ventriculi lateralis
nucleus caudatus
caput nuclei caudati
taenia chorioidea lam. affixae
foramen interventriculare
plexus chorioideus lateralis
taenia chorioidea laminae affixae
stria terminalis
lamina affixa thalami
pars centralis ventriculi lateralis
glomus chorioideum
crus fornicis
cornu inferius ventriculi lateralis
crus fornicis
taenia fornicis
plexus chorioideus ×
fissura transversa cerebri
cornu posterius ventriculi lateralis
splenium corporis callosi
cerebellum (vermis)
fissura calcarina

Fig. 164.

The Central Nervous System.

The Brain. (Cont.) The Cerebral Hemispheres. (Cont.)

Fig. 164. The two lateral ventricles, the fornix and the septum pellucidum, from above. Preparation as in Fig. 162, except that somewhat more brain substance and the middle portion of the corpus callosum are removed. On the left the chorioid plexus is cut and reflected.

The Rhinencephalon

is rudimentary in man. Its peripheral portion[1]) may be divided into anterior and posterior portions. The *anterior* portion consists of the *olfactory tract*, lying in the olfactory sulcus of the frontal lobe and enlarging at its anterior end to form the *olfactory bulb*. The tract begins at the *olfactory trigone*, situated at the anterior end of the perforated substance, by three white roots, the *medial*, *intermediate* and *lateral olfactory striae*. Fig. 174.

In addition, the *parolfactory area*, on the medial surface of the hemisphere, below the genu of the corpus callosum, belongs to the anterior portion of the rhinencephalon. It is separated from the superior frontal gyrus by the *anterior parolfactory sulcus* and from the subcallosal gyrus by the *posterior parolfactory sulcus*. Fig. 149, 178.

The *posterior* portion consists of the *subcallosal gyrus*, Fig. 149, 178, a rudimentary gyrus situated in front of the rostrum of the corpus callosum, of the anterior perforated substance, Fig. 149, and of the *limen* of the insula, Fig. 174, to which passes the *lateral olfactory stria*. Fig. 174.

The Lateral Ventricle.

The lateral ventricle lies in the interior of each hemisphere and extends into each of the lobes. The *central* part in the parietal lobe, below the corpus callosum and at the sides of the corpus striatum, sends off prolongations, the *cornua*, into the other three lobes. Fig. 163—166.

The *central portion* lies immediately beneath the corpus callosum, medial to a club-shaped swelling, the *corpus striatum*, which, with its *caudate nucleus* (see below), forms its lateral wall, while its floor is formed by the gray lamina affixa of the thalamus. In the angle between the floor and the corpus striatum is a raised cord, usually of a bluish tinge, the *terminal stria*, which consists of a tract of fibres and the terminal vein (see p. 167). Anteriorly, where the central portion passes into the anterior horn, it comes into relation with the pars libera of the pillar of the fornix and communicates with the third ventricle by the *interventricular foramen (foramen of Monro)*. On the medial wall is the fornix (see p. 184) and projecting upward from the floor, the chorioid plexus of the lateral ventricle (see p. 191). Fig. 163—167, 184, 188, 189, 205.

The *anterior cornu (horn)* extends forward into the frontal lobe, where it ends blindly. It is relatively broad, is covered by the anterior part of the corpus callosum, whose genu forms its anterior boundary. Medially is the septum pellucidum and laterally the portion of the corpus striatum known as the head of the *caudate nucleus*. The chorioid plexus does not extend into the anterior horn. Fig. 163—167, 188, 195—197.

---

[1]) The central rhinencephalon lies within the scope of the pallium.

The Central Nervous System.

The Brain. (Cont.) The Cerebral Hemispheres. (Cont.)

Fig. 165. The two lateral ventricles and the third ventricle, from above. The trunk and splenium of the corpus callosum, the body of the fornix and the tela chorioidea of the third ventricle have been removed. The hemispheres have been cut across transversely a little below the corpus callosum, and the left temporal lobe has been cut away as far as the tip of the inferior cornu. A sound passes through the interventricular foramen.

The Lateral Ventricle. (Cont.)

The *posterior cornu (horn)* is a short, triangular prolongation of the central portion into the occipital lobe, where it lies nearer the medial than the lateral surface, and ends in a point some distance from the occipital pole. Its roof is formed by the *occipital radiation* of the corpus callosum and, more laterally, by the *tapetum*, which is also a portion of the callosal radiation. On its medial wall there is a pronounced rounded elevation, the *calcar avis*, which is produced by the calcarine fissure. Above this there is frequently another elevation, the *bulb* of the posterior cornu. The posterior cornu is directly continuous with the inferior cornu. Fig. 163—168, 171.

The *inferior cornu (horn)* lies in the temporal lobe, nearer its medial than its lateral wall, and is a laterally convex hornlike portion of the lateral ventricle, whose medial wall to some extent is formed only by the ependymal epithelium. This wall is invaginated into the ventricle as the chorioid plexus of the lateral ventricle (see p. 191), the removal of which produces a slit-like opening between the ventricle and the transverse fissure. The inferior cornu communicates with the posterior part of the central portion and with the posterior cornu. The lateral wall and roof are the same as in the posterior horn (callosal radiation and tapetum), the floor is formed by a slight elevation, the *collateral trigone*, which extends into the posterior cornu between the calcar avis and the hippocampus, and occasionally bears a strong convex, longitudinal ridge, the *collateral eminence*, produced by the collateral fissure.

The most important structure of the inferior cornu is a whitish, curved swelling, situated on its medial wall, the *hippocampus*. It begins at the transition of the central portion into the posterior cornu and extends, gradually becoming thicker and broader, to the anterior end of the inferior horn, where it passes into the *uncus*. Here, where it reaches its greatest thickness, it shows a number of slight prominences, the *digitations* of the hippocampus *(pes hippocampi)*. The upper medial ends of both hippocampi are connected by the *hippocampal commissure*, which passes transversely beneath the corpus callosum and the fornix. On the medial surface of the hippocampus and forming its white covering, is the *fimbria*, the prolongation of the crus of the fornix. On the medial side of the roof of the inferior cornu there is also the *tail of the caudate nucleus* which, however, does not project into the cavity of the ventricle (see p. 191). Fig. 165—172, 190. Covered by the fimbria and between it and the hippocampal gyrus is a grey, frequently notched strip, the *dentate fascia*, which, like the greater part of the fimbria, is really outside the limits of the inferior cornu. The dentate fascia is continuous posteriorly with the *fasciola cinerea* from the gray covering of the corpus callosum and anteriorly it passes into the socalled band of Giacomini, which unites it to the uncus. Fig. 161, 168—172, 190.

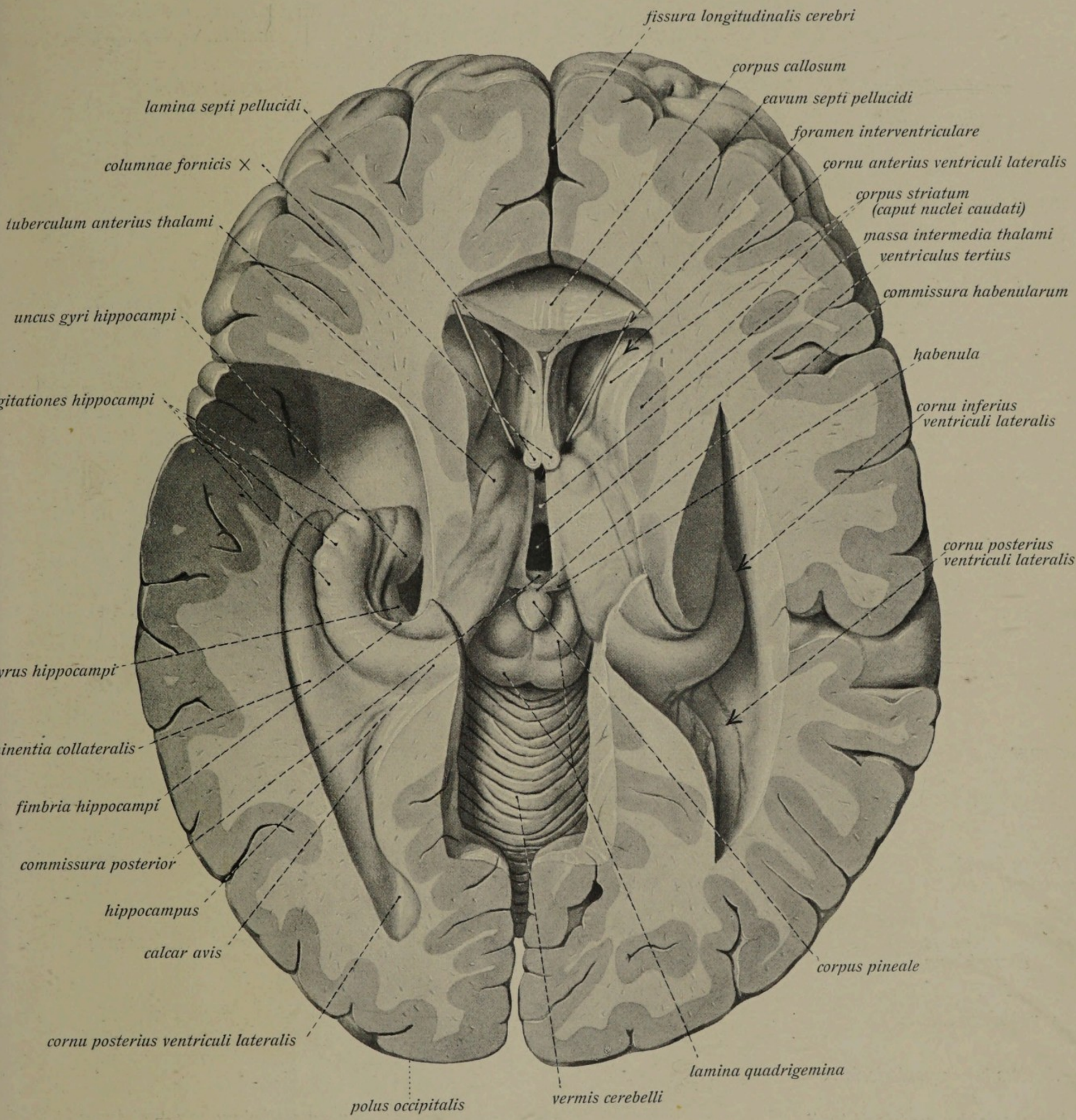
fissura longitudinalis cerebri
corpus callosum
lamina septi pellucidi
cavum septi pellucidi
foramen interventriculare
columnae fornicis
cornu anterius ventriculi lateralis
corpus striatum
(caput nuclei caudati)
tuberculum anterius thalami
massa intermedia thalami
ventriculus tertius
commissura habenularum
uncus gyri hippocampi
habenula
digitationes hippocampi
cornu inferius
ventriculi lateralis
cornu posterius
ventriculi lateralis
gyrus hippocampi
eminentia collateralis
fimbria hippocampi
commissura posterior
hippocampus
calcar avis
cornu posterius ventriculi lateralis
corpus pineale
lamina quadrigemina
polus occipitalis
vermis cerebelli

Fig. 165.

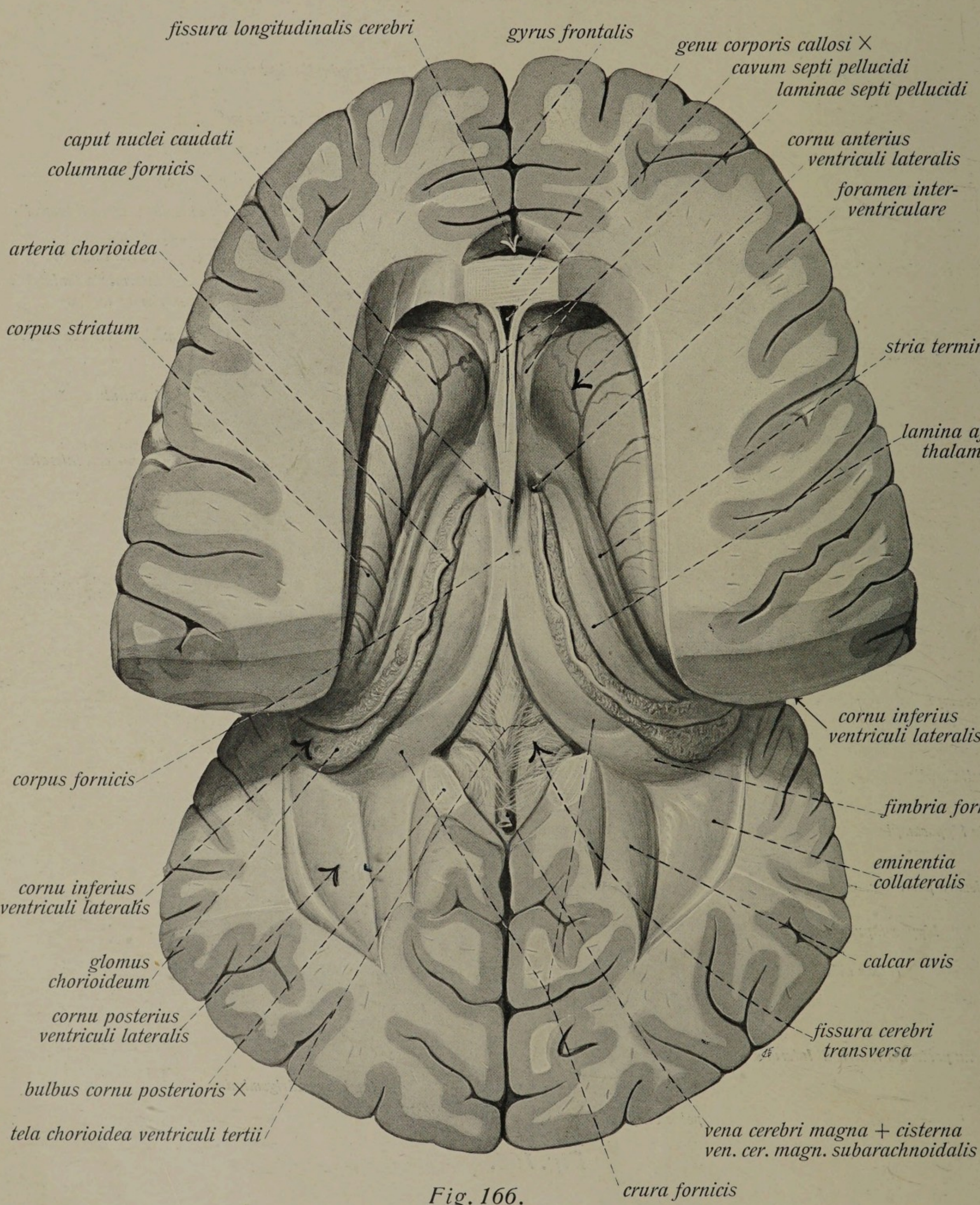
fissura longitudinalis cerebri
gyrus frontalis
genu corporis callosi ×
cavum septi pellucidi
laminae septi pellucidi
caput nuclei caudati
columnae fornicis
cornu anterius ventriculi lateralis
foramen inter-ventriculare
arteria chorioidea
corpus striatum
stria terminalis
lamina affixa thalami
cornu inferius ventriculi lateralis
corpus fornicis
fimbria fornicis
eminentia collateralis
cornu inferius ventriculi lateralis
glomus chorioideum
calcar avis
cornu posterius ventriculi lateralis
fissura cerebri transversa
bulbus cornu posterioris ×
tela chorioidea ventriculi tertii
vena cerebri magna + cisterna ven. cer. magn. subarachnoidalis
crura fornicis

Fig. 166.

Fig. 166. The lateral ventricles opened from above; the fornix and the transverse fissure. Preparation as in Fig. 164, except that the inferior cornu is opened on both sides and the splenium of the corpus callosum is removed.

The Chorioid Plexus of the Lateral Ventricle

has the form of an irregular, contorted band, loosely attached to the floor of each lateral ventricle, and consists of a highly vascular fold of pia mater, covered by the ventricular epithelium. It begins at the interventricular foramen, where it is continuous with the chorioid plexus of the third ventricle, and extends through the central portion of the ventricle and the inferior cornu. At the junction of these two regions it usually has a distinct enlargement, the *glomus chorioideum*. While the plexus in the central portion of the ventricle is connected with the lateral edges of the tela chorioidea of the third ventricle (see p. 192), in the inferior horn it bulges into the ventricle along a thin strip of the wall beside the hippocampus, carrying with it the greatly contorted *chorioid artery* (see p. 167), while the corresponding *chorioid vein* unites with the terminal vein at the interventricular foramen and opens into the internal cerebral vein (see p. 167). The plexus lies laterally to the fornix, to which it is attached, and it is also attached to the lamina affixa of the thalamus (see p. 192) into which its epithelial lining passes, forming the *taenia chorioidea*. In the inferior cornu the plexus is attached directly to the taenia fimbriae. Fig. 163, 164, 166, 167, 189—191.

The Ganglia of the Cerebral Hemispheres.

In addition to the grey cortex, each hemisphere contains four masses of grey substance, or ganglia, which, with the exception of the caudate nucleus, are completely imbedded in the substance of the hemisphere. The caudate and lentiform nuclei are connected by their anterior portions and together constitute the corpus striatum.

1. The **caudate nucleus** forms the medial upper portion of the corpus striatum and projects into the cavity of the lateral ventricle. It is a club-shaped structure; its anterior enlarged end is termed the *head* and its posterior portion, which curves backwards and downwards gradually becoming more slender, is the *tail*. It lies lateral to the thalamus, its head projecting in front of it, while the tail curves around its posterior portion. Between the thalamus (see p. 187) and the caudate nucleus is the *terminal stria*, a tract of fibres, which, in its anterior portion contains the *terminal vein* (see p. 167), while posteriorly it consists only of fibres. The caudate nucleus is separated from the lentiform throughout the greater part of its extent by the internal capsule. Fig. 163—167, 173, 180, 184, 188, 189, 195—197, 205.

2. The **lentiform (lenticular) nucleus** is the lateral, inferior part of the corpus striatum and is a large ganglion, triangular in both frontal and horizontal section, situated in the lower part of the hemisphere, lateral to the caudate nucleus and the thalamus. It consists of three portions, separated by sheets of medullated fibres, a lateral, dark grey part, the putamen and two smaller paler masses, the *globus pallidus*. The slightly convex, lateral surface of the *putamen* is separated by the *external capsule*, a thin fibre tract, from the neighbouring claustrum; the antero-medial; surface of the nucleus is separated by the anterior limb of the internal capsule from the caudate nucleus; while the postero-medial surface is separated by the posterior limb of the capsule from the thalamus. At its anterior end it is connected with the head of the caudate nucleus. Fig. 184, 188—190, 195—197, 205.

The **claustrum** is a small disk of grey substance, placed almost vertically; it is separated from the putamen by the external capsule and on the other surface is close to the gyri of the insula, being separated from their cortex only by a thin sheet of medullated fibres. Fig. 184, 188—190, 195—197, 205.

The **nucleus amygdalae** is an irregular roundish mass of grey substance, situated in the white substance of the anterior end of the temporal lobe, below the lentiform nucleus. It is connected with the cortex of the hippocampal gyrus. Fig. 196.

The Central Nervous System. The Brain. (Cont.)

The Interbrain, *diencephalon.*

The **third ventricle** is an unpaired narrow cavity between the two thalami. Its roof is formed by a layer of epithelium that covers the under surface of the *tela chorioidea (velum interpositum)*. This is a triangular sheet of pia mater, situated beneath the body and the crura of the fornix (see p. 184), and gives rise to the paired but short *chorioid plexuses* of the third ventricle. Fig. 167, 189, 205. The anterior wall of the ventricle is formed by the *pillars of the fornix*, the *anterior commissure*, the *rostral lamina* of the corpus callosum and the *terminal lamina*; its floor is formed by the structures of the *hypothalamus* (*optic chiasma, tuber cinereum, corpora mamillaria* and *posterior perforated substance*). Behind, the ventricle gradually passes over into the cavity of the midbrain, its posterior limits being indicated by the *epithalamus* (*pineal body, posterior commissure* and anterior end of the *quadrigeminal lamina*). Its lateral walls are the only boundaries that have any considerable extent and are formed mainly by the thalami, a *hypothalamic sulcus* indicating the boundary between the thalamus and the hypothalamus. The ventricle has three outpouchings, two in the region of the hypothalamus, separated by the keel-like projection of the optic chiasma, the third in the epithalamus. In front of the chiasma, between it and the terminal lamina, is the *optic recess;* behind the chiasma is the somewhat larger *infundibular recess*, which extends into the stalk of the hypophysis. The epithalamic outpouching, which extends into the pineal body, is termed the *pineal recess*. Beneath this is the *posterior commissure,* which connects the two hemispheres. The third ventricle communicates on each side with the lateral ventricle by the *interventricular foramen (foramen of Monro)* situated between the pillars of the fornix and the anterior ends of the thalamus. Fig. 149, 166, 173, 178, 180, 184, 189, 197, 205.

The **thalamus** is an elongated, almost oval body, whose rounded anterior end is raised into a small roundish *anterior tubercle*, while posteriorly it is greatly thickened to form the *pulvinar*, which overlaps the metathalamus and the lateral surface of the midbrain. The upper convex surface is partly free and covered with pia mater, and partly forms a portion of the floor of the lateral ventricle. It is covered by a layer of white substance, the *stratum zonale*. To it is attached the *lamina affixa*, originally a part of the medial wall of the forebrain; it passes as the *taenia chorioidea* into the epithelial layer of the chorioid plexus of the lateral ventricle (see also p. 187).

The medial wall of the thalamus, slightly convex, lies almost vertically and extends down to the hypothalamic sulcus. It is united with the corresponding surface of the opposite thalamus by a soft, very variable *intermediate mass (soft commissure)*, which passes across the cavity of the ventricle. The boundary between the upper and medial surfaces of the thalamus is a white *medullary stria*, which is continued posteriorly into the habenular trigone and also into the epithelial roof of the ventricle; when the roof is removed the torn edges of the medullary stria form the *taenia thalami*. The posterior surface of the thalamus, the pulvinar, is fused with the metathalamus (see p. 195) and the other surfaces are connected with the adjacent parts of the forebrain, the internal capsule, and corpus striatum. Fig. 149, 163—167, 173, 188, 189, 205.

Fig. 167. The lateral ventricles, corpus callosum, fornix, and tela chorioidea of the third ventricle. (5/4)
Preparation as in Fig. 164, 166, except that the corpus callosum and fornix are cut and reflected, after cutting through the septum pellucidum. In this way the transverse fissure and tela chorioidea of the third ventricle are exposed. The corresponding cut surfaces of the corpus callosum, fornix, and septum pellucidum are indicated by the numbers 1, 2.

Fig. 168. The posterior and inferior cornua of the lateral ventricle. (5/4) Preparation as in Fig. 166.

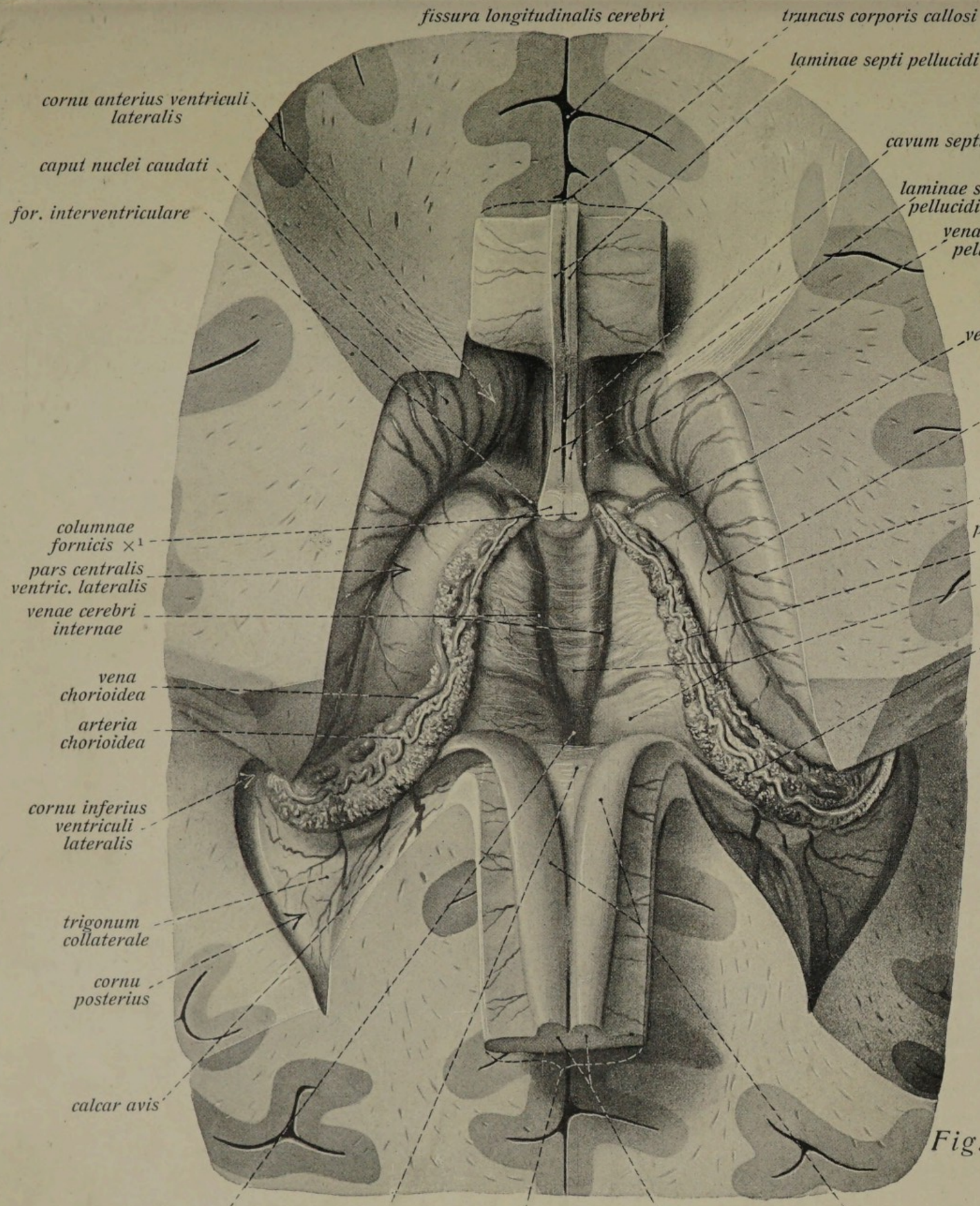

Fig. 167.

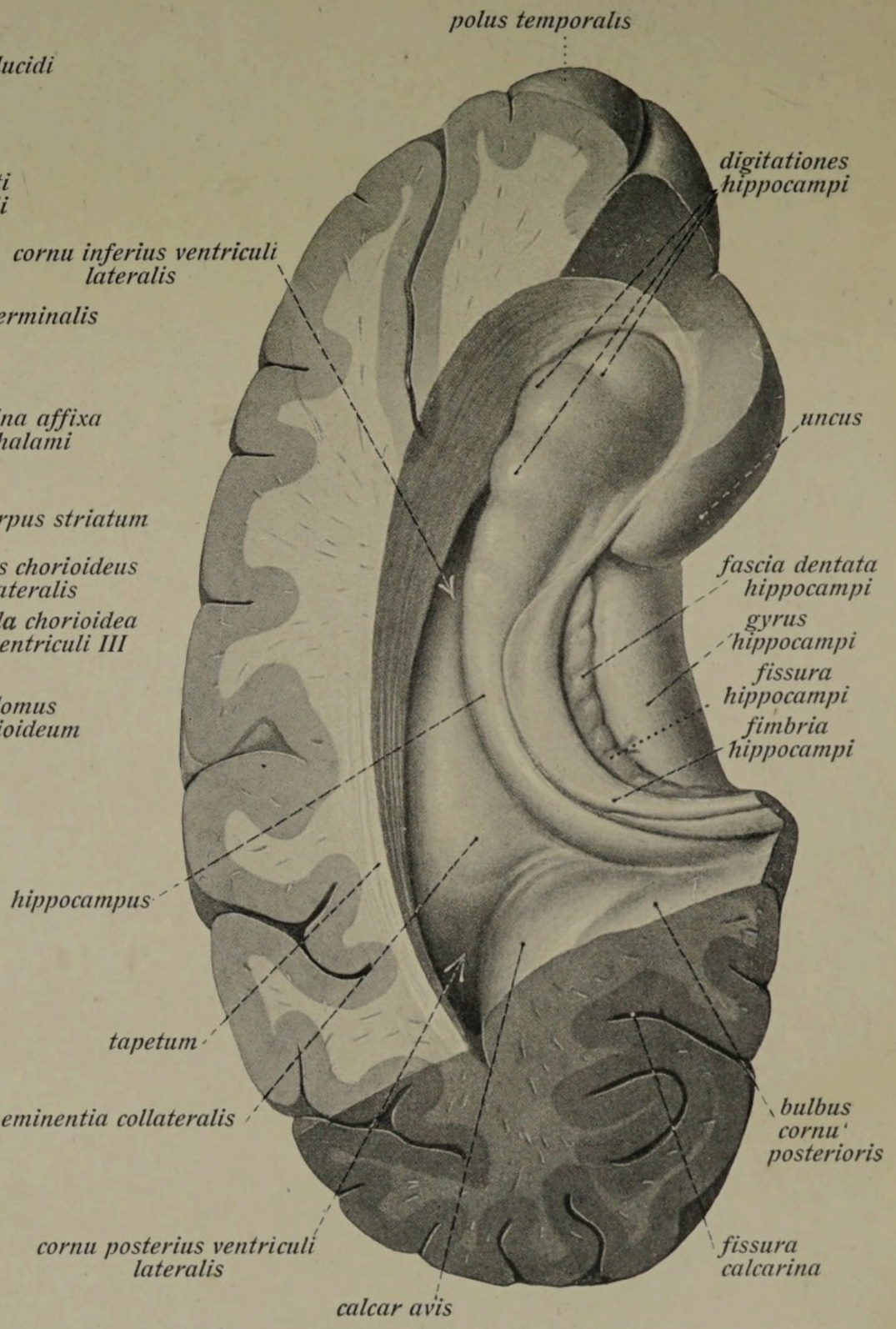

Fig. 168.

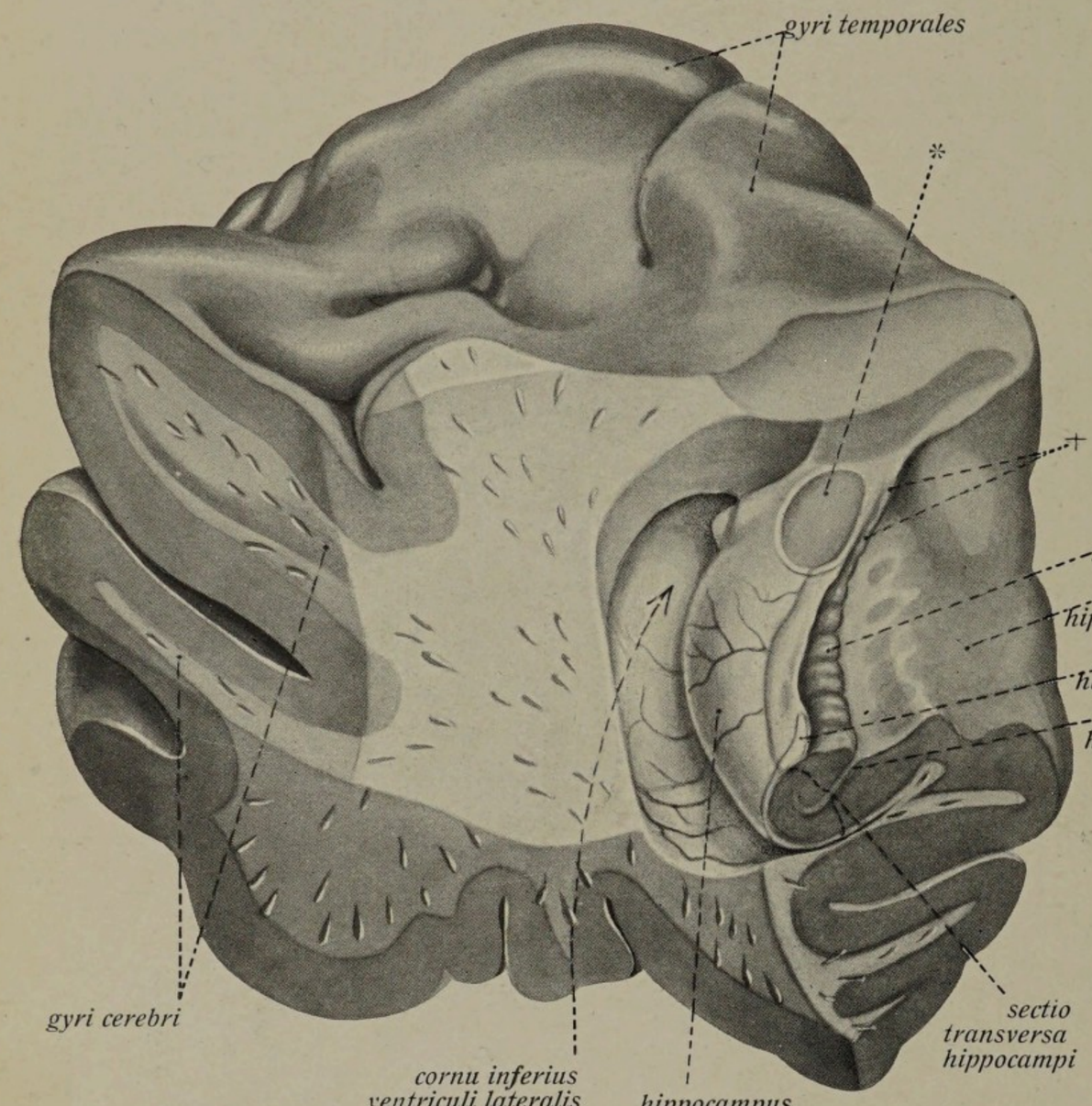

Fig. 171.

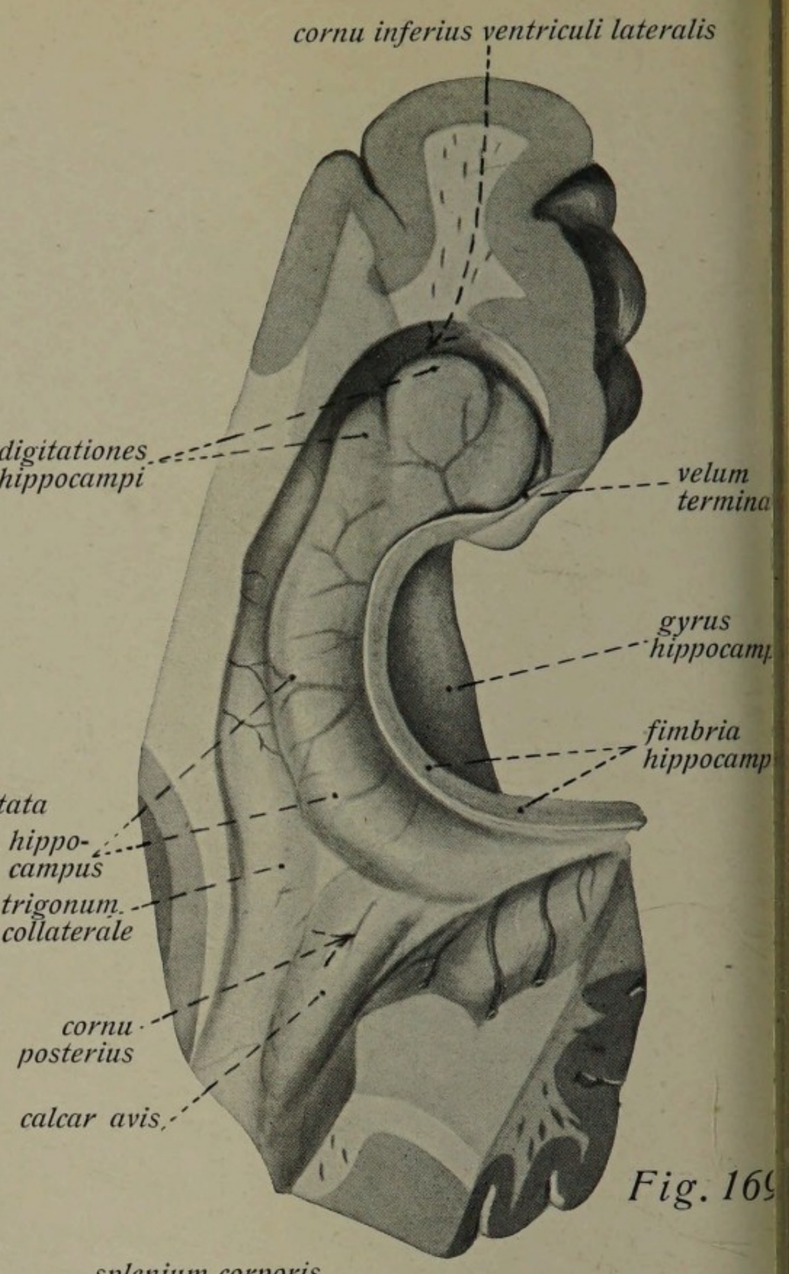

Fig. 169

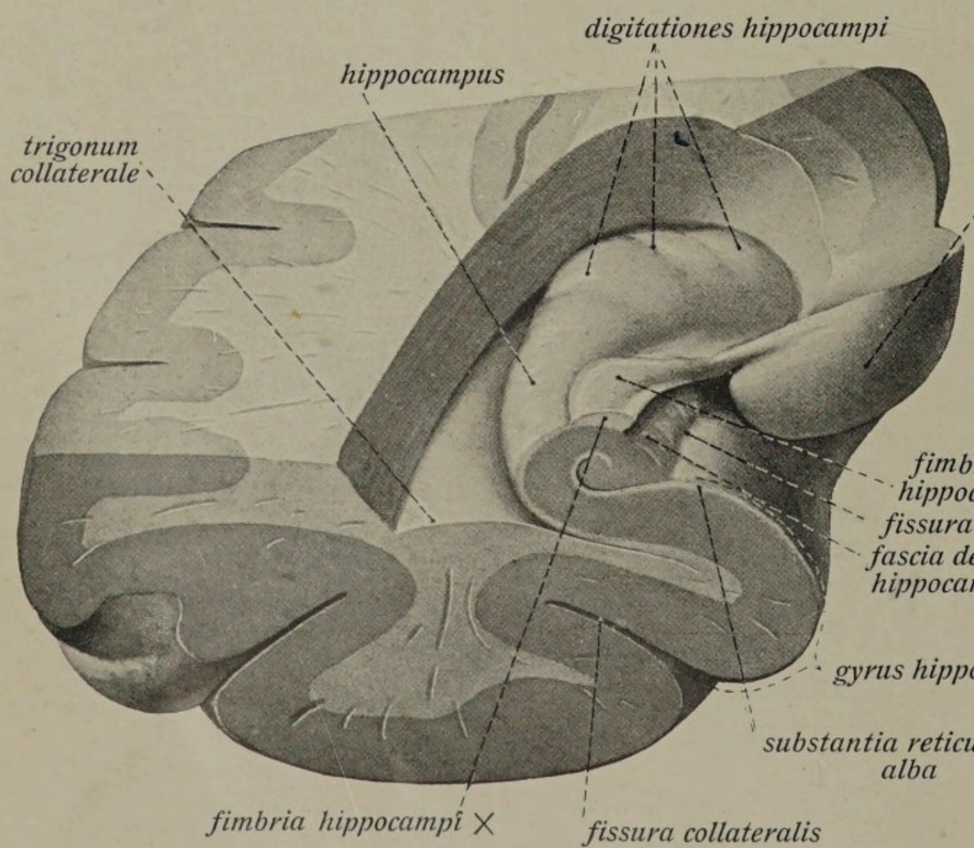

Fig. 170.

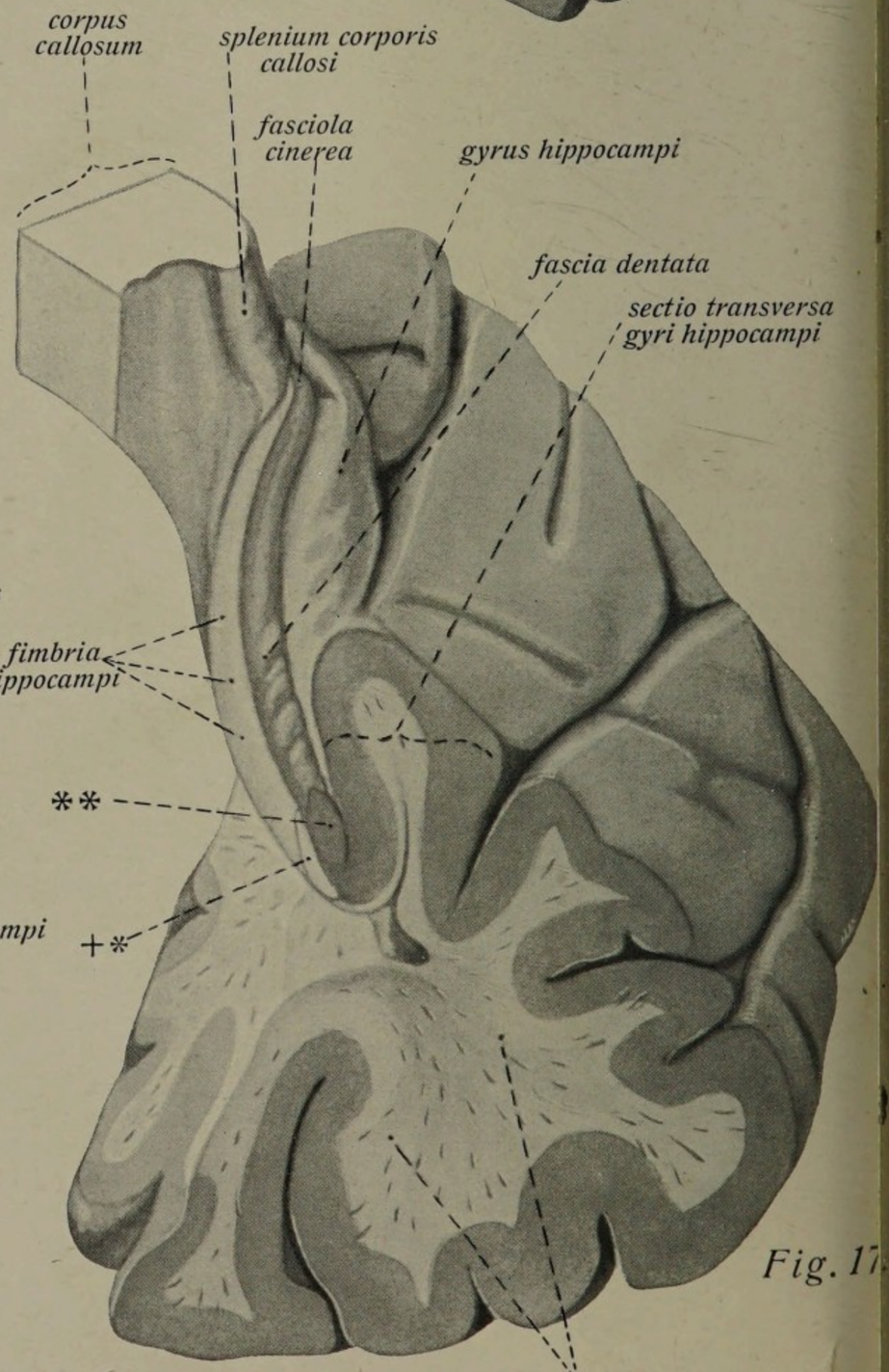

Fig. 17

Fig. 169. Floor of the descending horn of the lateral ventricle. (2/1)
The relations of the hippocampus and the hippocampal gyrus and fimbria are shown. Preparation as in Fig. 168.

Fig. 170. A frontal section of the anterior portion of the temporal lobe, after opening the descending horn. (2/1) From behind and above.

Fig. 171. Anterior end of the descending horn of the lateral ventricle. (2/1)
Preparation as in Fig. 169, 170, except that the uncus is displaced to show the band of Giacomini. + = Band of Giacomini. * = Section-surface of the anterior end of the hippocampus.

Fig. 172. Anterior end of the temporal lobe with the splenium of the corpus callosum, from behind and below. (2/1) The passage of the dentate fascia into the fasciola cinerea is shown. ** = Transverse Section of the gyrus dentatus. +* = Transverse Section of the fimbria hippocampi.

The **hypothalamus** forms the floor and the part of the lateral wall of the third ventricle that is below the hypothalamic sulcus. It consists of an anterior *optic* and a posterior *mamillary* portion. To the former belong the *tuber cinereum*, with the *infundibulum* and *hypophysis*, the *optic tract*, with the *optic chiasma*, and the *terminal lamina*. The **hypophysis** consists of an anterior epithelial and a posterior nervous lobe. The *terminal lamina* is the thin anterior wall of the third ventricle and is continued in front of the anterior commissure into the rostrum of the corpus callosum. The *mamillary* portion is formed by the two *corpora mamillaria* each of which contains a grey nucleus. Fig. 148, 149, 157, 161, 174, 177—179, 205.

The **epithalamus** consists of the *pineal body* and its stalk. The pineal body is a greyish-red, flattened, oval body, whose broader base is attached to the posterior part of the roof of the third ventricle, while its apex projects backwards and downwards upon the quadrigeminal lamina. It is connected to the thalamus by the *habenulae*, which are the direct prolongations of the medullary striae of the thalamus and unite in front of the root the pineal body to form a triangular white plate, the *habenular trigone*. Into the base of the pineal body there projects the *pineal recess*, while a slight depression between the pineal body and the tela chorioidea is termed the *suprapineal recess*. Fig. 149, 165, 173, 178, 180.

The **metathalamus** is formed by the two *geniculate bodies*. The more prominent *medial geniculate body* lies behind the pulvinar, at the anterior end of the inferior quadrigeminal brachium (see below); the less prominent *lateral geniculate body* is at the posterior lower portion of the thalamus, covered by the pulvinar. The *optic tract* apparently [1]) arises from both bodies, from the medial by a smaller *medial root* and from the lateral by a stronger *lateral root*. Fig. 177, 180, 206, 207.

The Midbrain, *mesencephalon*.

The lower surface of the midbrain is formed by the two *cerebral peduncles* and by the *interpeduncular fossa*, in which an *anterior* and a *posterior recess* occurs. The roof of the fossa is the *posterior perforated substance*, which shows numerous openings for blood vessels. The lateral surfaces of the midbrain are formed principally by the cerebral peduncles, the roof by the quadrigeminal lamina. Fig. 148, 149, 157, 173, 174, 177—178, 206, 207, 212, 213.

The *cerebral peduncles* are two white bands, which begin at the anterior border of the pons and pass forwards and upwards, above the optic tracts, diverging as they go, to enter the cerebral hemispheres. The under surface of each peduncle is strongly furrowed and is partly visible at the base of the brain, but for the most part it is covered by the optic tract and the hippocampal gyrus and its uncus. Fig. 148, 157, 174, 177, 206, 207, 212, 213.

---

[1]) In reality only the lateral geniculate is an optic centre.

The Central Nervous System. The Brain. (Cont.)

The Midbrain, *mesencephalon*. The Isthmus.

Fig. 173. The lateral ventricle, third ventricle, quadrigeminal plate and cerebellum, from above. (4/5) Preparation as in Fig. 166, but the corpus callosum, the tela chorioidea of the third ventricle and the temporal and occipital lobes of the cerebral hemispheres have been removed.

The **quadrigeminal lamina** forms the dorsal surface of the midbrain and at the sides passes directly into the tegmentum of the cerebral peduncles. It is a white, rectangular plate, formed by two large anterior *superior colliculi* and two smaller posterior *inferior colliculi*, which together form the *corpora quadrigemina*. From each superior colliculus a white band, the *superior brachium*, passes to the lateral geniculate body and a similar *inferior brachium* passes from each inferior colliculus towards the medial geniculate. Behind, the quadrigeminal plate passes over into the brachia conjunctiva of the isthmus, laterally into the upper dorsal portion of the pons. Fig. 149, 165, 173, 178, 180, 188, 206, 207, 212, 213.

The cavity of the midbrain, the *aquaeduct* (of Sylvius), is a narrow canal about $1^1/_2$ cm. in length, which connects the third and fourth ventricles. In cross section it is triangular or heart-shaped. Fig. 149, 177, 178, 212, 213.

Transverse sections of the midbrain show grey substance in each of the corpora quadrigemina, the *nuclei of the superior* and *inferior colliculi*, enclosed by a thin layer of white substance, the *stratum zonale*. The peduncles in cross section show, below the aquaeduct, the *tegmentum*, below this on either side an arched or semilunar strongly pigmented area (appearing dark grey in the fresh brain), the *substantia nigra*, and the *basis (crusta)*. The separation between the two latter portions is shown externally by the *lateral sulcus* of the midbrain. Fig. 177, 212, 213.

The *tegmentum* contains in its anterior part a large, round *nucleus ruber* and, in addition to other small nuclei, numerous longitudinal fibre bundles, which are termed the tegmental bundles. To these belongs the complicated fibre tract known as the *lemniscus (fillet)*, which, divided into a strong *medial* and a weaker *lateral (acoustic) lemniscus*, lies lateral to the nucleus ruber. The fibres near the median line cross in the *tegmental decussation*. An especially large decussation of the brachia conjunctiva occurs beneath the red nucleus. In the grey substance of the floor of the aquaeduct there arises in the region of the anterior colliculi the *oculo-motor nerve* from the *oculo-motor nucleus*, and in the region of the inferior colliculi and isthmus, the *trochlear nerve*. The root fibres of the former traverse the red nucleus and come to the surface at the lateral border of the interpeduncular fossa. Below the nuclei of these two nerves there is a longitudinal fibre-tract, ascending from the medulla oblongata, the *medial longitudinal fasciculus*. Fig. 177, 212, 213.

The *basis (crusta)* of the peduncles consists of longitudinal fibre bundles, which pass to the internal capsule, principally the pyramidal tracts and the cerebro-pontile tracts. Fig. 212, 213.

The Isthmus

is formed by the two *brachia conjunctiva*, the *anterior medullary velum* and the *trigonum lemnisci*. The first are flattened white bands, whose fibres connect the cerebellum and the midbrain, passing into the tegmentum. The two brachia converge towards the posterior colliculi and bound a triangular area covered by a thin layer of white substance, the *anterior medullary velum*. This forms the roof of the upper part of the fourth ventricle and is continuous with the white substance of the vermis of the cerebellum; above it arises a small bundle of fibres, the *frenulum*, from the groove that separates the two inferior colliculi. Between the brachia conjunctiva, the inferior quadrigeminal brachium and the lateral sulcus of the midbrain there is a triangular area, not always distinctly delimited, which contains the lateral lemniscus (fillet); it is the *trigonum lemnisci*. Fig. 180, 206.

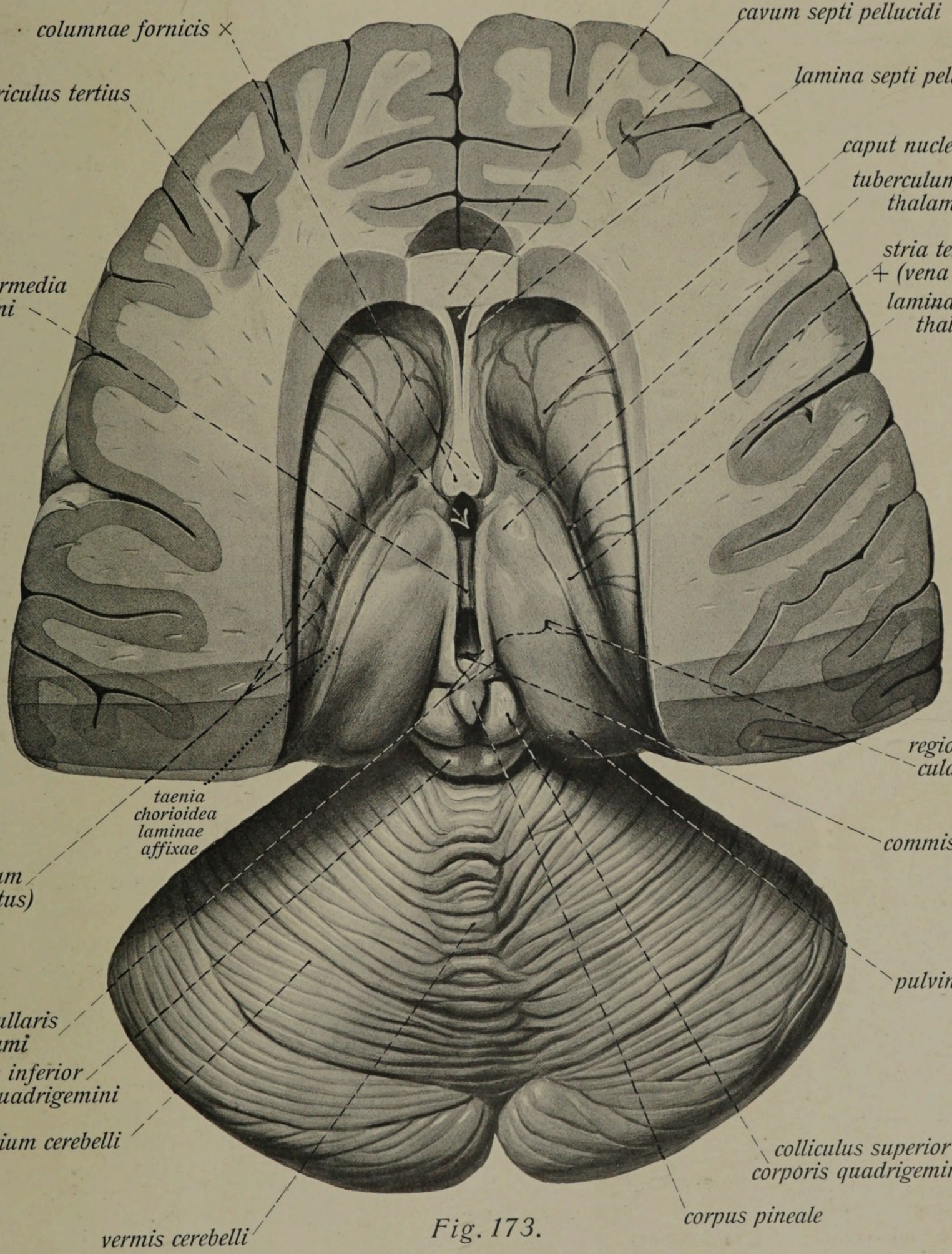
genu corporis callosi ×
cavum septi pellucidi
columnae fornicis ×
lamina septi pellucidi
ventriculus tertius
caput nuclei caudati
tuberculum anterius thalami
stria terminalis + (vena terminalis)
massa intermedia thalami
lamina affixa thalami
regio extraventricularis thalami
taenia chorioidea laminae affixae
commissura posterior
corpus striatum (nucleus caudatus)
pulvinar thalami
stria medullaris thalami
colliculus inferior corporis quadrigemini
hemisphaerium cerebelli
colliculus superior corporis quadrigemini
corpus pineale
vermis cerebelli

Fig. 173.

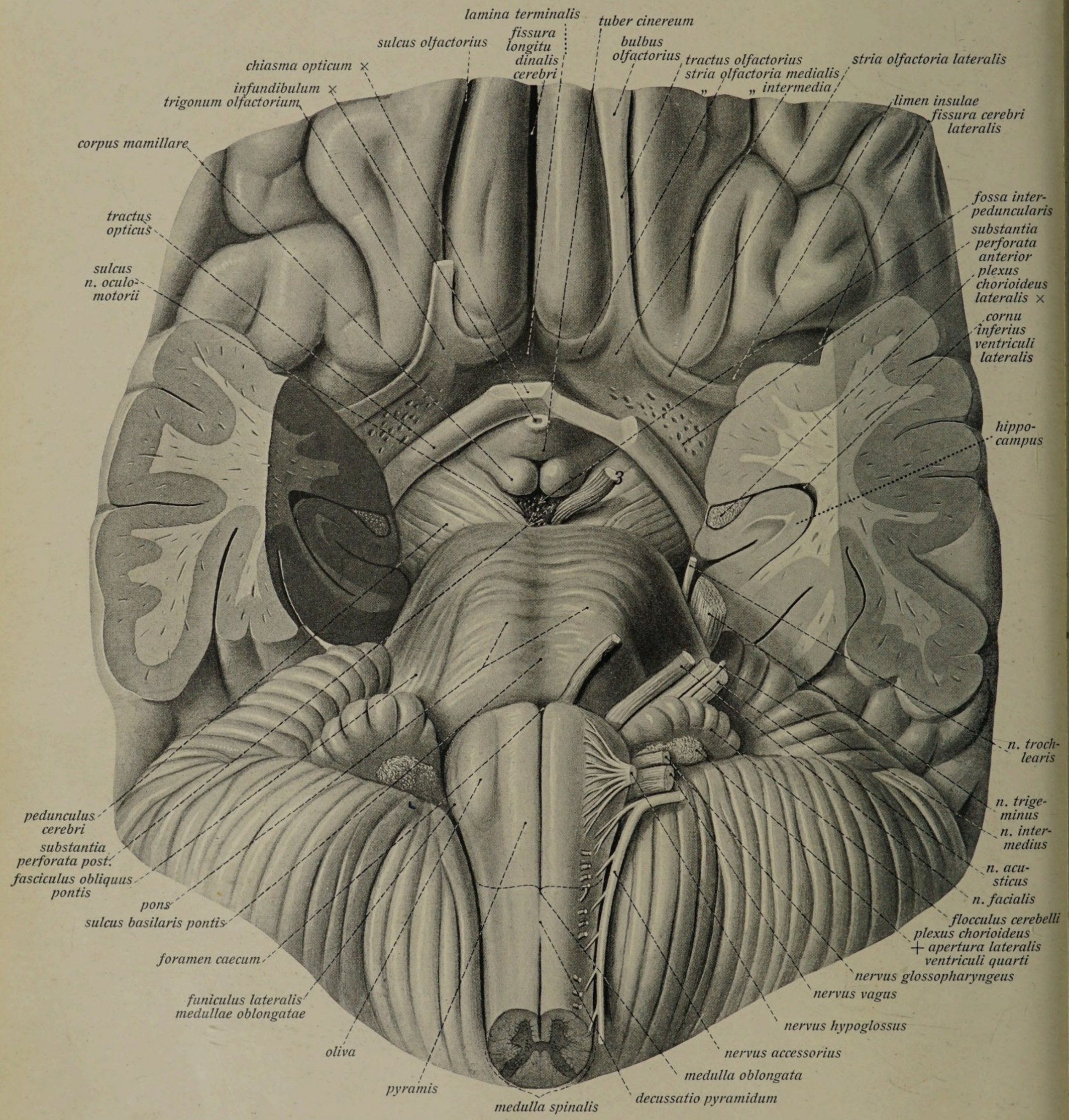
lamina terminalis
tuber cinereum
fissura longitudinalis cerebri
sulcus olfactorius
bulbus olfactorius
tractus olfactorius
stria olfactoria lateralis
stria olfactoria medialis
„ intermedia
chiasma opticum
infundibulum
trigonum olfactorium
limen insulae
fissura cerebri lateralis
corpus mamillare
fossa interpeduncularis
substantia perforata anterior
plexus chorioideus lateralis
tractus opticus
sulcus n. oculomotorii
cornu inferius ventriculi lateralis
hippocampus
3
n. trochlearis
n. trigeminus
n. intermedius
n. acusticus
n. facialis
flocculus cerebelli
plexus chorioideus
apertura lateralis ventriculi quarti
nervus glossopharyngeus
nervus vagus
nervus hypoglossus
nervus accessorius
medulla oblongata
decussatio pyramidum
pyramis
medulla spinalis
oliva
funiculus lateralis medullae oblongatae
foramen caecum
pons
sulcus basilaris pontis
substantia perforata post.
fasciculus obliquus pontis
pedunculus cerebri

Fig. 174.

The Central Nervous System. The Brain. (Cont.)

Fig. 174. The structures at the base of the brain, somewhat enlarged. The anterior ends of both temporal lobes are cut away and the optic nerves are cut close to the chiasma. A portion of the left optic tract is removed.
The roots of the cranial nerves are retained on the left side. 3 = oculomotor, 6 = abducens.

The Principal Conducting Paths of the Central Nervous System.

The cerebrum contains mainly three kinds of conducting paths, which form the greater part of the white substance at the level of the corpus callosum and of the *centrum semiovale* (Fig. 162) just above. According to their course they fall into three main groups.

I. Commissural fibres passing from one hemisphere to the other. The most important commissural paths are

1. The *callosal radiation* may be divided into the *frontal* portion passing from the genu, the *parietal* and *temporal* portions from the trunk and the *occipital* portion passing backwards. Belonging to the same system is the *tapetum*, passing from the splenium of the corpus callosum to the lateral walls of the posterior and inferior cornua. It is a part of the callosal radiation (p. 188). Fig. 195—197, 205.

2. The *anterior commissure* (olfactory commissure) unites, essentially, the two temporal lobes and is a long curved tract visible for a short distance in front of the pillars of the fornix and behind the terminal lamina (Fig. 178, 183, 196, 197), but elsewhere it is concealed in the substance of the hemispheres. It passes under the head of the caudate nucleus and in front of the anterior end of the lenticular nucleus towards the insula *(anterior part)*, and then curves around into the temporal lobe *(posterior part)* (Fig. 178, 183, 196).

3. The *hippocampal commissure* (fornix transversus) is the transverse connection between the two hippocampi. It occupies the space between the diverging crura of the fornix, below the splenium of the callosum (Fig. 167).

II. Association Paths.

These unite different parts of the same hemisphere and are divisible into short or *arcuate fibres* (Fig. 176) and long fibres. The most important of the latter are the *superior longitudinal fasciculus* (Fig. 175), the *inferior longitudinal fasciculus* (Fig. 176), the *uncinate fasciculus* (Fig. 175) and the *cingulum* (Fig. 176).

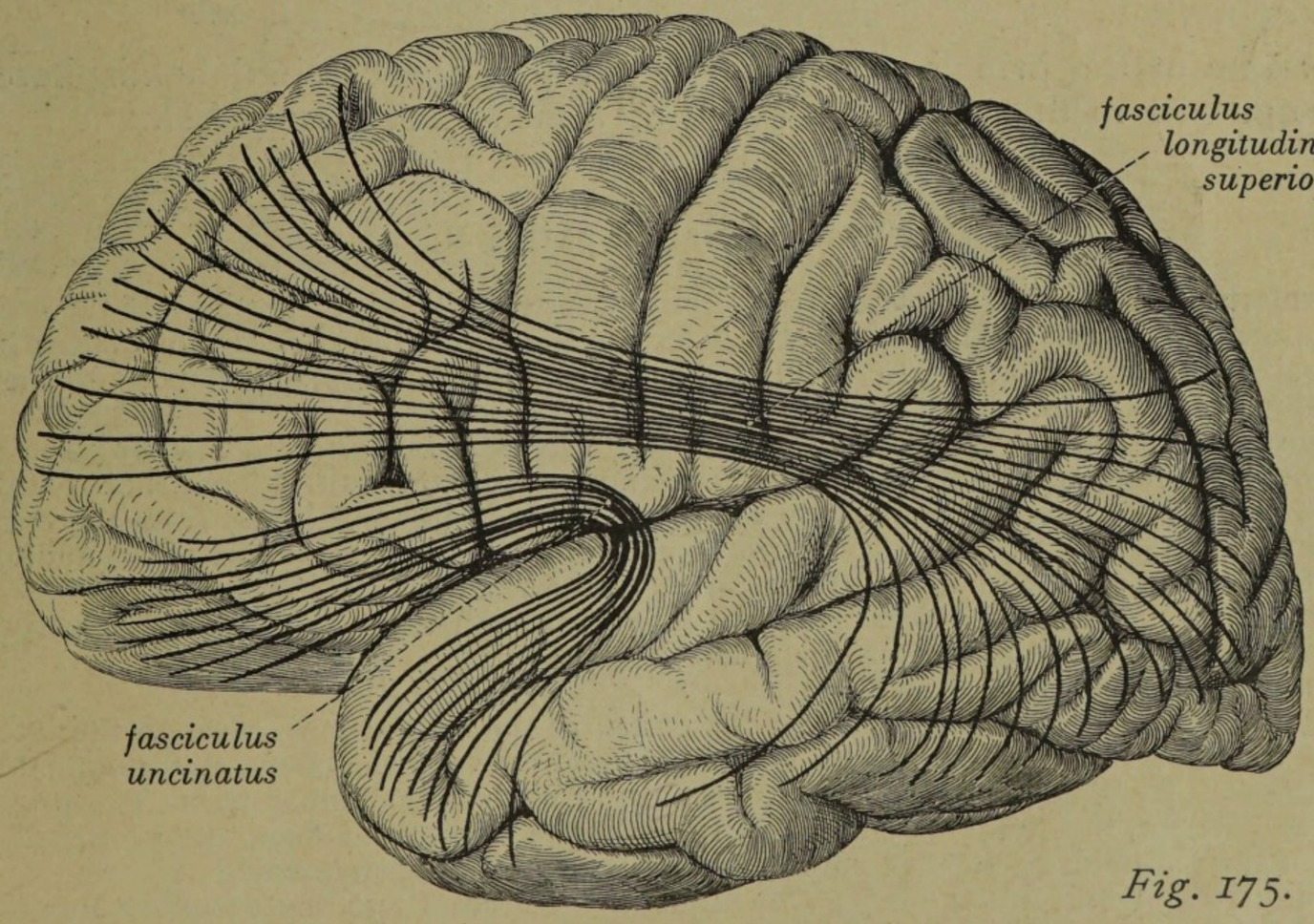

Fig. 175.

Fig. 175. Some of the principal association paths of the cerebral hemisphere projected upon its lateral surface (schematic).

The Central Nervous System. The Brain. (Cont.)

Fig. 177. The optic tracts. (2/1) The brain stem has been removed by a transverse section passing through the anterior colliculi.

Fig. 178. Part of a median longitudinal section of the human brain (compare Fig. 149), somewhat enlarged. * = tuber cinereum.

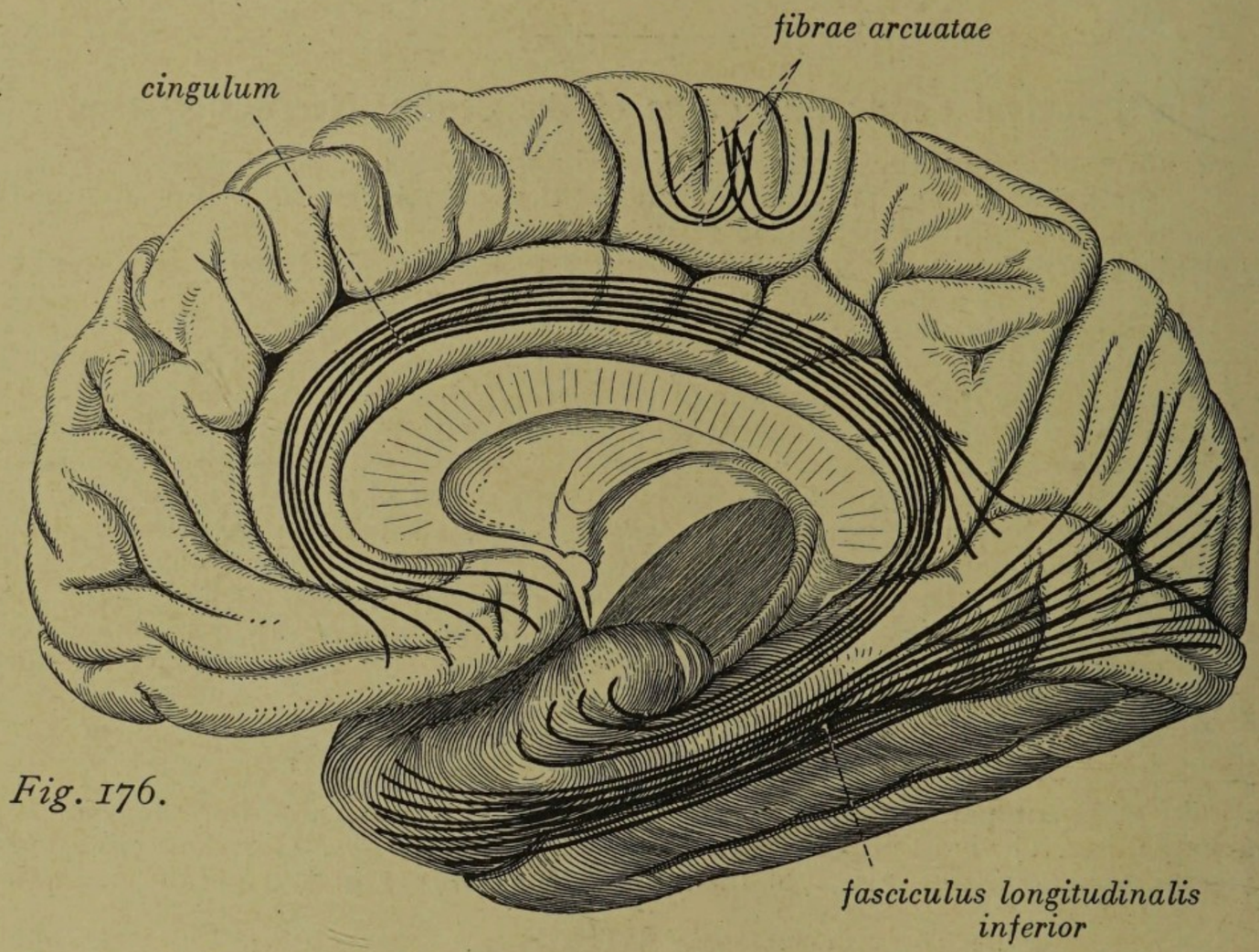

Fig. 176.

Fig. 176. Some of the principal association paths of the cerebral hemisphere projected upon its medial surface exposed by a median section (schematic).

Cerebral conduction paths. (Cont.)

III. **Projection fibres.** These connect the cerebral cortex with lower portions of the central nervous system or these with the cortex. They form what is termed the *corona radiata*. They are either long or short, the former going through the internal capsule and the crusta of the cerebral peduncles to the spinal cord, medulla oblongata and pons.

a) **Short paths.** The most important are 1. The *thalamic radiation*, connecting the cortex of all four lobes with the thalamus, and conversely the thalamus with the cortex (tegmental path).

2. Fibres to the optic and auditory cortex (occipital and temporal lobes) from the corpora quadrigemina, geniculate bodies and thalamus (central optic radiation and central part of the auditory path).

3. Fibres of the anterior portion of the cortex to the red nucleus.

4. The fornix must also be regarded as a long projection tract; it connects, however, the hippocampus only with the interbrain (corpus mamillare).

b) **Long projection paths.**

1. The motor or pyramidal tracts from the cortex of the central gyri, through the internal capsule and the basis of the cerebral peduncle to the spinal cord and to the nuclei of the motor cranial nerves in the medulla oblongata, pons, etc. This latter part is the so-called corticobulbar tract. The principal portion (cortico-spinal part) of the pyramid crosses to the opposite side of the spinal cord (crossed tract) in the decussation of the pyramids; a smaller portion (direct tract) remains uncrossed.

2. The cortico-pontile tracts are two in number, the frontal and the occipito-temporal, which, in the internal capsule and cerebral peduncle, are separated by the pyramidal tract. Their fibres pass from the cortex of the frontal and occipito-temporal lobes to the nuclei of the pons. Associated with them are the fibres from the pons nuclei to the cerebellar cortex (pontocerebellar tracts).

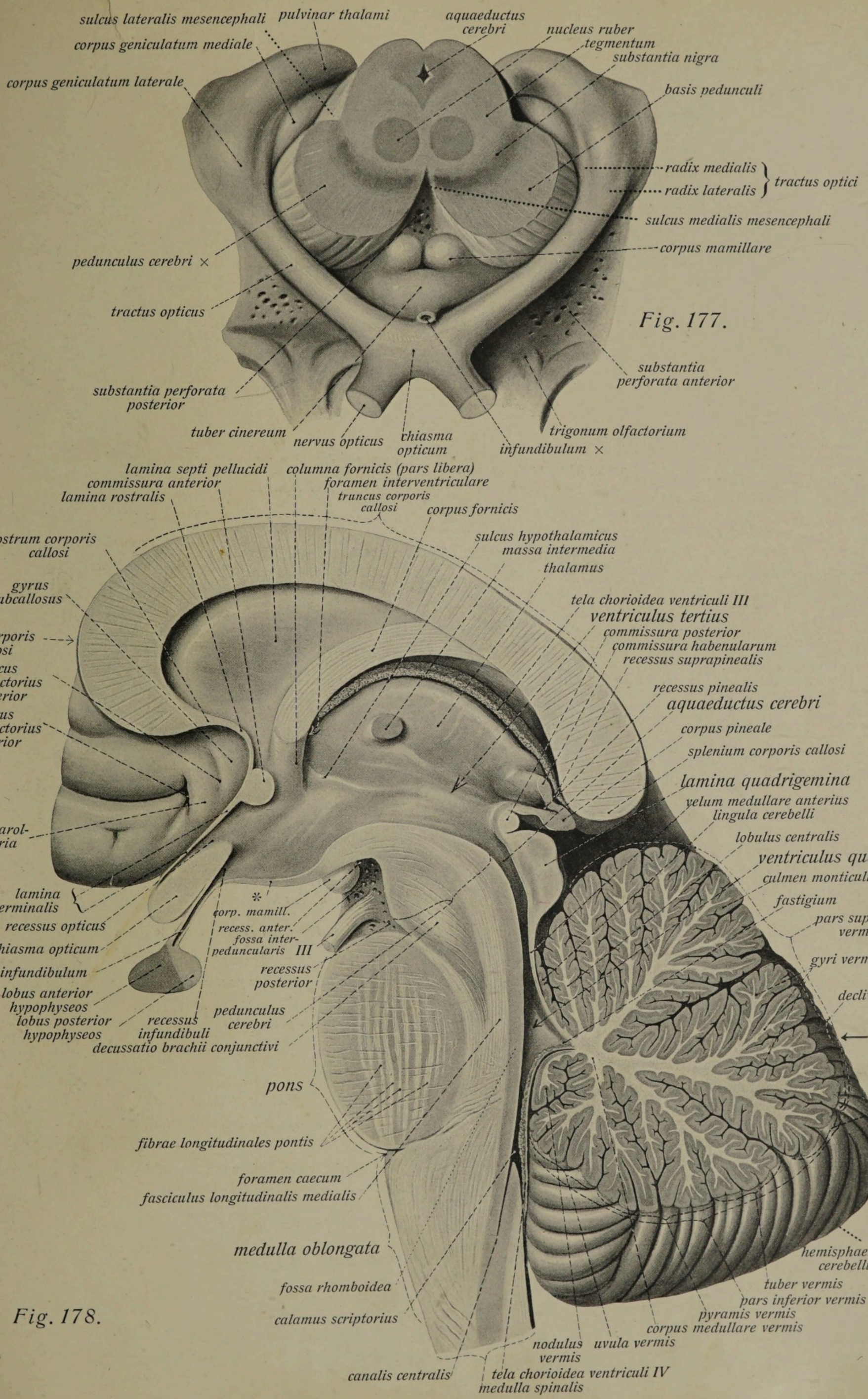

Fig. 177.

Fig. 178.

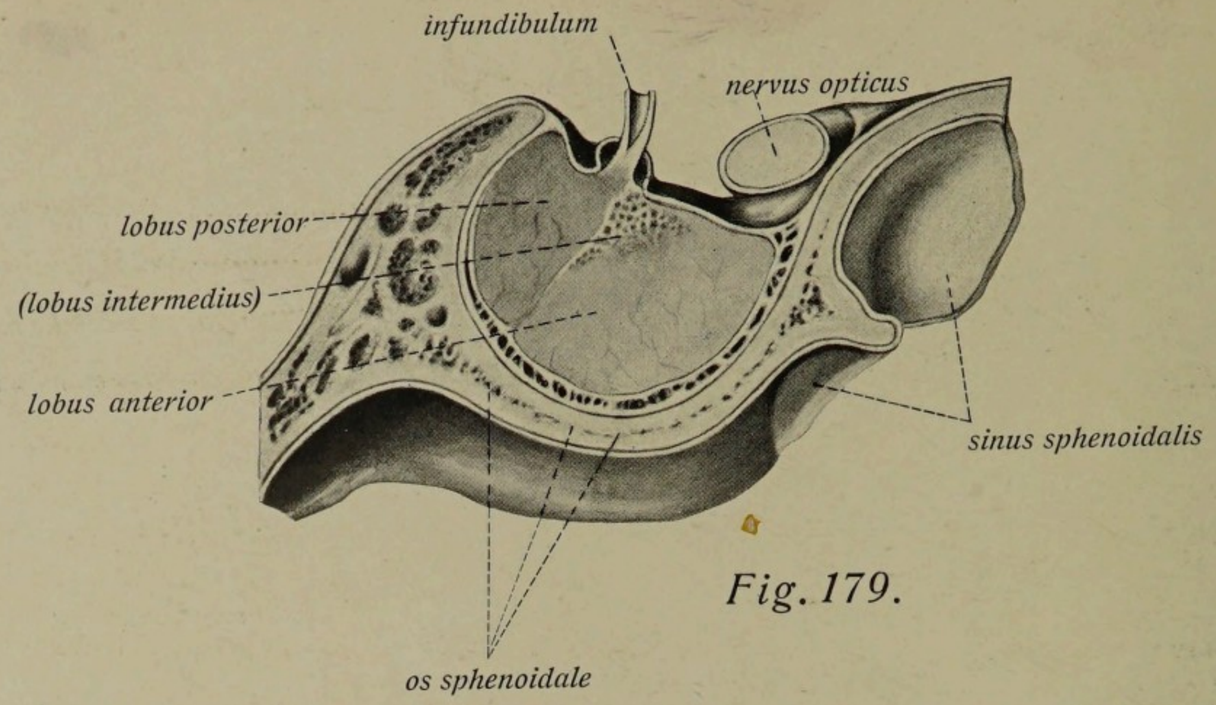

Fig. 179.

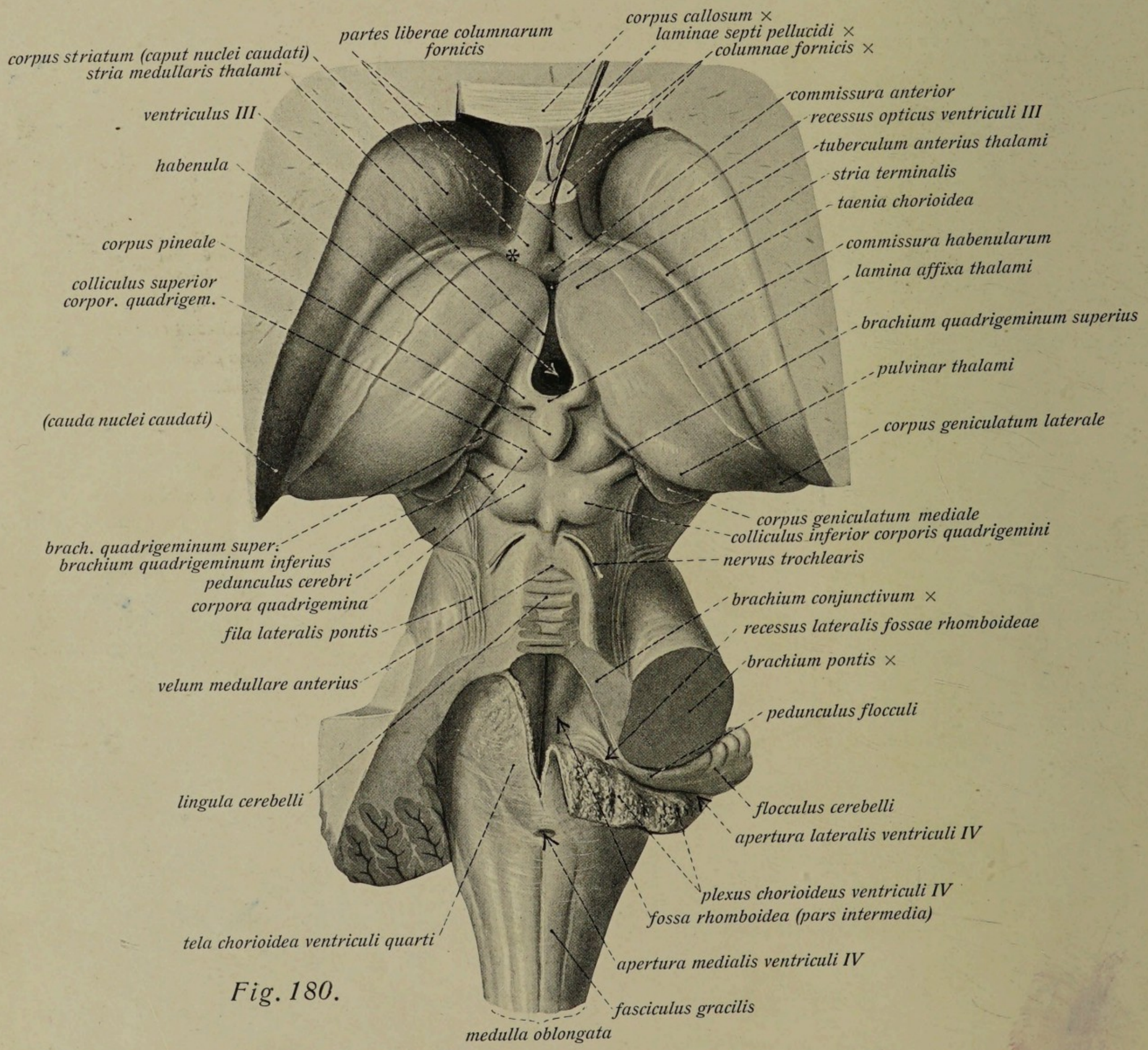

Fig. 180.

The Central Nervous System. The Brain. (Cont.)

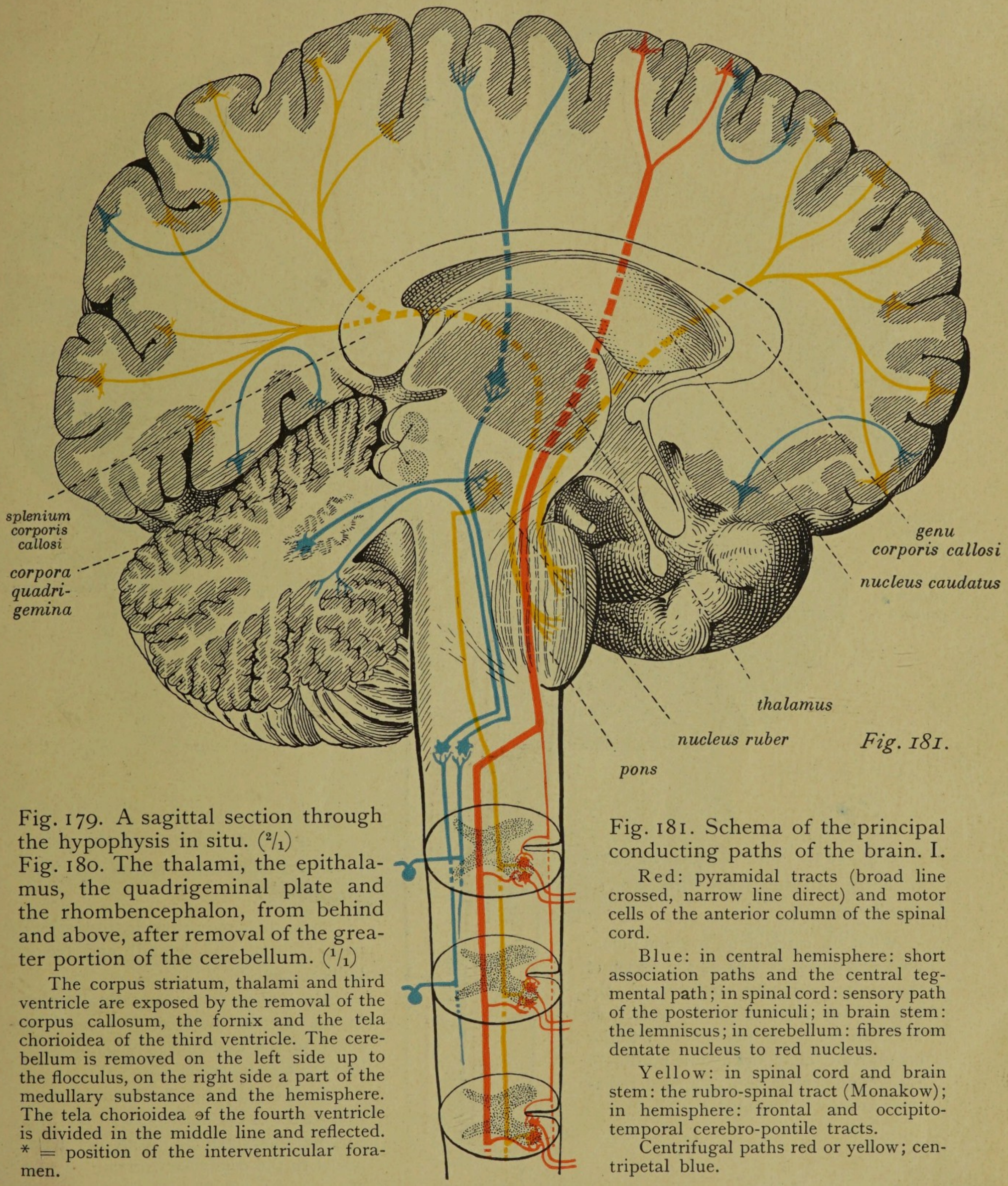

Fig. 181.

Fig. 179. A sagittal section through the hypophysis in situ. (2/1)
Fig. 180. The thalami, the epithalamus, the quadrigeminal plate and the rhombencephalon, from behind and above, after removal of the greater portion of the cerebellum. (1/1)

The corpus striatum, thalami and third ventricle are exposed by the removal of the corpus callosum, the fornix and the tela chorioidea of the third ventricle. The cerebellum is removed on the left side up to the flocculus, on the right side a part of the medullary substance and the hemisphere. The tela chorioidea of the fourth ventricle is divided in the middle line and reflected. * = position of the interventricular foramen.

Fig. 181. Schema of the principal conducting paths of the brain. I.

Red: pyramidal tracts (broad line crossed, narrow line direct) and motor cells of the anterior column of the spinal cord.

Blue: in central hemisphere: short association paths and the central tegmental path; in spinal cord: sensory path of the posterior funiculi; in brain stem: the lemniscus; in cerebellum: fibres from dentate nucleus to red nucleus.

Yellow: in spinal cord and brain stem: the rubro-spinal tract (Monakow); in hemisphere: frontal and occipito-temporal cerebro-pontile tracts.

Centrifugal paths red or yellow; centripetal blue.

The Central Nervous System. The Brain. (Cont.)

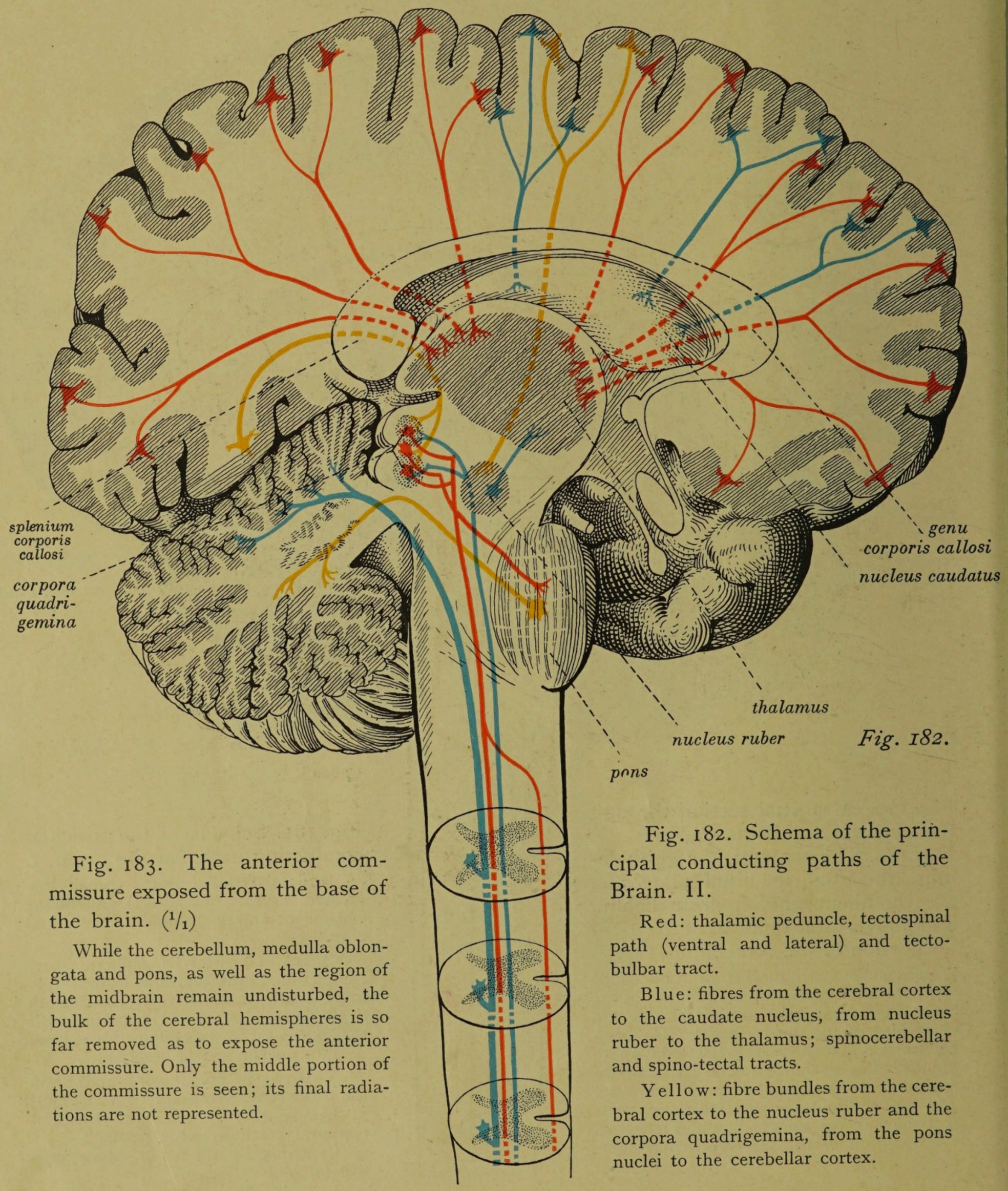

Fig. 182.

Fig. 183. The anterior commissure exposed from the base of the brain. (1/1)

While the cerebellum, medulla oblongata and pons, as well as the region of the midbrain remain undisturbed, the bulk of the cerebral hemispheres is so far removed as to expose the anterior commissure. Only the middle portion of the commissure is seen; its final radiations are not represented.

Fig. 182. Schema of the principal conducting paths of the Brain. II.

Red: thalamic peduncle, tectospinal path (ventral and lateral) and tecto-bulbar tract.

Blue: fibres from the cerebral cortex to the caudate nucleus, from nucleus ruber to the thalamus; spinocerebellar and spino-tectal tracts.

Yellow: fibre bundles from the cerebral cortex to the nucleus ruber and the corpora quadrigemina, from the pons nuclei to the cerebellar cortex.

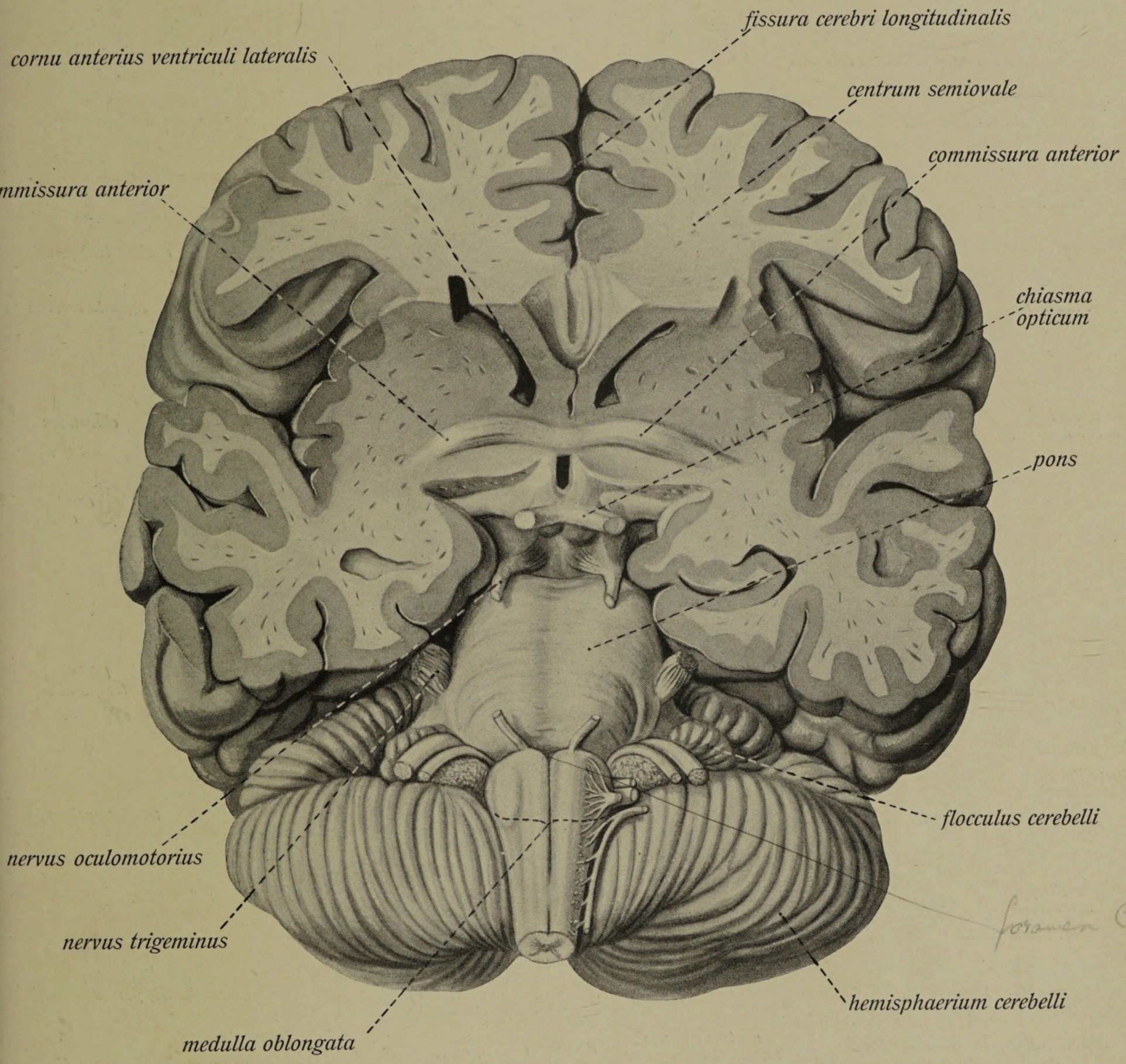
fissura cerebri longitudinalis
cornu anterius ventriculi lateralis
centrum semiovale
ommissura anterior
commissura anterior
chiasma opticum
pons
flocculus cerebelli
nervus oculomotorius
nervus trigeminus
hemisphaerium cerebelli
medulla oblongata

Fig. 183.

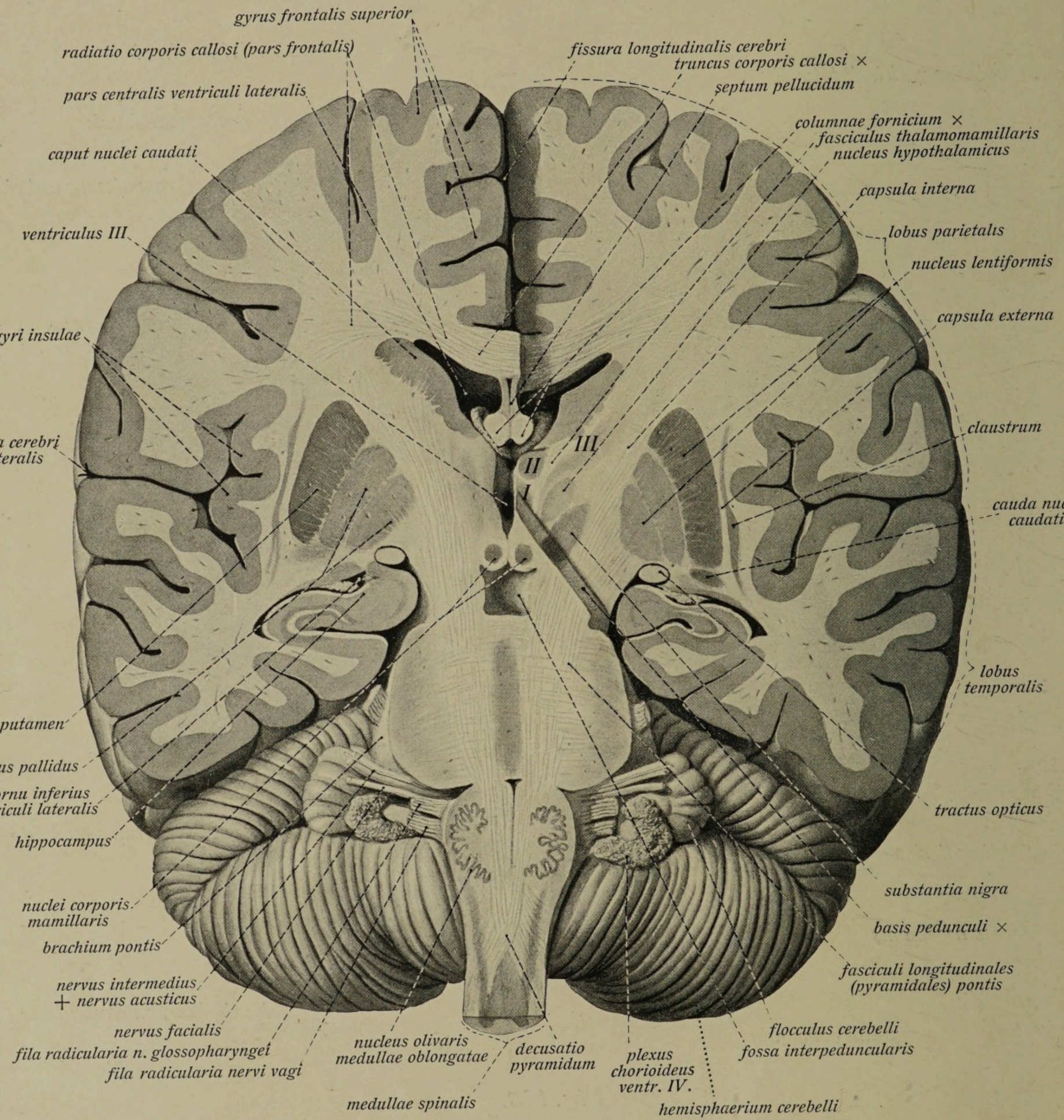
gyrus frontalis superior
radiatio corporis callosi (pars frontalis)
pars centralis ventriculi lateralis
caput nuclei caudati
ventriculus III
gyri insulae
fissura cerebri lateralis
putamen
globus pallidus
cornu inferius ventriculi lateralis
hippocampus
nuclei corporis mamillaris
brachium pontis
nervus intermedius + nervus acusticus
nervus facialis
fila radicularia n. glossopharyngei
fila radicularia nervi vagi
nucleus olivaris medullae oblongatae
medullae spinalis
decusatio pyramidum
plexus chorioideus ventr. IV.
hemisphaerium cerebelli
flocculus cerebelli
fossa interpeduncularis
fasciculi longitudinales (pyramidales) pontis
basis pedunculi ×
substantia nigra
tractus opticus
lobus temporalis
cauda nuclei caudati
claustrum
capsula externa
nucleus lentiformis
lobus parietalis
capsula interna
nucleus hypothalamicus
fasciculus thalamomamillaris
columnae fornicium ×
septum pellucidum
truncus corporis callosi ×
fissura longitudinalis cerebri
III
II
I

Fig. 184.

The Central Nervous System. The Brain. (Cont.)

Fig. 184. A section of the brain in the plane of the brain stem, from in front. (1/1)
On the left the section through the hemisphere is somewhat dorsal to that on the right. I, II, III indicate the anterior, medial and lateral nuclei of the thalamus.

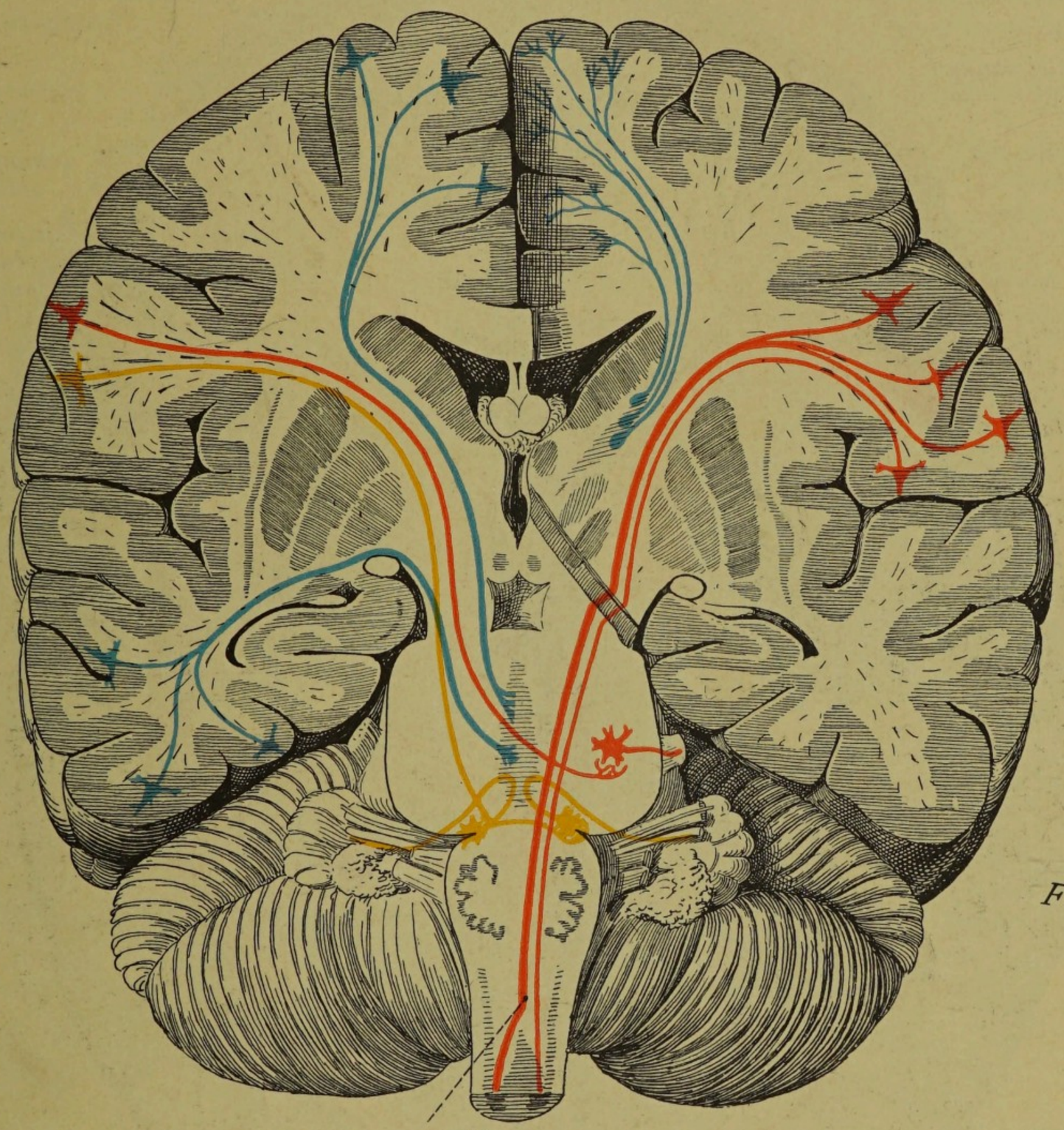

Fig. 185.

Fig. 185. Schema of a number of fibre tracts of the brain shown in the outlines of Fig. 184.

Red: On the right: pyramidal tracts (heavy line crossed, light line, direct) and a motor cell of the trigeminus; on the left: the cortico-bulbar tract to the latter.

Blue: cerebro-pontile tract and fibres from the thalamus to the cortex.

Yellow: motor nerve cells of the facial nerve and the fibres of the cortico-bulbar tract leading to them.

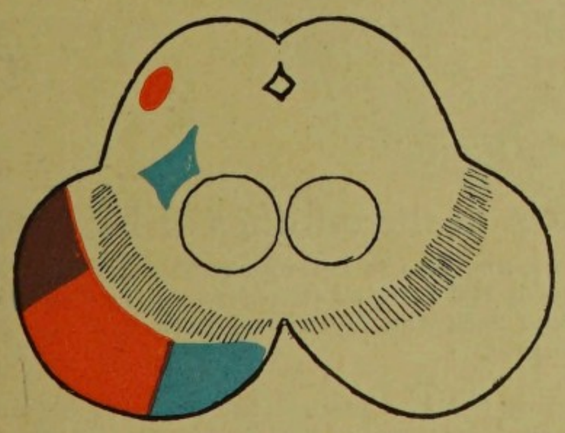

Fig. 186.

Fig. 186. Schema of the position of the principal fibre tracts in the midbrain.

In the basis of the peduncles the pyramidal tracts are red; the frontal cerebro-pontile tract blue; the occipito-temporal cerebro-pontile tract violet. In the tegmentum the lateral lemniscus is red, the medial blue.

The Central Nervous System. The Brain. (Cont.)

Fig. 188. Horizontal section through the brain. (1/1) On the left the section passes through the thalamus; on the right, about 1 cm. deeper through the corpora quadrigemina and the hypothalamic nucleus.

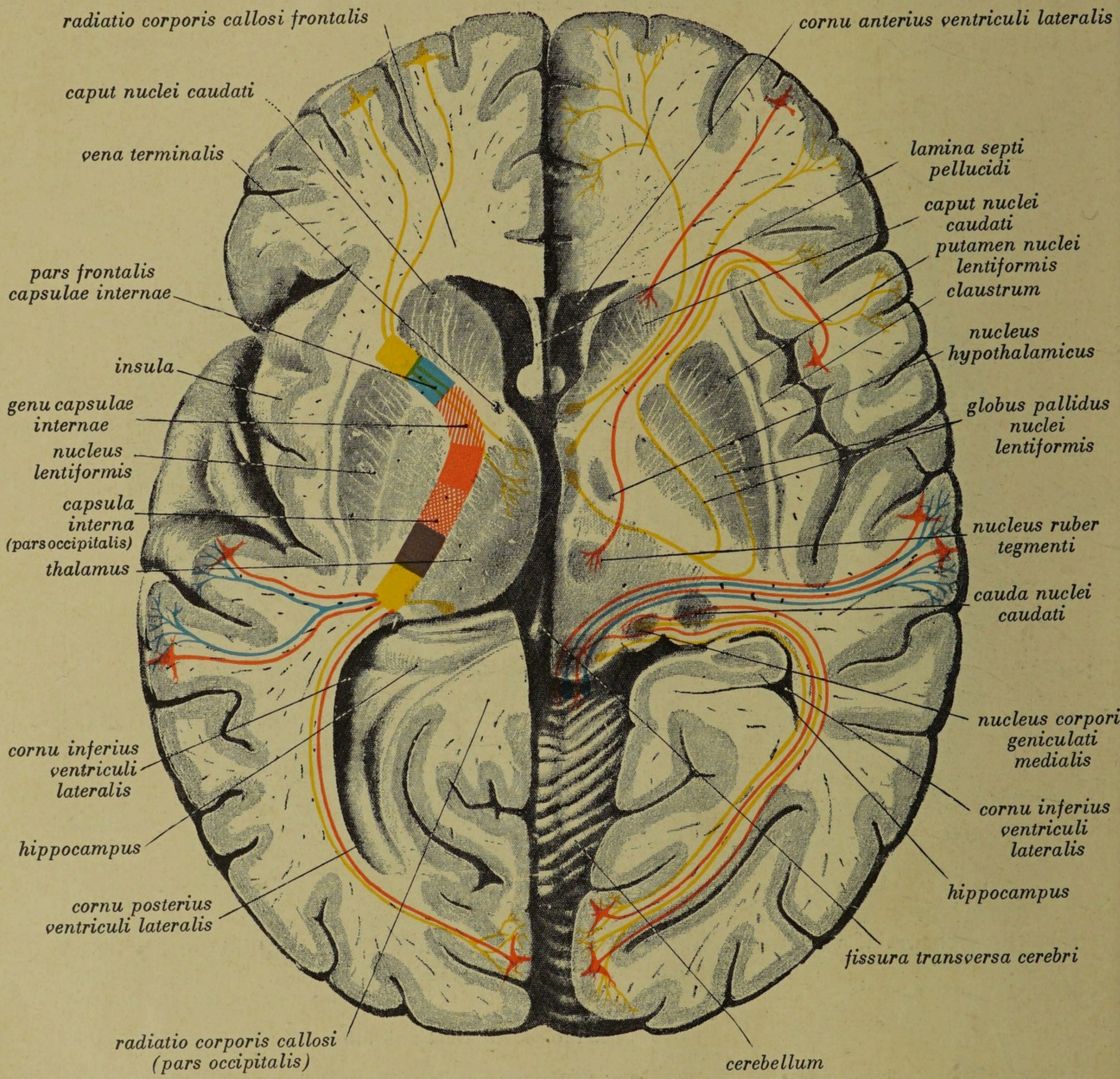

Fig. 187. Schema of a number of fibre tracts of the brain shown in the outlines of Fig. 188.

On the left is shown the arrangement of the paths traversing the internal capsule, in the anterior limb: the anterior thalamic radiation yellow, the frontal cerebro-pontile tract blue, the cortico-bulbar tract red striated (the genu of the capsule). In the posterior limb: the pyramidal tract for the arm red, for the leg cross hatched red; the tegmental path and the occipito-temporal cerebro-pontile tract violet; the central optic and auditory paths yellow.

In addition the following are shown:

Yellow: fibres from the cortex to thalamus (left) and vice versa (right), passing partly through the internal capsule, partly through the lenticular ansa; fibres from anterior colliculus and thalamus to occipital cortex (central optic radiation).

Blue: fibres from the posterior colliculi and medial geniculate body to temporal cortex (central auditory tract).

Red: fibres from visual cortex to the primary optic centre and from the auditory cortex to the auditory centres in the midbrain; fibres from the cortex to the caudate nucleus and nucleus ruber.

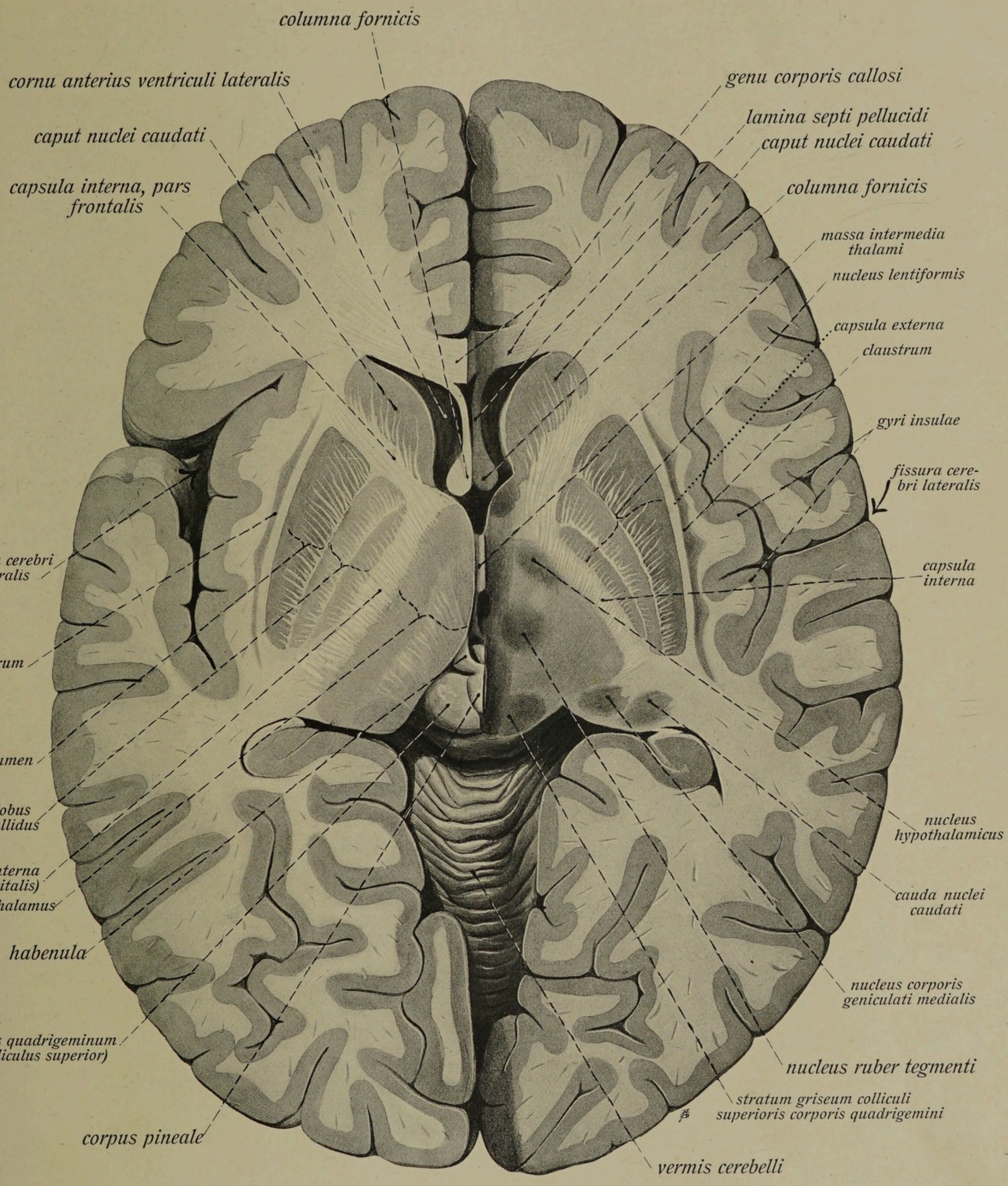
columna fornicis
cornu anterius ventriculi lateralis
caput nuclei caudati
capsula interna, pars frontalis
genu corporis callosi
lamina septi pellucidi
caput nuclei caudati
columna fornicis
massa intermedia thalami
nucleus lentiformis
capsula externa
claustrum
gyri insulae
fissura cerebri lateralis
capsula interna
issura cerebri lateralis
laustrum
putumen
globus pallidus
sula interna s occipitalis)
thalamus
habenula
corpus quadrigeminum (colliculus superior)
corpus pineale
nucleus hypothalamicus
cauda nuclei caudati
nucleus corporis geniculati medialis
nucleus ruber tegmenti
stratum griseum colliculi superioris corporis quadrigemini
vermis cerebelli

Fig. 188.

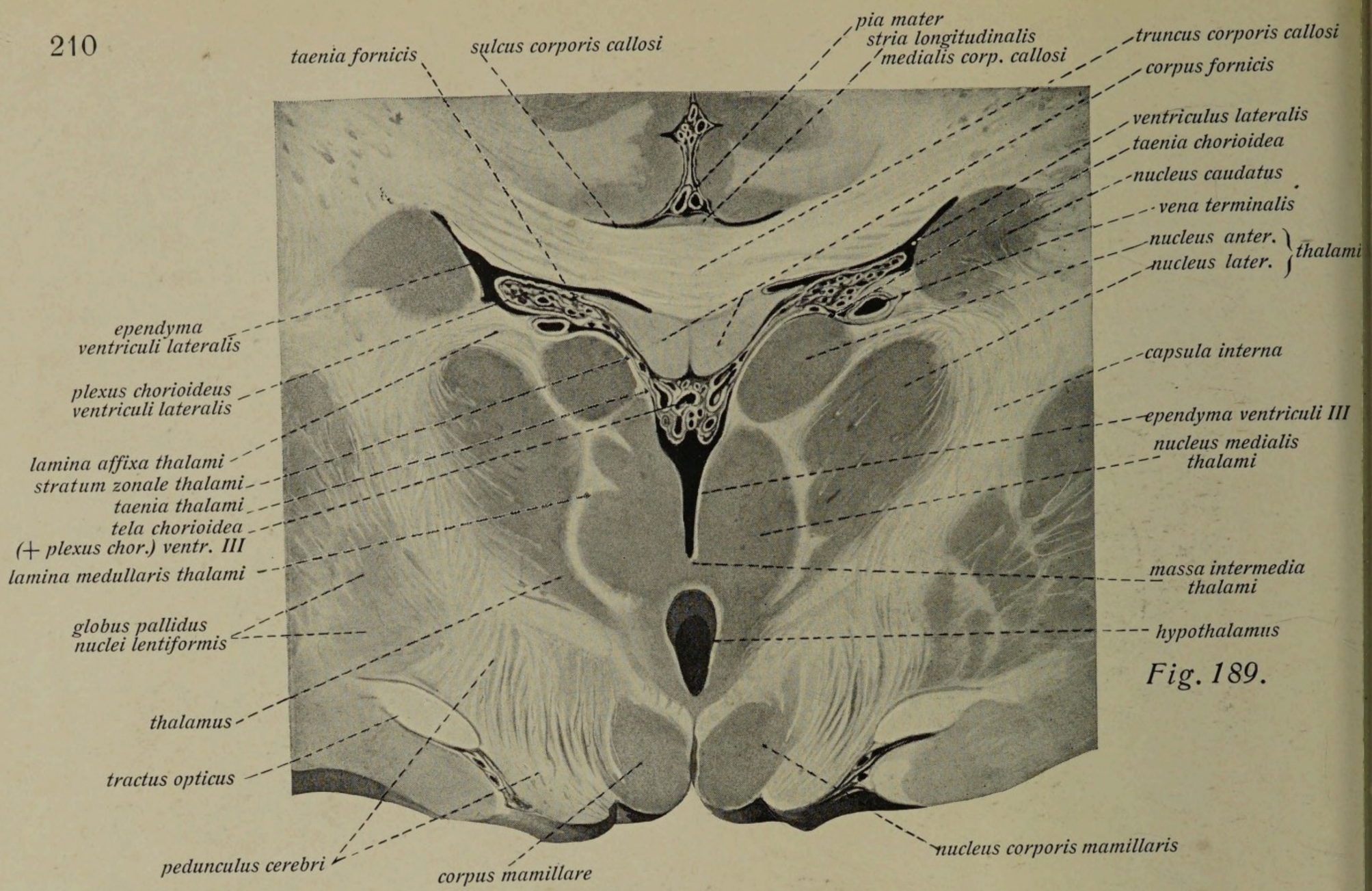

Fig. 189.

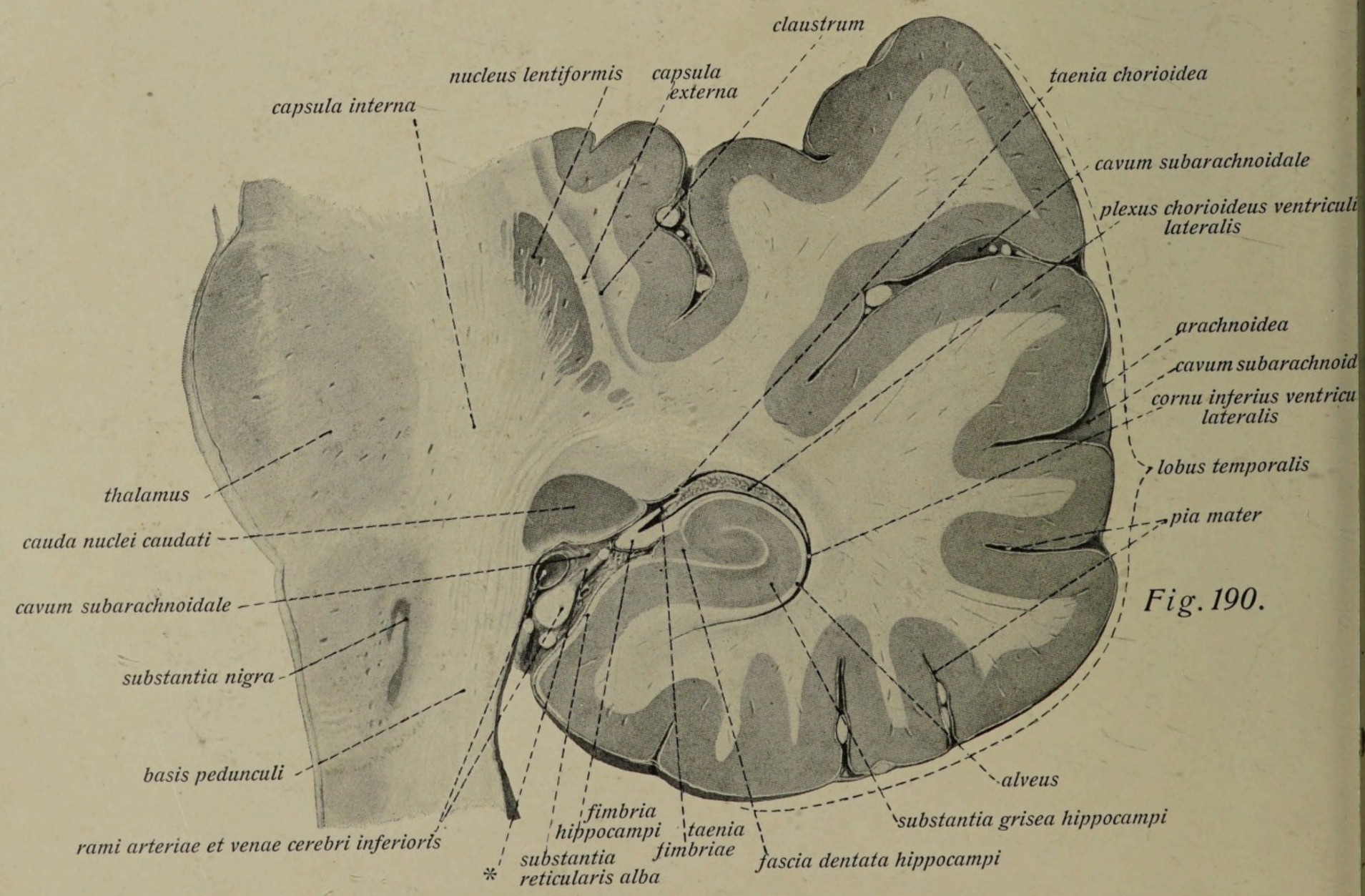

Fig. 190.

Fig. 189. A frontal section through the thalamus, third ventricle, hypothalamus, fornix and corpus callosum. (2/1) (Compare Fig. 205.)

Fig. 190. A frontal section through the temporal lobe and the adjacent portions of the interbrain and midbrain, somewhat enlarged. The pia mater and blood vessels are retained. * = small arterial twig.

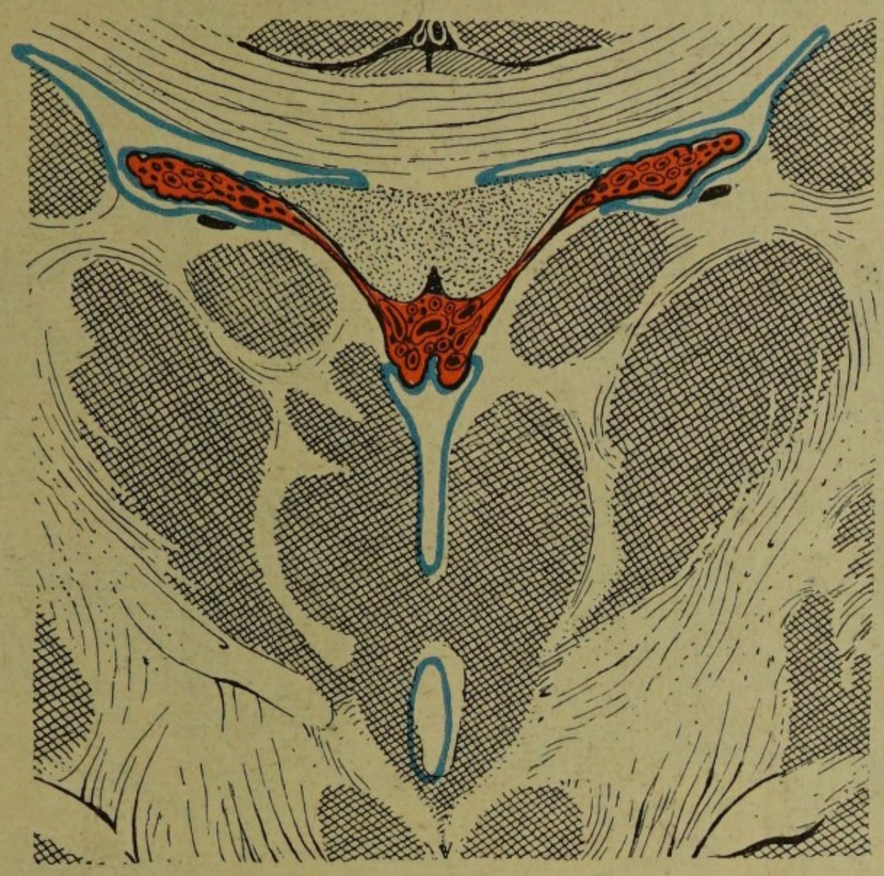

Fig. 191.

Fig. 191. Schema of the relations of the chorioid plexuses of the lateral and third ventricles to the ventricular ependyma.

Chorioid plexuses and pia mater red, ependyma blue.

Fig 192. The course of certain fibre tracts from and to the cerebral cortex.

Red: thalamic peduncle.

Blue: fibres from the cortex to the corpus striatum (caudate nucleus and putamen) and from the latter to the thalamus.

Yellow: on the right: fibres from the globus pallidus to the thalamus and from the thalamus to the cortex (lenticular ansa); on the left: from the cortex to the nucleus ruber and the corpora quadrigemina.

On the right: yellow = lenticular ansa; yellow + red = the peduncular ansa.

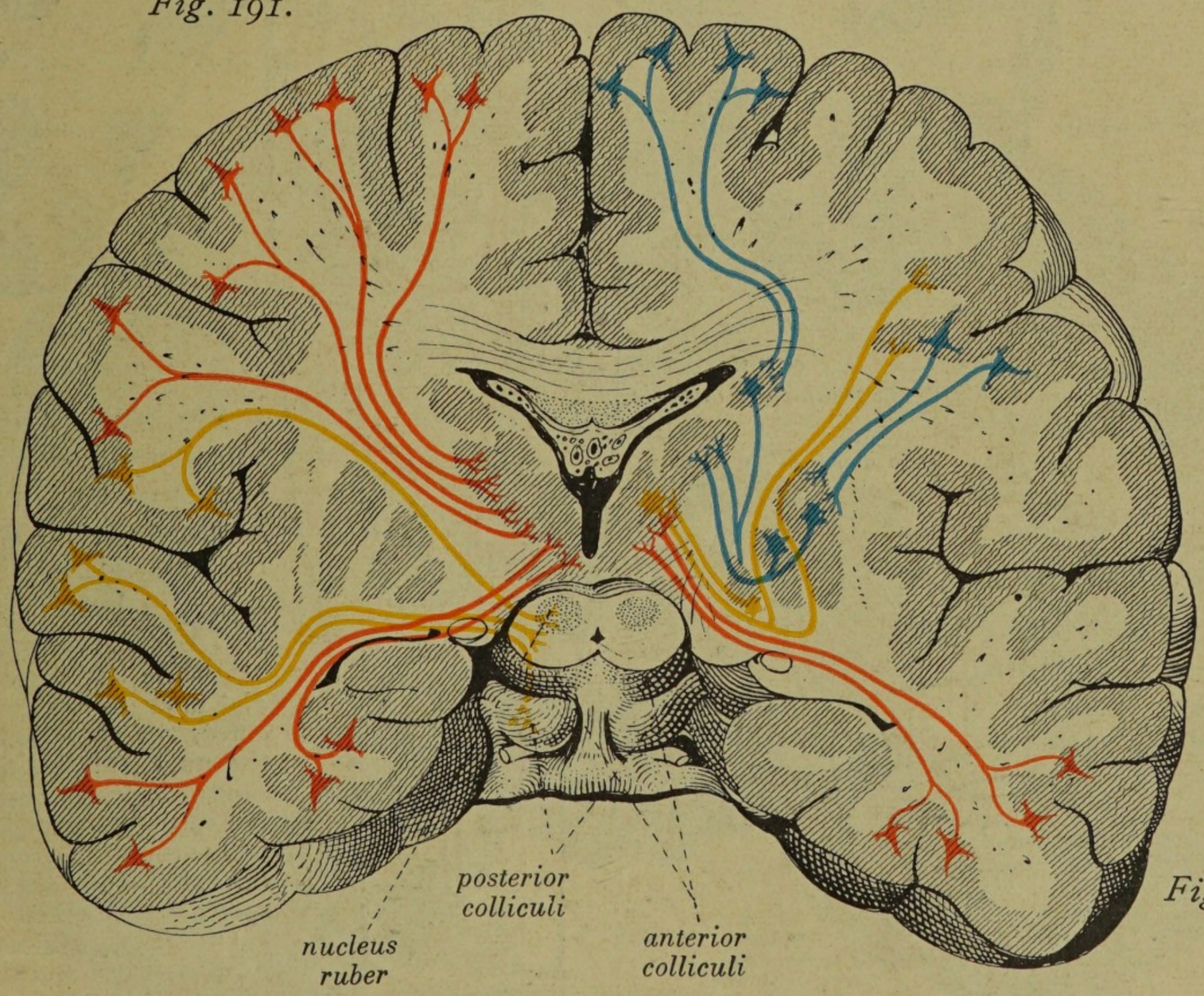

Fig. 192.

Fibre Paths.

Fig. 195. A frontal section of the brain in the region of the anterior part of the septum pellucidum.

Fig. 196. A similar section in the region of the anterior commissure.
In both sections one looks upon the posterior surface of the section.

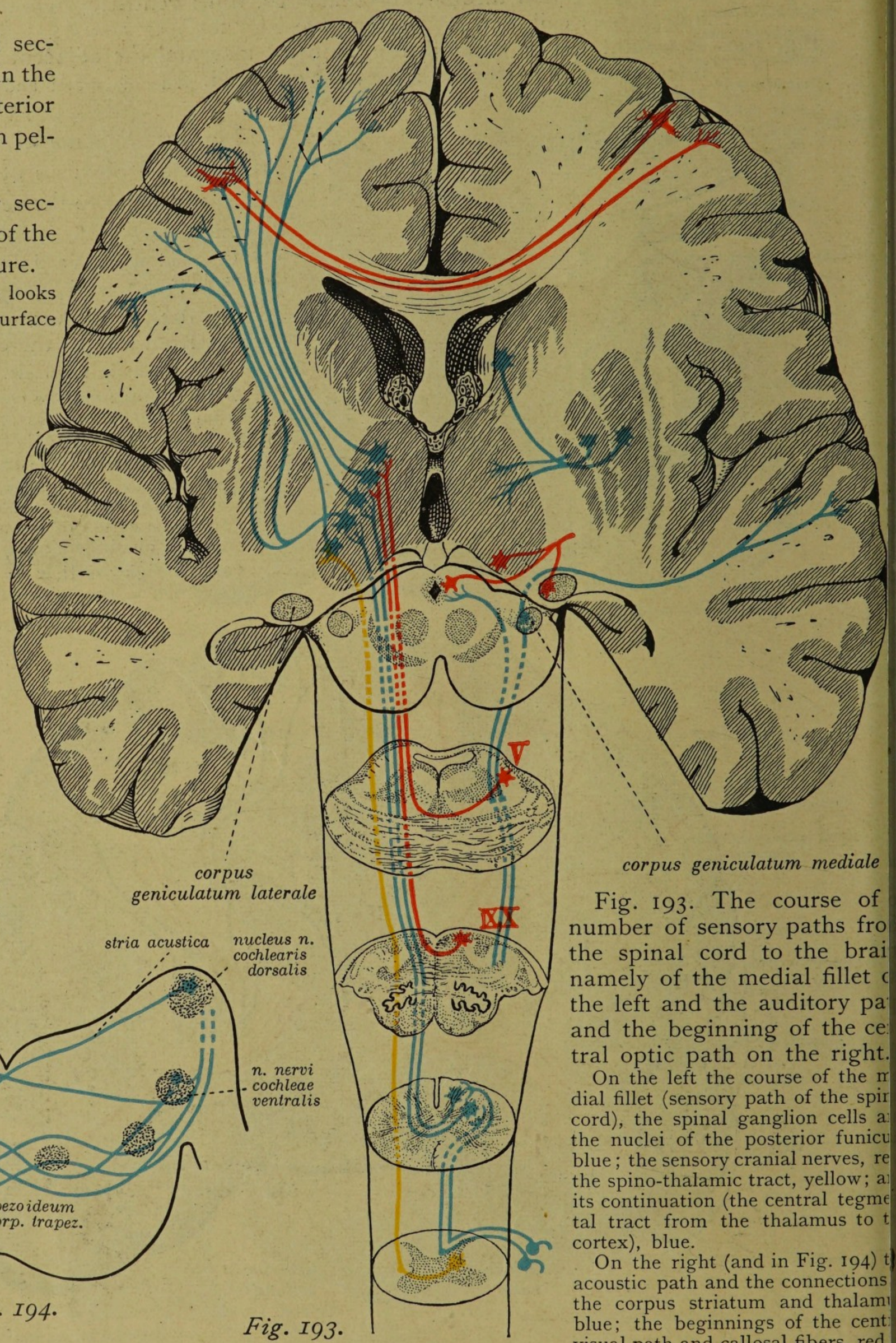

Fig. 193. The course of number of sensory paths fro the spinal cord to the brai namely of the medial fillet c the left and the auditory pa and the beginning of the ce tral optic path on the right.
On the left the course of the m dial fillet (sensory path of the spir cord), the spinal ganglion cells a the nuclei of the posterior funicu blue; the sensory cranial nerves, re the spino-thalamic tract, yellow; a its continuation (the central tegme tal tract from the thalamus to t cortex), blue.
On the right (and in Fig. 194) t acoustic path and the connections the corpus striatum and thalam blue; the beginnings of the cent visual path and callosal fibers, red.

Fig. 194. Schema of the course of the acoustic path in the pons.

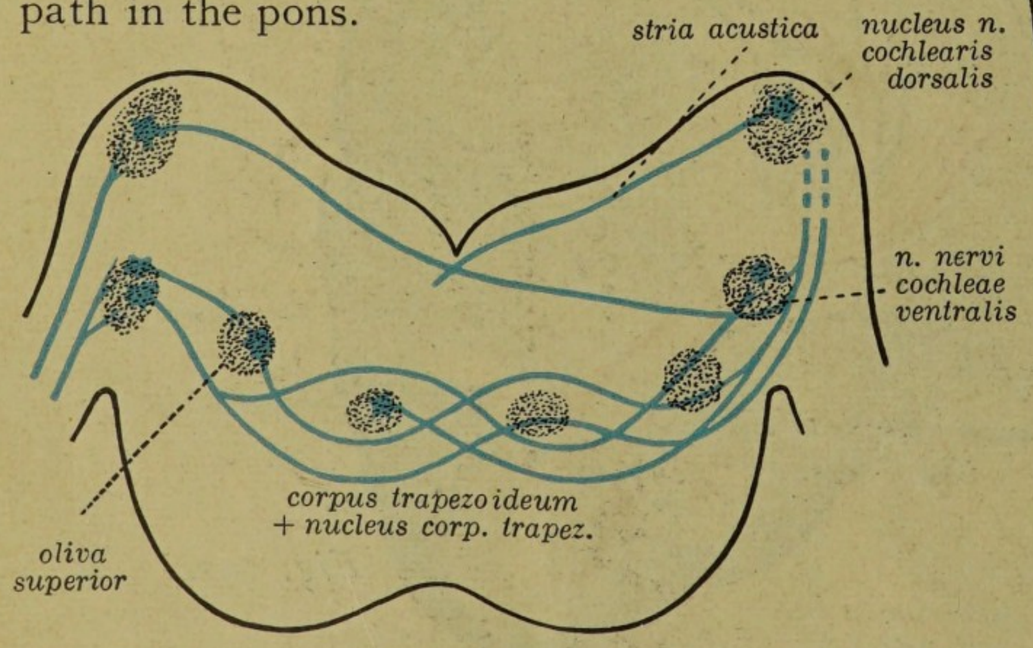

Fig. 194.

Fig. 193.

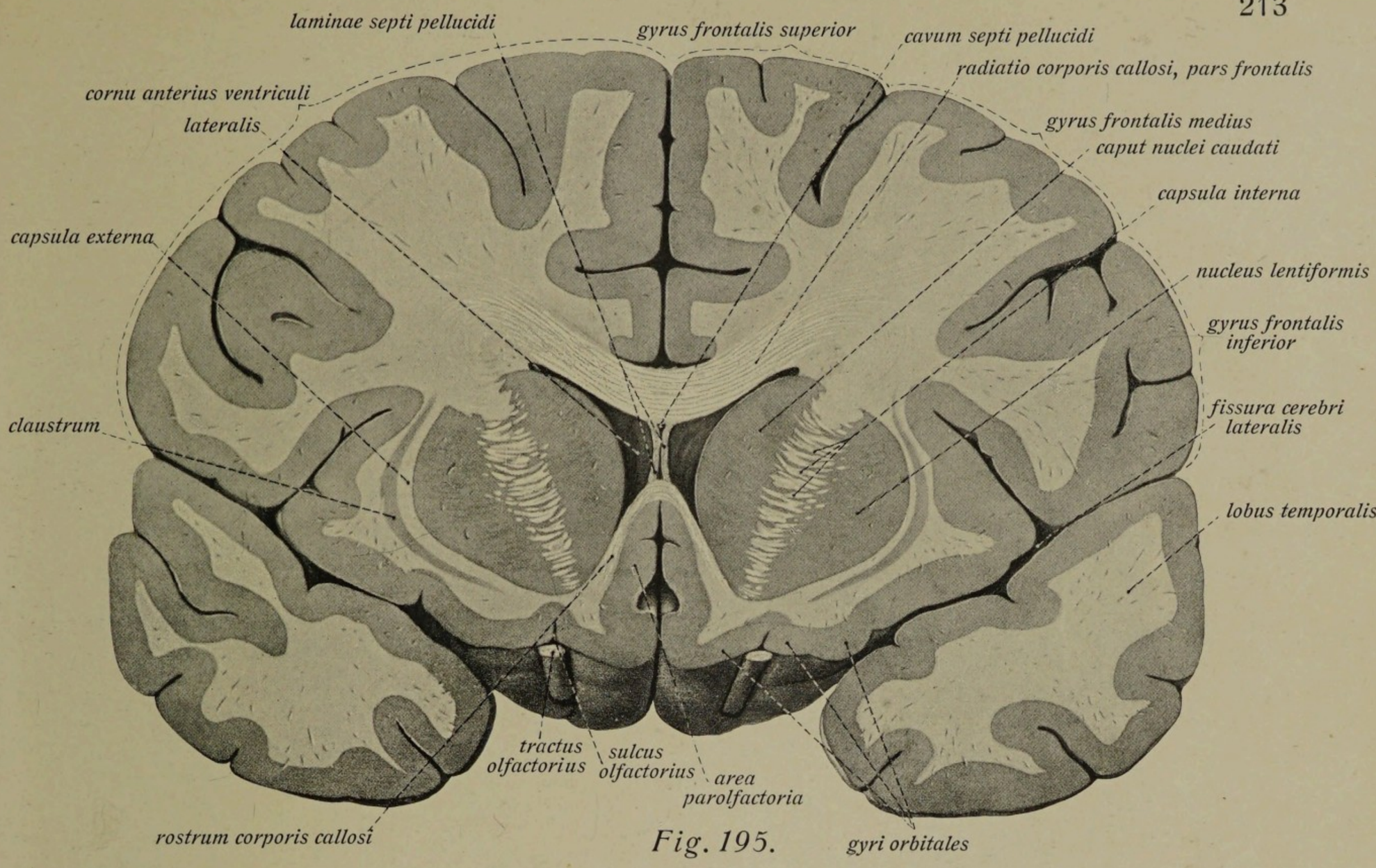

Fig. 195.

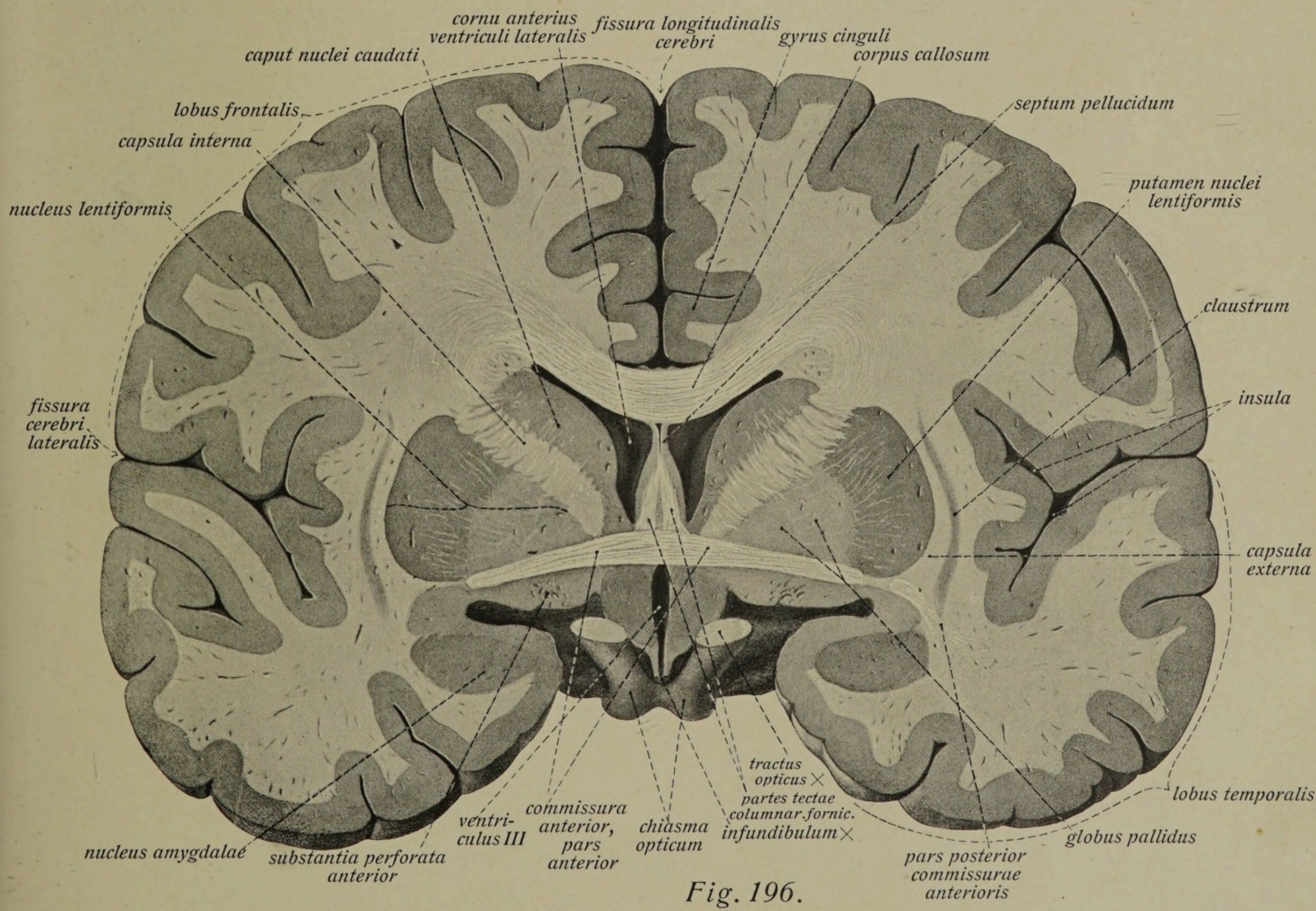

Fig. 196.

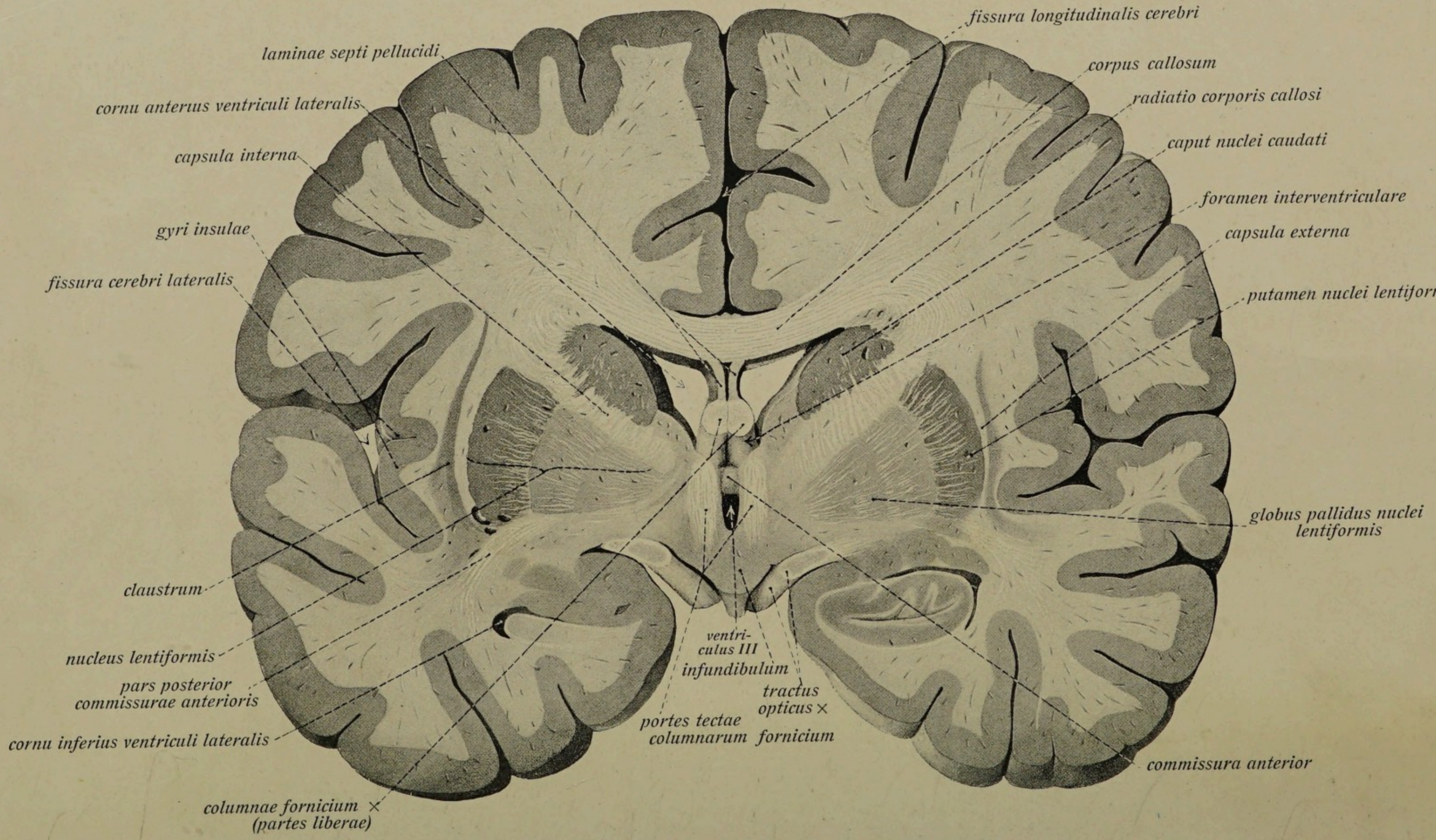

Fig. 197.

Fig. 197. Frontal section of the brain. The section passes through the anterior part of the third ventricle close behind the anterior commissure. (1/1)
One sees the anterior surface of the section.

The Central Nervous System. The Brain. (Cont.)

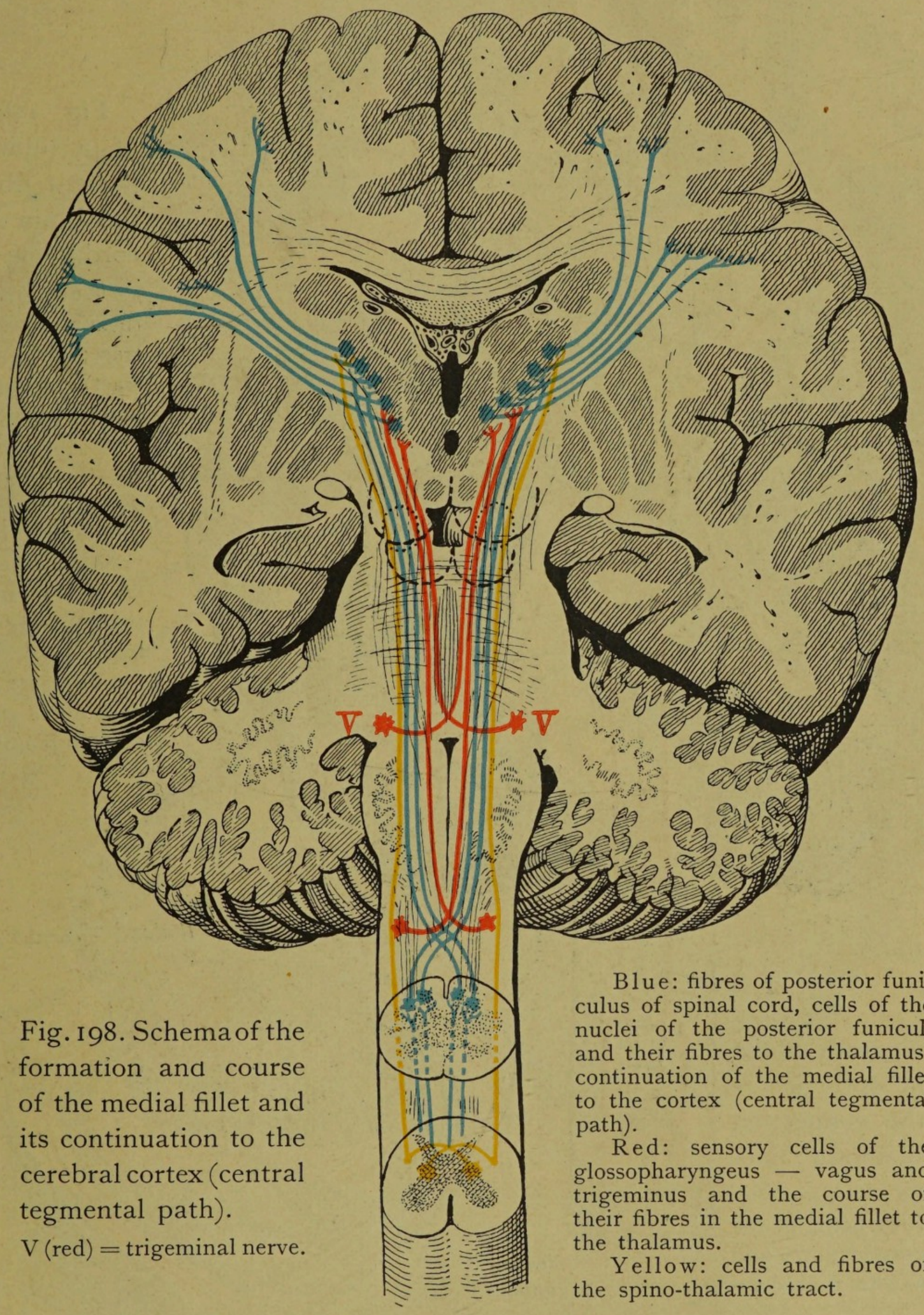

Fig. 197. Frontal section of the brain. The section passes through the anterior part of the third ventricle close behind the anterior commissure. (1/1)
One sees the anterior surface of the section.

Fig. 198. Schema of the formation and course of the medial fillet and its continuation to the cerebral cortex (central tegmental path).
V (red) = trigeminal nerve.

Blue: fibres of posterior funiculus of spinal cord, cells of the nuclei of the posterior funiculi and their fibres to the thalamus; continuation of the medial fillet to the cortex (central tegmental path).

Red: sensory cells of the glossopharyngeus — vagus and trigeminus and the course of their fibres in the medial fillet to the thalamus.

Yellow: cells and fibres of the spino-thalamic tract.

The Central Nervous System. The Brain. (Cont.)

Fibre Paths.

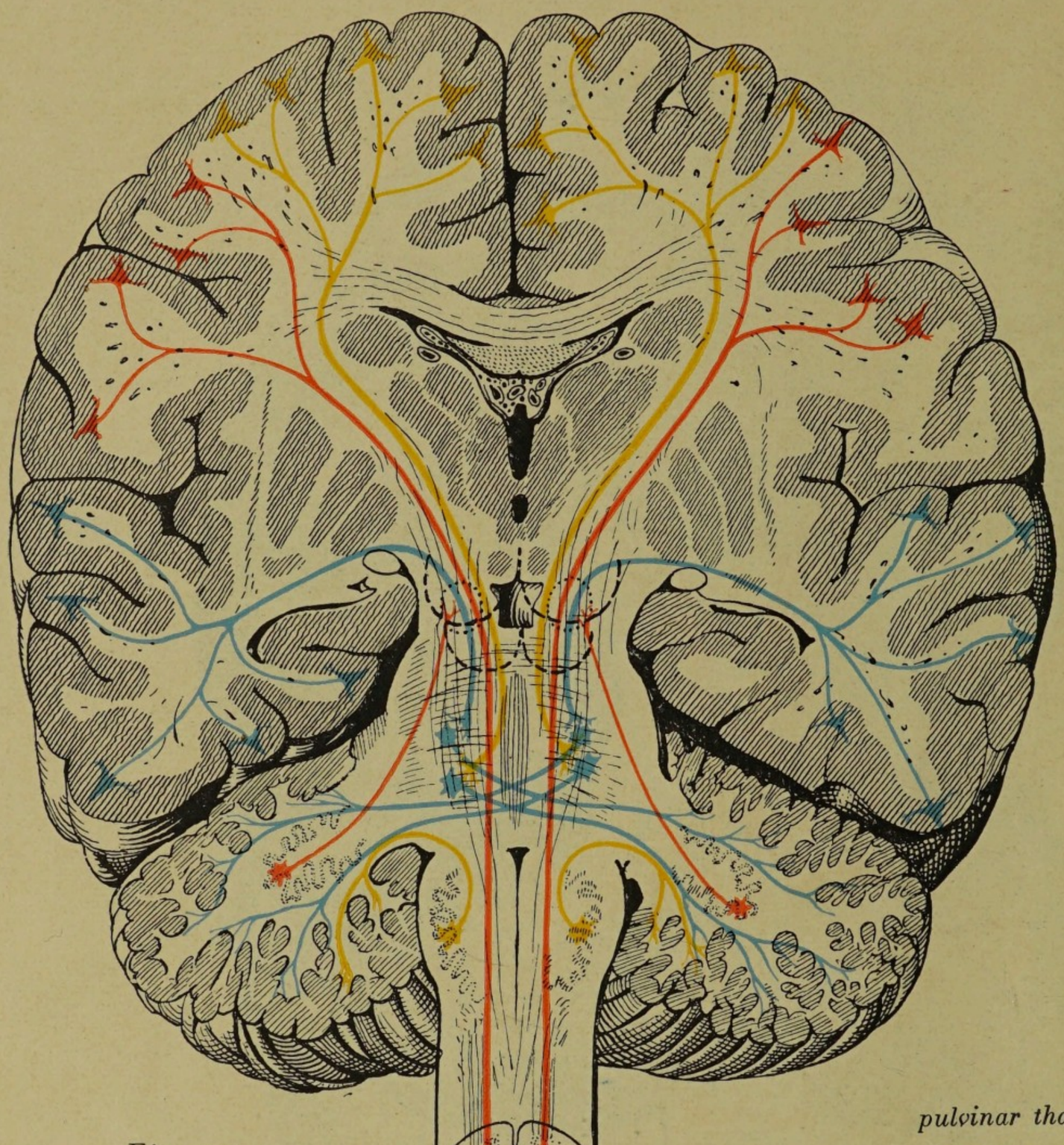

Fig. 199. Diagram of a number of important fibre tracts of the brain and spinal cord.

Red: pyramidal tracts (heavy line the crossed tract; light one the direct tract) and motor cells of the anterior column; also fibres from the dentate nucleus to the corpora quadrigemina.

Blue: fibres from the pons nuclei to the cerebellar cortex and the occipito-temporal cerebro-pontile tract.

Yellow: cerebello-olivary fibres and the frontal cerebro-pontile tract.

Fig. 199.

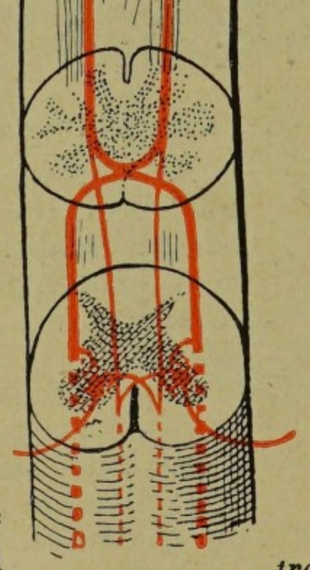

Fig. 200. Diagram of the optic tract, the optic decussation and the connection with the oculomotor nucleus.

Red and blue: paths of the crossed and uncrossed fibres and their connection with the oculomotor nucleus.

Yellow: oculomotor nucleus and oculomotor nerve roots.

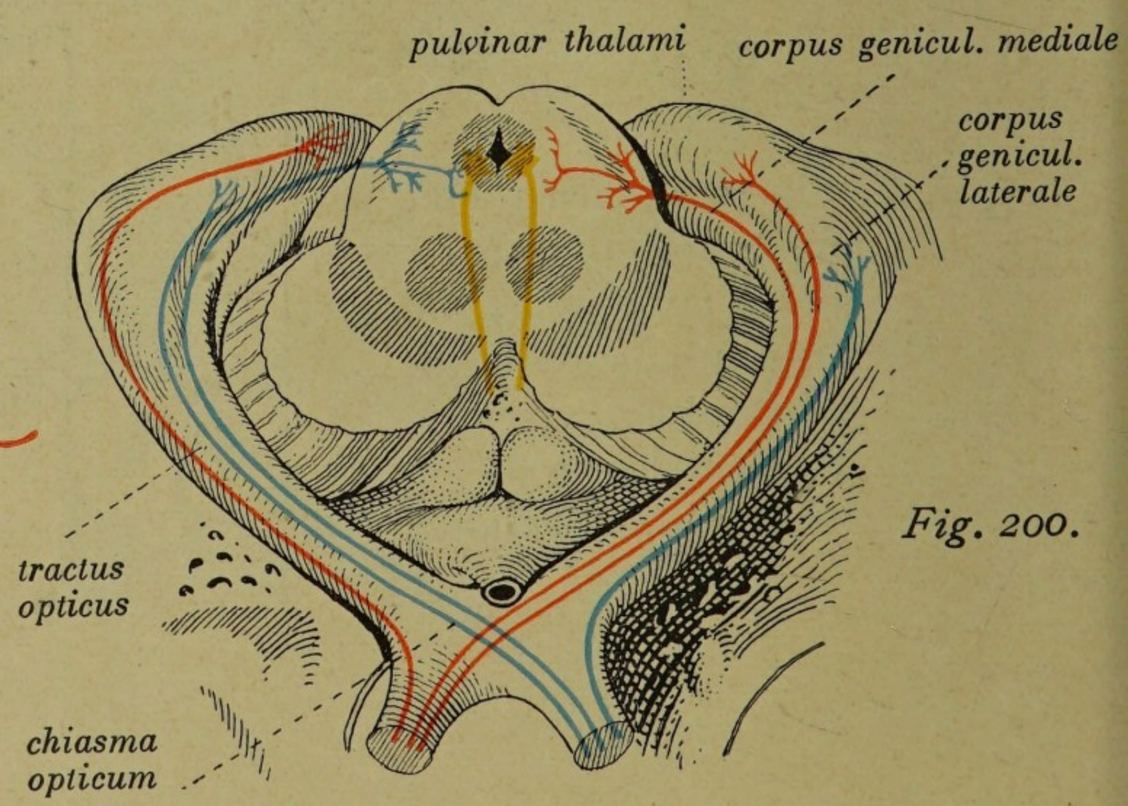

Fig. 200.

The Central Nervus System. The Brain. (Cont.)

Fibre Paths.

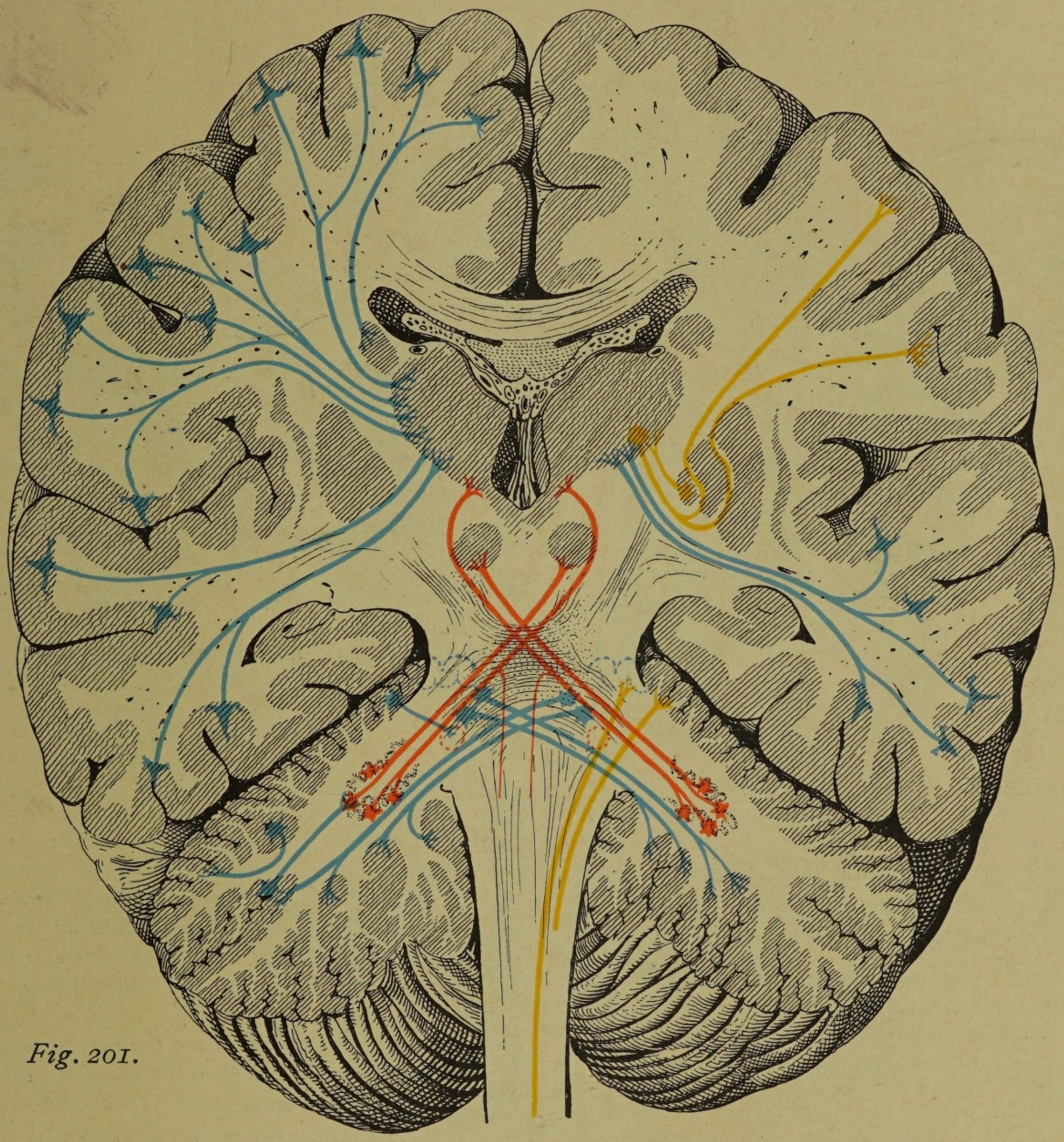

Fig. 201.

Fig. 201. Schema of a series of fibre tracts of the cerebral hemispheres, cerebellum and pons.

red: fibres from the dentate nucleus of the cerebellum to the thalamus and red nucleus and their crossing in the decussation of the brachia conjunctiva; also, as a broken circle, Deiter's vestibular nucleus.

blue: thalamic radiation, fibres from the pons nuclei to the cerebellar cortex and from this to Deiter's nucleus and the dentate nucleus; also association fibres of the cerebellum; as a broken line, the cortex of the vermis.

yellow: the lenticular ansa (yellow and blue, right = ansa peduncularis) and fibres ascending to the cerebellar cortex through the restiform body from the spinal cord and medulla oblongata.

The Central Nervous System. The Brain. (Cont.)

Fibre Paths.

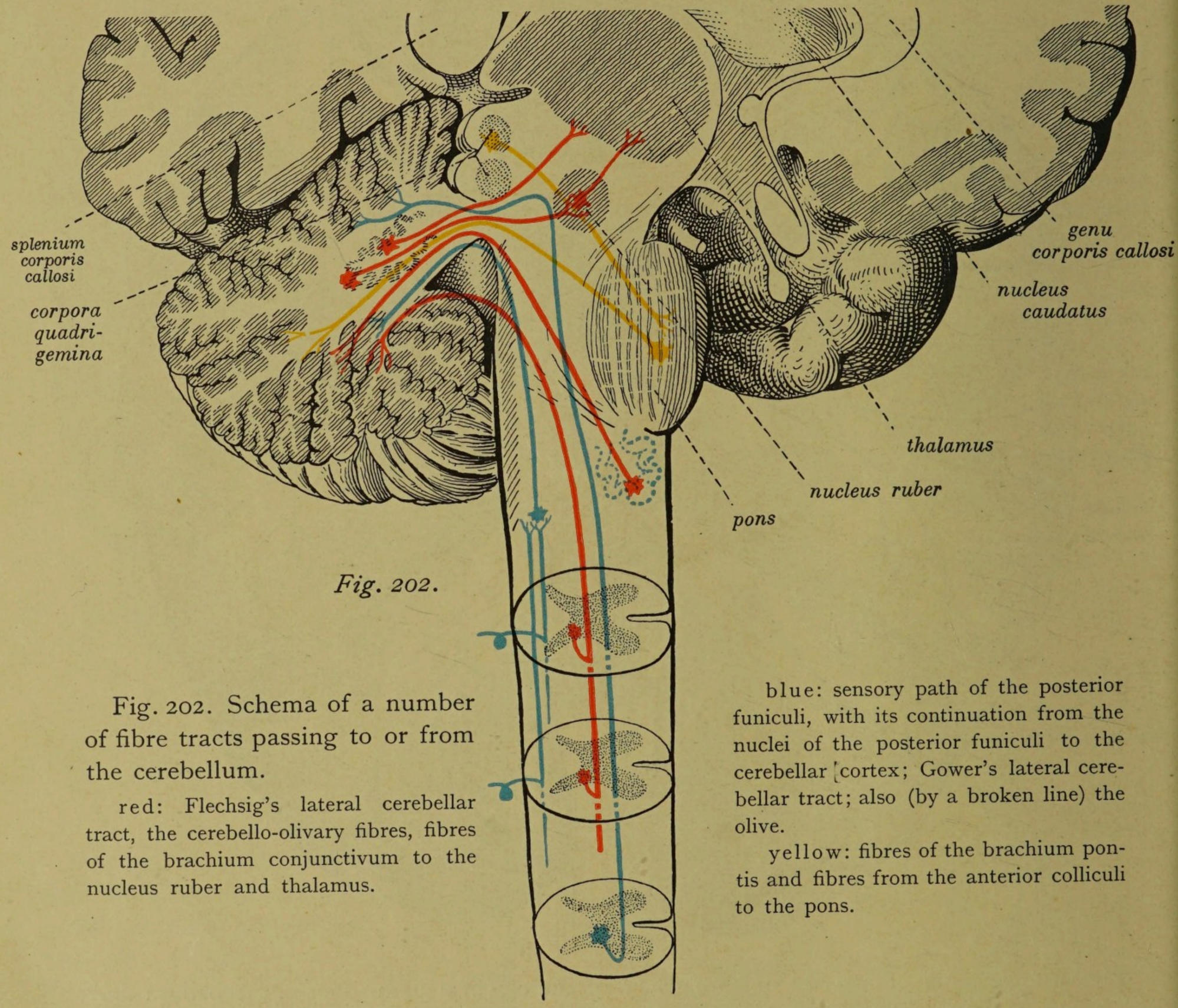

Fig. 202.

Fig. 202. Schema of a number of fibre tracts passing to or from the cerebellum.

red: Flechsig's lateral cerebellar tract, the cerebello-olivary fibres, fibres of the brachium conjunctivum to the nucleus ruber and thalamus.

blue: sensory path of the posterior funiculi, with its continuation from the nuclei of the posterior funiculi to the cerebellar cortex; Gower's lateral cerebellar tract; also (by a broken line) the olive.

yellow: fibres of the brachium pontis and fibres from the anterior colliculi to the pons.

The Central Nervous System. The Brain. (Cont.)

Fibre Paths.

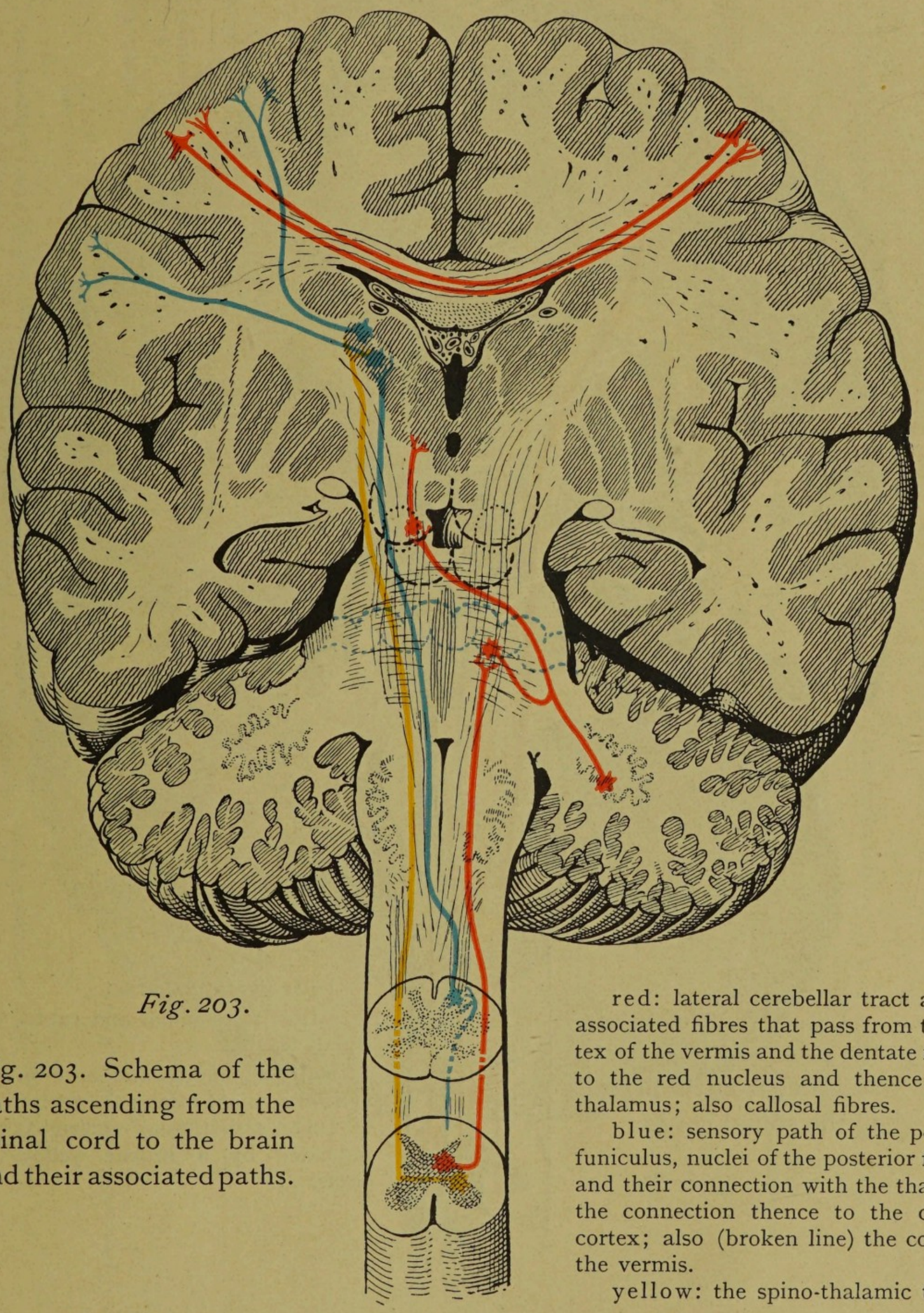

Fig. 203.

Fig. 203. Schema of the paths ascending from the spinal cord to the brain and their associated paths.

red: lateral cerebellar tract and the associated fibres that pass from the cortex of the vermis and the dentate nucleus to the red nucleus and thence to the thalamus; also callosal fibres.

blue: sensory path of the posterior funiculus, nuclei of the posterior funiculi and their connection with the thalamus; the connection thence to the cerebral cortex; also (broken line) the cortex of the vermis.

yellow: the spino-thalamic tract.

The Central Nervous System. The Brain. (Cont.)

Fibre Paths.

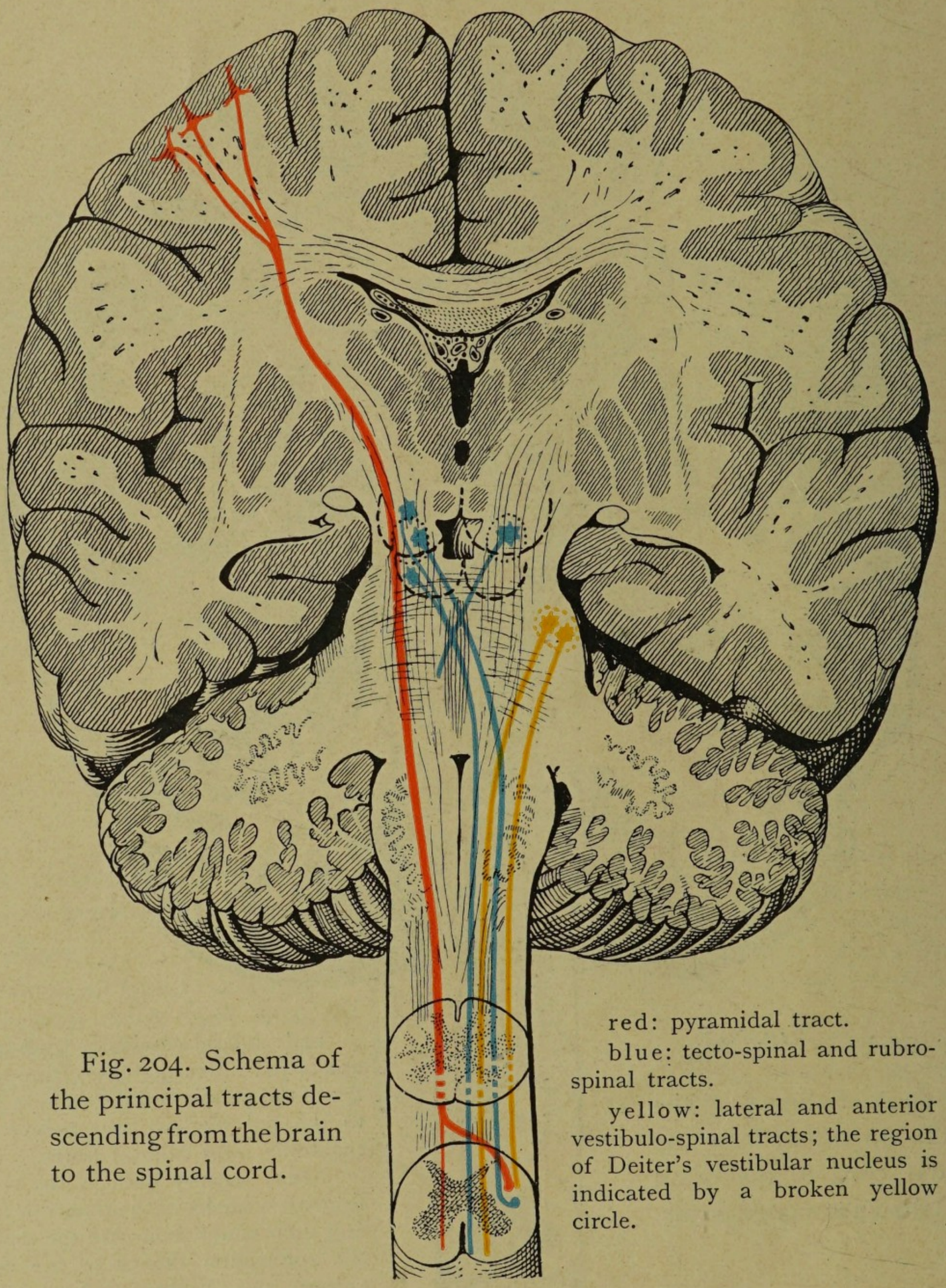

red: pyramidal tract.

blue: tecto-spinal and rubro-spinal tracts.

yellow: lateral and anterior vestibulo-spinal tracts; the region of Deiter's vestibular nucleus is indicated by a broken yellow circle.

Fig. 204. Schema of the principal tracts descending from the brain to the spinal cord.

Fig. 205. Frontal section of the brain in the region of the third ventricle. (1/1) The anterior surface of the section is shown. * = fasciculus pedunculo-mamillaris.

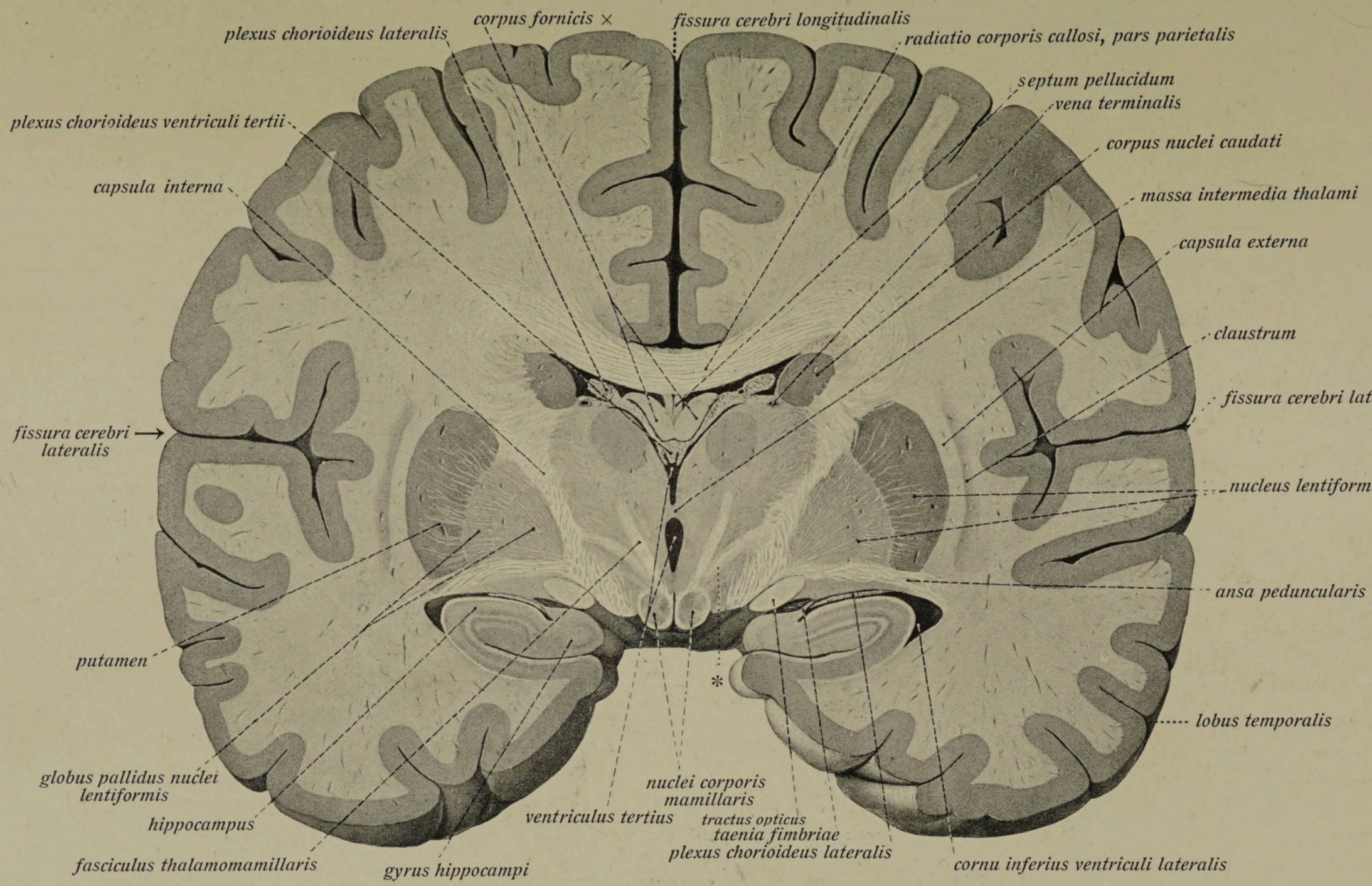
plexus chorioideus lateralis
corpus fornicis ×
fissura cerebri longitudinalis
radiatio corporis callosi, pars parietalis
septum pellucidum
vena terminalis
plexus chorioideus ventriculi tertii
corpus nuclei caudati
capsula interna
massa intermedia thalami
capsula externa
claustrum
fissura cerebri lateralis
fissura cerebri lateralis
nucleus lentiformis
ansa peduncularis
putamen
*
lobus temporalis
globus pallidus nuclei lentiformis
nuclei corporis mamillaris
hippocampus
ventriculus tertius
tractus opticus
taenia fimbriae
plexus chorioideus lateralis
fasciculus thalamomamillaris
gyrus hippocampi
cornu inferius ventriculi lateralis

Fig. 205.

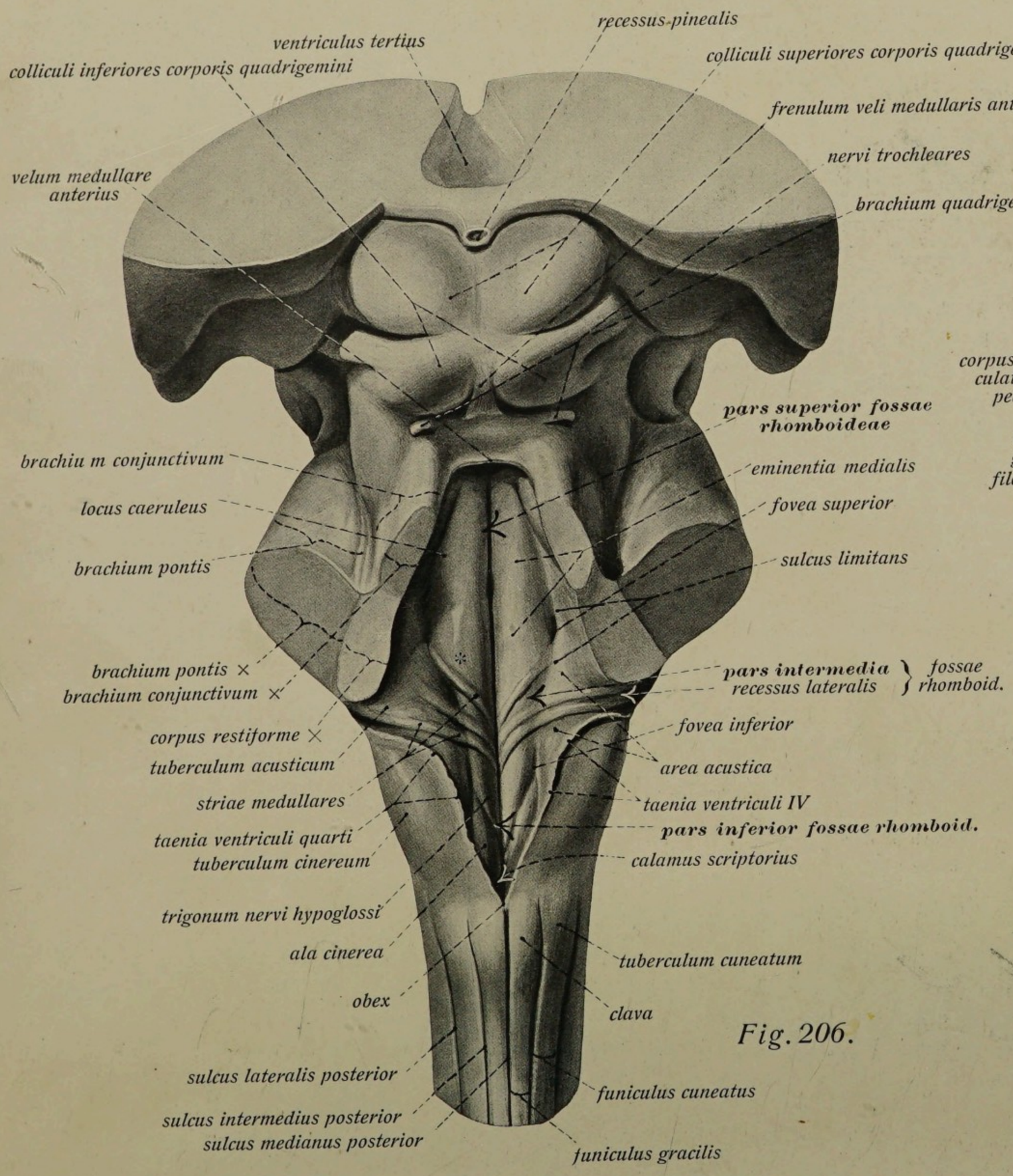

Fig. 206.

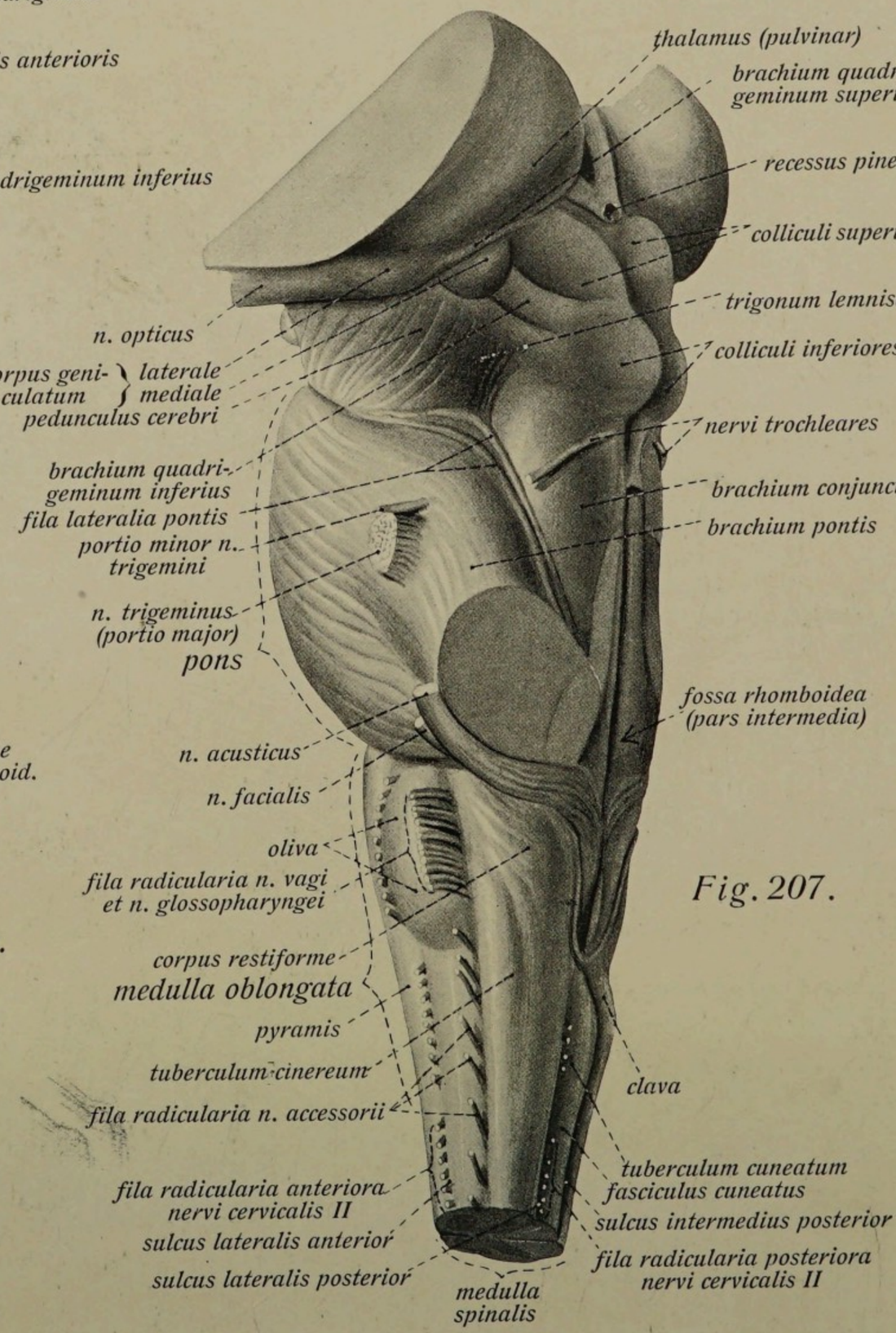

Fig. 207.

Fig. 208 and

In
hy
se

Fig. 206. The
enl
The
* =

Fig. 207. The

The Central Nervous System. The Brain. (Cont.)

The Rhombencephalon.

Fig. 206. The quadrigeminal lamina and rhomboid fossa, from behind. Somewhat enlarged.

The cerebellum and pineal body are removed; the posterior end of the thalamus is shown. * = position of the facial colliculus.

Fig. 207. The same preparation from the side and from behind. Somewhat enlarged.

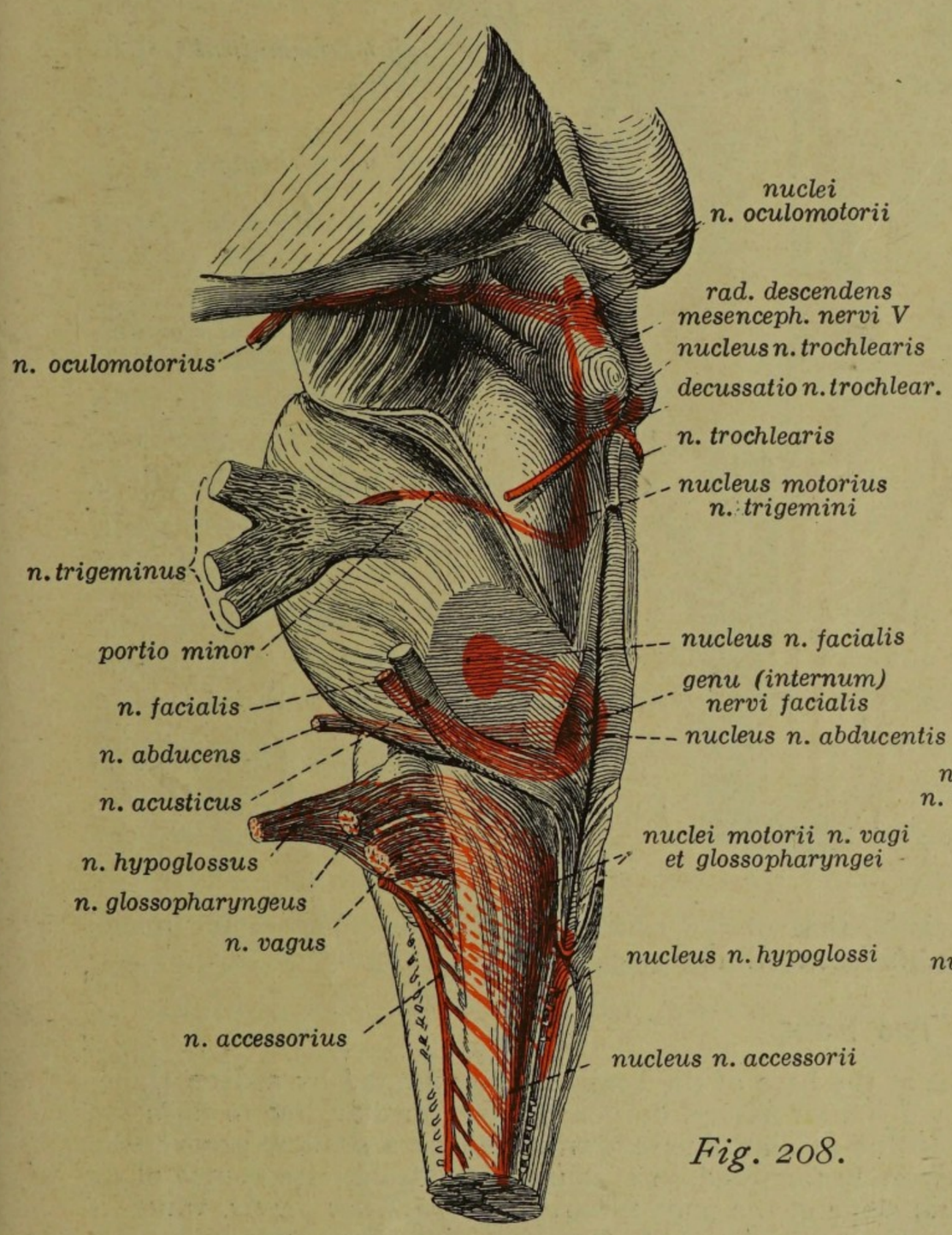

Fig. 208.

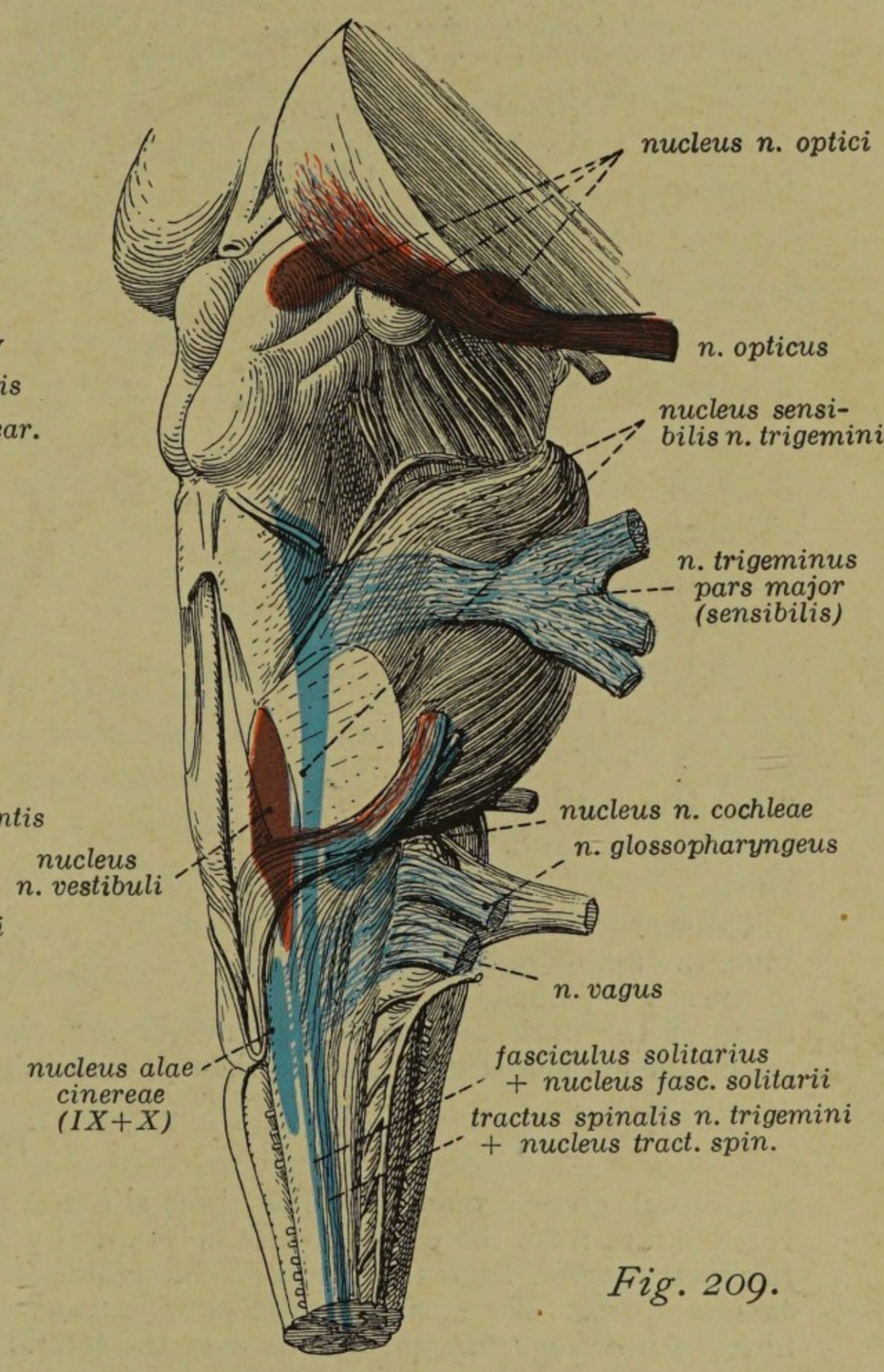

Fig. 209.

Fig. 208 and 209. The nuclei of the 2nd—12th cranial nerves from the side.

In Fig. 208 the motor nuclei and roots are shown (red, red broken lines represent roots of the hypoglossal); in Fig. 209 the general sensory nerves are indicated by blue, those of the special senses by violet (the cochlear nerve however, by blue).

The Central Nervous System. The Brain. (Cont.)

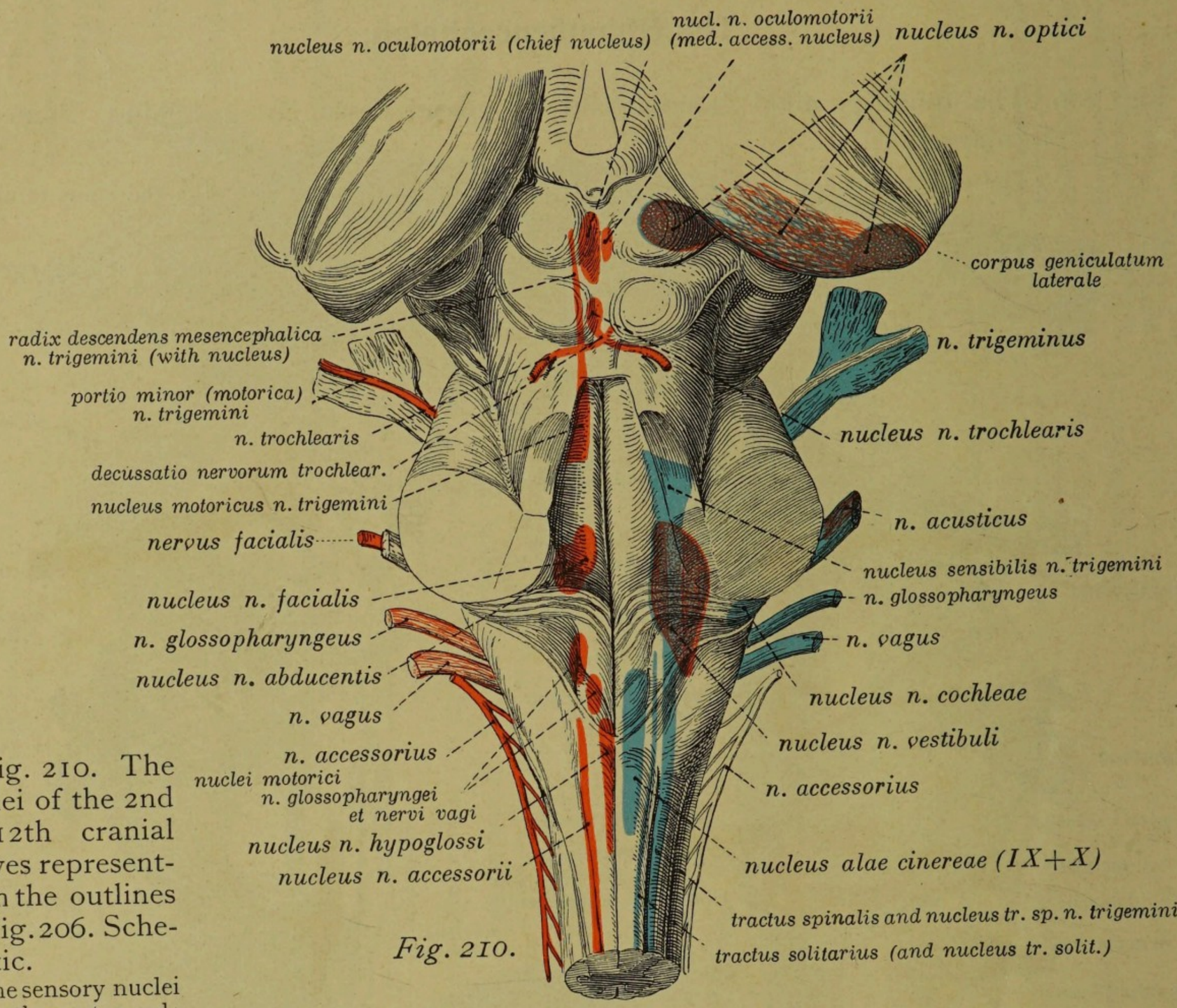

Fig. 210.

Fig. 210. The nuclei of the 2nd to 12th cranial nerves represented in the outlines of Fig. 206. Schematic.

The sensory nuclei blue, the motor red; of the sensory nuclei those of the optic and vestibular nerves are violet, that of the cochlear nerve blue. The motor nuclei are on the left side, the sensory on the right. The different vestibular nuclei are not distinguished.

The Pons

is a broad, convex mass of white fibres situated at the base of the brain. It is separated by a deep transverse fissure from the cerebral peduncles and by a similar fissure, deepened in the median line to form the *foramen caecum*, from the medulla oblongata. In the median line it is traversed by a shallow groove, the *basilar sulcus*. The surface of the pons is transversely furrowed on account of the transverse course of its fibres. An *oblique fasciculus* runs over the lateral slope of the pons towards the *brachium pontis*, which is a broad mass of fibres which passes to the cerebellum and into which the fibres of the pons gradually pass. Fig. 148, 149, 174, 178, 183, 184, 206, 207.

The Medulla Oblongata

is the direct continuation of the spinal cord and resembles it externally, except that it enlarges above where it takes part in the formation of the inferior part of the rhomboid fossa. Above it is separated from the pons by the transverse fissure mentioned above, while in the rhomboid fossa it shows no line of demarcation. In addition, the medulla oblongata is connected with the cerebellum by the restiform bodies. The *anterior median fissure* of the spinal cord is continued upon the medulla oblongata to the foramen caecum, interrupted only at the level of the first cervical nerve by the decussation of the pyramids. By the sides of it lie the *pyramids*, flattened bands formed by the decussation of the lateral pyramidal tracts.

The Central Nervous System. The Brain. (Cont.)

The Rhombencephalon.

The Fourth Ventricle, The Rhomboid Fossa.

The fourth ventricle is a flat cavity between the pons and the upper part of the medulla oblongata on the one hand, and the cerebellum on the other. It connects above with the aquaeduct of the midbrain and below with the central canal of the lower part of the medulla (at the calamus scriptorius). Its roof is formed anteriorly by the anterior medullary velum and in part by the brachia conjunctiva, but in its lower portion it is covered in partly by the pia mater, lined with ependymal epithelium and forming the *tela chorioidea* of the fourth ventricle, and partly by the *posterior medullary velum*. The former is attached to the margins of the rhomboid fossa by the *taeniae of the fourth ventricle*; the latter passes into the peduncle of the flocculus of the cerebellum (see p. 237) and meets the anterior medullary velum to form the *fastigium*. At the calamus scriptorius the taeniae form a projection, the *obex*. On the ventricular surface of the tela chorioidea there are vascular projections from the pia mater, forming the *chorioid plexus* of the fourth ventricle, which extends into a lateral outpouching of the ventricle at its broadest portion, the *lateral recess*, and becomes visible at the base of the brain behind the flocculus of the cerebellum and beside the root of the glossopharyngeal nerve. At this region the ventricle appears to have a paired *lateral aperture* (inconstant?) and in the median line in front of the obex there is an unpaired *medial aperture* which is gradually formed during extrauterine life. Fig. 149, 178, 180, 214, 234.

The *rhomboid fossa* is the floor, or more properly speaking the anterior wall of the fourth ventricle. It is a rhombic depression, pointed above and below, lying on the posterior surface of the pons and medulla oblongata. Its upper point lies in the region of the isthmus, its lower in the region of the myelencephalon, its principal part lying on the dorsal surface of the pons. A *superior*, an *inferior* and an *intermediate* portion may be distinguished, the last being its broadest portion. The lower pointed part of the inferior portion is termed the *calamus scriptorius*. Throughout the entire length of the fossa there is a *posterior median fissure* bounded by two elevations, the *medial eminences*. The intermediate part extends by means of the *lateral recess* to the ventral surface of the rhombencephalon. It possesses a flat elevation, the *acoustic area*, which extends partly into the inferior portion and into the lateral recess (here forming the often indistinct *acoustic tubercle*) and over which variably developed and often plexiform white fibres, the *medullary striae*, run. Towards the superior portion there is in the region of the medial eminence a rounded elevation, the *facial colliculus*, corresponding to the genu of the facial nerve. In the upper portion, lateral to the medial eminence, there is an elongated area which has a dark color in the fresh brain and is called the *locus caeruleus*. The inferior portion has a triangular grey area beside the medial eminence, the *hypoglossal trigone*, and just below the medullary striae there is another triangular grey area, the *ala cinerea* (vagus-glossopharyngeus nucleus). Fig. 180, 206, 207, 215, 220—222.

The Central Nervous System. The Brain. (Cont.)

Fig. 212. Transverse section of the midbrain in the region of the anterior colliculi. (4/1)

Fig. 213. Transverse section of the midbrain in the region of the posterior colliculi. (4/1)
The somewhat oblique section has also cut a part of the superficial layer of the pons. From preparations stained with Weigert's medullary stain. The white substance (nerve fibres) dark, grey substance light.

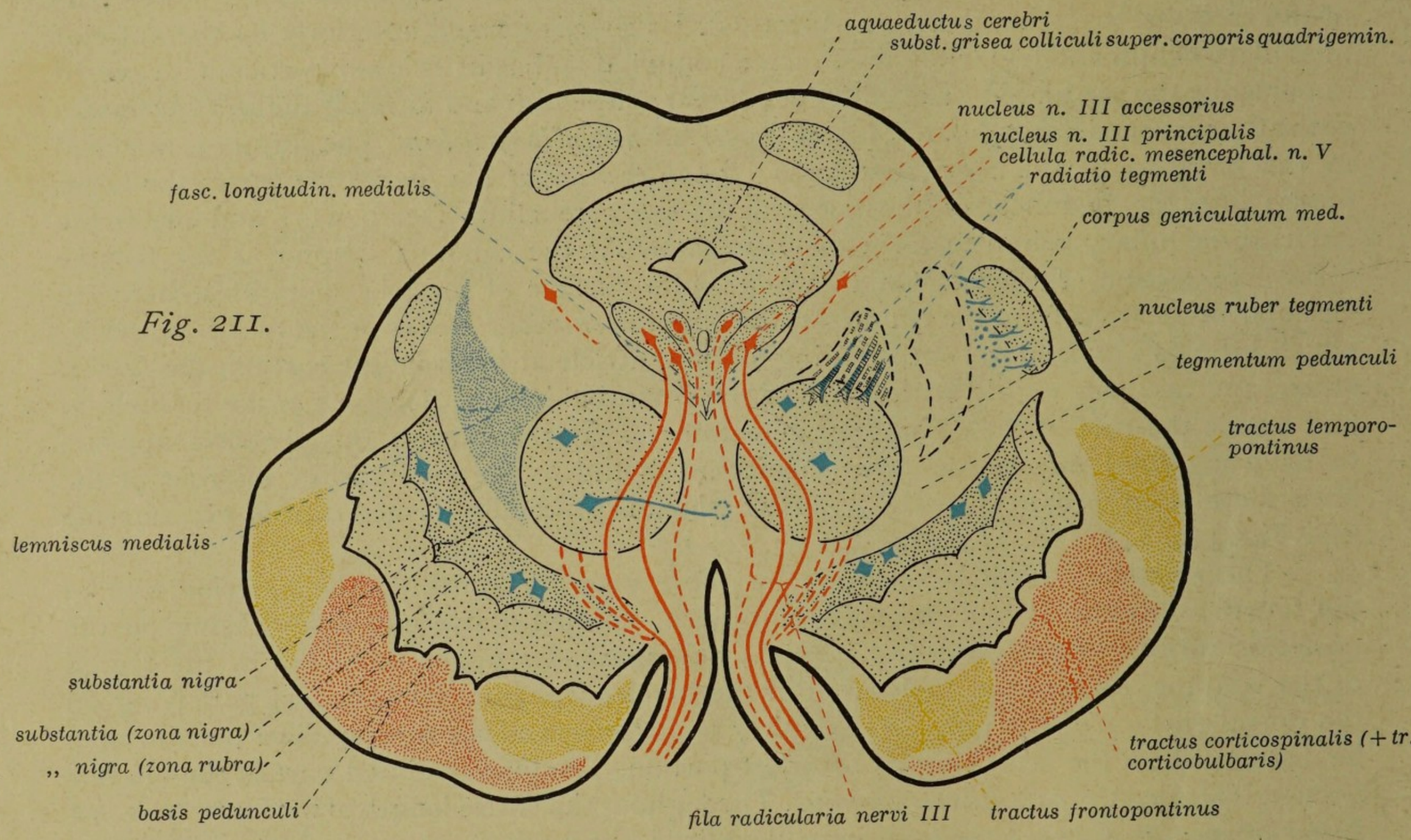

Fig. 211.

Fig. 211. Diagram of the structure of the midbrain (after Müller-Spatz).

Medulla Oblongata. (Continued from p. 224.)

Next these are the *lateral funiculi*, separated from the pyramids by the continuation upwards of the *anterior lateral sulcus* of the cord; in the upper part of the medulla oblongata these funiculi enlarge to an elongated anterior elevation, the *olive*, and to a posterior flat one, the *tuberculum cinereum* (the prolongation of the posterior column of the cord). On the posterior surface, the *posterior median sulcus* extends to the obex and the *lateral* and *intermediate posterior sulci* are also continued upon the medulla, marking out the *fasciculi gracilis* and *cuneatus*. The gracilis ends below the calamus scriptorius in an enlargement, the *clava*, and the cuneate somewhat higher in a less evident *cuneate tubercle*. Both funiculi pass into the *restiform body*, the continuation of the lateral funiculus passing to the cerebellum. Fig. 148, 149, 174, 178, 206, 207.

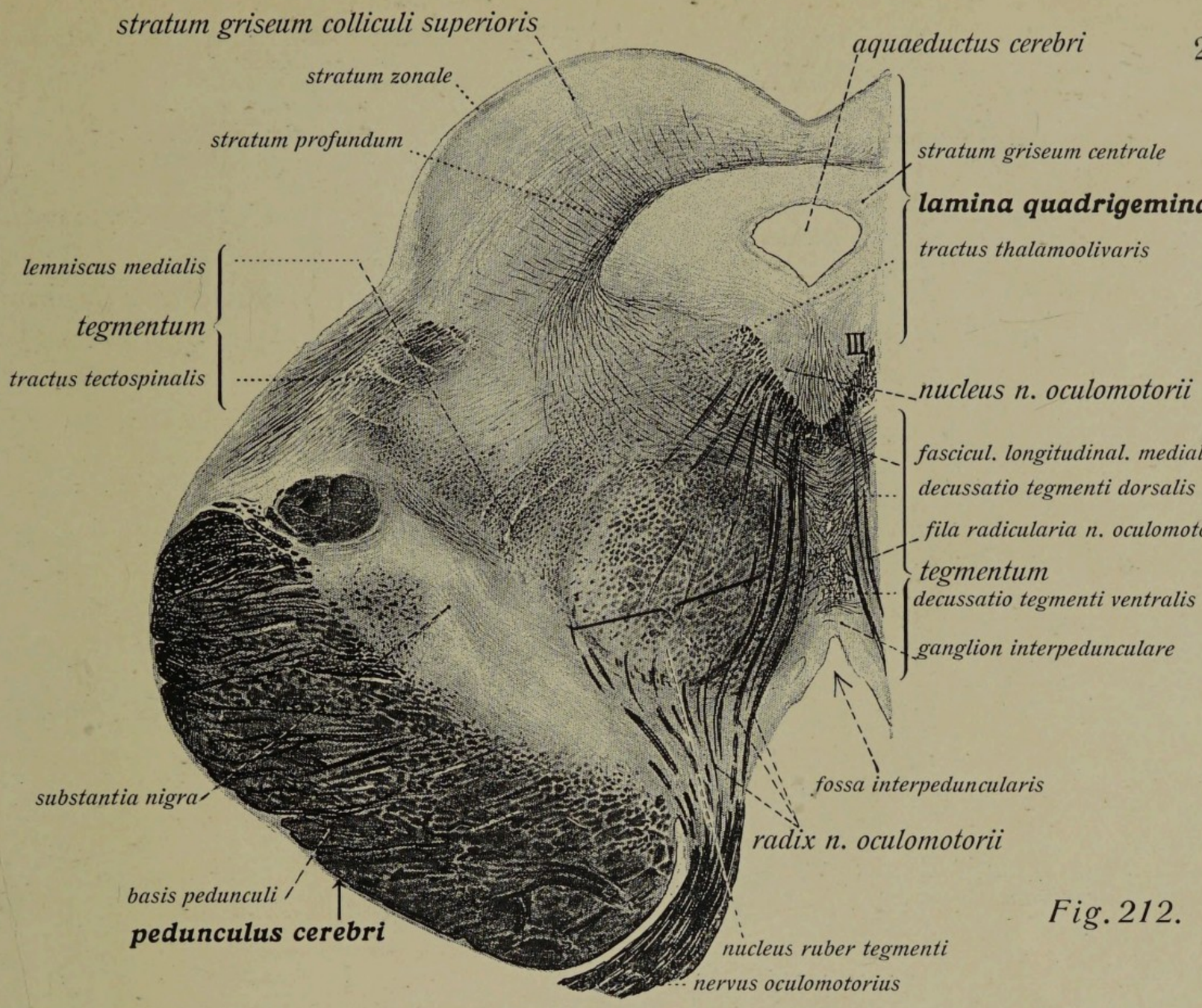

Fig. 212.

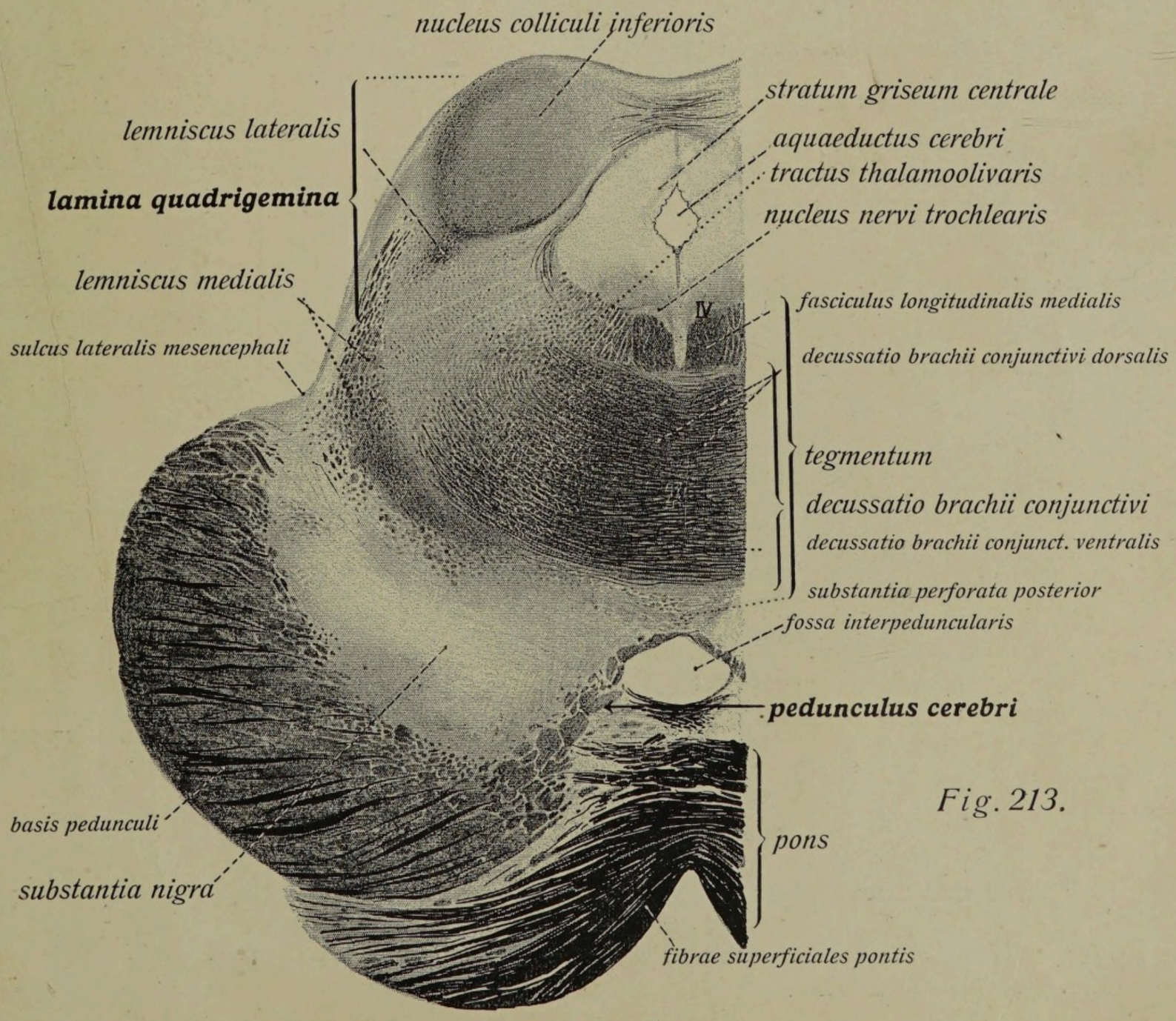

Fig. 213.

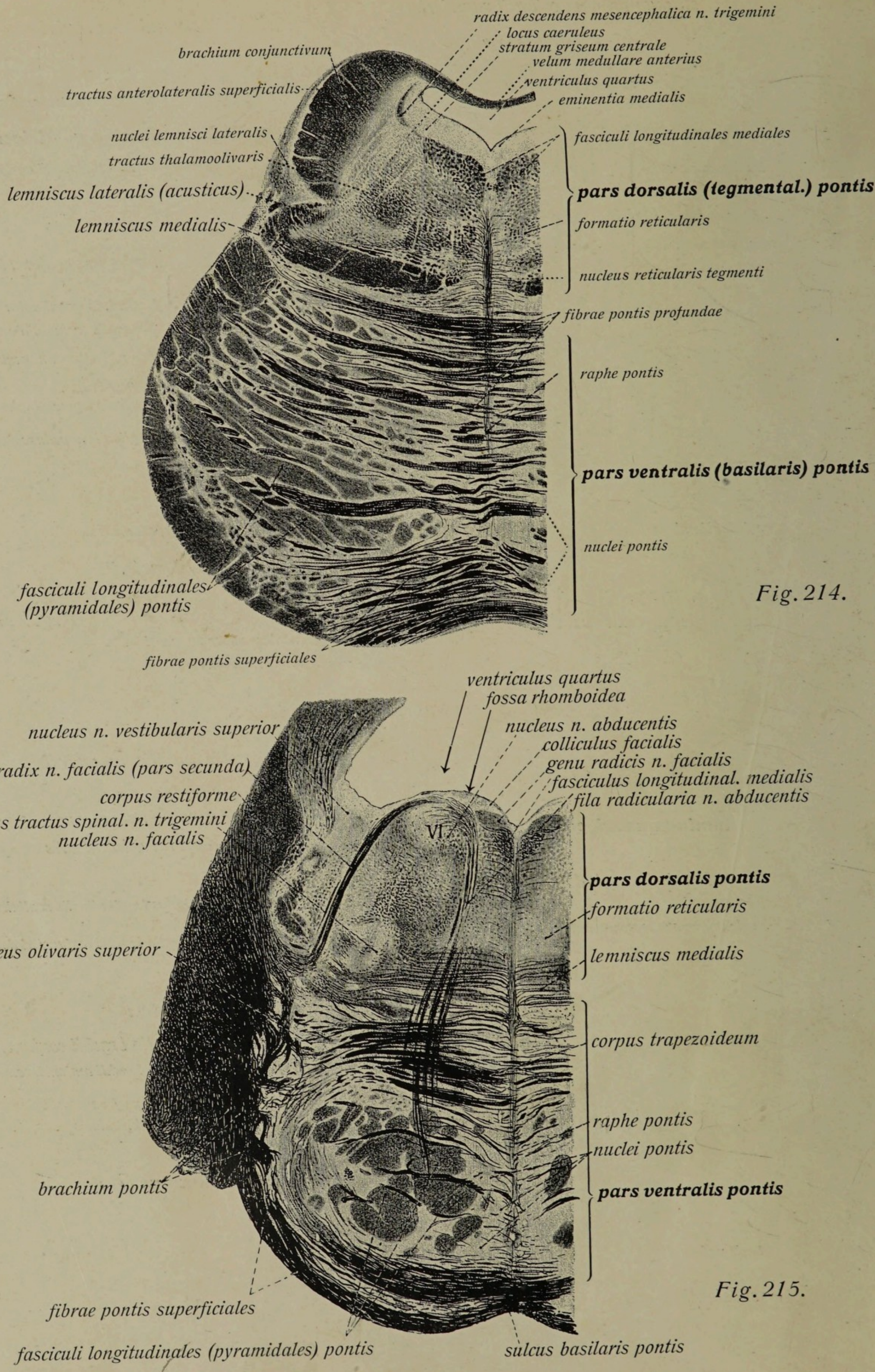
radix descendens mesencephalica n. trigemini
locus caeruleus
stratum griseum centrale
velum medullare anterius
ventriculus quartus
eminentia medialis
brachium conjunctivum
tractus anterolateralis superficialis
nuclei lemnisci lateralis
tractus thalamoolivaris
lemniscus lateralis (acusticus)
lemniscus medialis
fasciculi longitudinales mediales
pars dorsalis (tegmental.) pontis
formatio reticularis
nucleus reticularis tegmenti
fibrae pontis profundae
raphe pontis
pars ventralis (basilaris) pontis
nuclei pontis
fasciculi longitudinales (pyramidales) pontis
fibrae pontis superficiales
Fig. 214.
ventriculus quartus
fossa rhomboidea
nucleus n. vestibularis superior
radix n. facialis (pars secunda)
corpus restiforme
nucleus tractus spinal. n. trigemini
nucleus n. facialis
nucleus n. abducentis
colliculus facialis
genu radicis n. facialis
fasciculus longitudinal. medialis
fila radicularia n. abducentis
VI
pars dorsalis pontis
formatio reticularis
lemniscus medialis
nucleus olivaris superior
corpus trapezoideum
raphe pontis
nuclei pontis
pars ventralis pontis
brachium pontis
fibrae pontis superficiales
fasciculi longitudinales (pyramidales) pontis
sulcus basilaris pontis
Fig. 215.

The Rhombencephalon.

Fig. 214. Transverse section through the middle of the pons and the isthmus. (5/1) White substance dark, grey substance clear.

Fig. 215. Transverse section through the lower portion of the pons, at the level of the abducens nucleus. (5/1) Of the facial nerve only the second part is cut lengthwise and the genu obliquely; the first part is not visible. Laterally is the brachium of the pons, separated from the cerebellum.

Fig. 216.

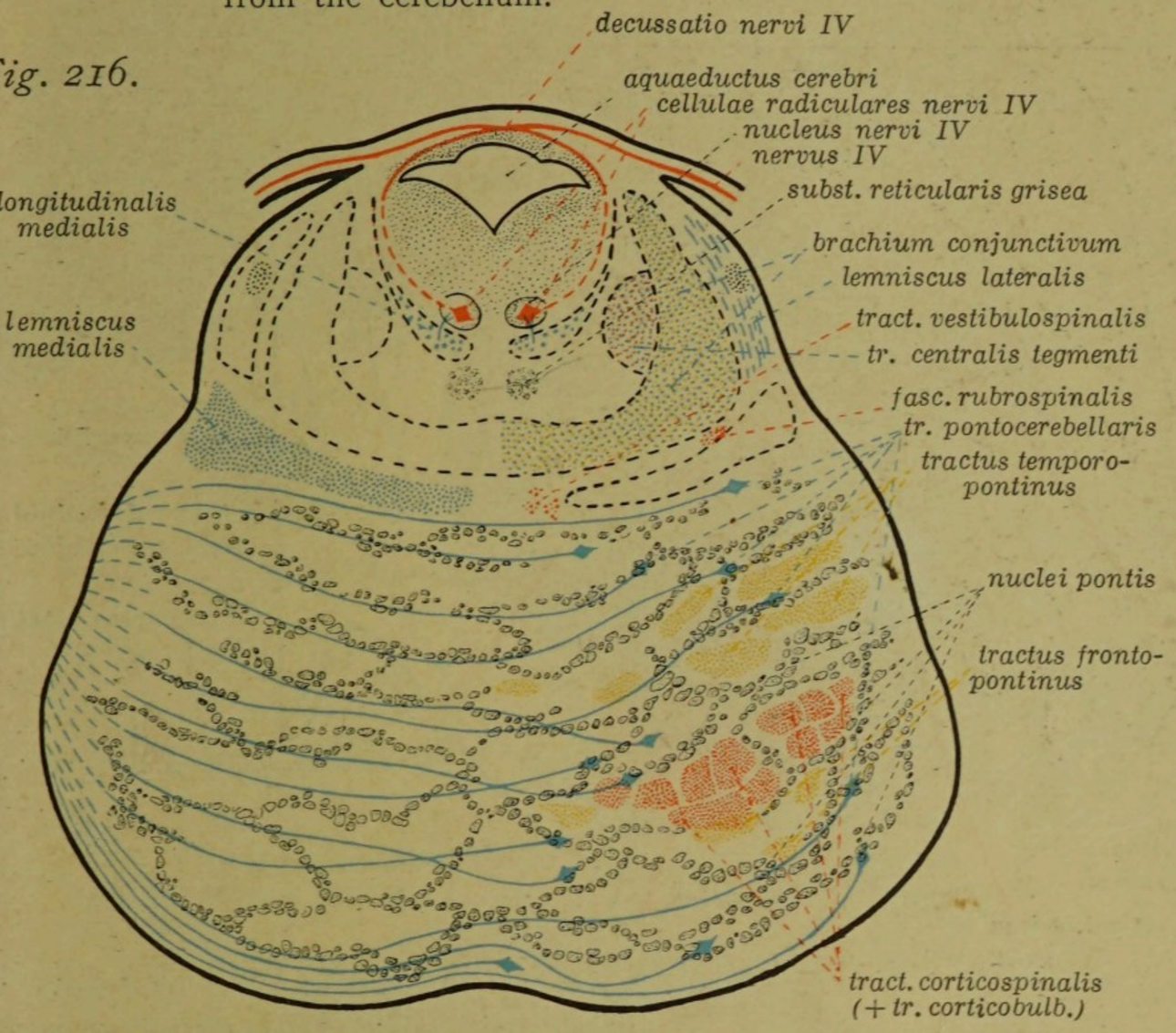

Fig. 216. Diagram of the structure of the upper portion of the pons (after Müller-Spatz).

In general the descending paths are yellow or red, the ascending paths blue.

Fig. 217.

Fig. 217. Diagram of the structure of the pons at the level of the trigeminal nuclei (after Müller-Spatz).

The colours are as in Fig. 216.

Fig. 220. Transverse section through the upper part of the medulla oblongata. (7/1) The roman numerals indicate the nuclei of cranial nerves (a after VIII denotes the vestibular and b the cochleat nuucleus. = position of the ala crinerea.

Fig. 221. Transverse section through the middle part of the medulla oblongata, the middle of the region of the olive. (7/1) White substance dark, grey substance light. * = position of the ala cinerea.

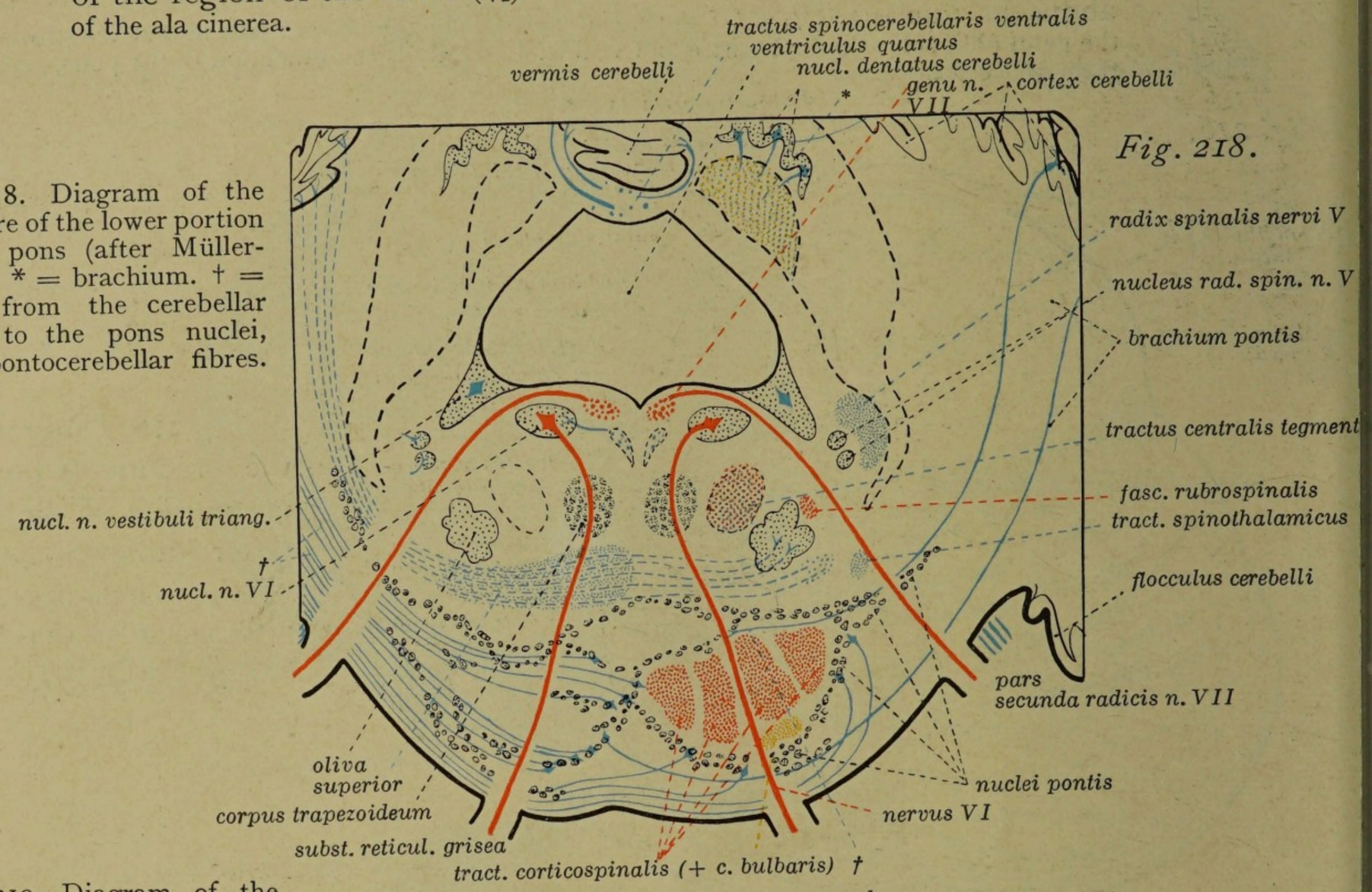

Fig. 218.

Fig. 218. Diagram of the structure of the lower portion of the pons (after Müller-Spatz). * = brachium. † = fibres from the cerebellar cortex to the pons nuclei, †† = pontocerebellar fibres.

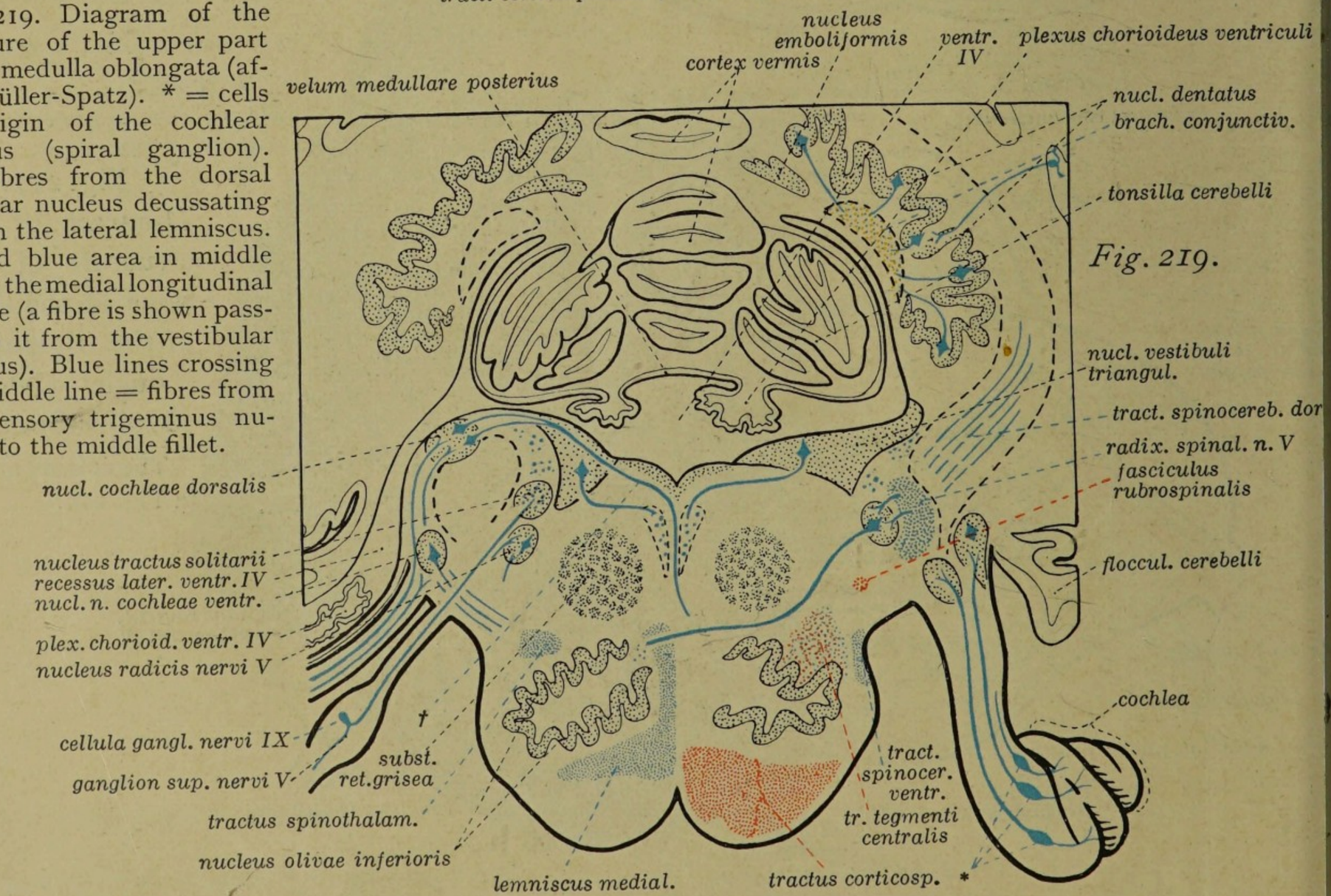

Fig. 219.

Fig. 219. Diagram of the structure of the upper part of the medulla oblongata (after Müller-Spatz). * = cells of origin of the cochlear nucleus (spiral ganglion). † = fibres from the dorsal cochlear nucleus decussating to join the lateral lemniscus. Dotted blue area in middle line = the medial longitudinal bundle (a fibre is shown passing to it from the vestibular nucleus). Blue lines crossing the middle line = fibres from the sensory trigeminus nucleus to the middle fillet.

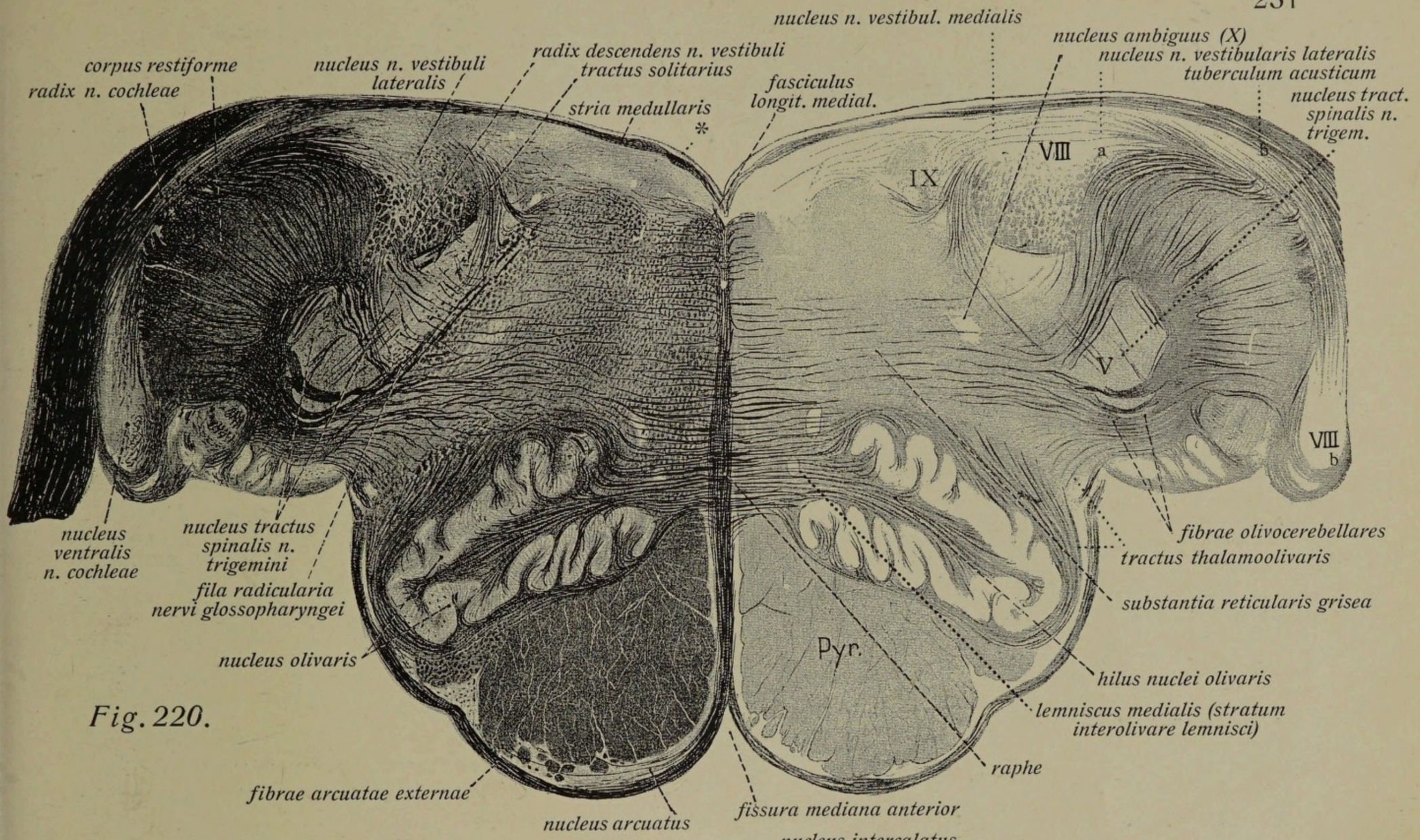

Fig. 220.

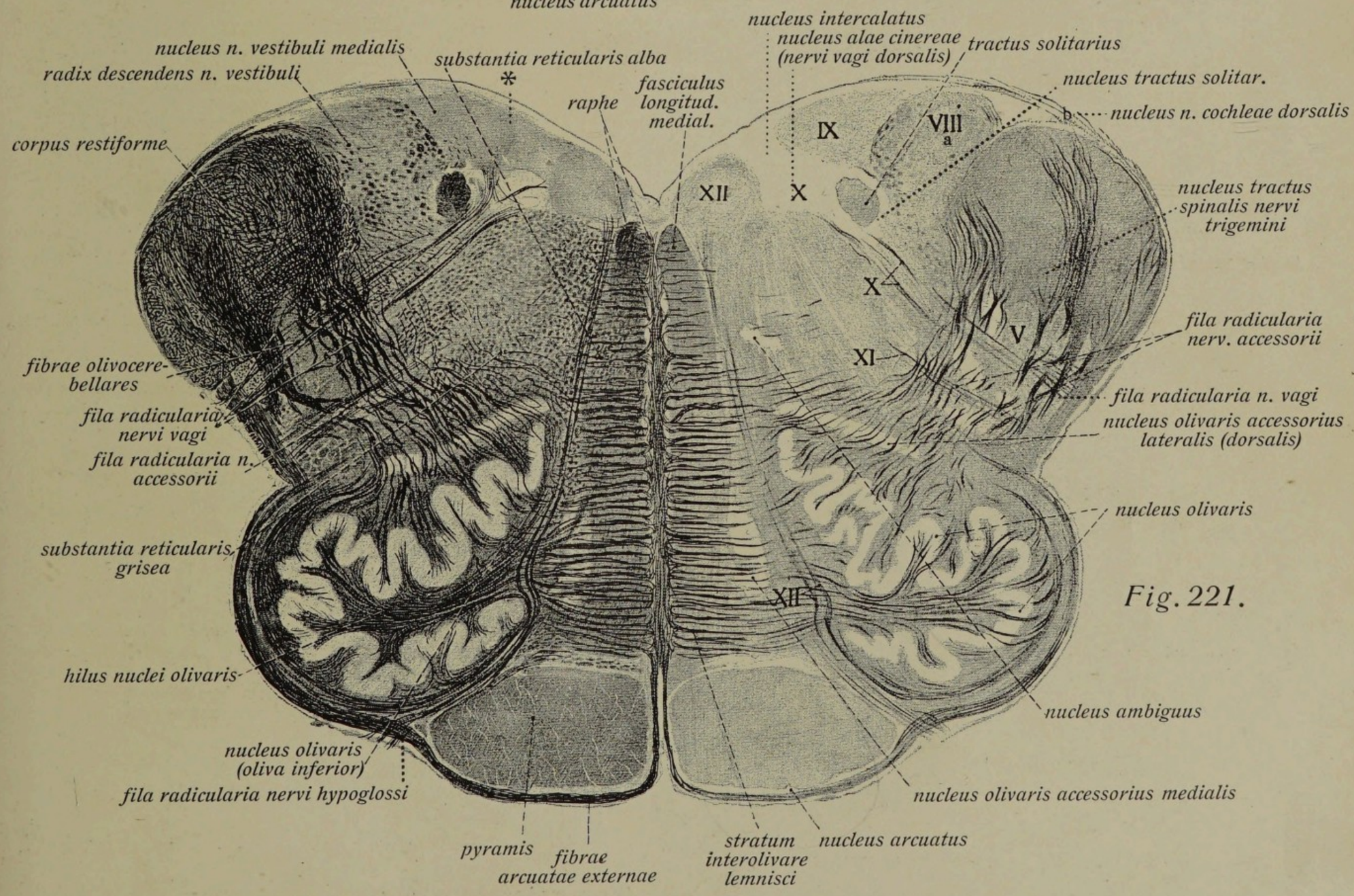

Fig. 221.

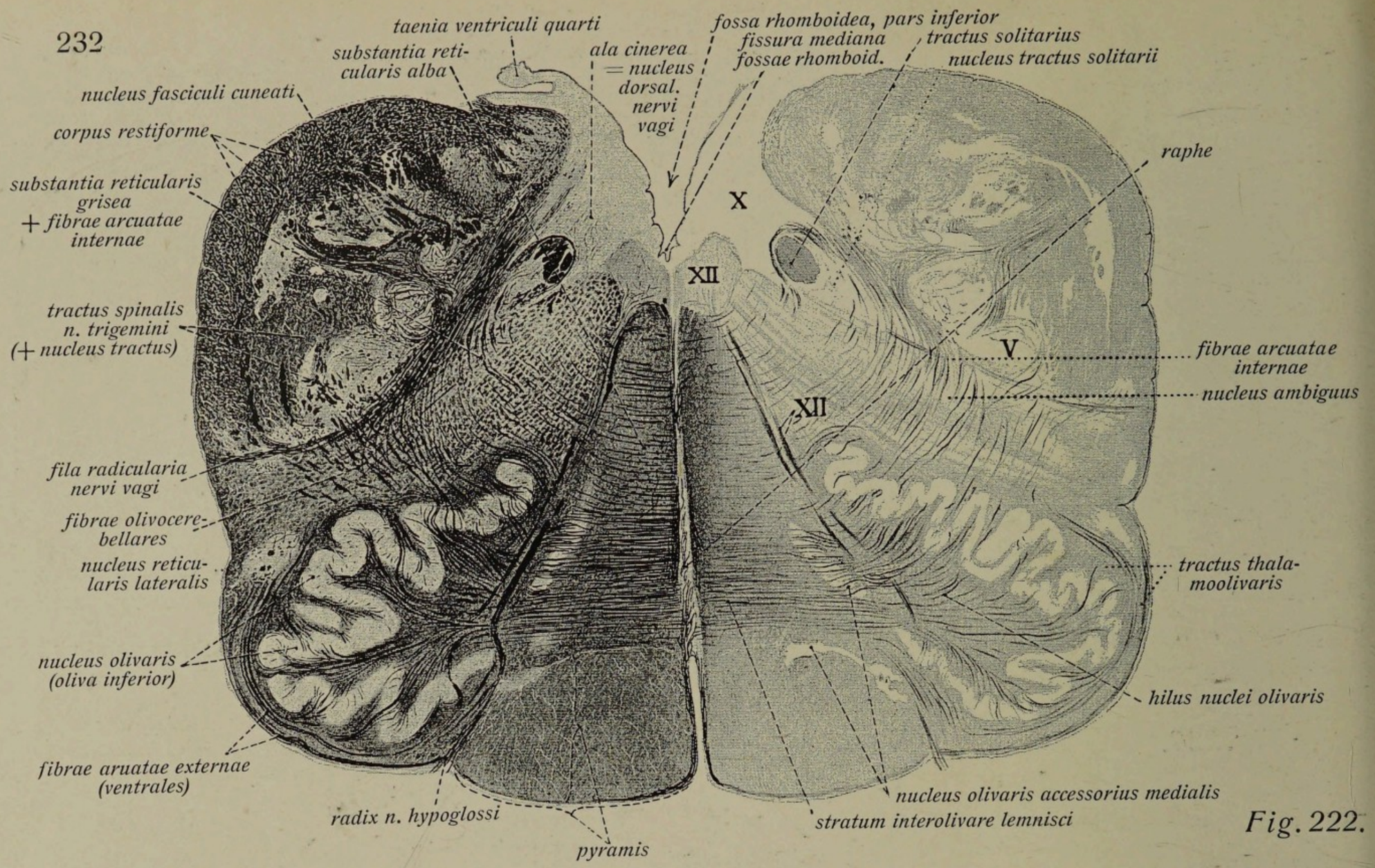

Fig. 222.

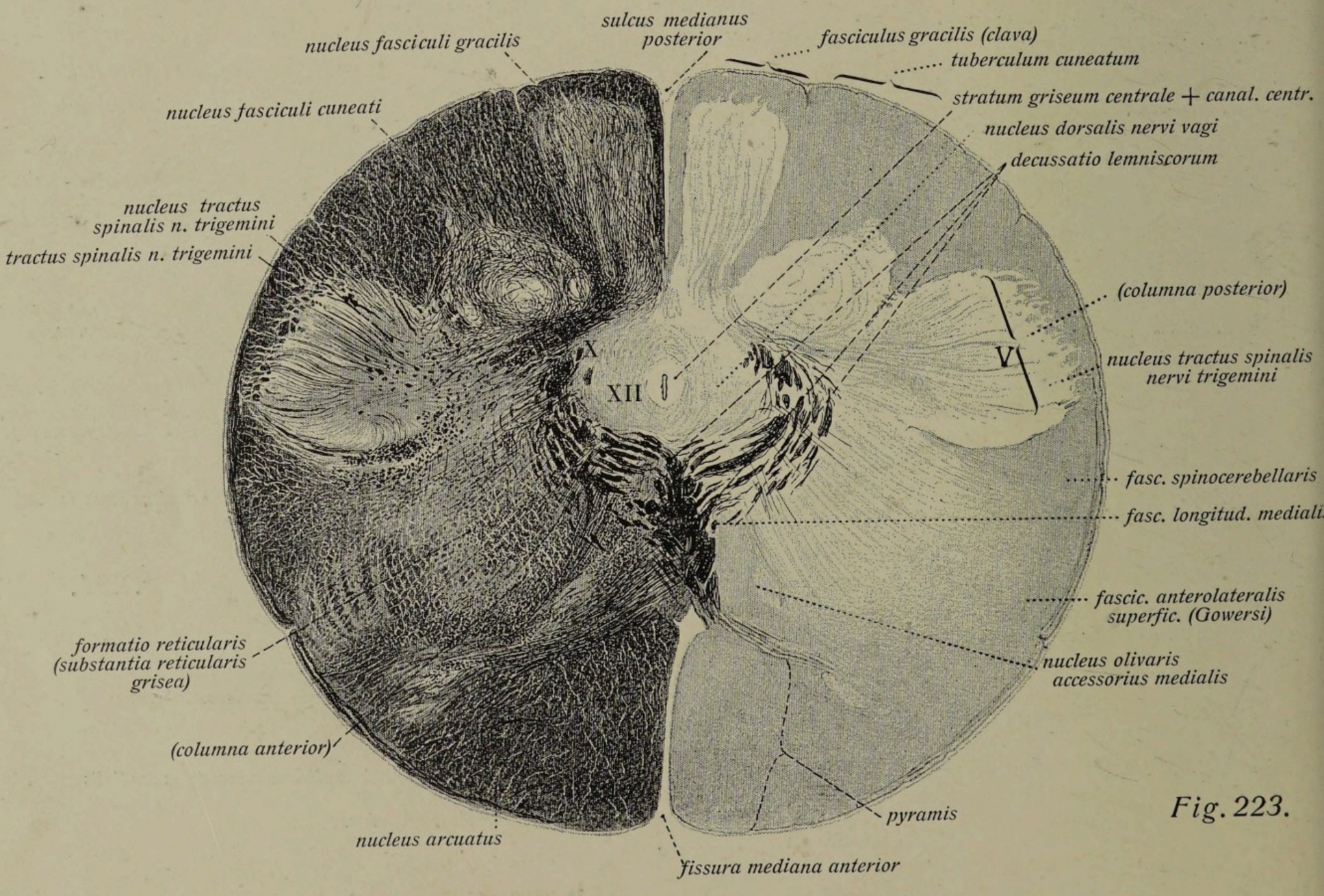

Fig. 223.

Transverse sections of the medulla oblongata.

Fig. 222. Transverse section of the middle portion of the medulla oblongata, in the region of the calamus scriptorius. ($^7/_1$) The roman numerals indicate the cranial nerve nuclei. White substance dark, grey substance light.

Fig. 223. Transverse section through the lower part of the medulla oblongata, in the region of the decussation of the pyramids. ($^7/_1$)

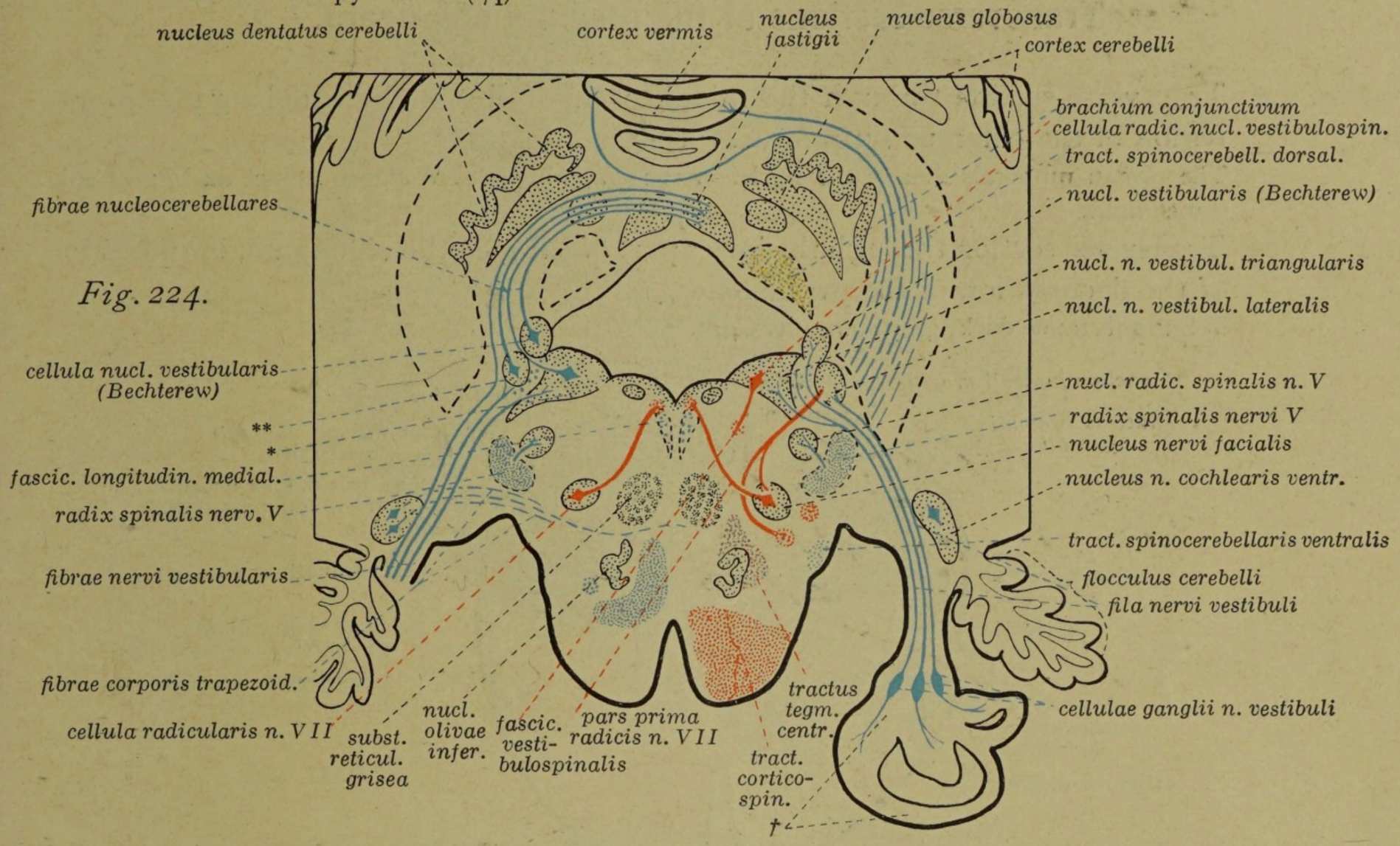

Fig. 224.

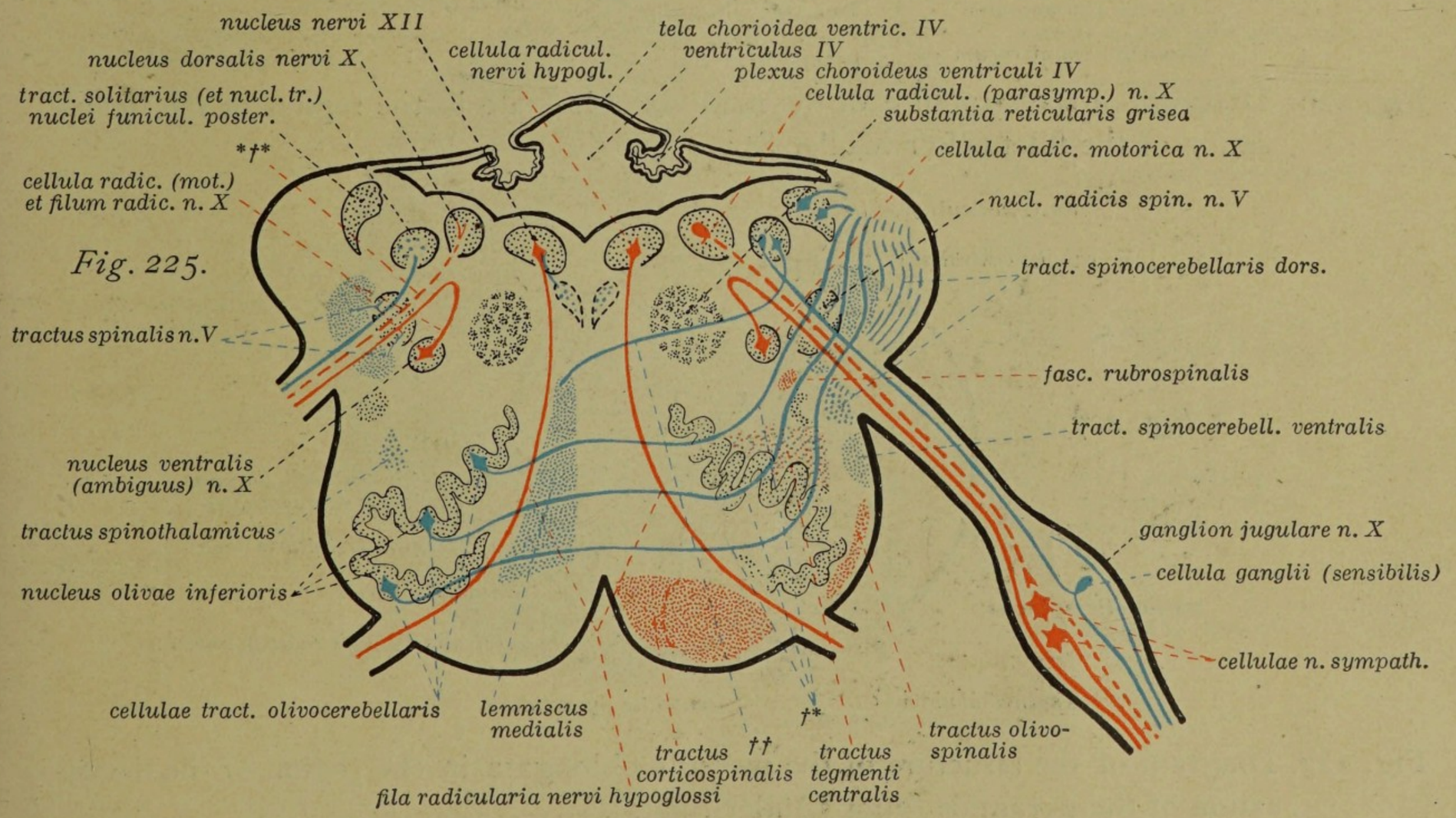

Fig. 225.

Fig. 224 and 225. Diagrams of the structure of the medulla oblongata at the level of the vestibular nuclei (224) and at that of the IX—XII cranial nerves (after Müller-Spatz). † = semicircular canal. †* = olivocerebellar fibres. †† = fibres from the nucleus of the solitary tract to the middle fillet. * = fibres from the vestibular nerve to the triangular nucleus. ** = the same to the lateral nucleus. *†* = afferent fibres to the visceromotor vagus nucleus.

The Central Nervous System. The Brain. (Cont.)

The Myelencephalon.

Transverse sections of the medulla oblongata.

Fig. 228. Transverse section through the middle part of the Medulla oblongata, in the region of the calamus scriptorius. (7/1)
The roman numerals denote the nuclei of the cranial nerves. White substance dark, grey substance light.

Fig. 229. Transverse section through the lower part of the medulla oblongata, in the region of the decussation of the pyramids. (7/1)
White substance dark, grey substance light.

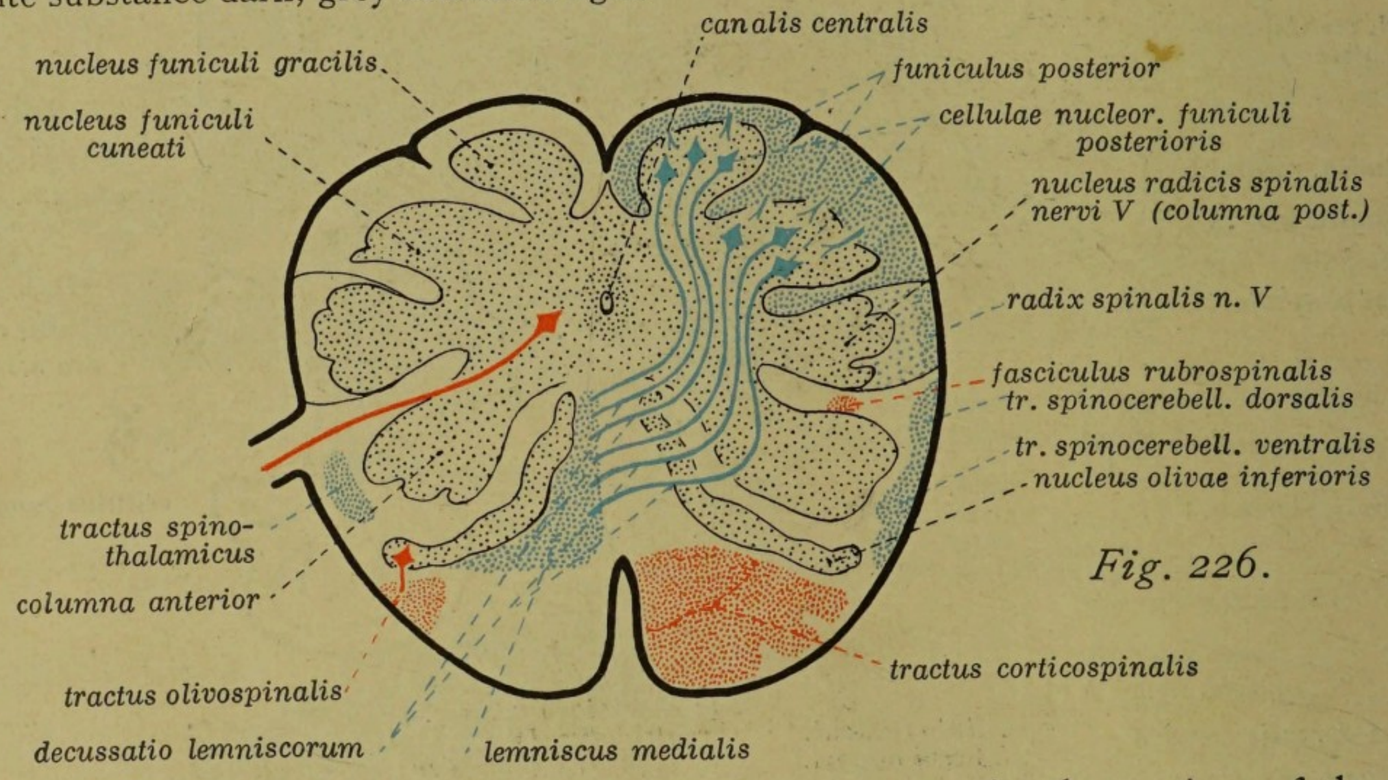

Fig. 226.

Fig. 226. Diagram of the structure of the medulla oblongata in the region of the decussation of the fillet (after Müller-Spatz).

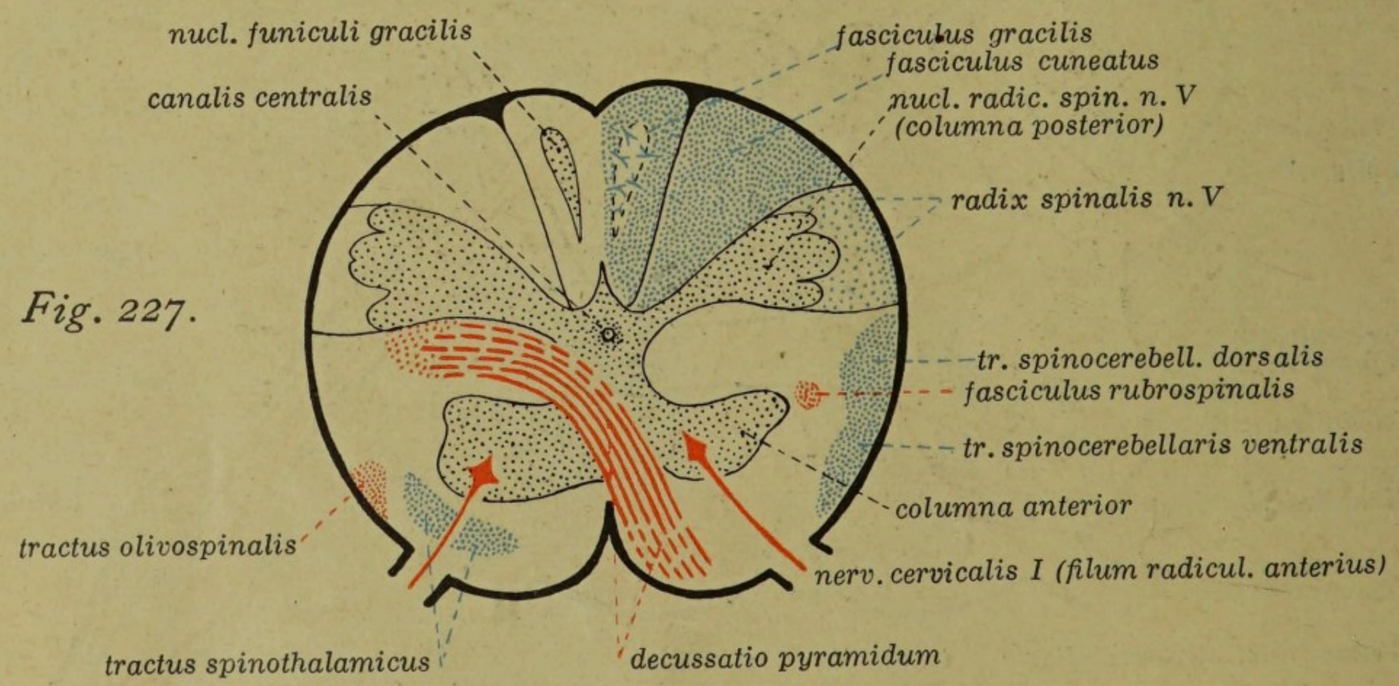

Fig. 227.

Fig. 227. Diagram of the structure of the medulla oblongata in the region of the decussation of the pyramids (after Müller-Spatz).

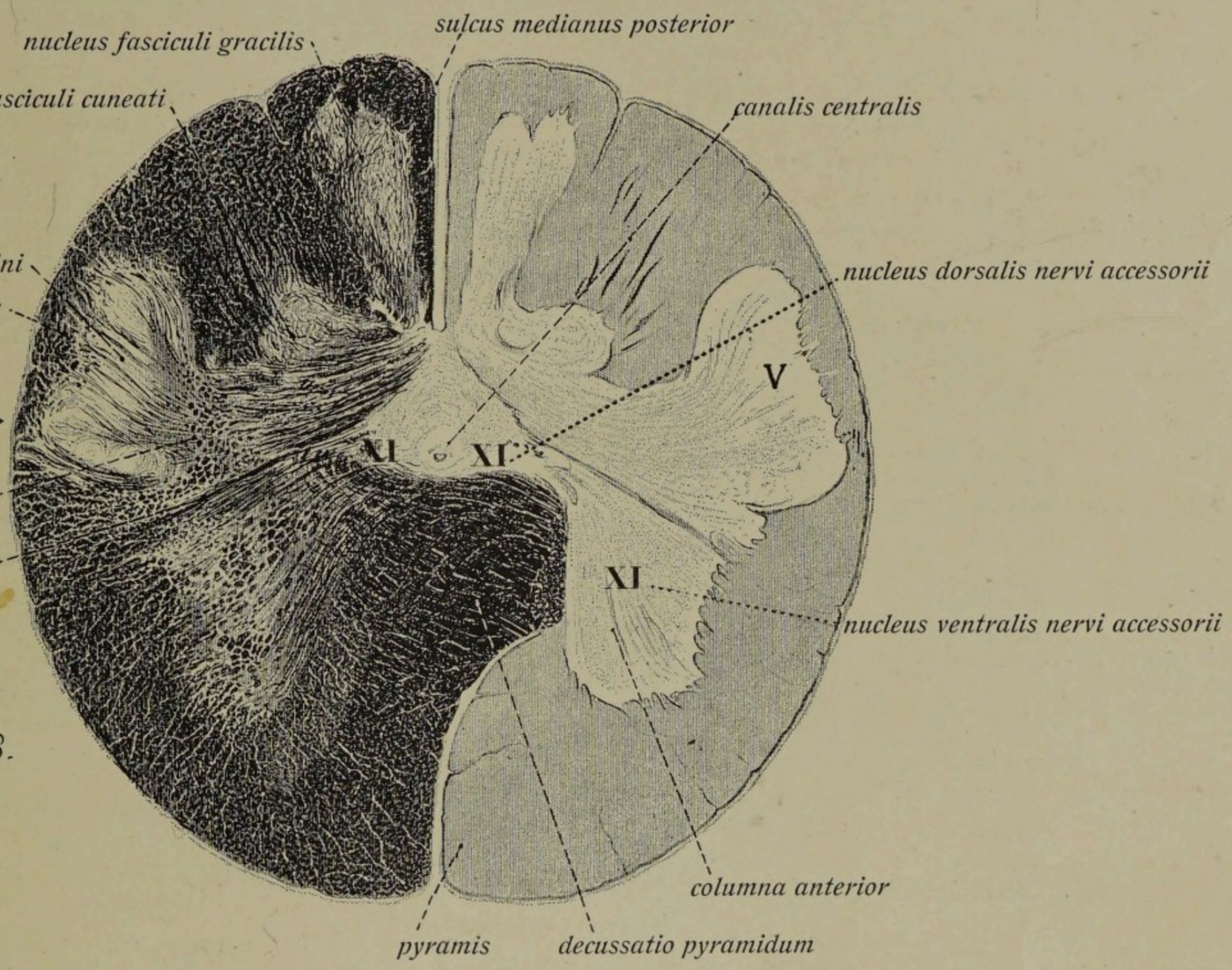

Fig. 228.

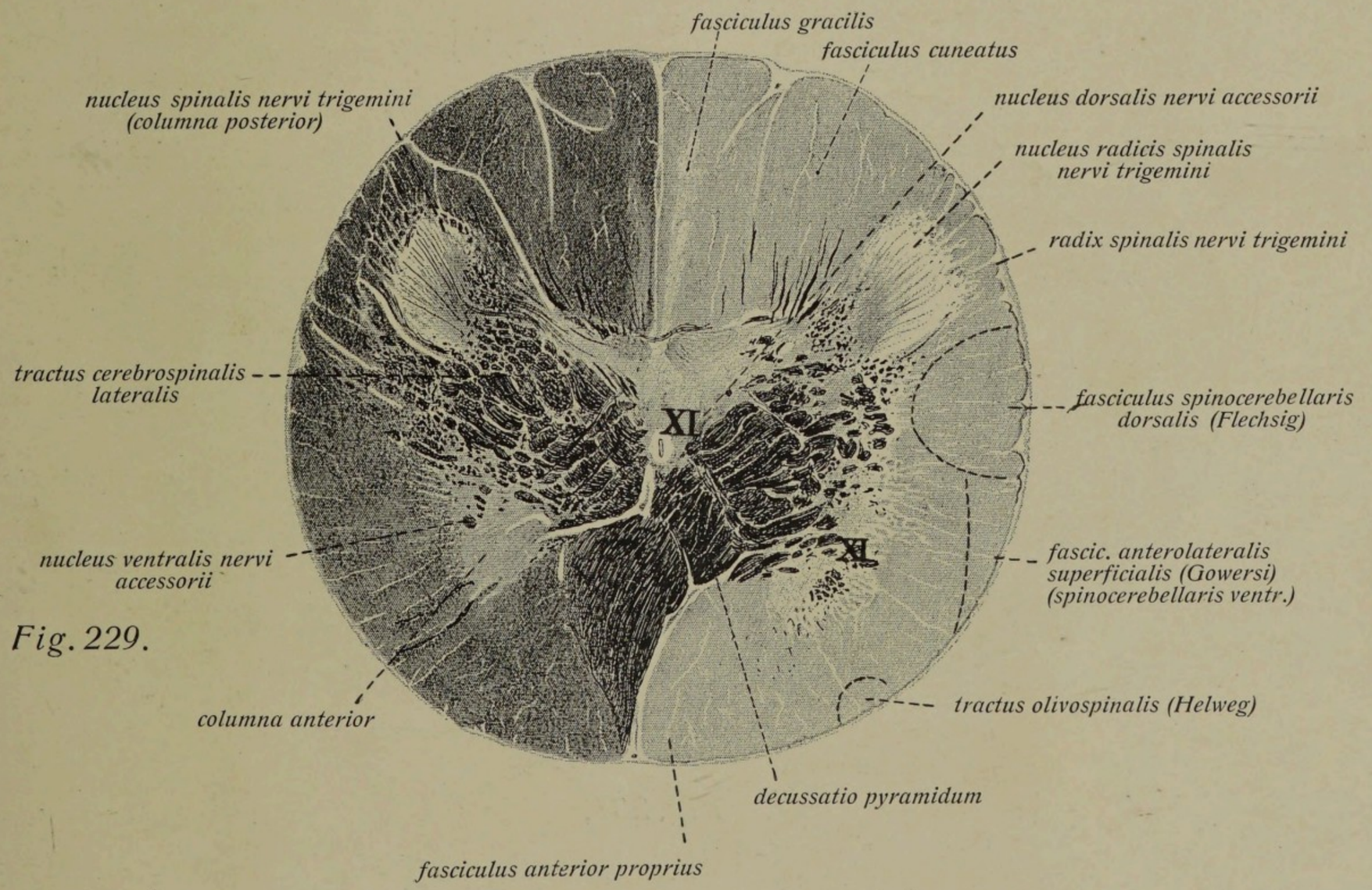

Fig. 229.

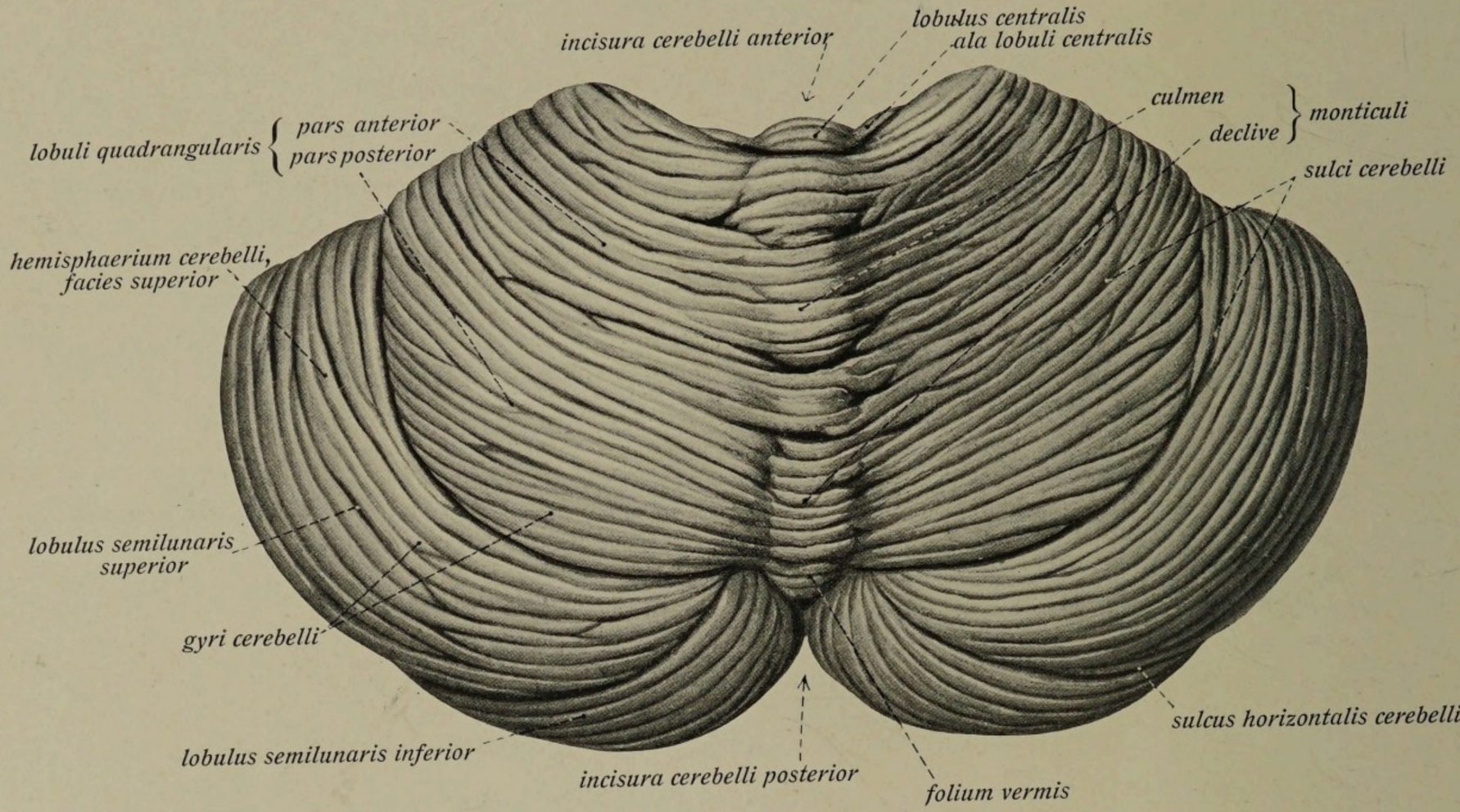

Fig. 230.

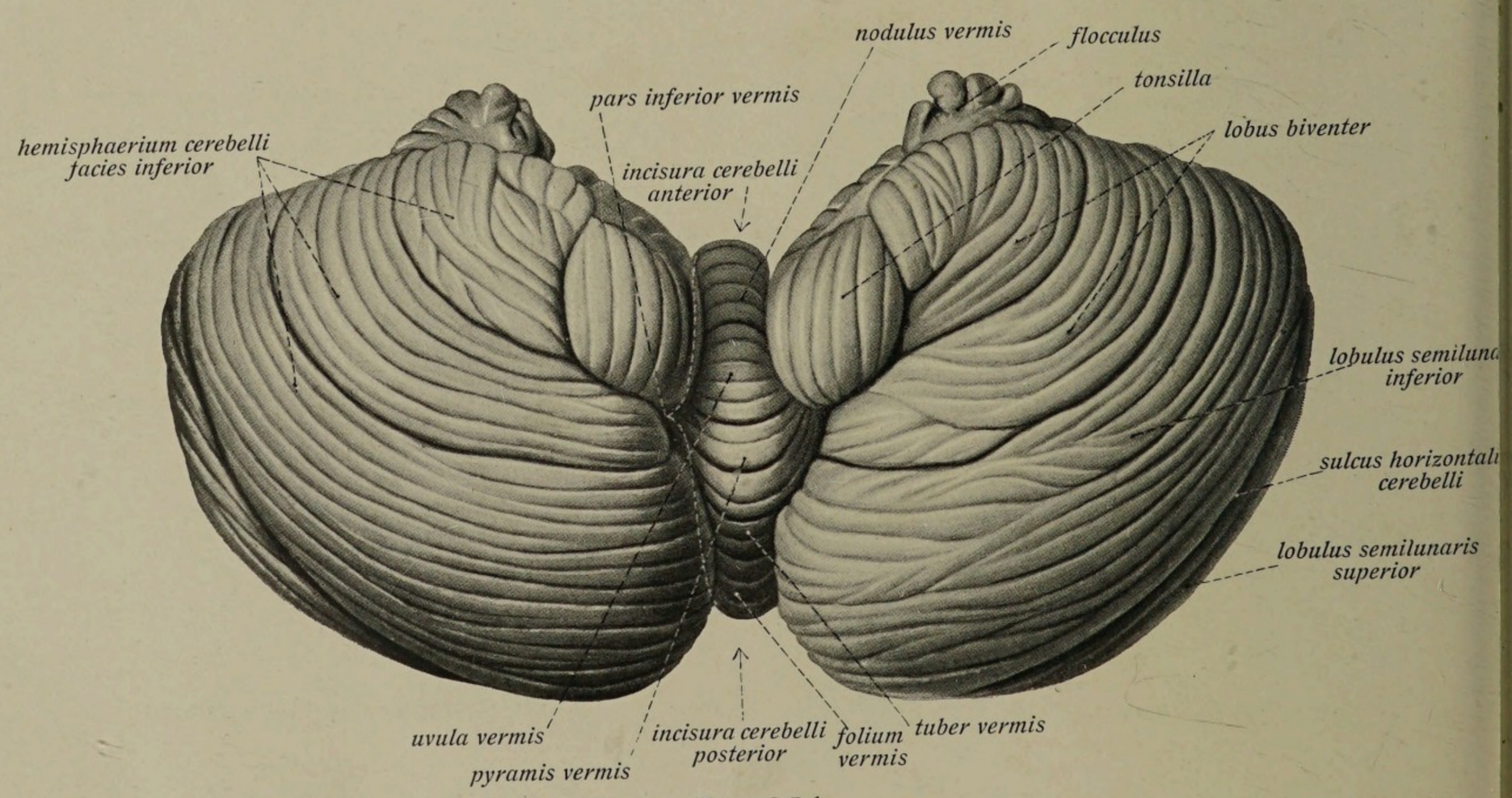

Fig. 231.

The Central Nervous System. The Brain. (Cont.)

The Cerebellum.

Fig. 230. The cerebellum seen from above and behind. (1/1)
Fig. 231. The cerebellum seen from below. (1/1)
The cerebellar peduncles have been cut and the pia mater removed.

The Cerebellum

is a relatively independent portion of the brain, characterized by the conformation of its surface. It differs from the cerebrum by its darker (reddish brown) colour and by the close succession and regular arrangement of its surface furrows (see below). It is a transverse, ellipsoidal mass, behind and above the rhomboidal fossa in the region of the medulla oblongata, the pons and the colliculi (partly), and below (and behind) the cerebral hemispheres, being overlapped by their occipital lobes. It is separated from the hemispheres by the tentorium (see p. 152). Its surface is formed of grey substance (cortex) and is divided by very narrow, almost parallel *sulci* into thin *gyri*.

The cerebellum consists of a small unpaired middle portion, the *vermis*, and two paired *hemispheres*. On their sloping upper surface the hemispheres pass without demarcation into the vermis, which here projects above them (superior vermis), while the inferior vermis is separated from the strongly convex and prominent hemispheres by a deep, broad groove, the *vallecula*. At the convex borders of the hemispheres the boundaries of the two parts are indicated by flat notches, the *anterior* and *posterior incisures*. The cerebellum is united by three peduncles with the neighboring parts of the brain stem, namely, by the brachia conjunctiva (see p. 196) with the midbrain, by the brachia pontis (see p. 224), the strongest of the three, with the pons and by the *restiform bodies* (see p. 226) with the medulla oblongata. Fig. 148, 149, 178, 183, 230—235.

Each **cerebellar hemisphere** is divided by a *horizontal sulcus* into a *superior* and an *inferiore* surface. By somewhat deeper sulci the superior surface is divided into the following lobes: 1. the *ala of the central lobule*. 2. the *quadrangular lobule* and 3. the *superior semilunar lobule*. On the more convex inferior surface there may be distinguished: 1. the *inferior semilunar lobule*, 2. the *lobulus biventer*, 3. the prominent *tonsil* and 4. the *flocculus*. The last, the smallest of the lobes, projects strongly on the basal surface of the hemisphere and is attached to it by a flat *peduncle*. Each lobule consists of a small, dendritically branched *medullary lamina*, over whose branchings there is a thin layer of grey cortex *(substantia corticalis)*. The medullary laminae arise from a flattened mass of white substance in the interior of the hemisphere, the *medullary body*. Fig. 174, 178, 183, 184, 230—235.

The Central Nervous System. The Brain. (Cont.)

Fig. 232. The cerebellum seen from in front, after cutting the cerebellar peduncles. (1/1)

Fig. 233. The cerebellum seen from below and somewhat from behind.
The right tonsil has been removed and the pons cut transversely, so that a portion of the fourth ventricle is seen.

The Cerebellum. (Cont. from p. 237.)

The Vermis of the Cerebellum is a relatively small, unpaired, medial structure uniting the two hemispheres, and, like these, consists of a central medullary substance, *corpus medullare*, which projects as *medullary laminae* into the individual lobes of the vermis, where they are covered by the grey substance of the gyri, forming the *arbor vitae*.

The superior vermis corresponds to the superior surface of the hemispheres and from before backwards is divided into 1. the *lingula*, a small, flat half-lobe lying close to the anterior medullary velum and passing laterally into two small strips of fibres, the *vinculum*, which apply themselves to the corresponding brachia pontis; it has no corresponding lobe on the hemisphere.[1]) 2. the *central lobule*, larger than the preceding and smaller than the next, corresponds to the ala of the central lobule of the hemisphere. 3. The *monticulus* forms the greater part of the superior vermis and is divided into the *culmen* and *declive montis*; it corresponds to the quadrangular lobule of the hemisphere. 4. The *folium*, a small lobule in the posterior incisure; it forms the transition to the inferior vermis and corresponds to the superior semilunar lobule of the hemisphere.

The inferior vermis consists of: 5. The *tuber*, which corresponds to the inferior semilunar lobule of the hemisphere. 6. The *pyramid*, corresponding to the lobulus biventer. 7. The *uvula*, which connects the two tonsils and 8. the roundish *nodulus*, which, close behind the tela chorioidea of the fourth ventricle, corresponds to the flocculus. Fig. 149. 178. 230—233.

Just as ganglia are imbedded in the white substance of the cerebral hemispheres, so too in the cerebellum. The largest is the flat *dentate nucleus*, formed by a thin, folded layer of grey substance enclosed by the medullary substance and also enclosing a portion of it which is connected with the surrounding substance at the hilus. Concentric fibres surround the nucleus, forming its *capsule*. Near the hilus of the dentate nucleus lies the much smaller, elongated *emboliform nucleus* and beside this the variable *nucleus globosus* and, finally, in the roof of the fourth ventricle, the *fastigial nucleus*. Fig. 234, 235.

---

[1]) Providing that the vincula linguae are not assigned to the hemispheres.

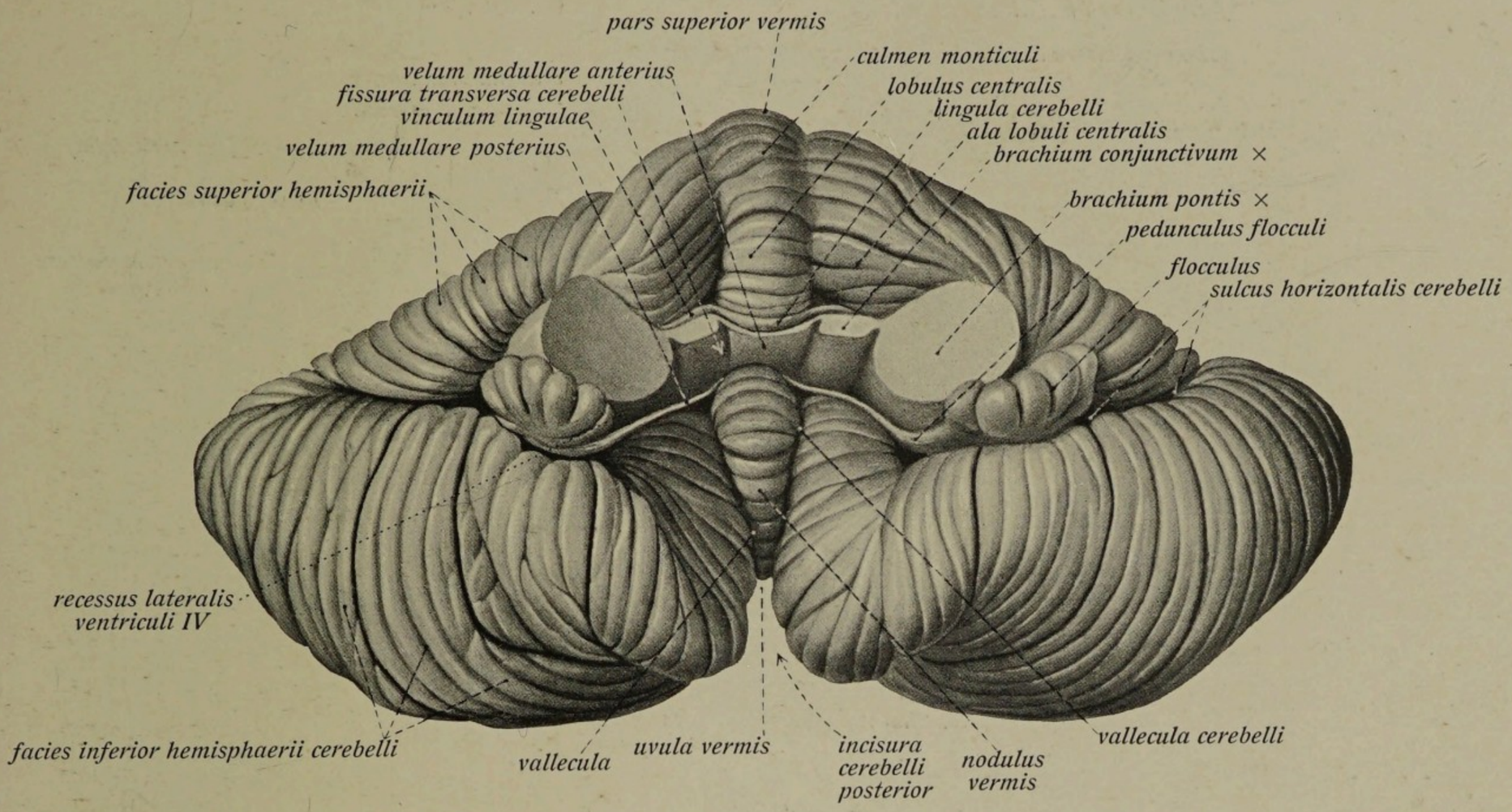

Fig. 232.

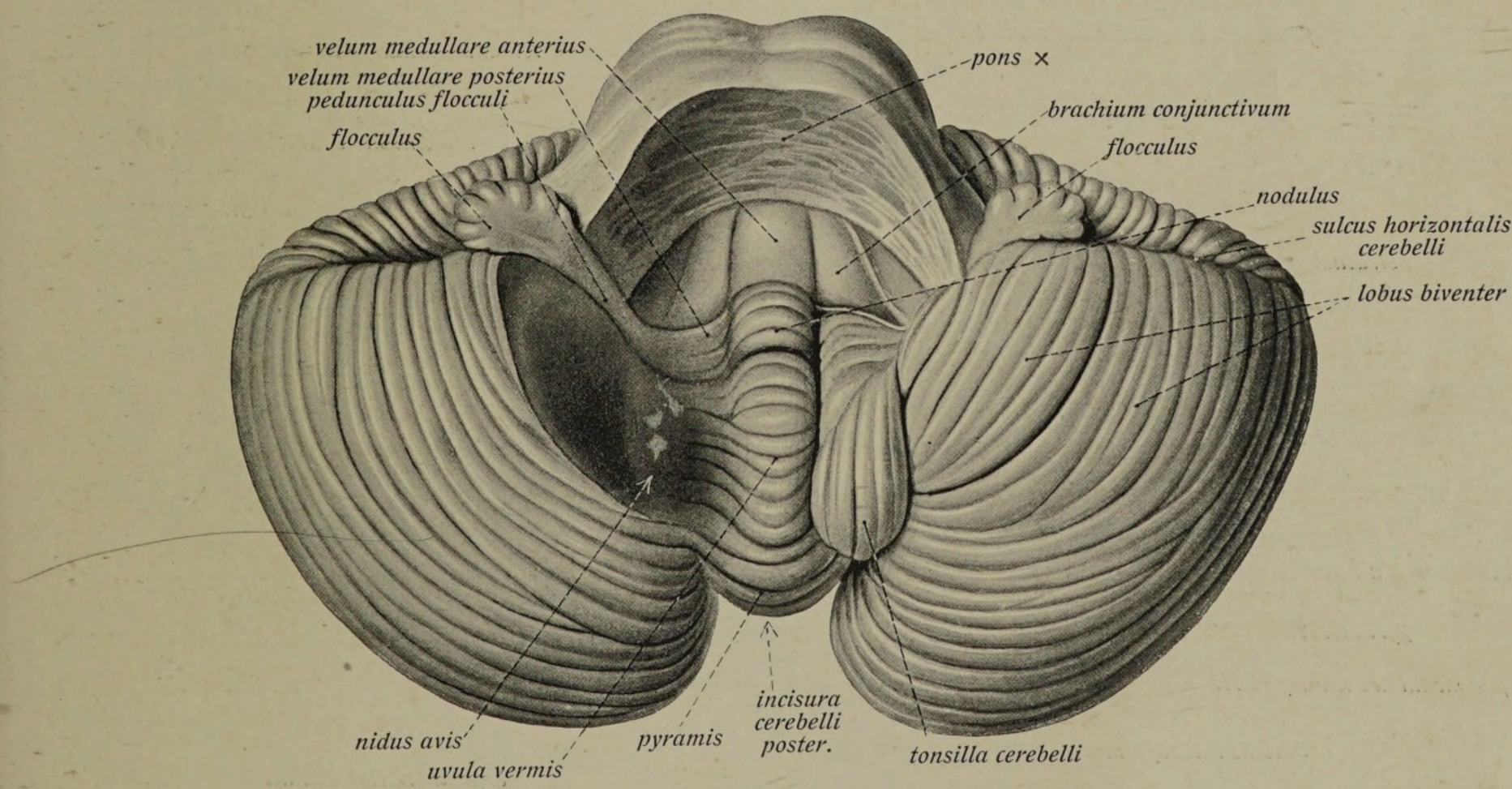

Fig. 233.

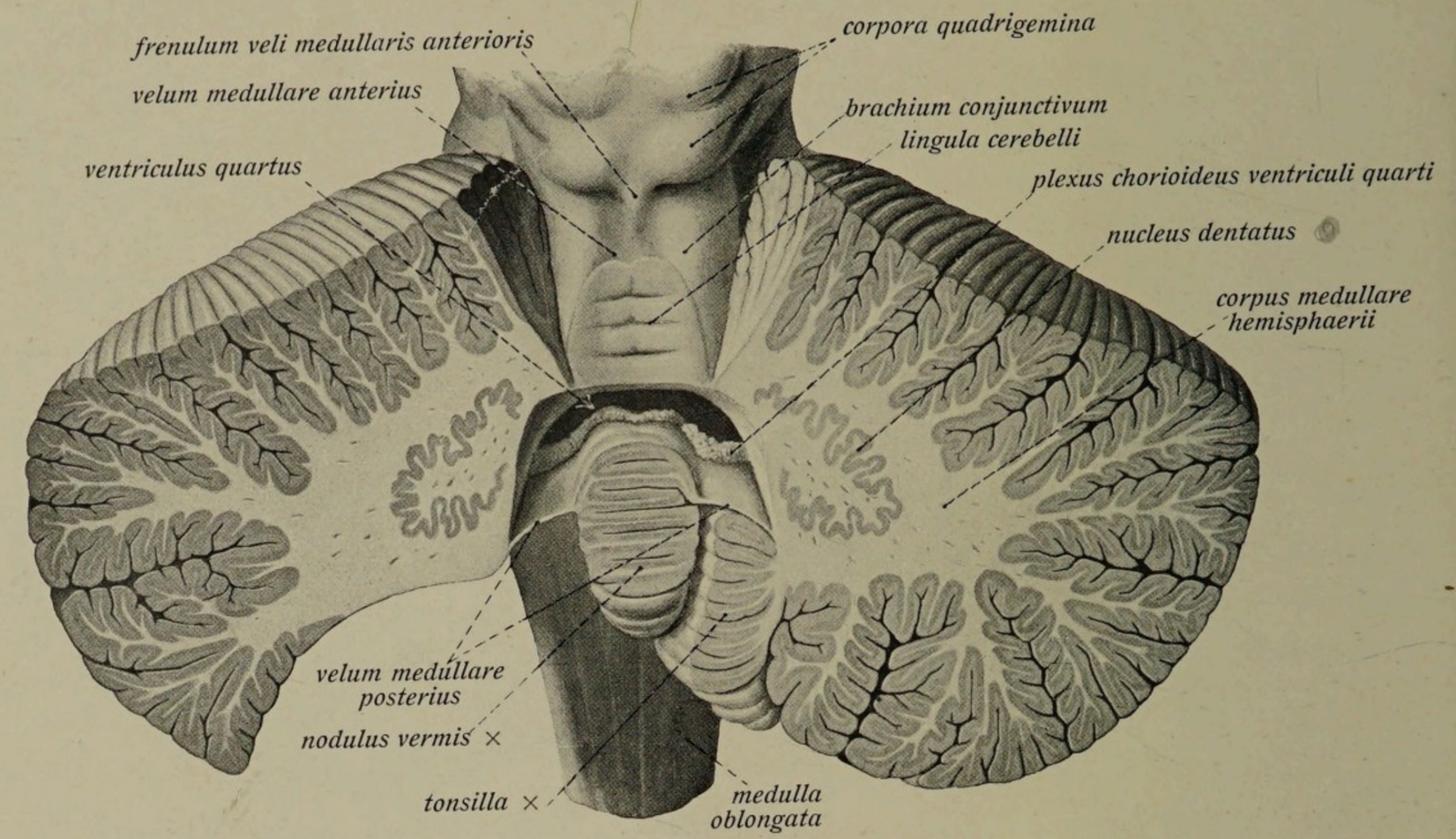

Fig. 234.

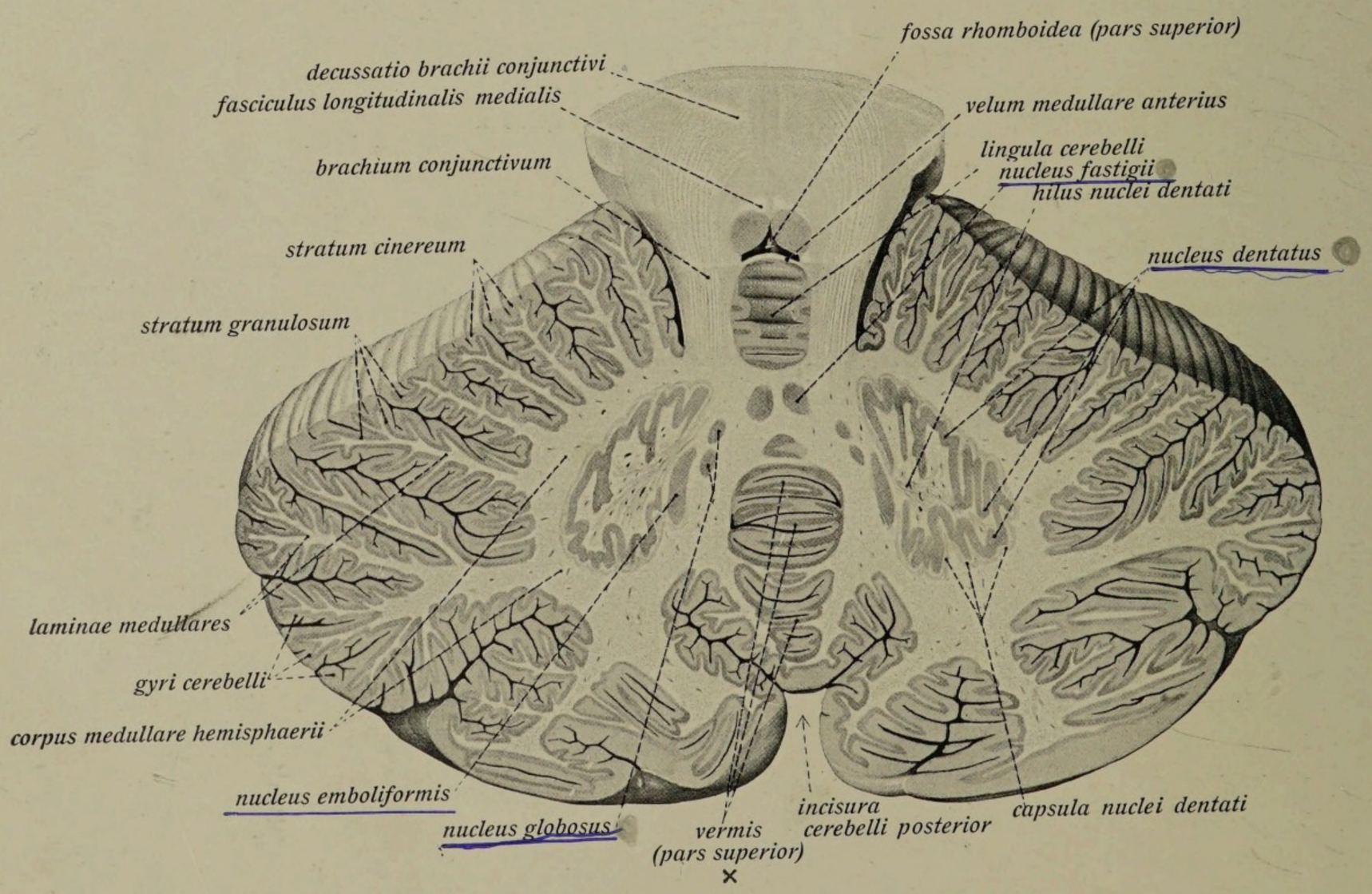

Fig. 235.

The Central Nervous System. The Brain. (Cont.)

The Cerebellum.

Fig. 234. The boundaries of the fourth ventricle shown by a partial removal of the cerebellum. (1/1). The vermis of the cerebellum is removed as far as the lingula and nodulus, the posterior portions of the hemispheres are removed by an almost vertical section, and from the left hemisphere the tonsil and lobus biventer are also removed, in order to show the posterior medullary velum. The roots of the trochlear nerve are removed.

Fig. 235. Section through the cerebellum in the plane of the brachia conjunctiva. (1/1)

The Cerebellum.

The principal Cerebellar conducting Paths.

In the cerebellum the following are the most important paths:

I. The *arcuate (arciform) fibres*, short tracts uniting cortical areas of the same hemisphere.

II. Fibres from the cortex to the dentate and fastigial nuclei and to Deiter's vestibular nucleus.

III. Fibres that unite the cerebellum with other portions of the brain and running, accordingly, in the cerebellar peduncles. These are:

1. The fibres of the brachia conjunctiva. These arise from the dentate nucleus, cross in the decussation of the brachia conjunctiva and pass to the nucleus ruber and thalamus of the opposite side. Some descending collaterals pass to the medulla oblongata. They also contain Gower's lateral cerebellar tract.

2. The fibres of the *brachium pontis*, which arise from the pons nuclei and pass to the hemisphere of the opposite side.

3. The fibres of the *restiform body*, which arise partly in the spinal cord and partly in the medulla oblongata. A medial and a lateral group of fibres may be made out; the former unite the sensory cranial nerve nuclei with the cerebellum, whereby fibres of the vestibular râmus of the acoustic nerve and fibres of the trigeminus pass directly, to the cerebellum (tegmental nucleus). One may speak, therefore, of a direkt sensory cerebellar path, in contrast to the connections of the sensory nuclei with the tegmental nucleus = indirect sensory cerebellar path.

The lateral portion of the restiform body contains: fibres from the nuclei of the posterior funiculi to the cerebellar cortex, these being both crossed and uncrossed (external arcuate fibres); fibres of Flechsig's lateral cerebellar tract and fibres from the olivary nucleus of the medulla oblongata, *cerebello-olivary fibres*; the majority of these last fibres are crossed and end in the cortex of the vermis.

The Sense Organs.

The Eye.

Fig. 236. The fundus of a moderately pigmented eye as seen by the ophthalmoscope (From Haab, Atlas der Ophthalmoskopie). The retinal vessels show distinct reflex striae. The optic papilla shows a distinct scleral, but a diffuse chorioidal ring.

Fig. 237. The fundus of a slightly pigmented eye as seen by the ophthalmoscope. (From Haab, Atlas der Ophthalmoskopie.) The chorioidal vessels are visible, shining through. The optic papilla has both the scleral and chorioidal rings distinct.

p n o = papilla of the optic nerve. fc = central fovea. vsr = retinal blood vessels. * = retinal veins. ** = chorioidal ring. × = retinal arteries.

The Eyeball.

The eyeball, *bulbus oculi*, is almost spherical, but its anterior sixth (corneal segment) has a stronger curvature than the rest.

It consists of three concentric membranes, curved in correspondence with the outer surface and enclosing the transparent, partly fluid, partly compact contents of the eye. The outer membrane is the *tunica fibrosa*, the middle one the *tunica vasculosa* and the inner one the *retina (tunica nervosa)*. The contents of the eyeball are separated by the *iris*, formed from the middle membrane, into two principal parts. In front of it lies the *anterior chamber (camera)* of the eye, whose other boundary is formed by the *cornea*, the anterior transparent part of the fibrous tunic. Behind the iris there is a firm convex *crystalline lens*, fastened to the so-called ciliary body of the middle tunic by the *zonula ciliaris*. Between this and the iris is the small *posterior chamber (camera)*. The entire cavity of the eyeball behind the lens, is filled by the *vitreous body (vitreous humor)*, a semifluid mass.

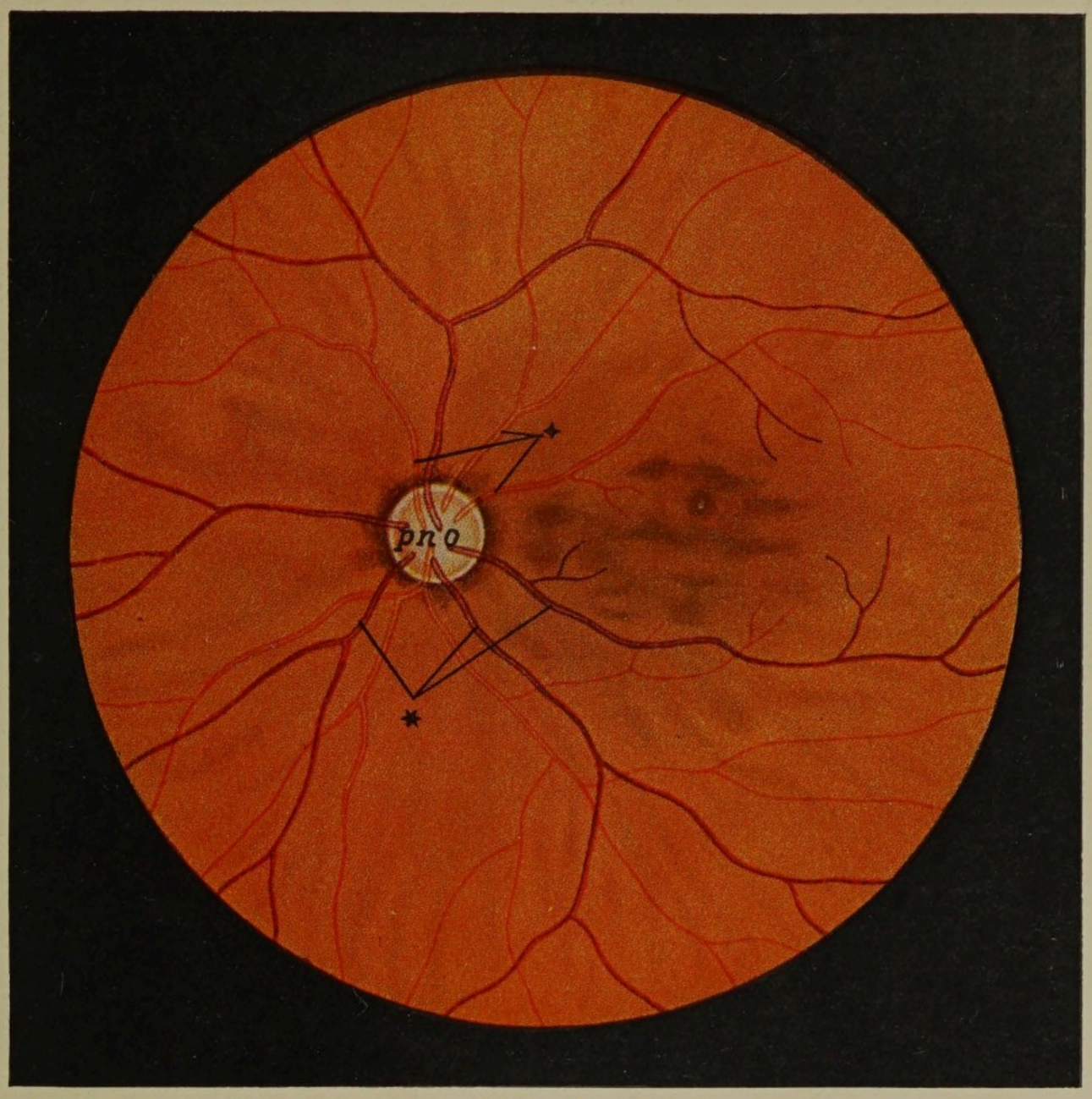

Fig. 236

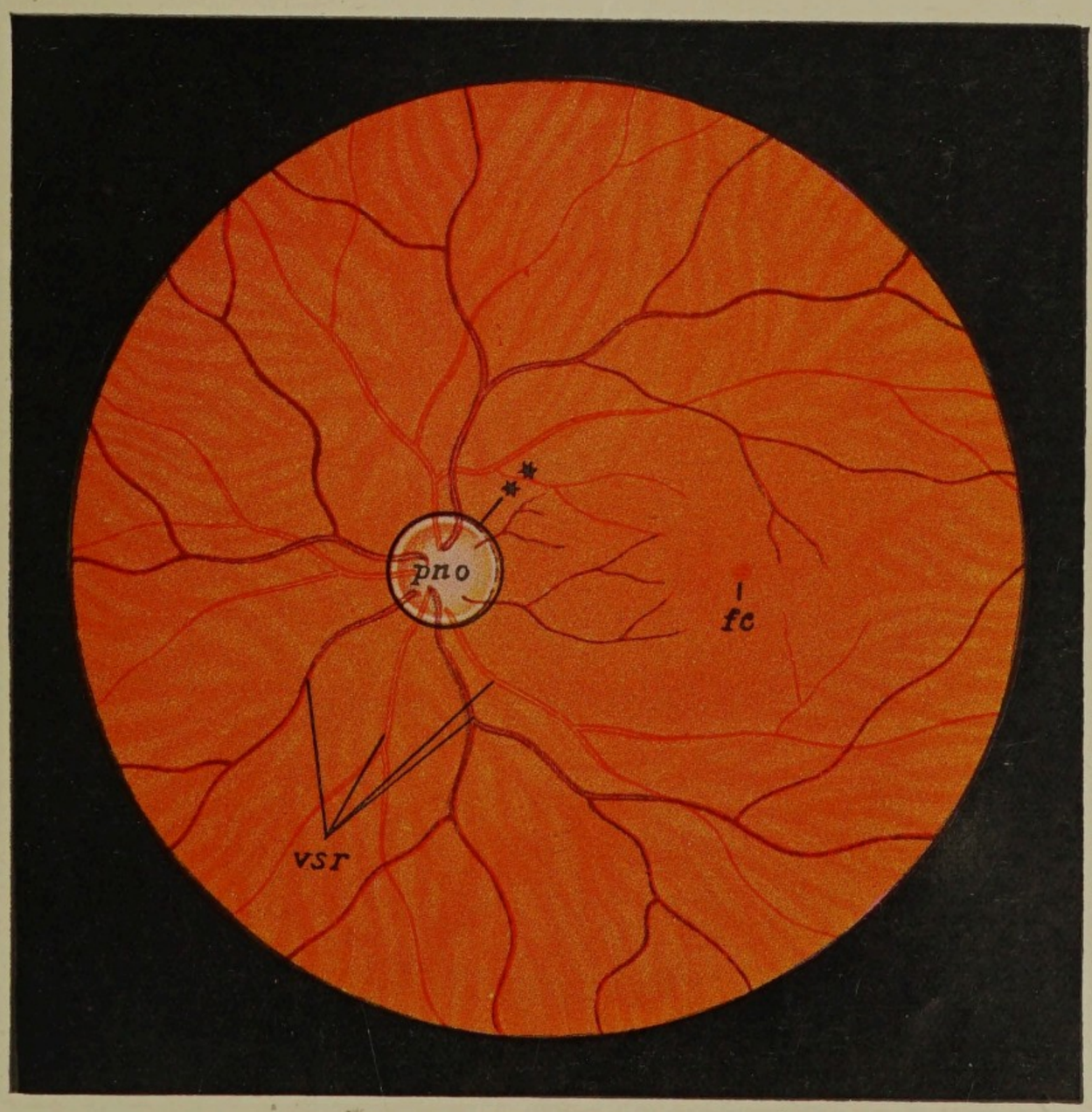

Fig. 237

Fig. 238. He
ind

The Eye. (Cont.)

The Eyeball.

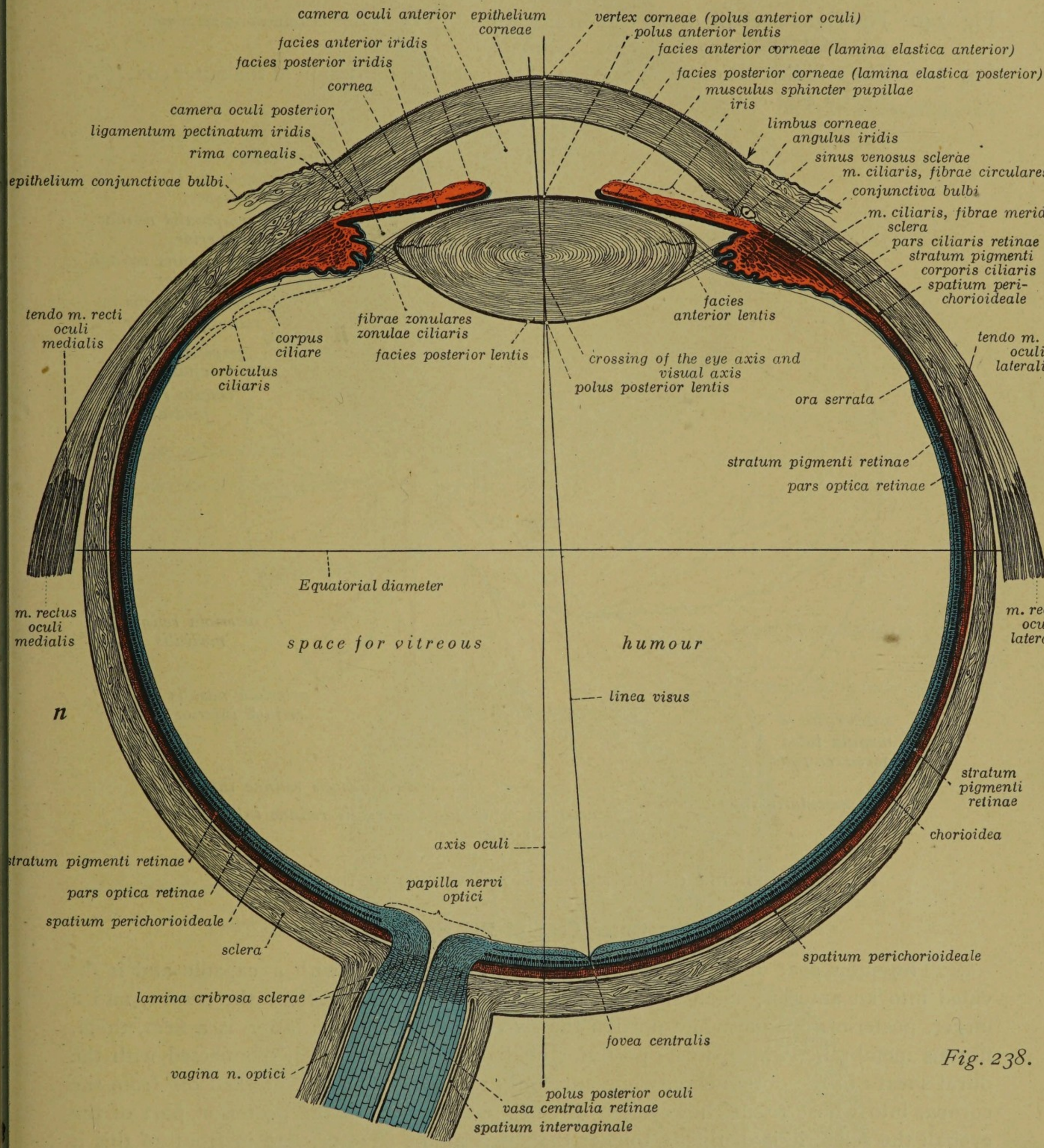

Fig. 238.

Fig. 238. Horizontal meridional section of the eyeball (schematic). The inner membrane is indicated by blue, the middle one by red. n = nasal, t = temporal.

The Eye. The Eyeball. (Cont.)

Fig. 240. The right eyeball divided meridionally. ($^5/_1$) The vitreous humor is removed.
n = nasal, t = temporal.

Fig. 241. The middle coat of the eye, exposed by meridional division of the outer coat. ($^4/_1$)
* = cut edge of the pectinate ligament.

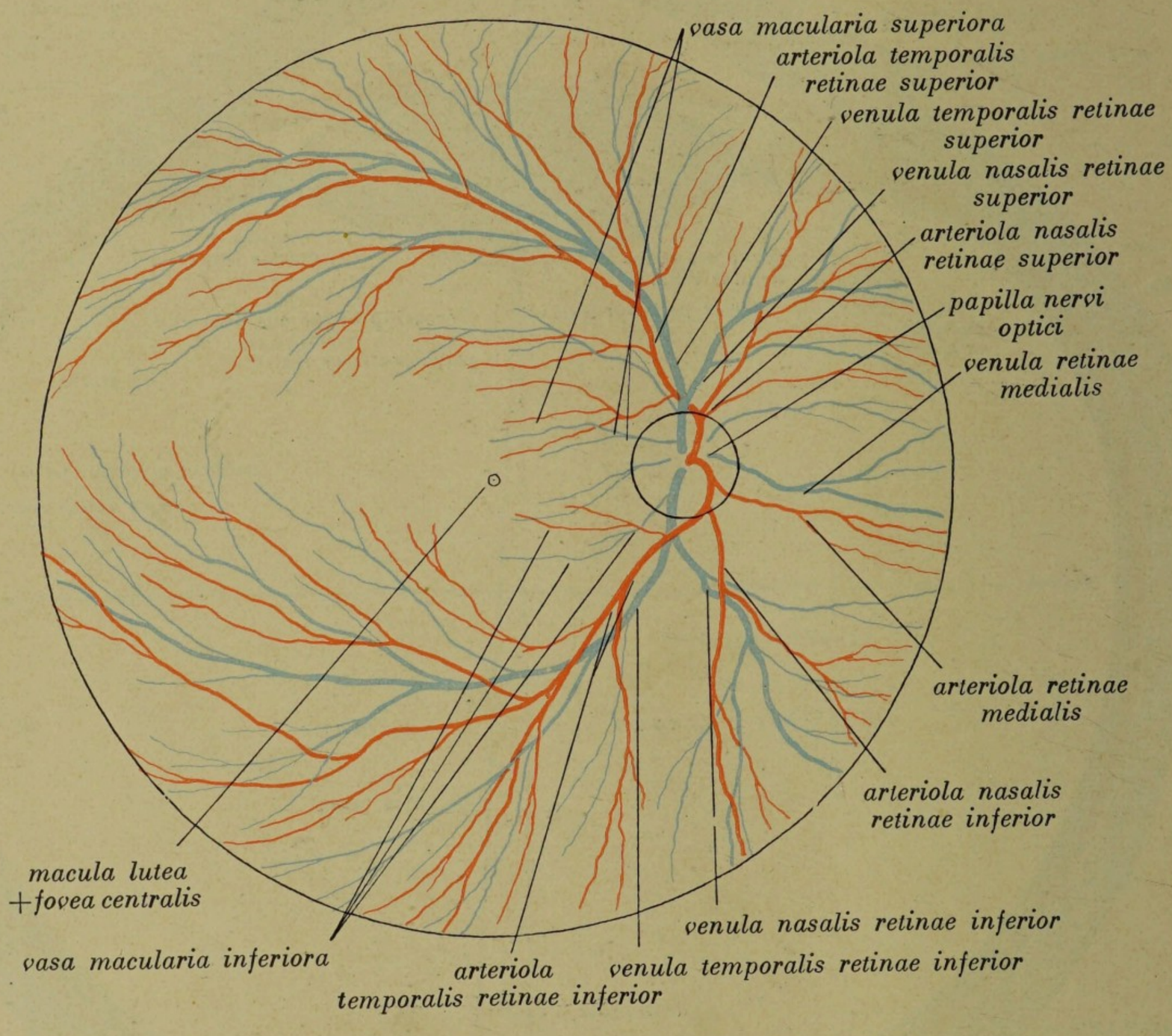

Fig. 239. Schema of the retinal blood vessels of the right eye.

The Outer Coat of the Eyeball.

The outer coat of the eye encloses the entire eyeball as with a capsule and is divided into an anterior, smaller, transparent, strongly curved portion, the *cornea*, and a larger, posterior, opaque white portion the *sclera (sclerotic)*. The latter is a firm, thick, fibrous membrane, which, in its posterior medial part, is intimately connected with the dural sheath of the optic nerve, while anteriorly it is rather sharply marked off from the cornea, into whose tissue, however, it directly passes over. In the posterior part of the eyeball the sclerotic is distinctly thicker than it is at the equator, and in front of this it is again thickened, owing to the insertion of the rectus muscles of the eyeball.

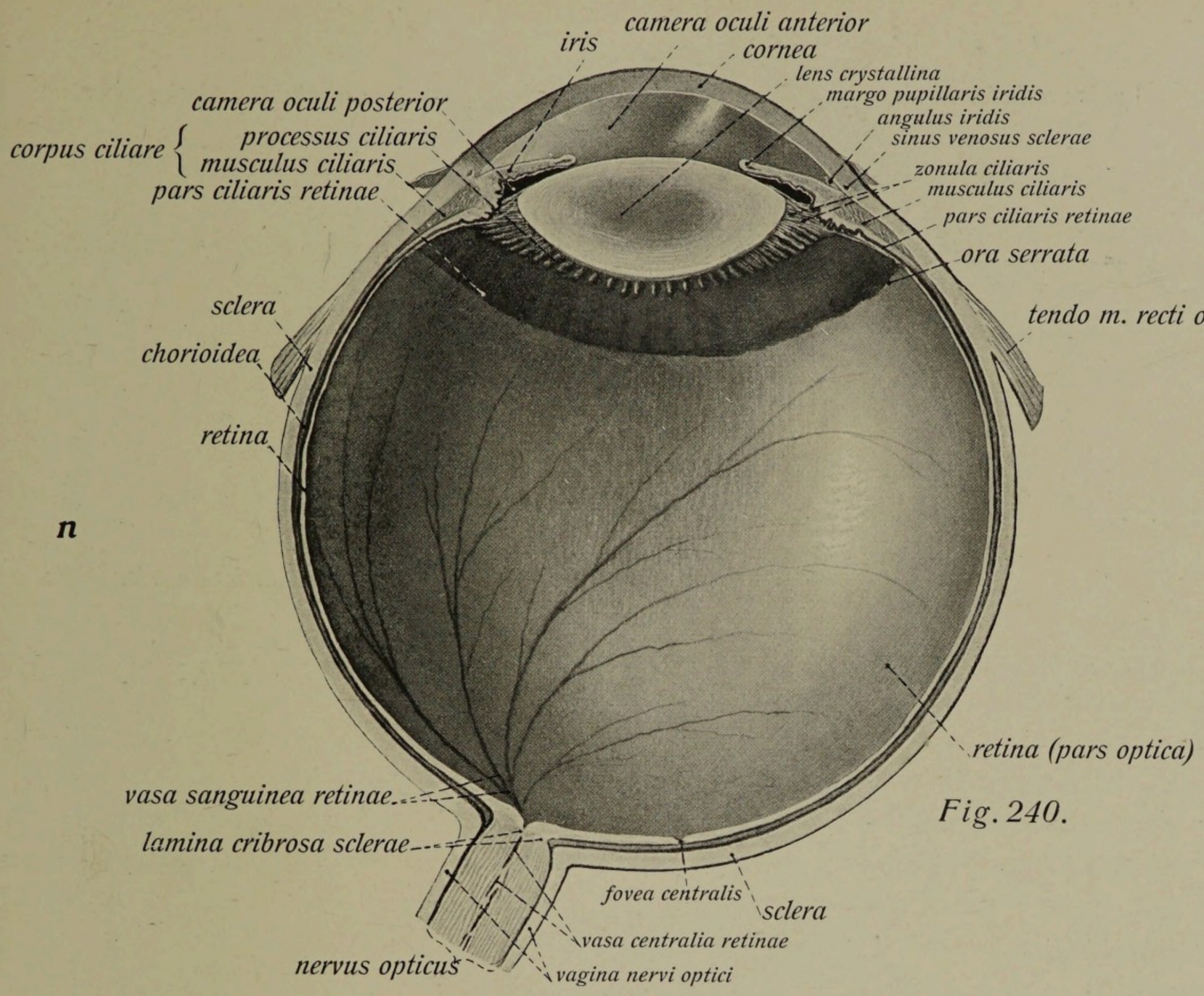

Fig. 240.

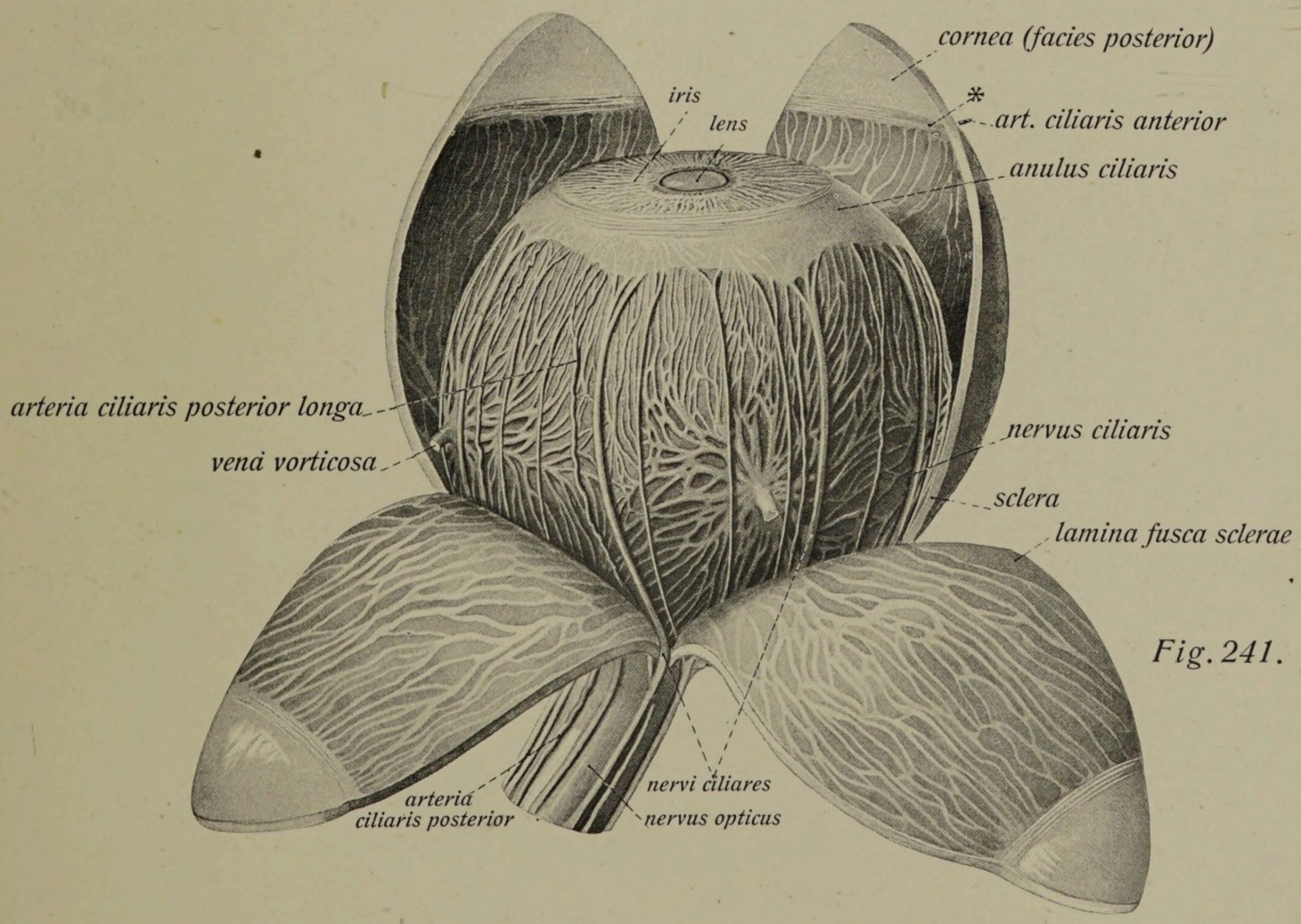

Fig. 241.

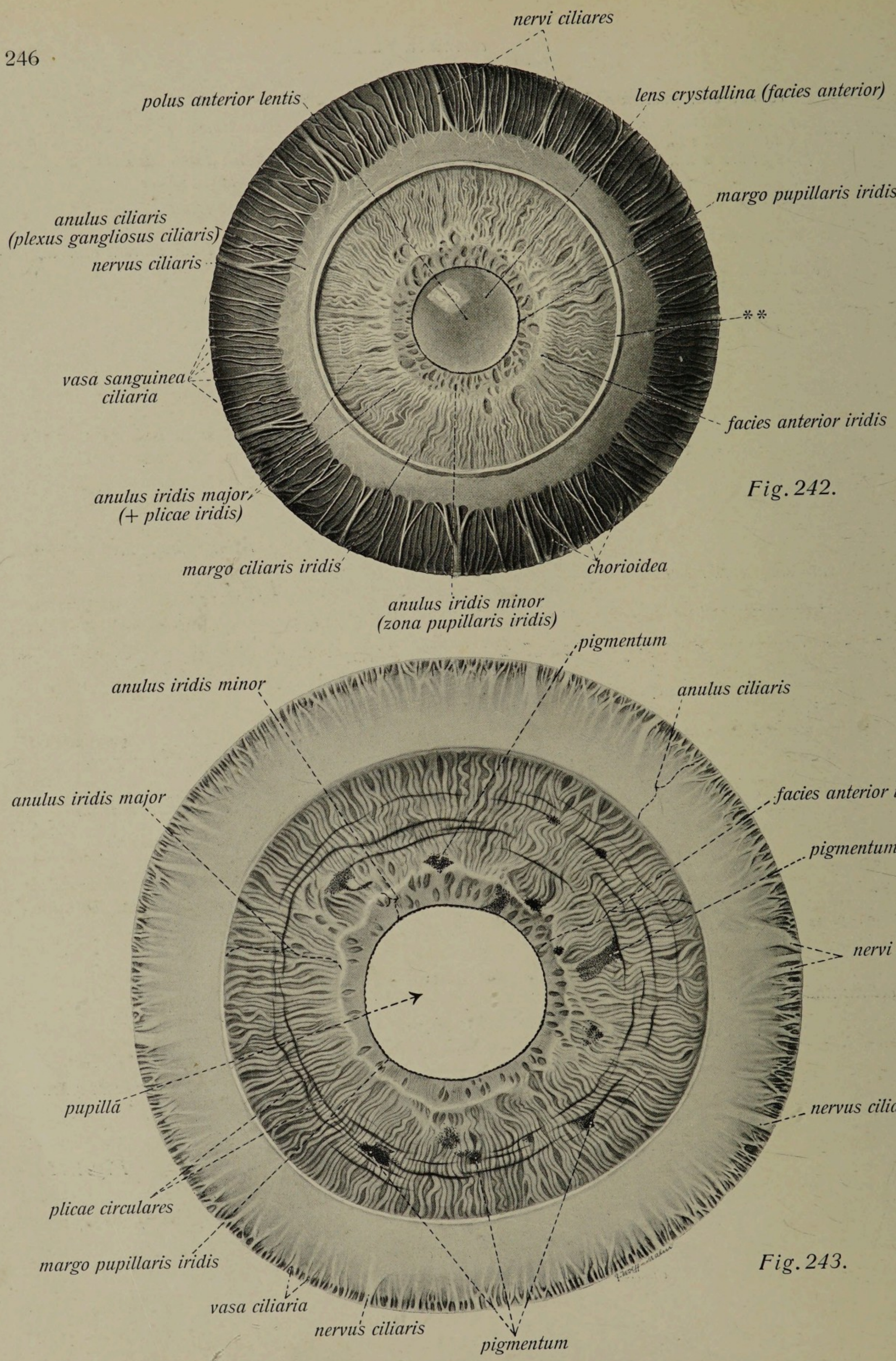

Fig. 242.

Fig. 243.

The Eye. The Eyeball. (Cont.)

Fig. 242. The middle coat of the eye from in front, after the complete removal of the cornea and sclerotic. ($^5/_1$)
** = remains of the sclerotic (placed over the pectinate ligament).

Fig. 243. Anterior surface of the human iris. ($^{10}/_1$)
The outer coat of the eye is removed; around the iris the ciliary anulus is visible. Pigment flecks in the iris and several circular folds of contraction are seen.

The Outer Coat of the Eyeball. (Cont.)

The sclerotic passes into the cornea in such a way that it forms a sort of groove for the reception of the margin of the cornea *(rima cornealis)*. The groove that indicates the boundary between the sclerotic and cornea on the anterior surface of the eyeball is termed the *scleral sulcus*. It corresponds closely to a circular venous sinus, the *canal of Schlemm*, which lies in the sclerotic close to its inner surface. In its posterior part, to the nasal side of the axis of the eyeball, the sclerotic is pierced in a circular area by the bundles of the optic nerve, this area being termed the *lamina cribrosa*. The inner surface of the sclerotic is united to the middle coat by a thin layer of delicate pigmented tissue, the *lamina fusca*, an exceedingly thin *perichorioidal space* intervening. In the region of the so-called *pectinate ligament* there is an intimate connection of the anterior part of the sclerotic with the margin of the iris.

The **cornea** is a transparent, saucer-like membrane, which is more strongly curved than the sclerotic. Its surfaces are *anterior* and *posterior*; the point of its greatest curvature is the *vertex* and the border by which it connects with the sclerotic, the *limbus*.

It is thicker than the sclera and its marginal part is thicker than the central part. Both surfaces are smooth and are almost concentrically curved. The anterior one has a slightly greater area and is covered by the *corneal epithelium*, which at the limbus of the cornea passes imperceptibly into that of the conjunctiva (see p. 259); the posterior surface is covered by the *corneal endothelium* and forms the anterior wall of the anterior chamber of the eye.

The Middle Coat of the Eyeball.

The middle coat of the eyeball is a thin and soft, pigmented membrane, which carries the blood vessels and the internal musculature of the eye. It consists of three parts. The posterior, which is the chief, is termed the *chorioid* and is closely applied to the sclerotic. At the point of entrance of the optic nerve it is perforated. The anterior part of the middle coat, the *iris*, has the form of a diaphragm with a central opening, the *pupil*, and rests on the anterior surface of the lens. The middle part, which, however, is in front of the equator of the eyeball, is thickened and forms what is called the *ciliary body*. This is rather firmly attached to the anterior portion of the sclerotic by a ring-shaped thickening, the *ciliary anulus*.

The Eye. The Eyeball. (Cont.)

Fig. 244. The anterior half of a right eyeball divided at the equator, from behind. The vitreous humor is removed. ($^5/_1$) n = nasal.

Fig. 245. The posterior half of a right eyeball divided at the equator, from in front. The vitreous humor is removed. ($^5/_1$) t = temporal.

The **chorioid** is a thin, pigmented, vascular membrane, whose perfectly smooth inner surface is turned towards the retina, while its rougher outer surface is in contact with the sclerotic. On its outer surface one sees the larger vessels and nerve stems, running for the most part meridionally, and especially the radially arranged venous roots of the *vorticose* veins. The layer of the chorioid in which the large vessels and nerves lie is termed the *vascular lamina*, the inner layer the *chorio-capillary lamina*, since it contains the capillaries. The actual chorioid is not in direct contact with the sclerotic, but is connected with it by a thin pigmented *supra-chorioidal lamina*, both layers of tissue passing into one another; nevertheless the space occupied by the loose lamina is termed the *perichorioidal space*.

The **ciliary body** is a ring-shaped thickening of the middle coat, which passes insensibly into the chorioid posteriorly, while the outer border of the iris arises from its anterior part. It consists of a *ciliary muscle* lying close to the inner surface of the anterior part of the sclerotic and a *corona ciliaris*. The muscle is a ring-shaped band. triangular in section, in the region of the *anulus ciliaris*; it consists of external *meridio-nal fibres* and internal *circular* ones. The corona ciliaris is the surface turned to the posterior chamber of the eye and the vitreous humor and possesses about 70 radially arranged vascular projections, the *ciliary processes*, between which is a variable number of smaller *ciliary folds*. The processes and folds are highest at their anterior ends, in the neighbourhood of the equator of the lens. Their summits are unpigmented and conse-quently appear as pale lines on relatively dark backgrounds. The *orbiculus ciliaris* is the posterior part of the ciliary body, which passes insensibly into the chorioid, the boundary between the two corresponding to the ora serrata of the retina.

The **iris** has the form of a transverse circular disk perforated at the centre, whose *anterior* surface is a boundary of the anterior chamber of the eye, while the *posterior* is in contact with the lens. The central opening, the *pupil*, is surrounded by an almost circular, sharp border, the *margin of the pupil*, while the outer border, the *ciliary margin*, passes into the ciliary body. It is connected to the inner surface of the sclerotic by the *pectinate ligament*, this rounding off the angle between the cornea and iris; in the adult it is quite rudimentary.

The anterior and posterior surfaces of the iris have quite different appearances. The anterior surface shows a varying coloration according to the amount of pigment it contains; if it contains little or none, the bluish pigment of its posterior (retinal) layer shows through and it has a bluish color, but if it itself contains pigment, usually in flecks, it has a brownish color. Further, the anterior surface in the region of the pupillary margin possesses fine depressions or crypts, while the much broader ciliary region shows more or less distinctly wavy, radiating striations, wrongly termed *folds* of the iris, which are due to blood vessels shining through.

The posterior surface is always dark brown or black, since it is covered by the pigmented layer of the inner coat. Further, it has a folded surface, fine, almost concentric, folds being crossed with coarser radiating ones, the latter becoming closer and more numerous towards the pupillary margin. The dark pigment of the posterior surface extends to the border of the pupil and may be seen there as a finely notched border.

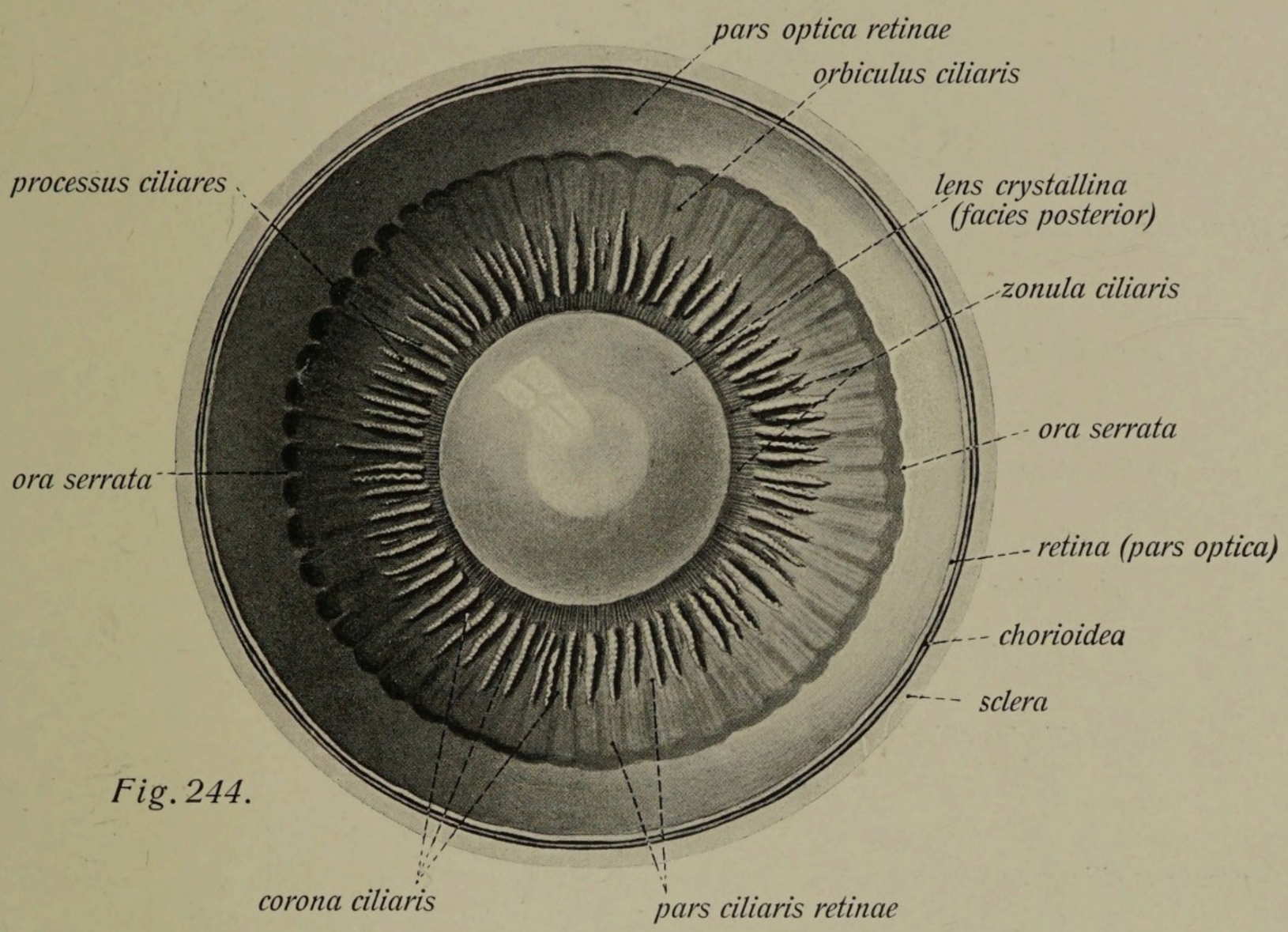

Fig. 244.

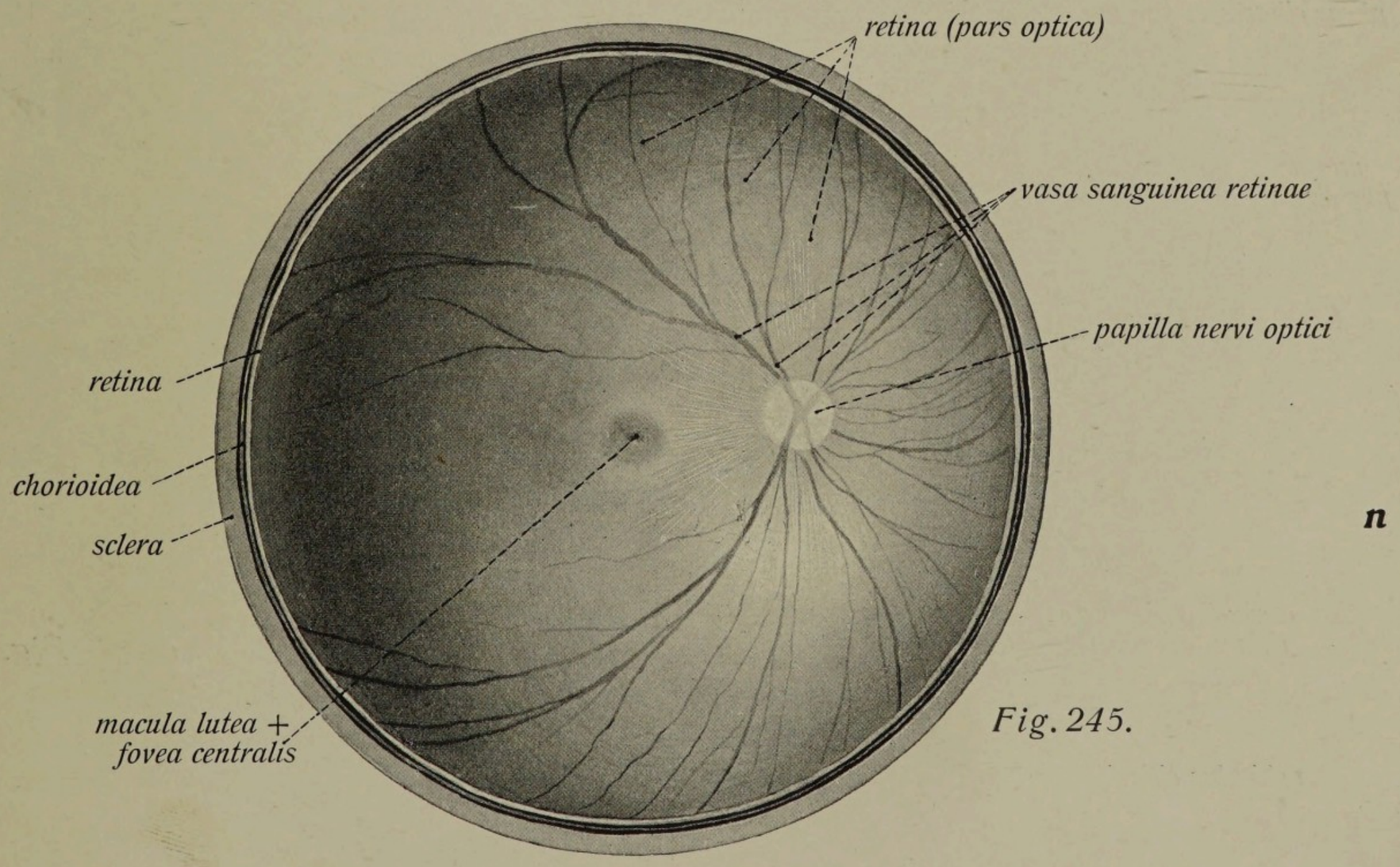

Fig. 245.

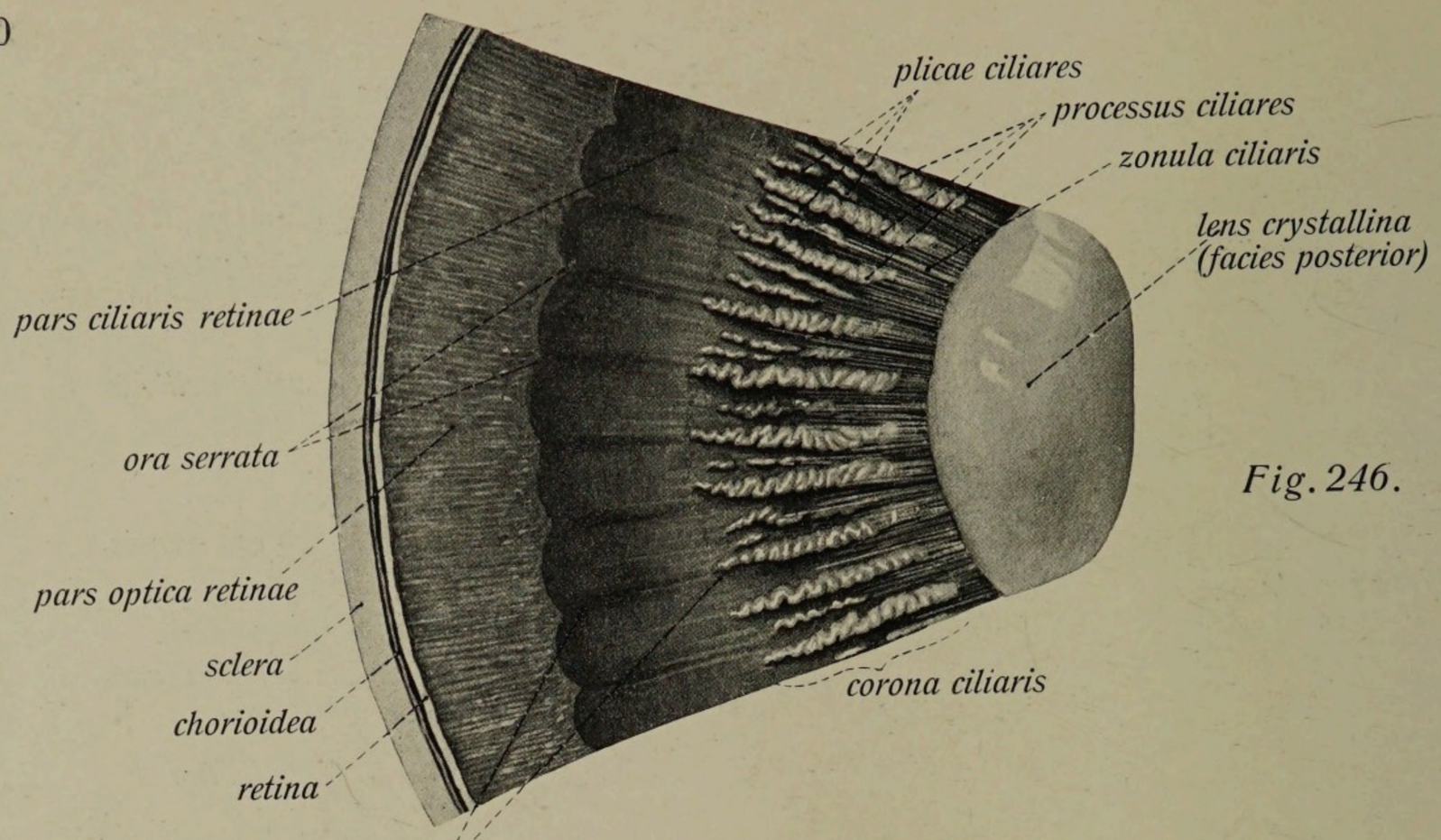

Fig. 246.

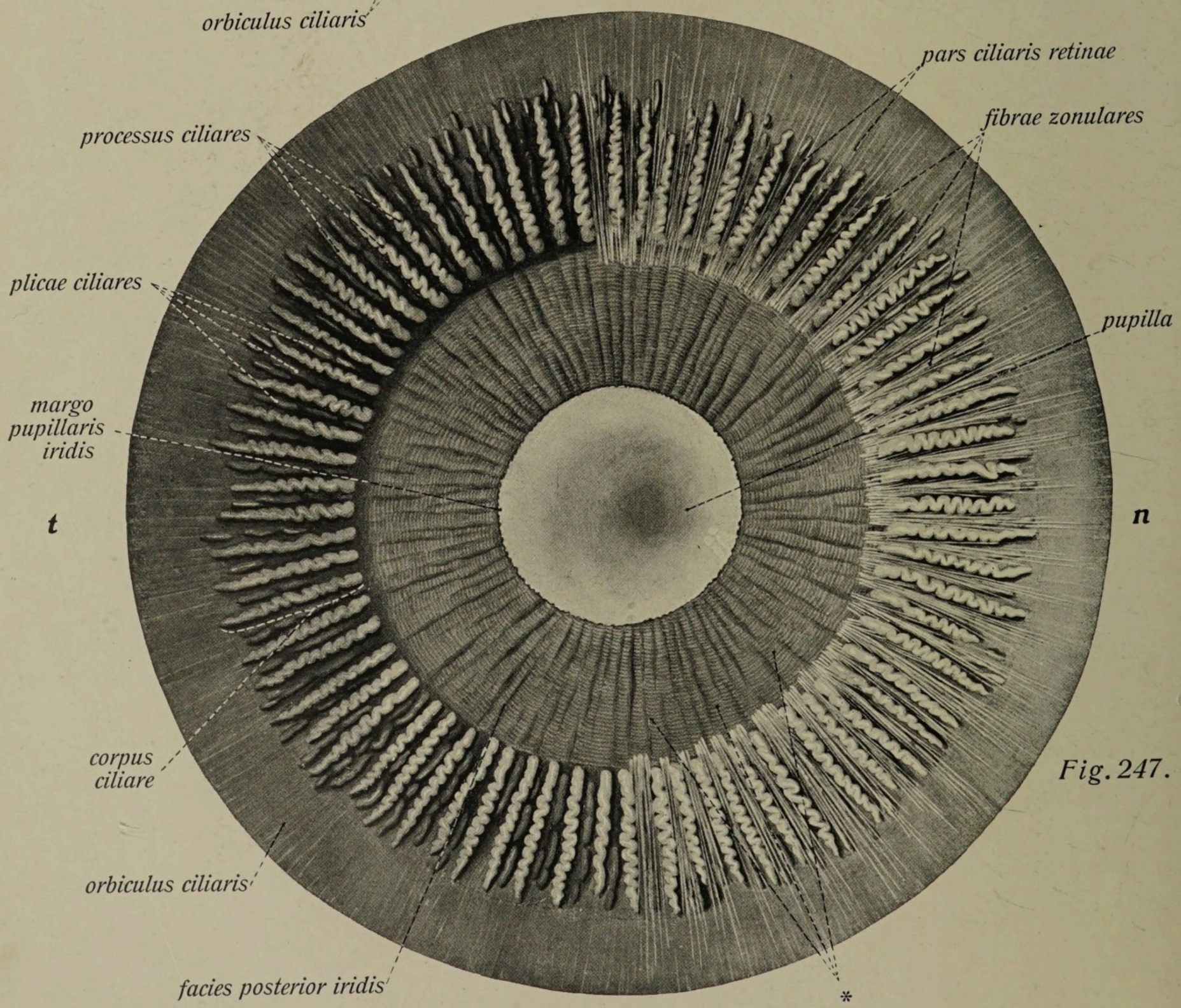

Fig. 247.

The Eye. The Eyeball. (Cont.)

Fig. 246. A portion of Fig. 244. ($^{10}/_{1}$)

Fig. 247. The posterior surface of the iris and the ciliary body after removal of the lens. ($^{10}/_{1}$)
On the left the zonula fibres are removed; in the pupil the posterior surface of the cornea is visible. * = folds of the posterior surface of the iris.

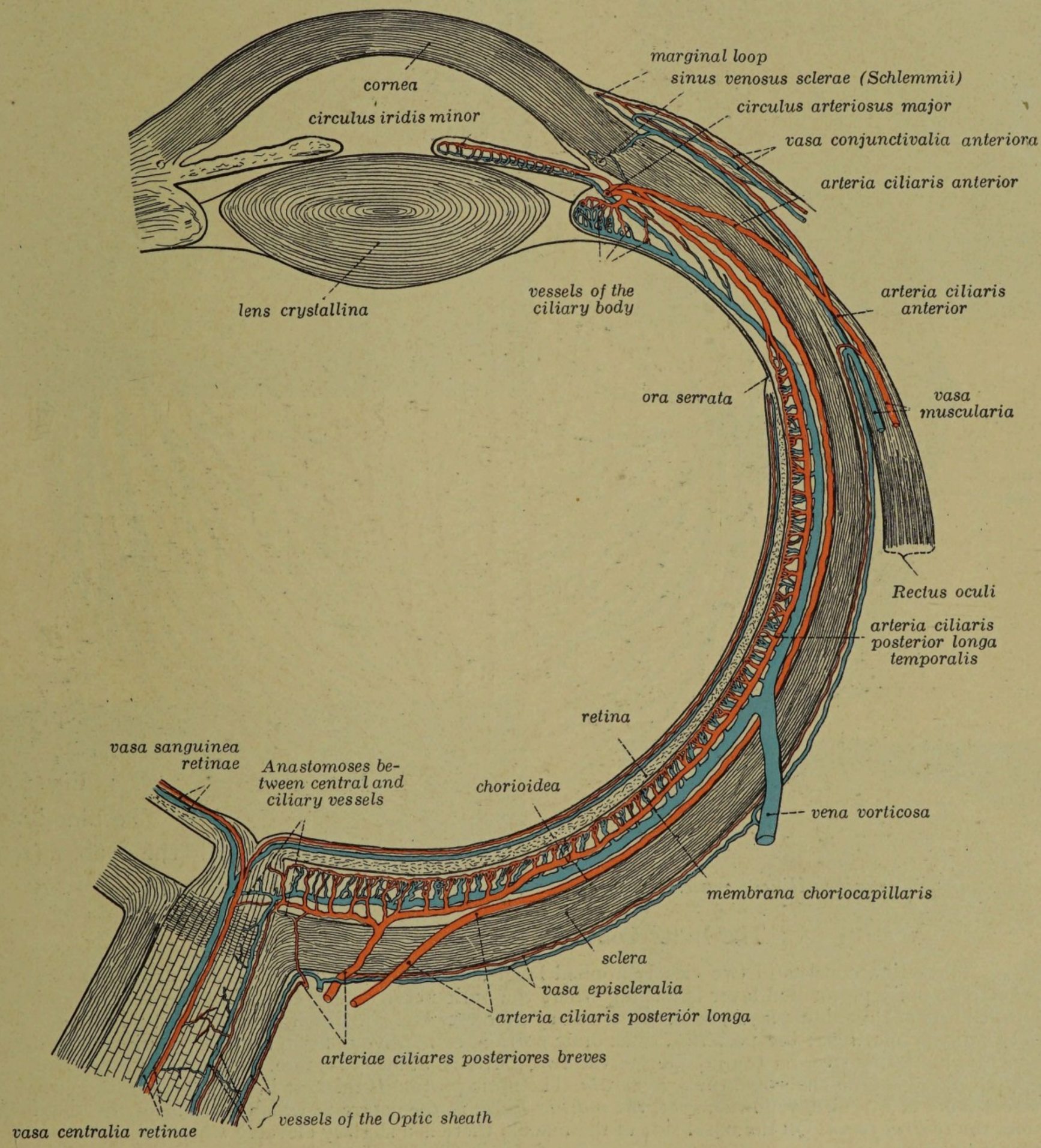

Fig. 248. The blood vessels of the eyeball, schematically represented after Th. Leber.

The Eye. The Eyeball. (Cont.)

Fig. 250. The lens of an adult, with numerous radii, from in front. ($^{10}/_{1}$)
Fig. 251. The lens, from the side. ($^{10}/_{1}$)
Fig. 252. The lens, divided at its equator, the capsule partly reflected. ($^{6}/_{1}$)
Fig. 253. The lens of a child, with three radii, from in front. ($^{10}/_{1}$)

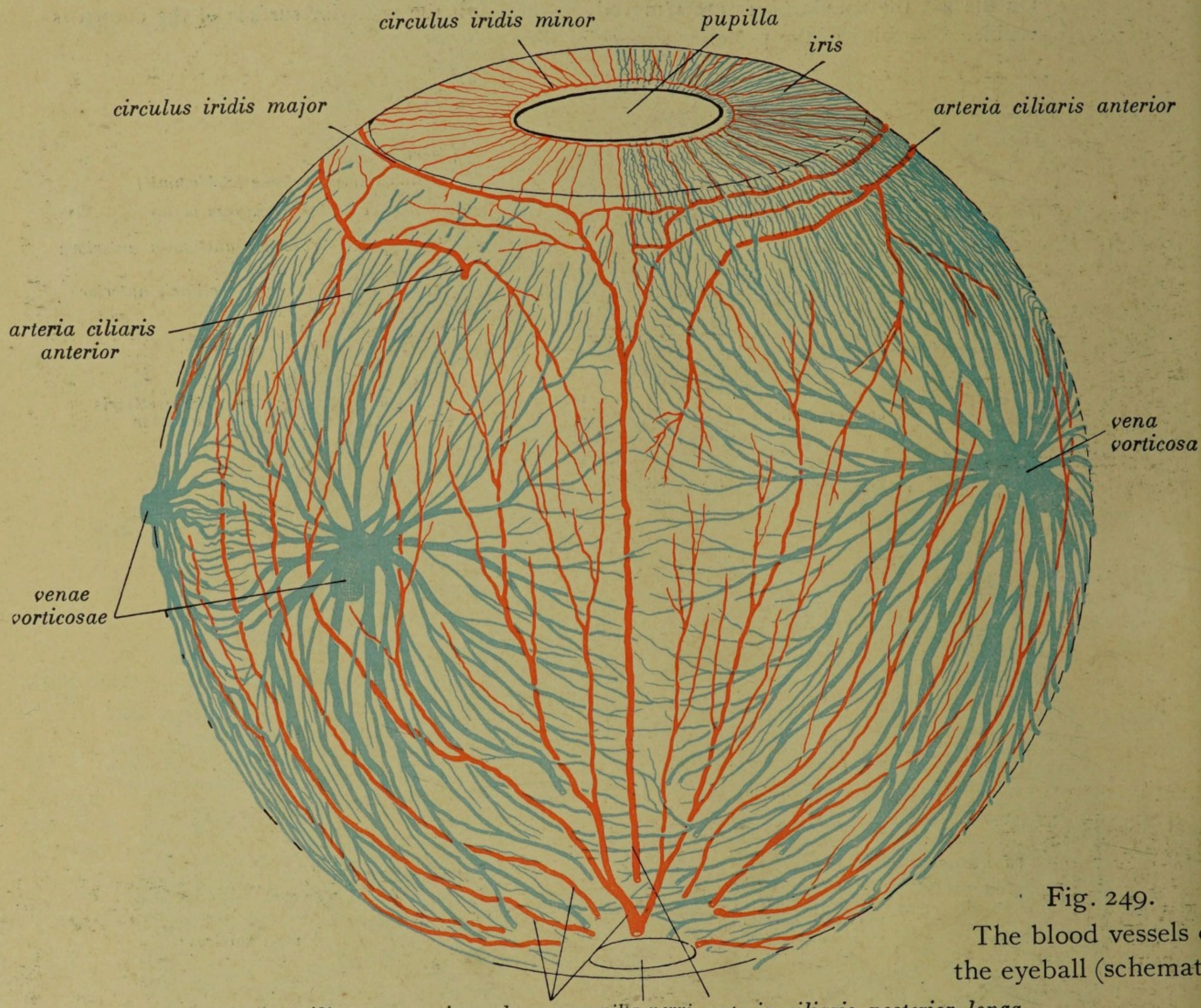

Fig. 249. The blood vessels of the eyeball (schematic).

The Inner Coat of the Eyeball. *The Retina.*

The retina consists of two closely applied layers, which pass into one another at the margin of the pupil. The outer pigmented layer is lacking where the optic nerve enters, elsewhere it is present and covers all the parts of the middle layer, such as the ciliary processes etc. The inner layer, the actual retina, consists of two distinct portions; the posterior, thick optic portion, responsive to light, and the anterior *caecal portion*, which is nonresponsive. At the junction of the two portions, about 3—4 mm. in front of the equator of the eyeball, there is a notched line, the *ora serrata*. The optic portion is thickest in the region of the visual axis, where there is a diffuse, yellowish spot, the *macula lutea*, at the centre of which is a sharply defined depression, the *central fovea*. On the nasal side of the macula there is a slightly elevated white circle, the *papilla* of the optic nerve.

The *caecal portion* consists of the *ciliary part*, covering the inner surface of the ciliary body, and the *iridic part*, covering the posterior surface of the iris; this portion is pigmented (see p. 248).



Fig. 250.

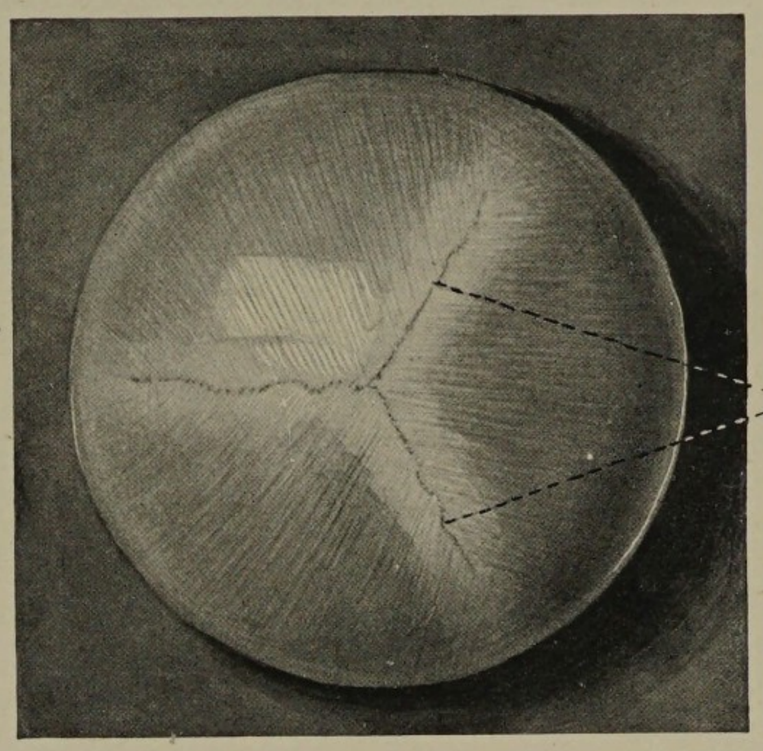

Fig. 253.

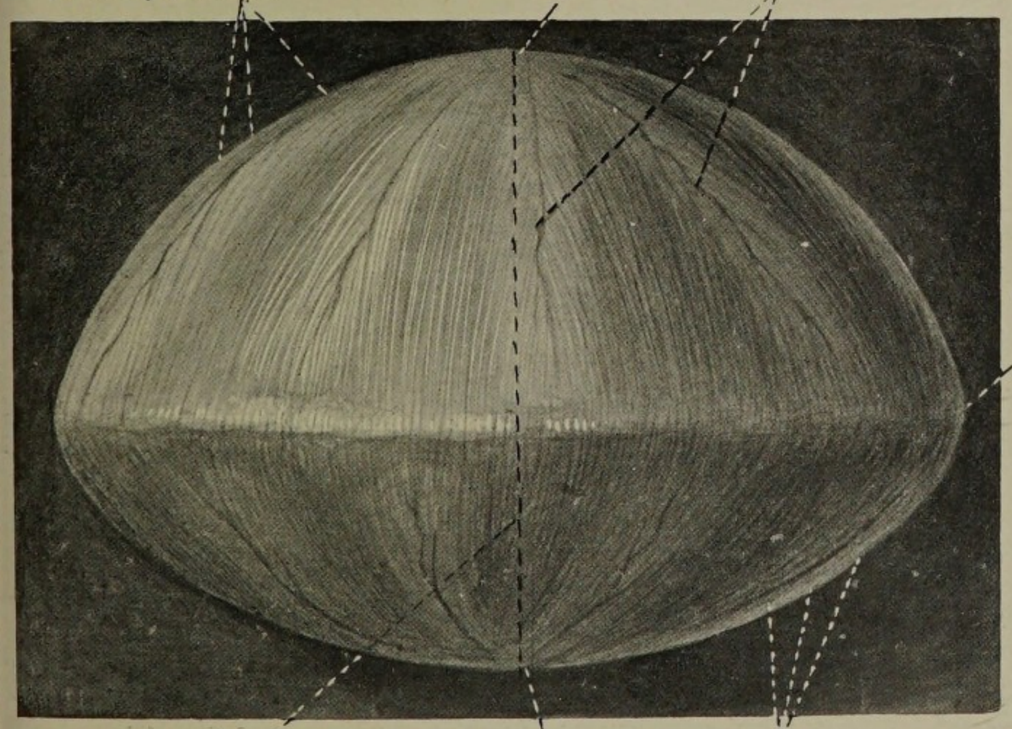

Fig. 251.

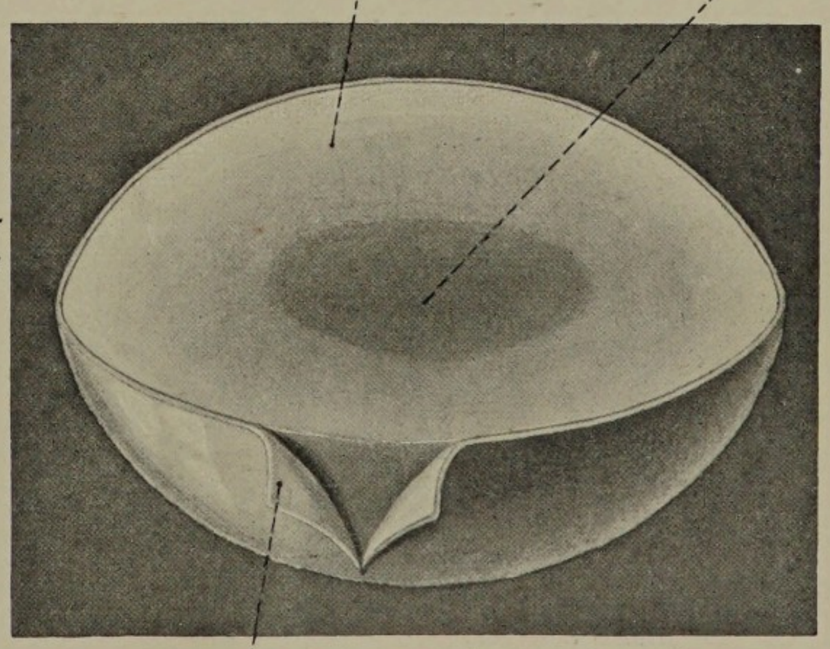

Fig. 252.

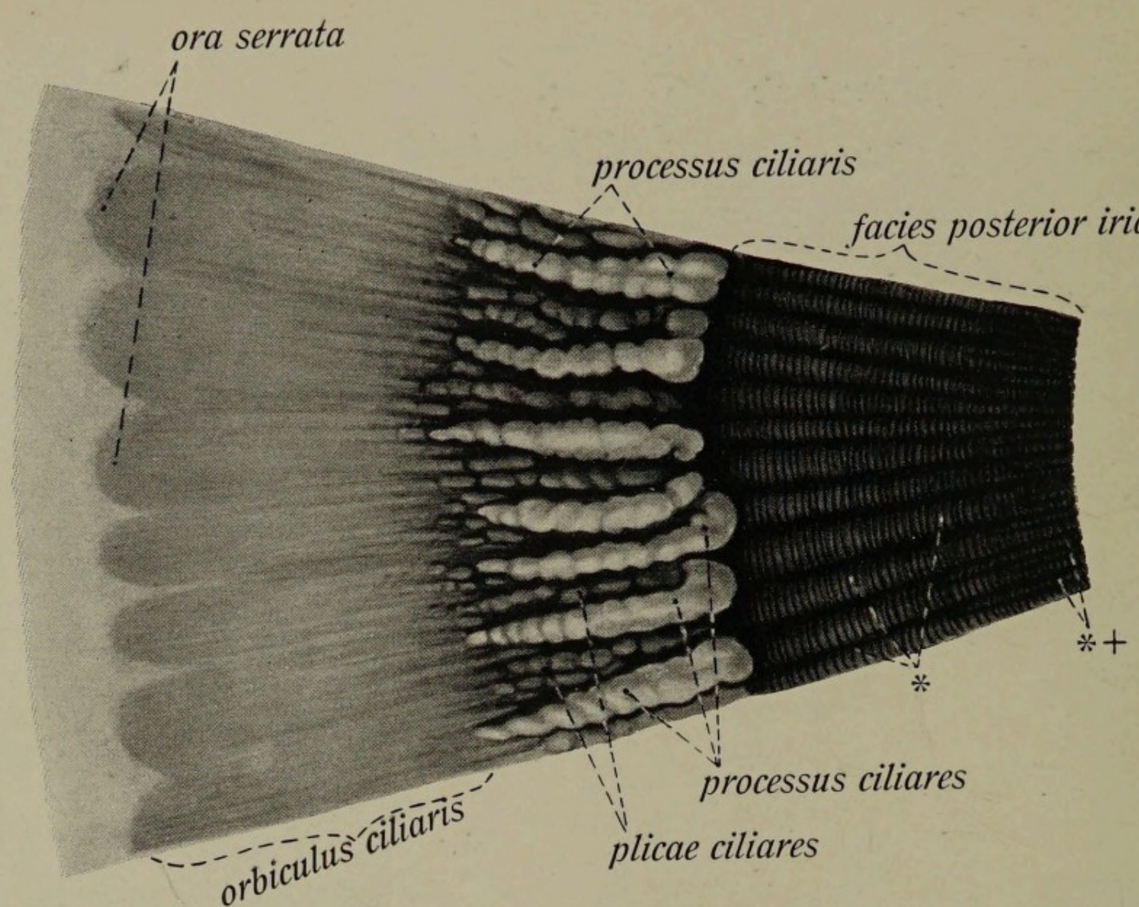

Fig. 254.

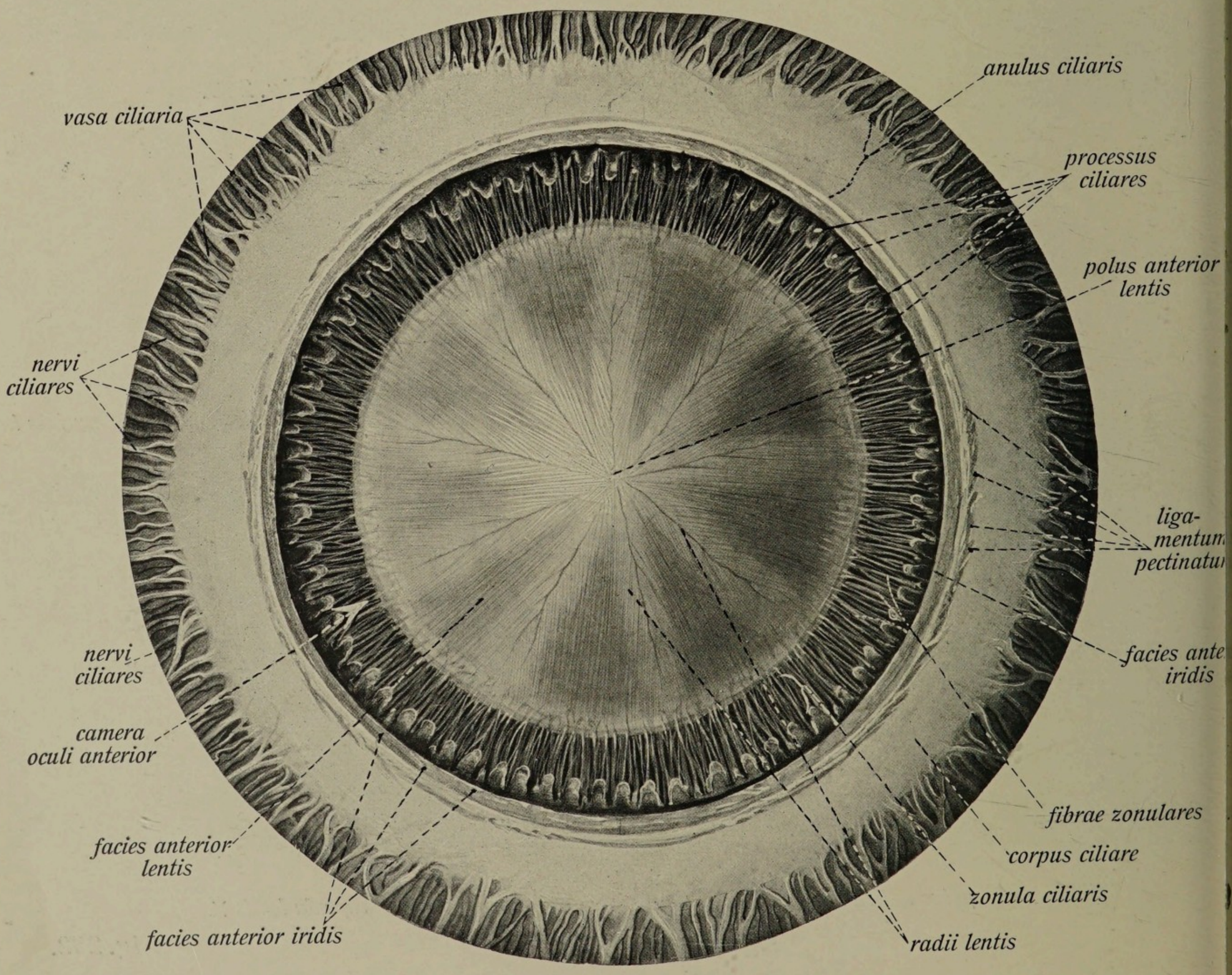

Fig. 255.

The Eye. The Eyeball. (Cont.)

Fig. 254. A sector of Fig. 247 more highly magnified. ($^{15}/_{1}$) On the left is the nasal part of the ora serrata; upon it is the orbiculus ciliaris, then the corona ciliaris with the ciliary processes and folds and, finally, the dark posterior surface of the iris.
* = coarser outer radiating folds. *+ = dense and fine inner radiating folds.

Fig. 255. The fibres of the ciliary zonule from in front. ($^{10}/_{1}$) The outer coat of the eye is completely removed and also the most of the iris. One sees the anterior ends of the ciliary processes and folds, with the zonular fibres passing to their insertion on the lens.

The Crystalline Lens.

The *crystalline lens* is a biconvex, transparent structure, placed behind the iris and closing the opening of the pupil. Its *anterior* surface is not so strongly convex as the *posterior*; the central points of the two surfaces are termed the *anterior* and *posterior poles*, and the line joining these the *axis* of the lens. The margin between the two surfaces is termed the equator and is usually distinctly notched, the notches corresponding to the bundles of the ciliary zonule which are here inserted.

The actual substance of the lens is enclosed within a homogeneous *capsule* and consists of the *nucleus* and *cortical substance*, not clearly separable and formed of *lens fibres*. The anterior and posterior ends of the lens fibres meet on both the anterior and posterior surface in a star-like figure, which is three rayed in young individuals, but in later life has several rays, the *radii lentis*.

The Vitreous Body.

The *vitreous body* fills the large cavity of the eyeball, situated behind the lens; it is spherical in form, but on its anterior surface where it is in contact with the lens it has a *hyaloid fossa*. It consists of a fluid *vitreous humor* contained in the meshes of a *vitreous stroma*, this latter condensing at the surface to form the *hyaloid membrane*, resting on the inner surface of the retina, but only artificially separable from the rest of the vitreous tissue.

The Ciliary Zonule.

The *ciliary zonule* is the circular suspensory apparatus of the lens and consists of very delicate, stiff fibres which take their origin from the entire breadth of the ciliary orbiculus and from the intervals between the ciliary processes. The fine fibres collect together to closely set bundles, which pass through the intervals between the ciliary processes to the lens, to whose equator they are attached, giving it its notched form.

The Eye. The Optic Nerve.

Fig. 257. A horizontal section through both orbits. (2/3) The section is somewhat oblique in its posterior part, so as to cut the entire length of the optic nerves.

Fig. 258. The two eyeballs and optic nerves of a child. (1/1) The orbits have been opened from above and their entire contents removed, except the eyeballs and the optic nerves.

The Optic Nerve.

The optic nerve passes through the optic foramen above and medial to the ophthalmic artery. It then comes to lie in the axis of the muscle cone, surrounded by the oblique origins of the recti and their tendinous ring, and passes, surrounded by the fat tissue of the orbit, to the medial (nasal) part of the posterior portion of the eyeball. In the orbit it

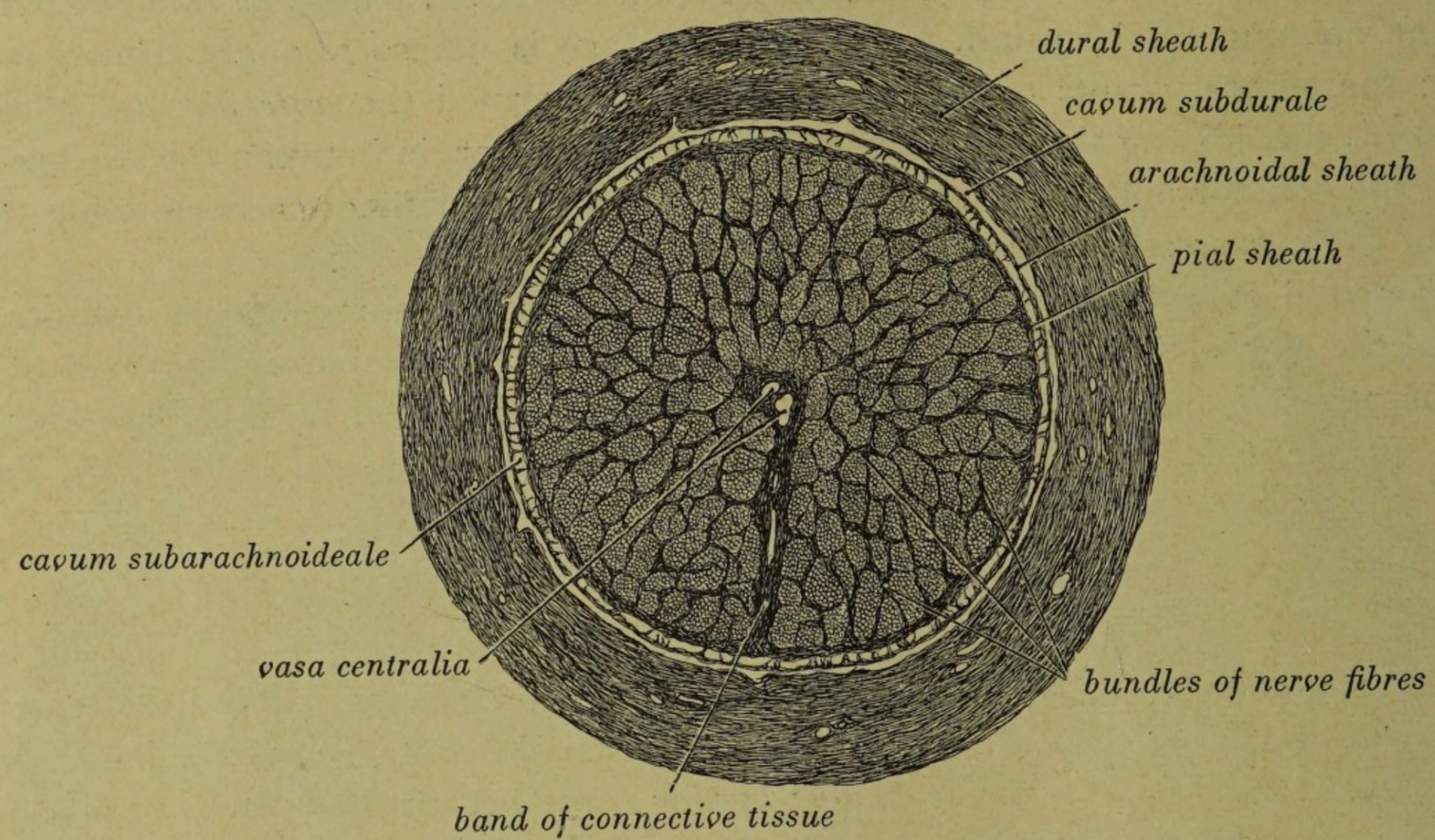

Fig. 256. Transverse section of the optic nerve.

makes a flat S-shaped curve in the horizontal plane, in that it bends first laterally and then returns to the axis of the muscle cone, to make a second very short bend laterally just before entering the eyeball. At about 10—12 mm. from the eyeball the *central retinal vessels* pass into the nerve from below, and run in its axis to the papilla of the optic nerve. As they enter the lamina cribrosa of the sclerotic the nerve fibres lose their medullary sheaths, so that the nerve becomes decidedly thinner and the extremity of the nerve at the optic papilla seems much diminished in size.

The investments of the optic nerve, which are the direct continuations of the brain membranes, are termed its sheath (*vagina*). Inside the skull cavity the nerve is enclosed in pia only, the so-called pial sheath; at the optic foramen the central dura mater is directly continued upon the nerve forming its dural sheath. Between these two the cerebral arachnoid extends upon the nerve forming its arachnoidal sheath. The cleft-like intervaginal spaces between the sheaths of the nerve correspond to the cavities between the cranial meninges and are in direct connection with them (the subdural and subarachnoid cavities).

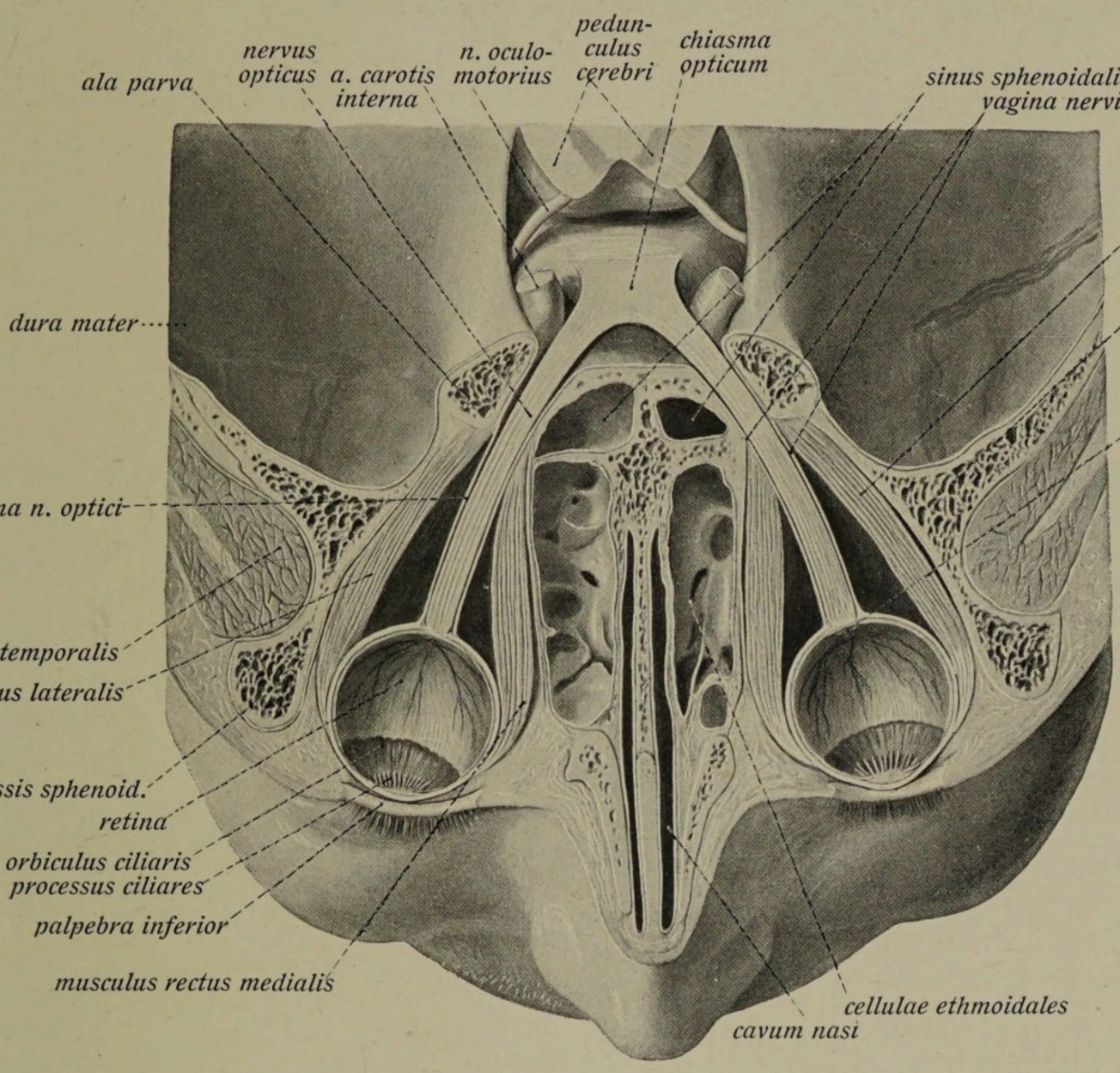

Fig. 257.

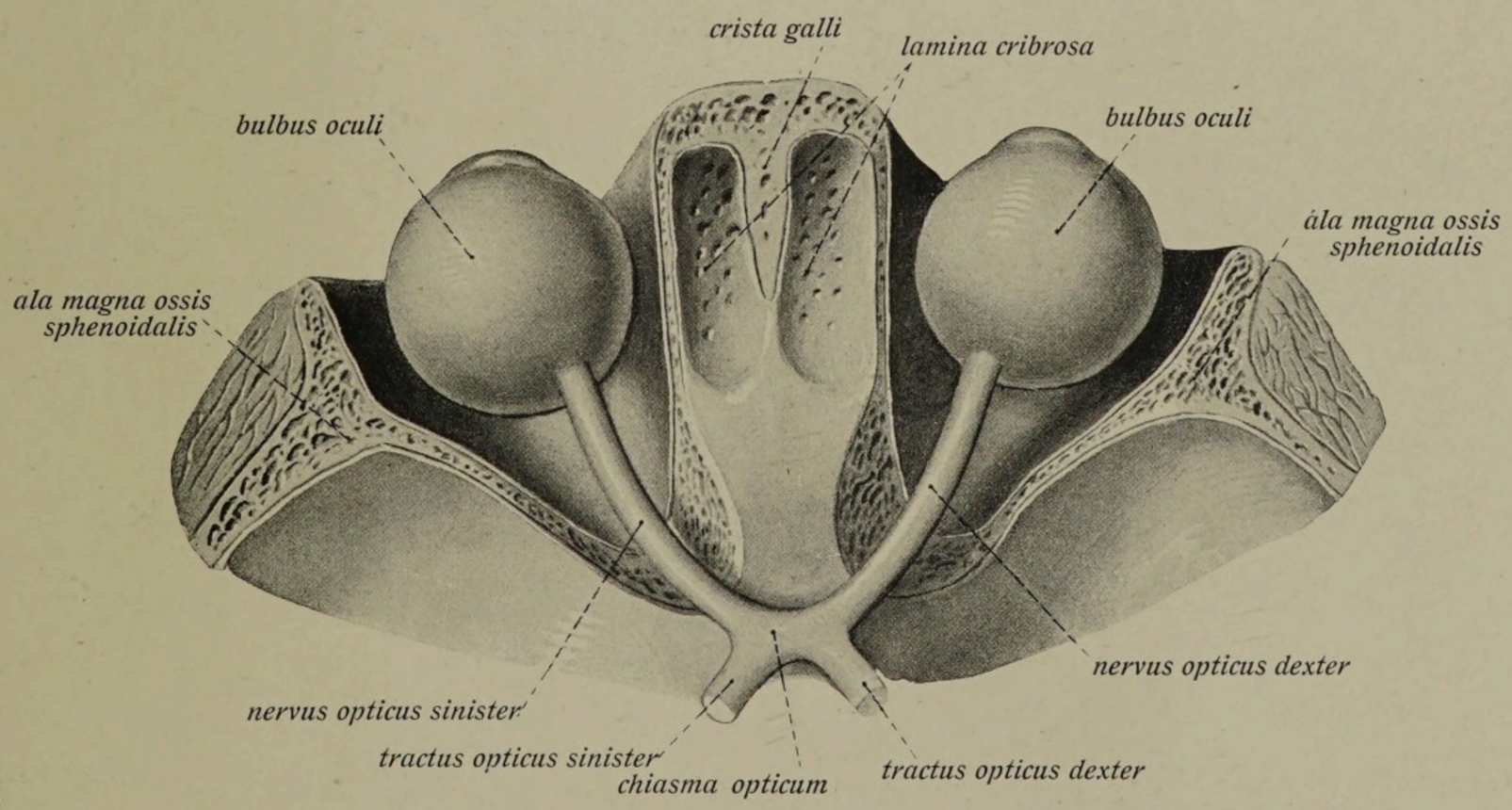

Fig. 258.

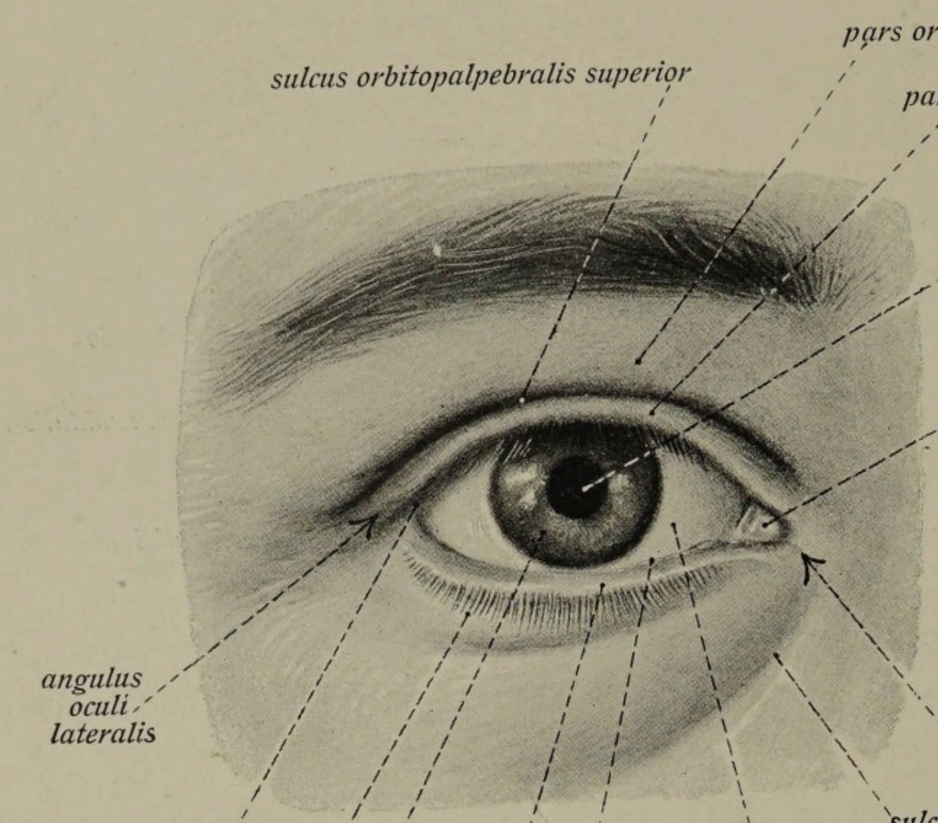

Fig. 259.

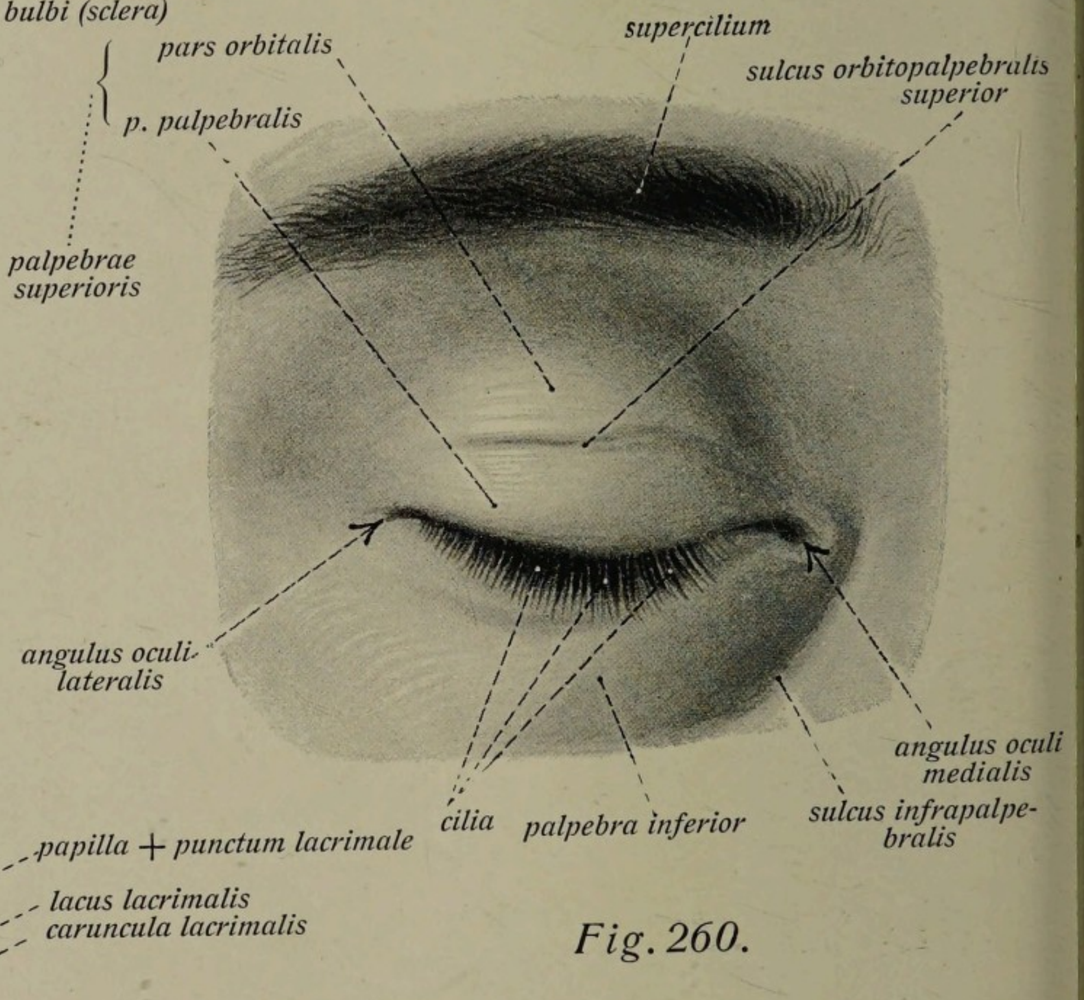

Fig. 260.

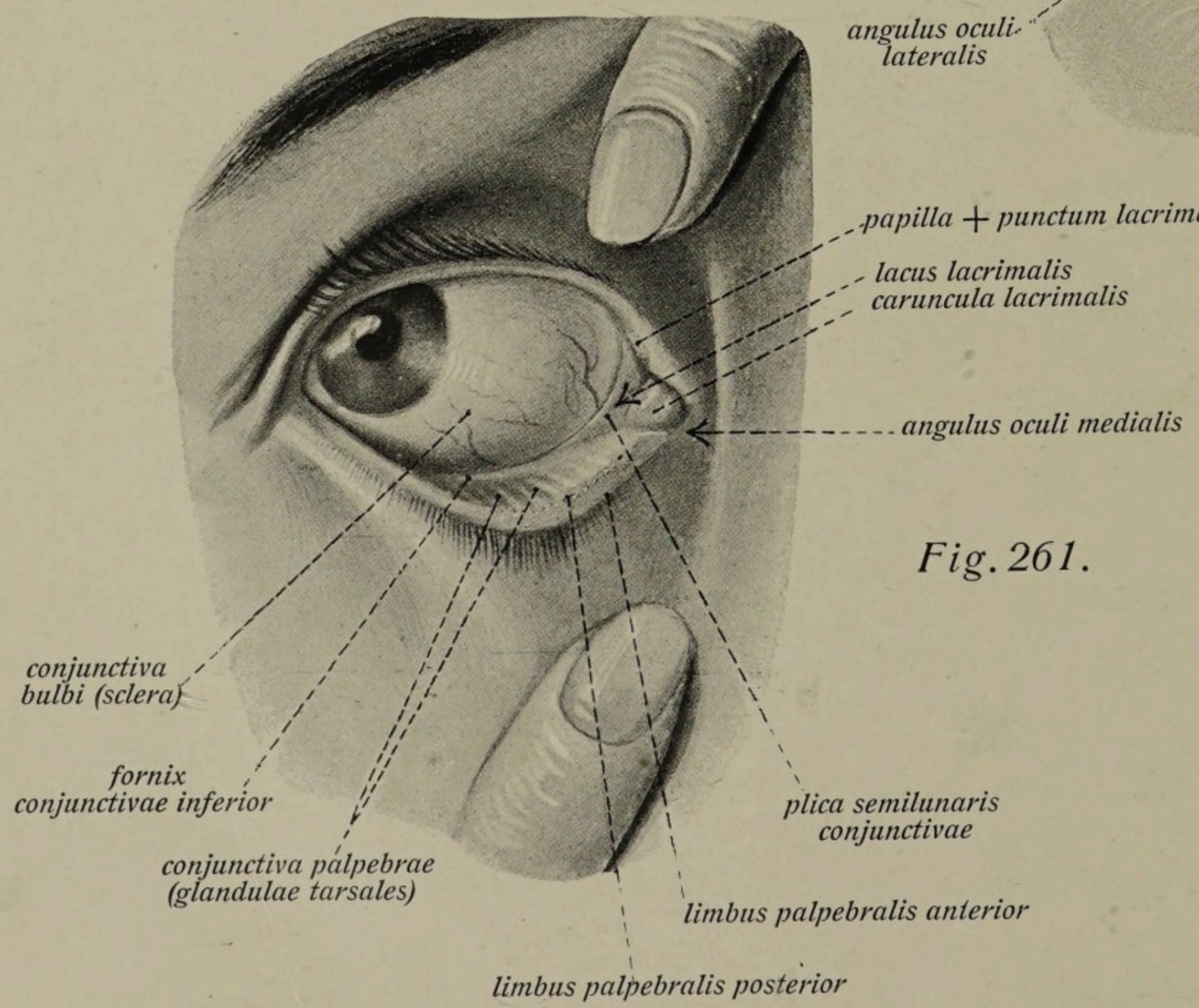

Fig. 261.

The Eye. The Conjunctiva and the Lids.

Fig. 259. The right eye, open, from in front. (1/1)
Fig. 260. The right eye, closed. (1/1)
Fig. 261. The right eye fully opened by forcible separation of the lids, from the temporal side and above. (1/1)

The Conjunctiva.

The *conjunctiva* is a mucous membrane, directly continuous with the external skin and lining the conjunctival sac. It consists of the *palpebral* and *bulbar conjunctivae*, which pass into one another at the base of the eyelids, forming in the upper lid the *superior* and in the lower lid the *inferior conjunctival fornix*. The *palpebral conjunctiva* covers the niner surface of the eyelid as a smooth membrane, equal in extent to the tarsus (see below) with which it is fused.

The *bulbar conjunctiva* extends from the conjunctival fornix to the margin of the cornea where it ends in the *conjunctival limbus*. At the inner angle of the eye it forms a *semilunar fold*, concave laterally, which forms one of the boundaries of the lacus lacrimalis (see below and Fig. 267).

The Eyelids, *palpebrae*.

The two eyelids, the broader upper lid and the narrower lower one, are two folds of skin stretched across the outer opening of the orbit. They have a distinctly concave *posterior surface* and a convex *anterior surface*, and bound by their free edges the almost horizontal *rima palpebrarum*, in such a way as to form at their medial and lateral ends the *medial* and *lateral palpebral commissures*. Thus is formed the sharply angled and somewhat higher *lateral angle* of the eye and the rounded, lower *medial angle*. The upper lid with a distinctly convex border meets the lower one which has an almost straight and but slightly concave border, in the rima palpebrarum. A strong transverse fold, the *orbito-palpebral sulcus*, is formed at the base of each lid when it is opened. The free edges that bound the rima palpebrarum are not mere edges, but narrow surfaces, each divisible into the blunt *anterior limbus* and the sharper *posterior limbus*, the former bearing 2—3 rows of strong hairs, the eyelashes *(cilia)*.

The *lacus lacrimalis* is the name given to the region of the medial angle of the eye bounded by the medial portions of the two eyelids and the *semilunar fold* of the conjunctiva. On its floor there is a low, reddish elevation, with sebaceous glands and fine hair follicles, the *lacrimal caruncle*.

The Eye. The Eyelids and Lacrimal Apparatus.

Fig. 263. The orbital septum of the right eye from in front. (1/1)
The external skin and the Orbicularis oculi have been removed.
Fig. 264. The eyelids and lacrimal glands from behind. (1/1)

The Eyelids, *palpebrae*. (Cont.)

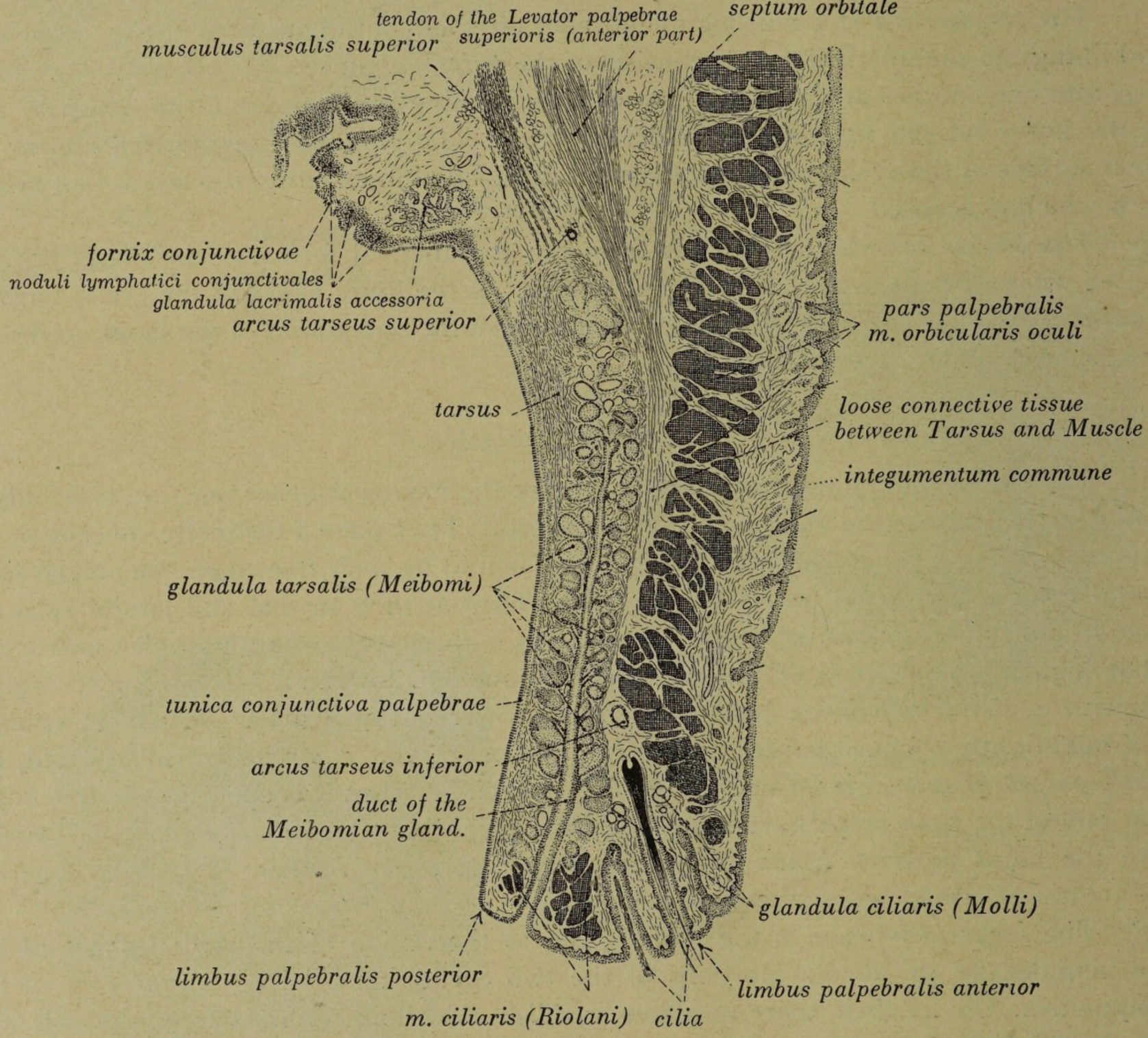

Fig. 262. Vertical section through the upper eyelid. (15/1)

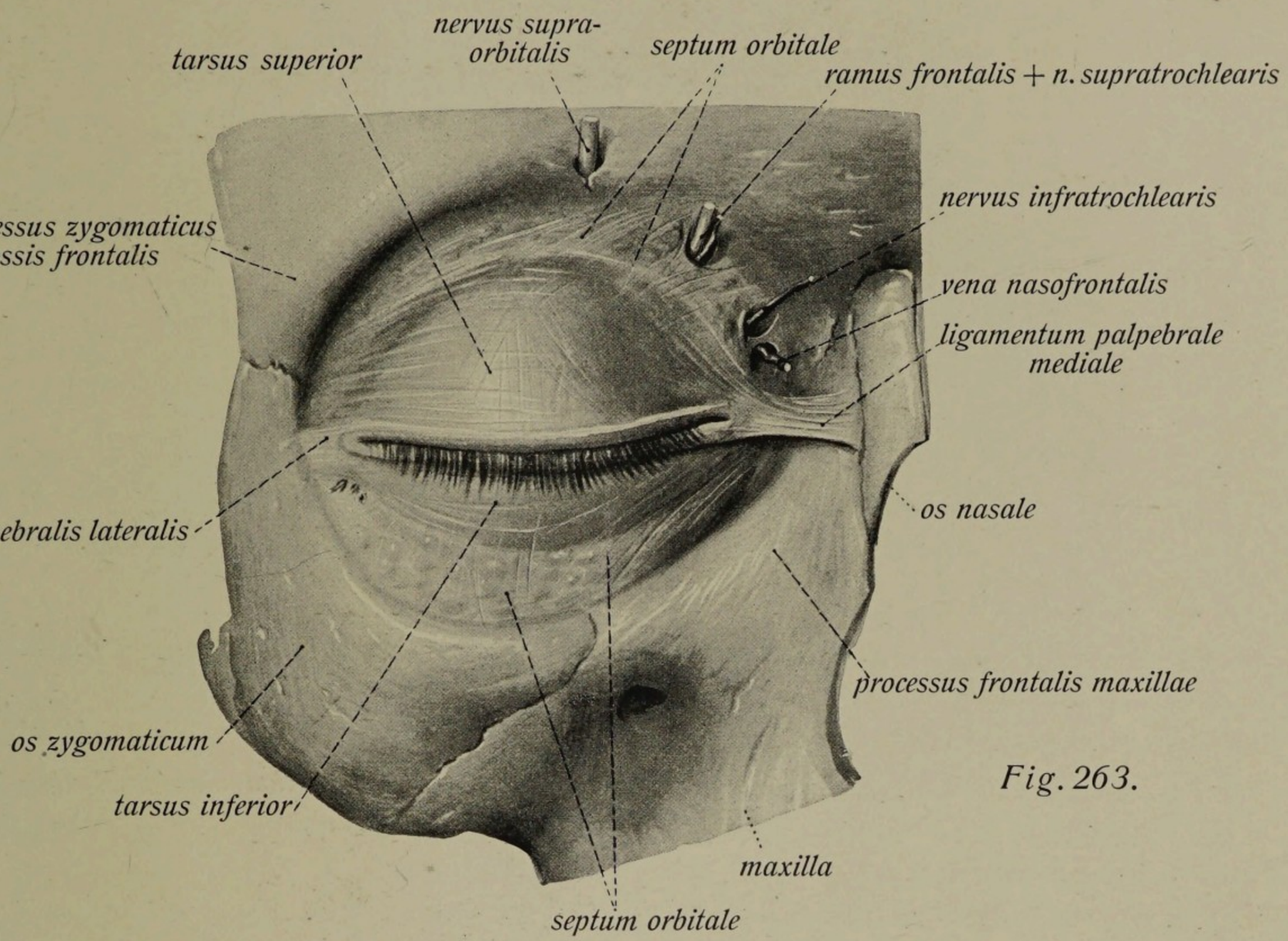

Fig. 263.

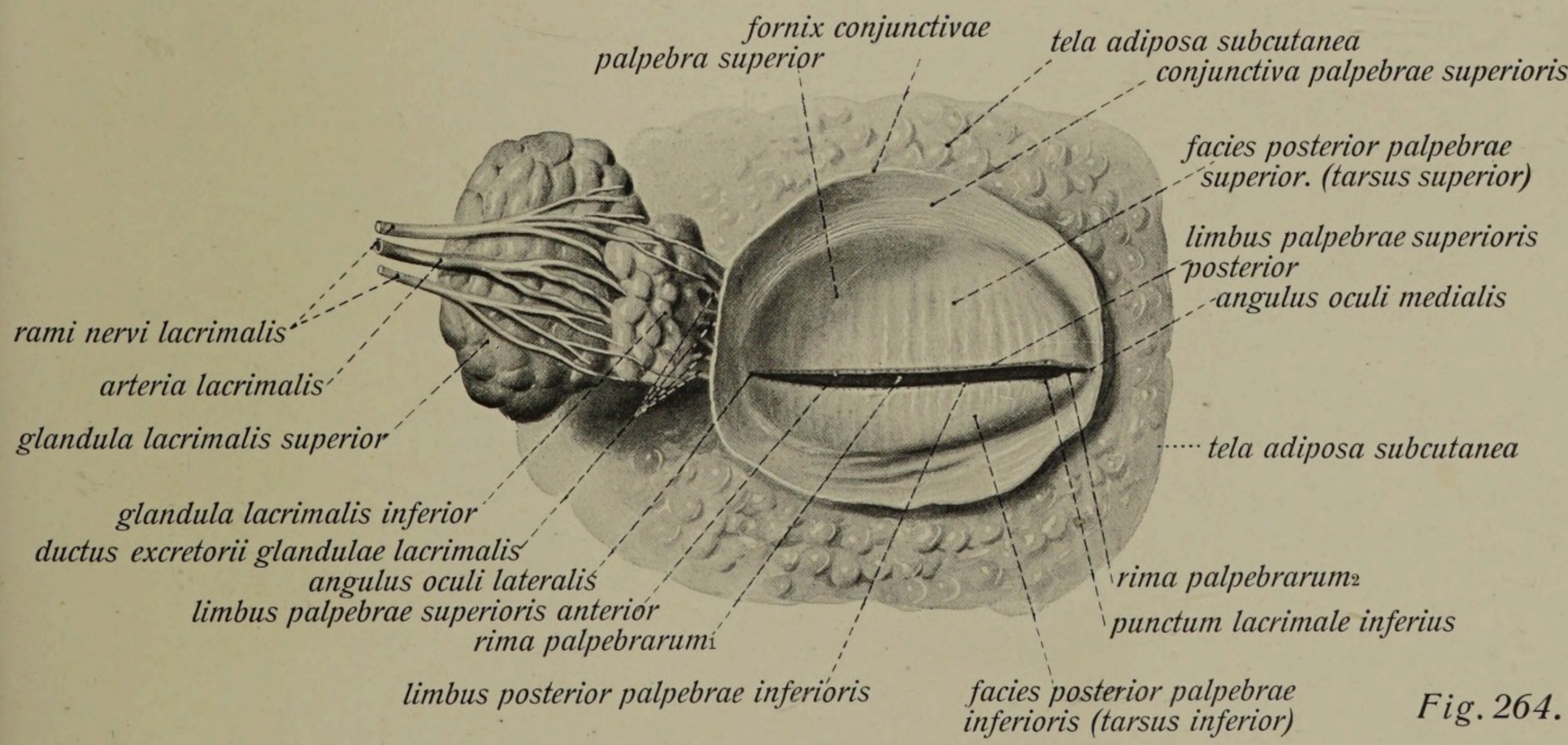

Fig. 264.



Fig. 265.

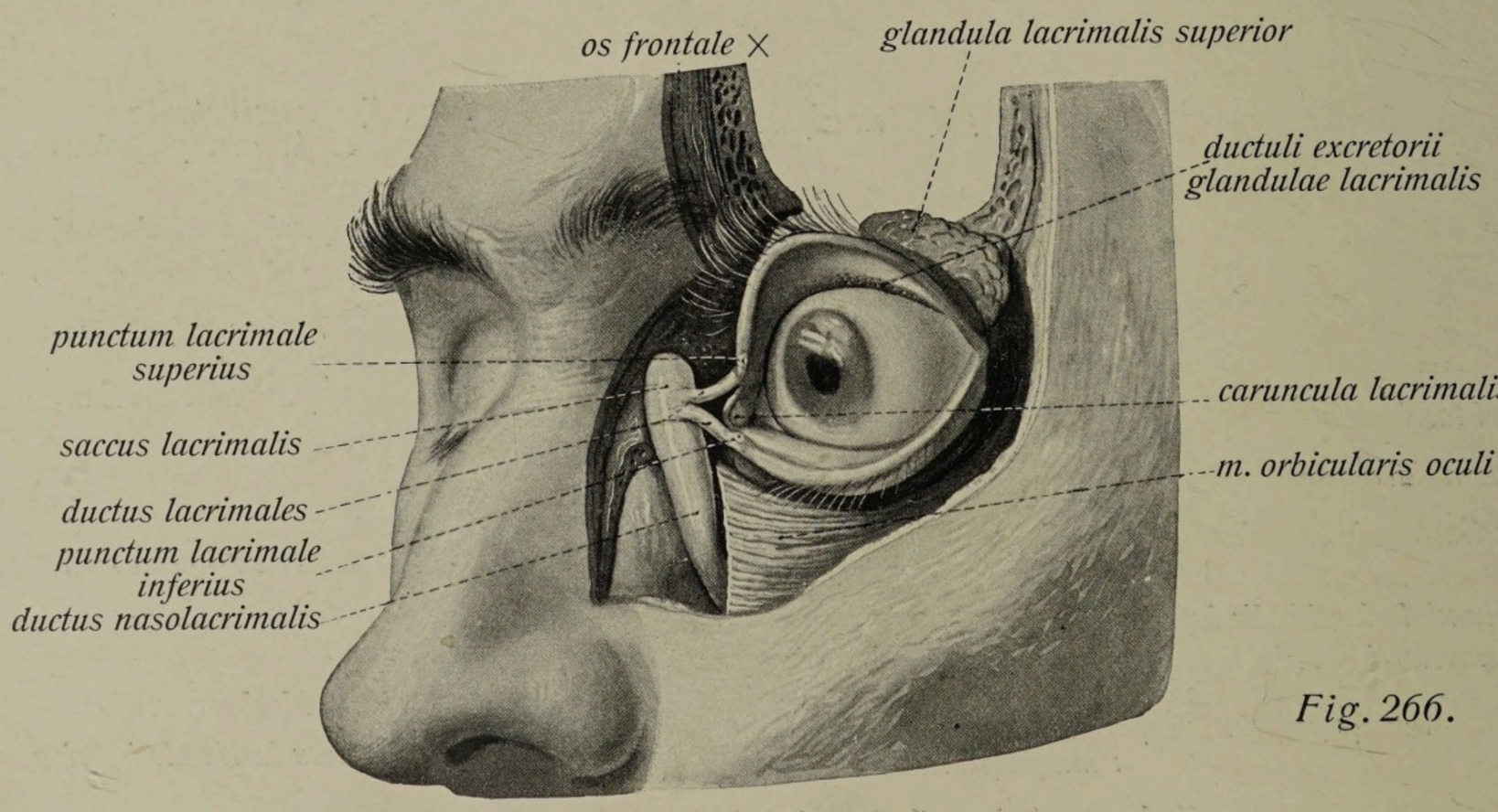

Fig. 266.

Fig. 265. The two eyelids from the posterior surface, made transparent by soda-glycerine; Meibomian glands (from O. Schultze, Topographische Anatomie). ($^4/_1$)

Fig. 266. General view of the entire lacrimal apparatus (from O. Schultze, Topographische Anatomie). ($^2/_3$)
A piece is sawed from the frontal bone to expose the upper lacrimal gland; similarly a part of the frontal process of the maxilla and the medial palpebral ligament are removed to expose the lacrimal sac and the upper part of the nasolacrimal duct.

The Eyelids, *palpebrae*. (Cont.)

The support of each eyelid is a cartilage-like plate of connective tissue, the *tarsus* (see Fig. 284), which is curved in correspondence to the lids. Its form is in general that of the lid, and consequently the higher upper lid has a higher tarsus than the lower. The greatest height of the superior tarsus is at the middle of the breadth of the lid. Both tarsi have an irregular semilunar shape; the medial end is broader than the lateral. One edge of the tarsus is close to the free edge of the eyelid, but the other edge does not extend to the base of the lid but is some distance from it and sharply marked off from the neighboring tissue.

The tarsus of both the upper and the lower eyelid is traversed throughout its entire height by the *tarsal (Meibomian) glands*, which lie in a single layer, parallel to one another, their ducts opening at slight intervals from one another along the posterior palpebral limbus.

At the angles of the eyelids the tarsi are also connected with the *medial palpebral ligament* and the *lateral palpebral raphe*. The former is a tendinous arch attached to the frontal process of the maxilla, and its anterior limb extends transversely over the anterior surface of the lacrimal sac, while the broader posterior limb passes behind the lacrimal sac to the posterior lacrimal crest. It interlaces with the orbital septum (see p. 275) and serves for the fixation of the medial angle. The *lateral palpebral raphe* is not an actual ligament, but a strip of tendinous tissue that interlaces with the fibres of the Orbicularis oculi and with the orbital septum. The musculature of the eyelids is formed by the *palpebral portion* of the *Orbicularis oculi*, whose fibres arch around the rima palpebralis and spread out between the external skin and the anterior surface of the tarsi. The bundles nearest the free edge of the lid, separated from the rest of the muscle by the roots of the eyelashes (cilia), form what is termed the *ciliary muscle* (Riolan's).

Fig. 267. The lacrimal sac and the lacrimal ducts from in front. (1/1) The skin and musculature is divided and partly removed, partly reflected. The medial palpebral ligament is cut.

Fig. 268. The lacrimal ducts, lacrimal sac and naso-lacrimal duct opened, from in front and from the side. (1/1) Preparation as in Fig. 267, but a piece of the maxilla has been chiselled away to expose the naso-lacrimal duct.

The Lacrimal Apparatus.

The *superior lacrimal gland* lies in the lacrimal groove of the frontal bone, close under the periorbita and with its long axis parallel to the margin of the orbit. The surface turned toward the bone is distinctly convex, that turned toward the eyeball concave. The *inferior lacrimal gland* is only about one-third as large as the superior and lies below it, close to the conjunctival fornix of the lateral angle of the eye. In contrast to the superior one, it consists of only loosely connected, sometimes completely separated, lobules, and its ducts, as well as those of the superior gland, open on the lateral portion of the conjunctival fornix. The number of the ducts of both glands is 10—15.

The *lacrimal ducts* begin at the *puncta lacrimalia* on the edges of the upper and lower eyelids, near the medial commissure of the lids, between this and the medial ends of the tarsi. There is a *superior* and an *inferior punctum*, situated on small, low elevations, the *lacrimal papillae*, on the edges of the eyelids. The lacrimal ducts themselves are very narrow and thin-walled arched canals, situated in the medial portion of the eyelids and running parallel to the boundaries of the lacus lacrimalis. The first part of each runs vertically from its punctum lacrimale, and then follows a bend almost into a transverse direction and at the bend there is an enlargement, the *ampulla*. The two lacrimal ducts open close together, rarely by means of a common terminal part, into the lateral wall of the lacrimal sac.

The *lacrimal sac* is the upper, blind end of the naso-lacrimal duct, which is here moderately or not at all enlarged. It lies in the lacrimal fossa at the medial angle of the orbit; its upper, somewhat smaller, blind end is termed the *fornix* of the lacrimal sac. About 1.5—2 mm. below the apex of the fornix the two lacrimal ducts open on a slight evagination of the lateral wall. Above the sac is stretched the medial palpebral ligament, and it, as well as the lacrimal ducts, is also surrounded by the fibres of the *lacrimal portion* (Horner's muscle) of the Orbicularis oculi. Below, the lacrimal sac is directly continued into the bony canal in which it lies. Like this it opens into the anterior part of the inferior meatus of the nose in such a way, that the duct passes for some distance obliquely through the nasal mucous membrane forming the *lacrimal* (Hasner's) *fold*.

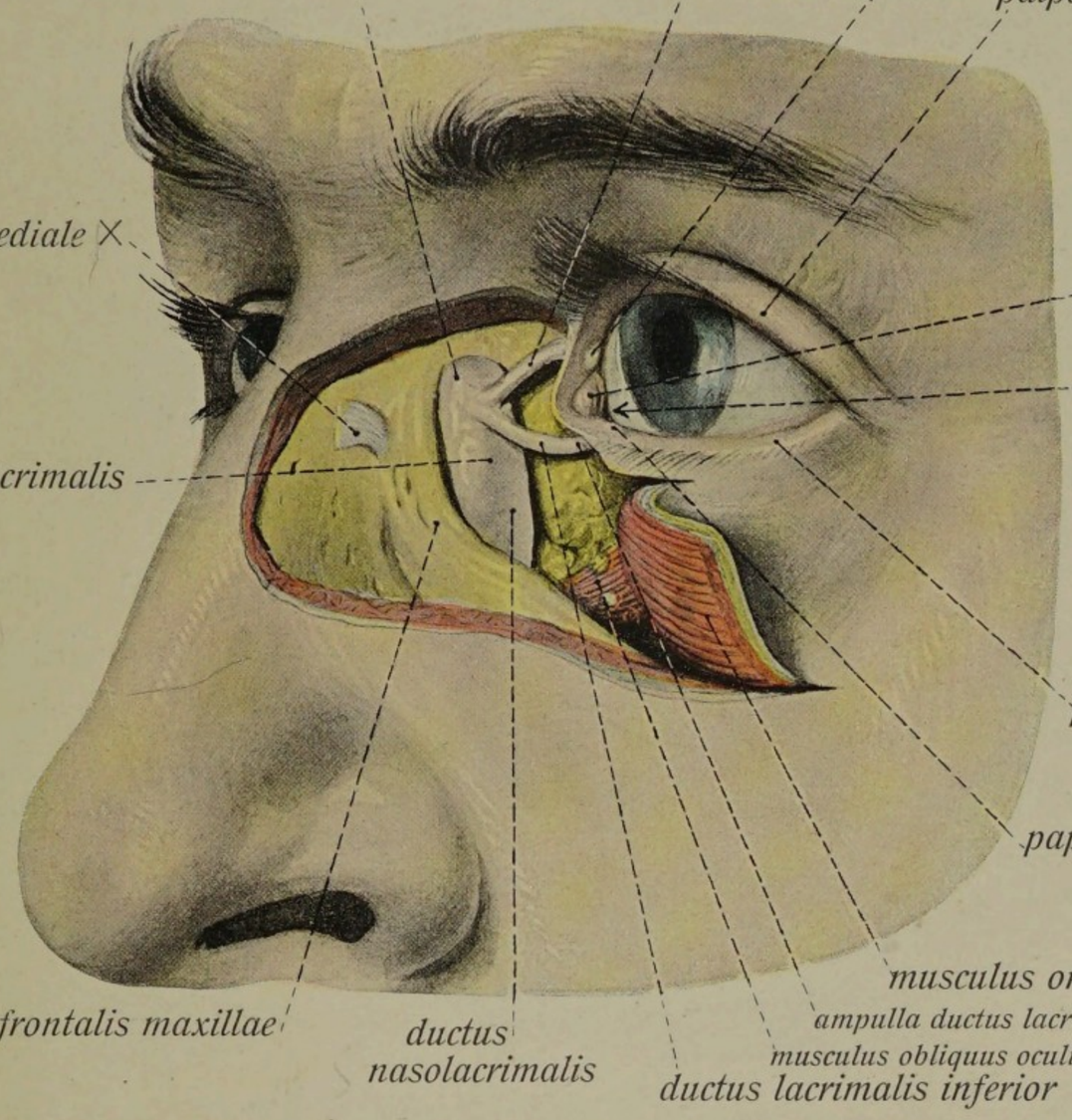

Fig. 267.

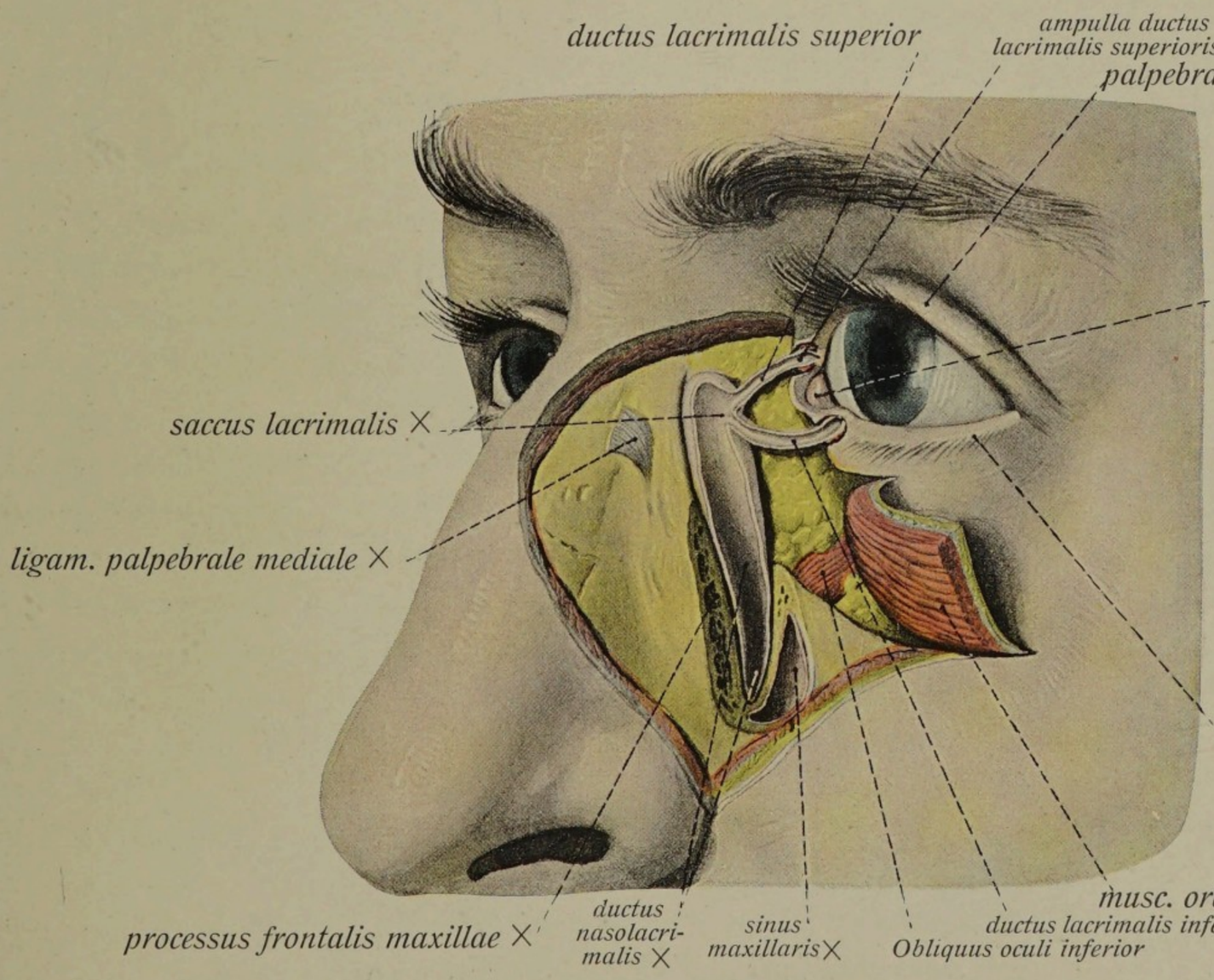

Fig. 268.

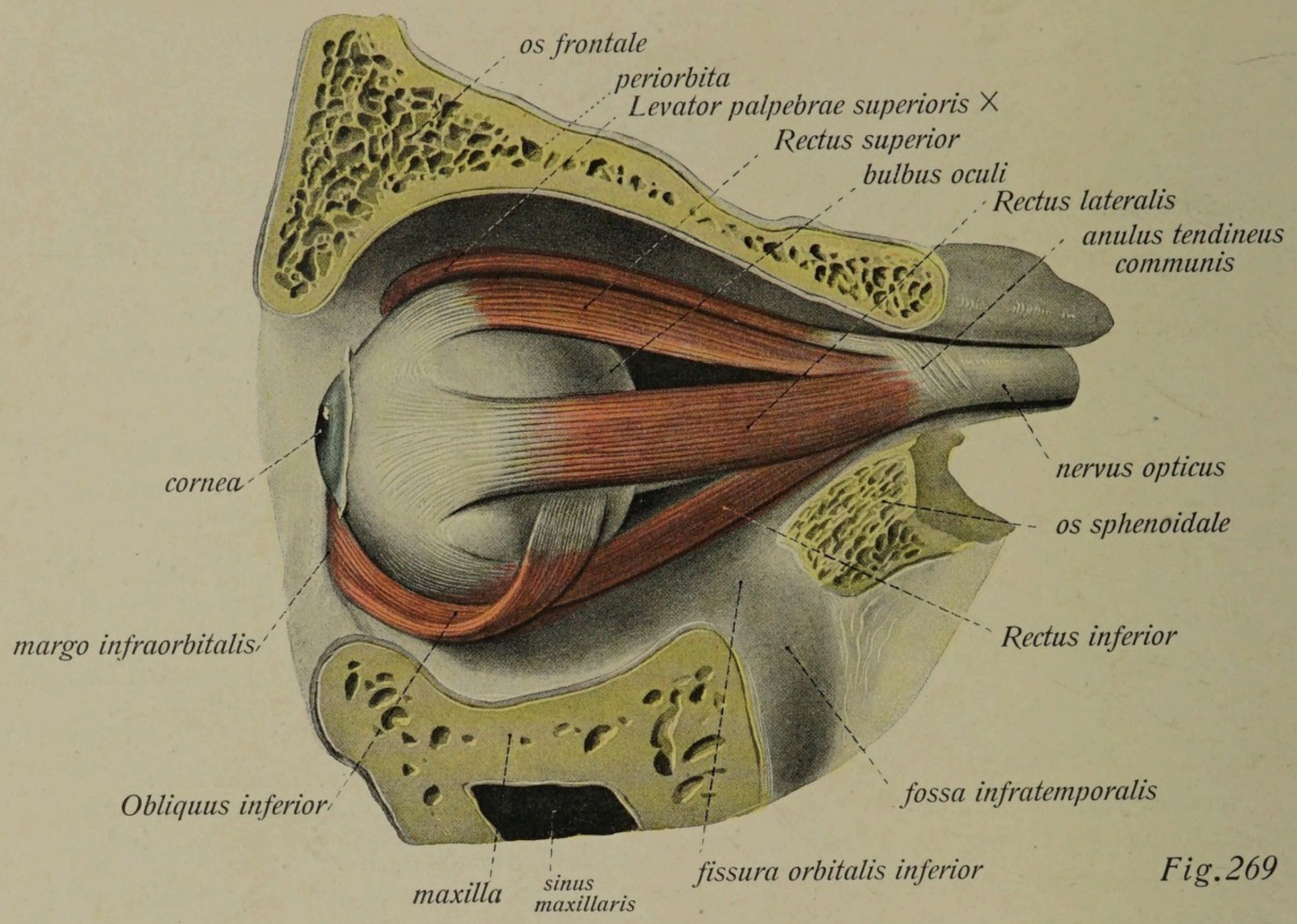

Fig. 269

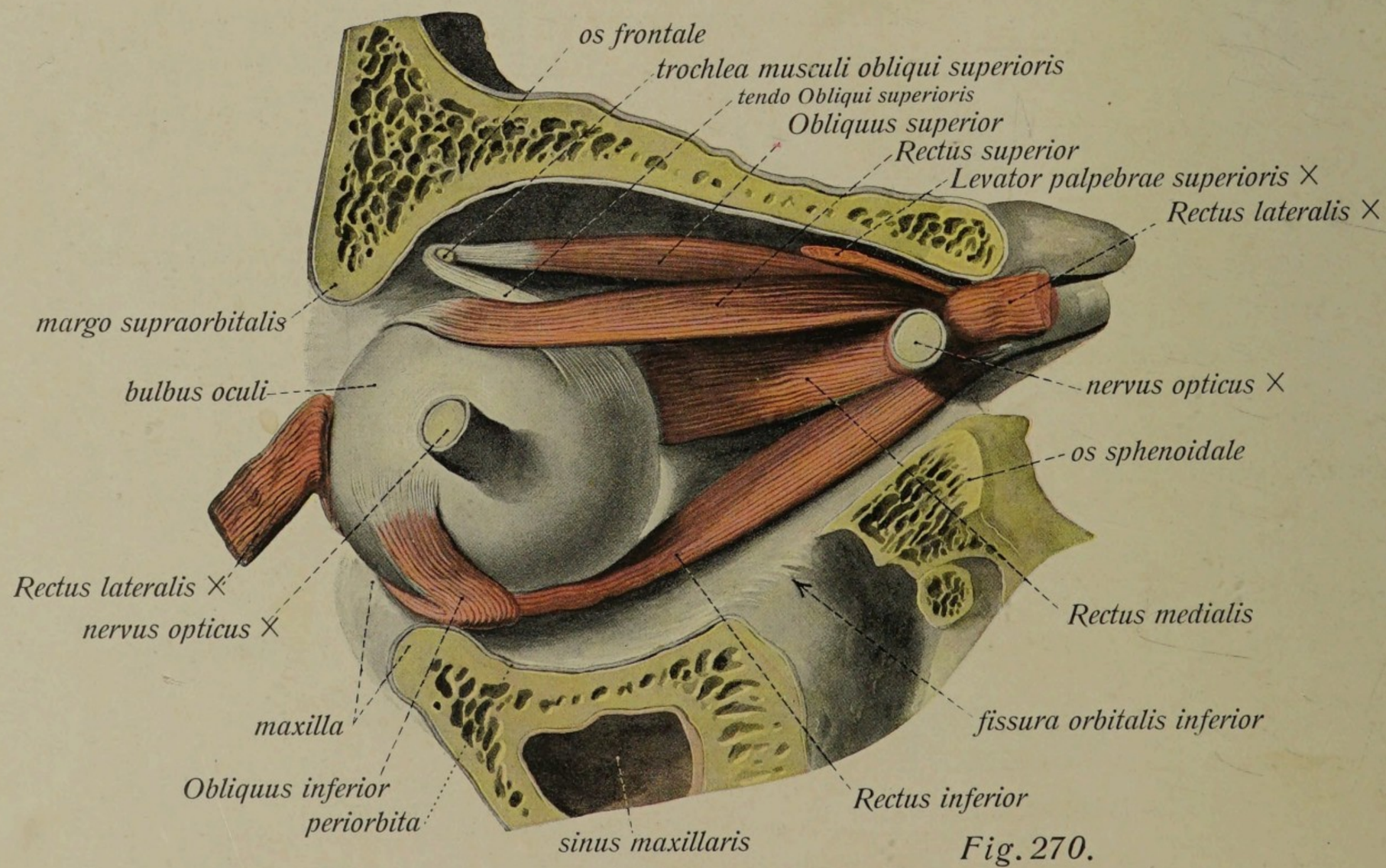

Fig. 270.

The Eye. The Muscles of the Eye.

Fig. 269. The muscles of the eye from the lateral side (somewhat enlarged).
The lateral wall of the orbit is cut away and the other contents, together with the fascia and eyelids are removed. The Levator palpebrae superioris is in large part retained.

Fig. 270. The muscles of the eye from the lateral side (somewhat enlarged).
Preparation as in Fig. 269, but the Rectus lateralis and the optic nerve are cut. The eyeball is rotated so that its lower pole with the stump of the optic nerve is directed laterally. The Levator palpebrae superioris is largely removed.

The Muscles of the Eye.

The movements of the eyeball are produced by six muscles, four of which are termed the *recti*, and two the *obliqui*. The four recti have much in common; they are long, flat muscles, becoming broader in front and narrower behind, have a straight course and end in short, flat tendons, about a centimeter in width, which insert at regular intervals from one another into the sclerotic, in front of the equator of the eyeball and behind the sclero-corneal junction. The two obliqui do not resemble one another so closely, but have this in common, that they run obliquely and their tendons are inserted behind the equator of the eyeball. Five of the six muscles have a common origin at the optic foramen by short tendons from a *tendinous ring* (Zinnii) which surrounds the optic nerve.

The *Rectus superior* is the weakest and thinnest of all, and runs with the Levator palpebrae superioris (see p. 272), largely covered by this and partly in close contact with it, above the upper surface of the optic nerve and the upper quadrant of the eyeball to in front of the equator. The lateral part of its tendon remains farther from the margin of the cornea than does the middle part, this reaching almost to the cornea.

The *Rectus medialis* is the strongest of all the eye muscles, but is shorter than the Rectus superior so far as its fleshy portion is concerned and has a very short tendon, the shortest of all. It is inserted nearest to the margin of the cornea in an almost latitudinal line. It lies in the sagittal plane.

The *Rectus lateralis* is not placed quite sagittally as is the medial, but inclines temporalwards from this plane. Although it inserts farther away from the margin of the cornea than does the medial, it is necessarily longer than this on account of the convergence of the axes of the orbit posteriorly. The greater length is given, however, solely by the length of the tendon, the fleshy part being, indeed, shorter. The insertion of the tendon is on a latitudinal line, which is much farther away from the corneal margin than is that of the medialis. The muscle arises like the others, chiefly from the tendinous ring, but with a small head *(lacertus)* from the spine on the border of the superior orbital fissure.

The Eye. The Muscles of the Eye. (Cont.)

Fig. 273. The muscles of the eye from in front and from the side. The skin, eyelids and fascia are removed. In addition to the eyeball and the muscles, only the superior lacrimal gland and a portion of the orbital fat are retained.

Fig. 274. The eyeball with stumps of the eye muscles, from in front.

Fig. 275. The eyeball with stumps of the eye muscles, from behind and below.

Fig. 276. The eyeball with stumps of the eye muscles, from behind and above.

All four figures (p. 269) are about one-third larger than natural size.

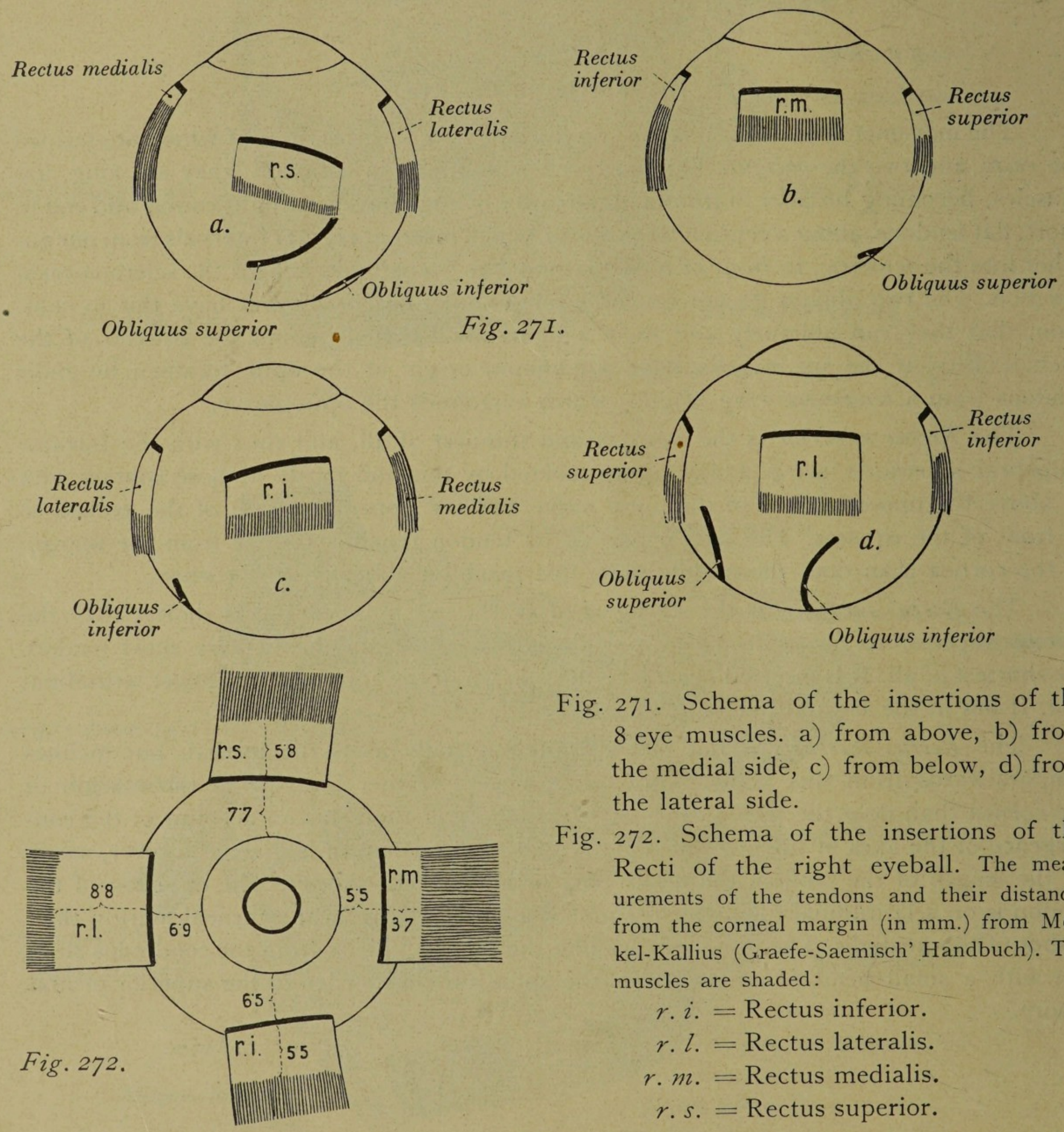

Fig. 271.

Fig. 271. Schema of the insertions of the 8 eye muscles. a) from above, b) from the medial side, c) from below, d) from the lateral side.

Fig. 272.

Fig. 272. Schema of the insertions of the Recti of the right eyeball. The measurements of the tendons and their distances from the corneal margin (in mm.) from Merkel-Kallius (Graefe-Saemisch' Handbuch). The muscles are shaded:

r. i. = Rectus inferior.
r. l. = Rectus lateralis.
r. m. = Rectus medialis.
r. s. = Rectus superior.

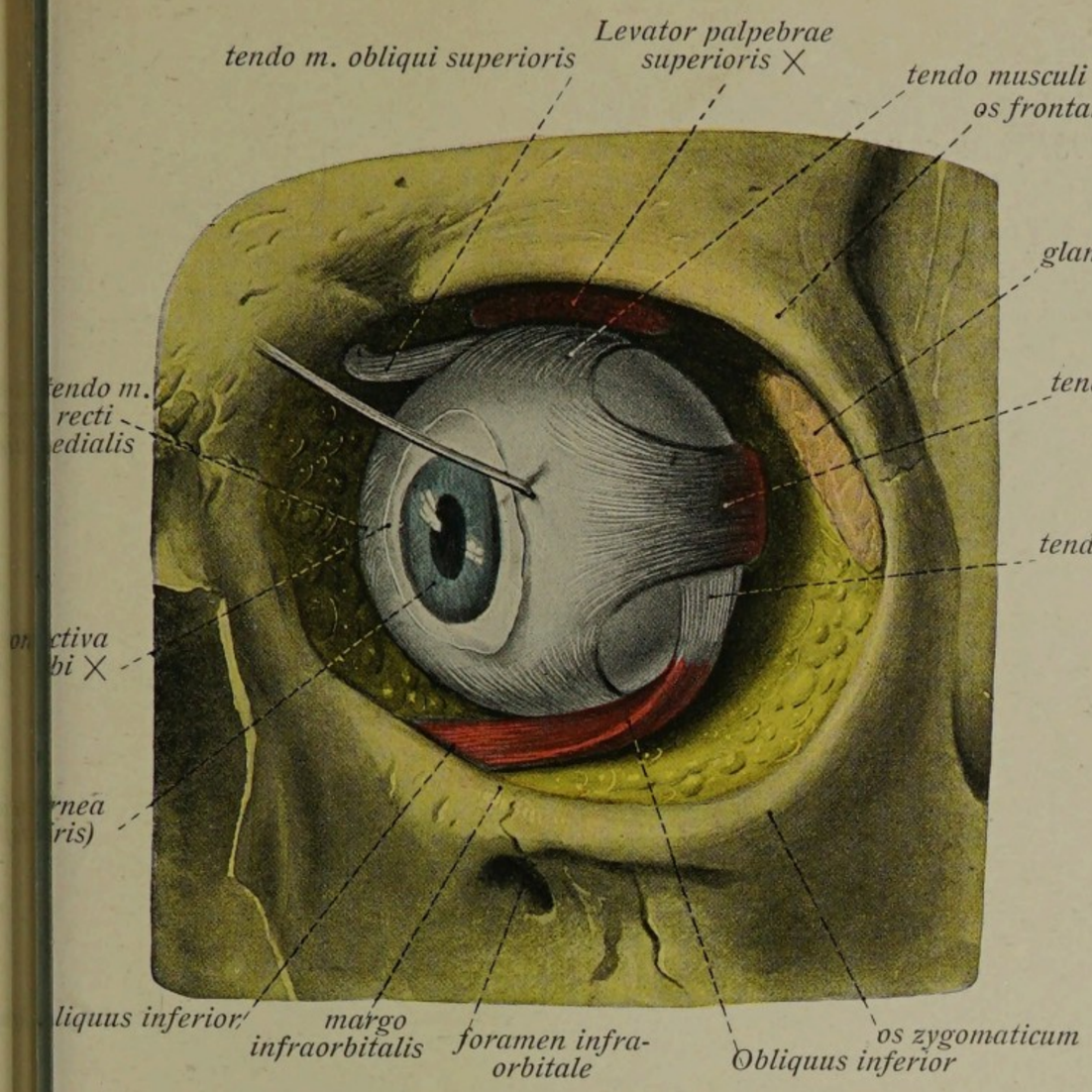

Fig. 273.

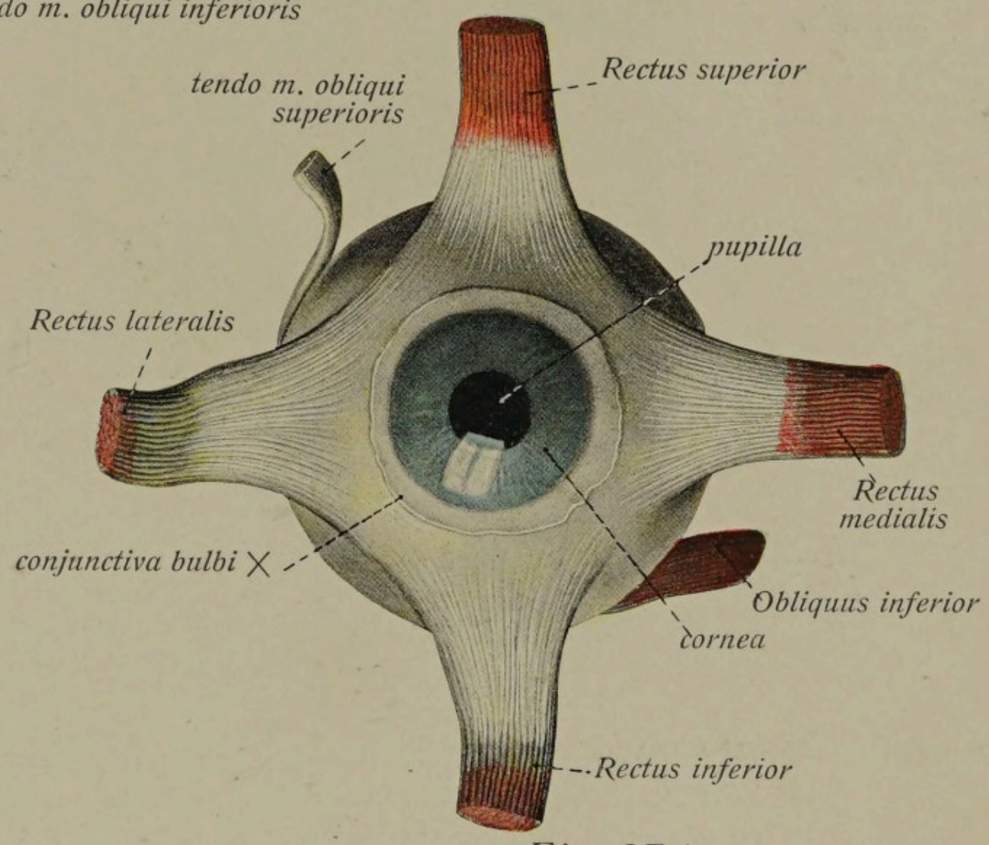

Fig. 274.

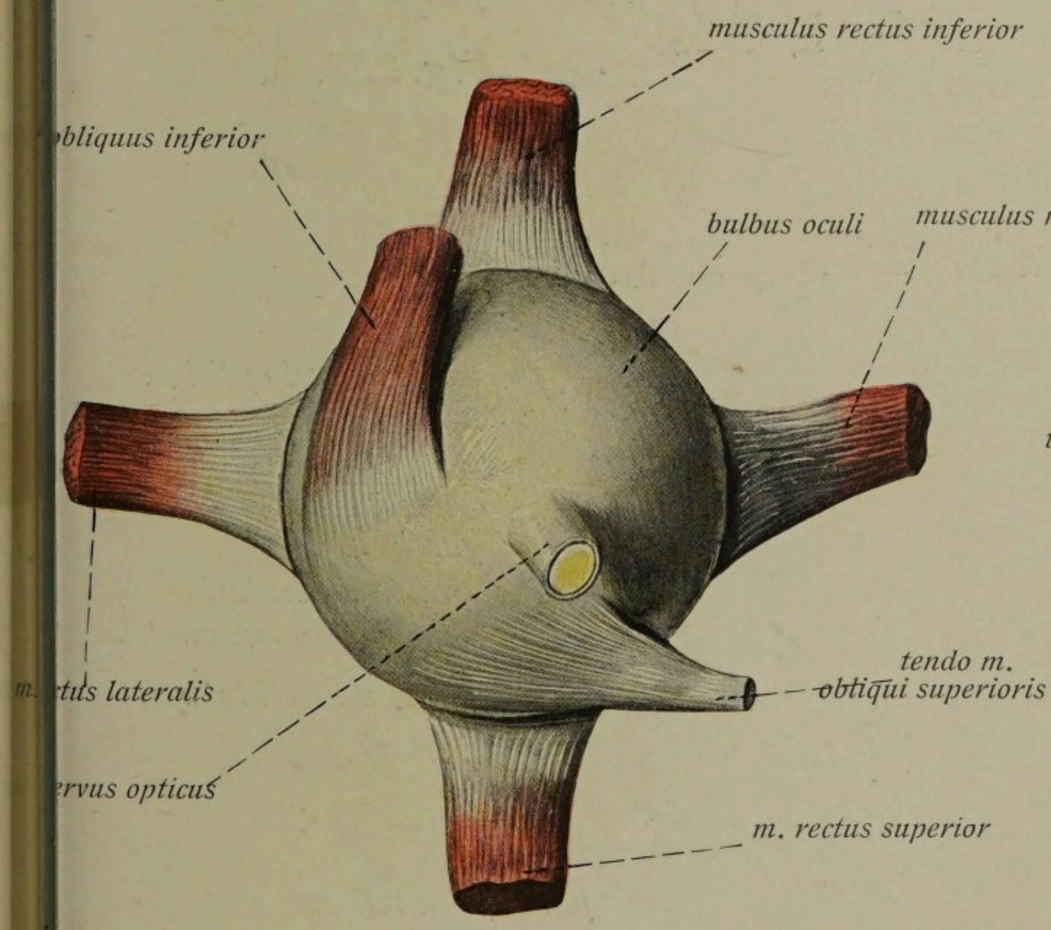

Fig. 275.

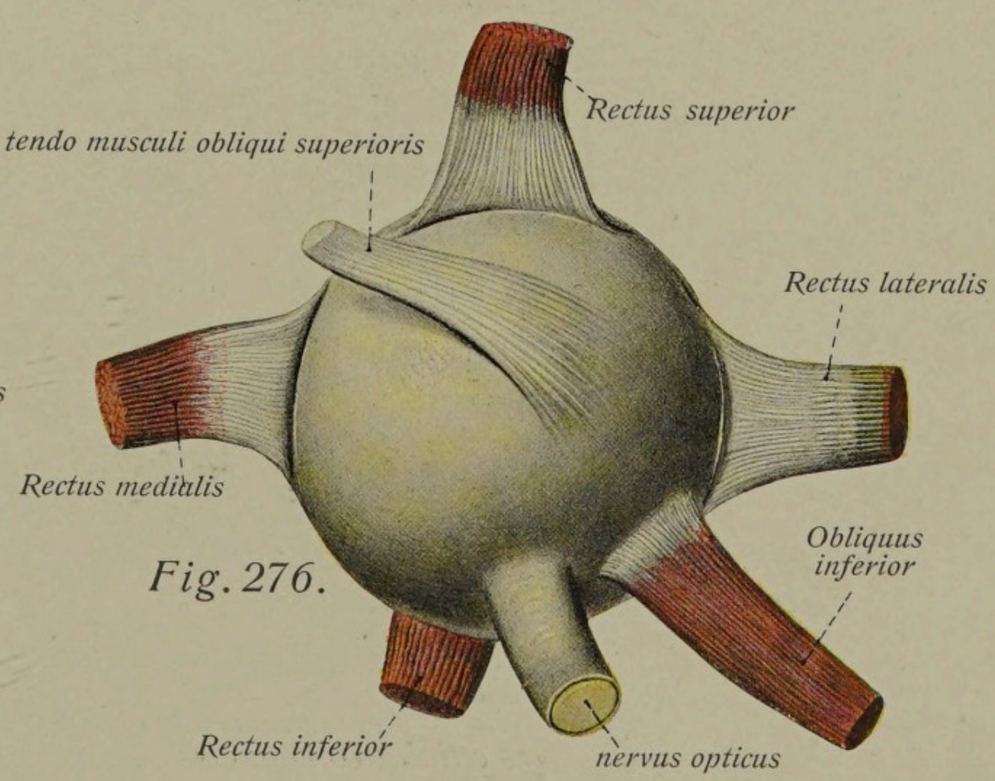

Fig. 276.

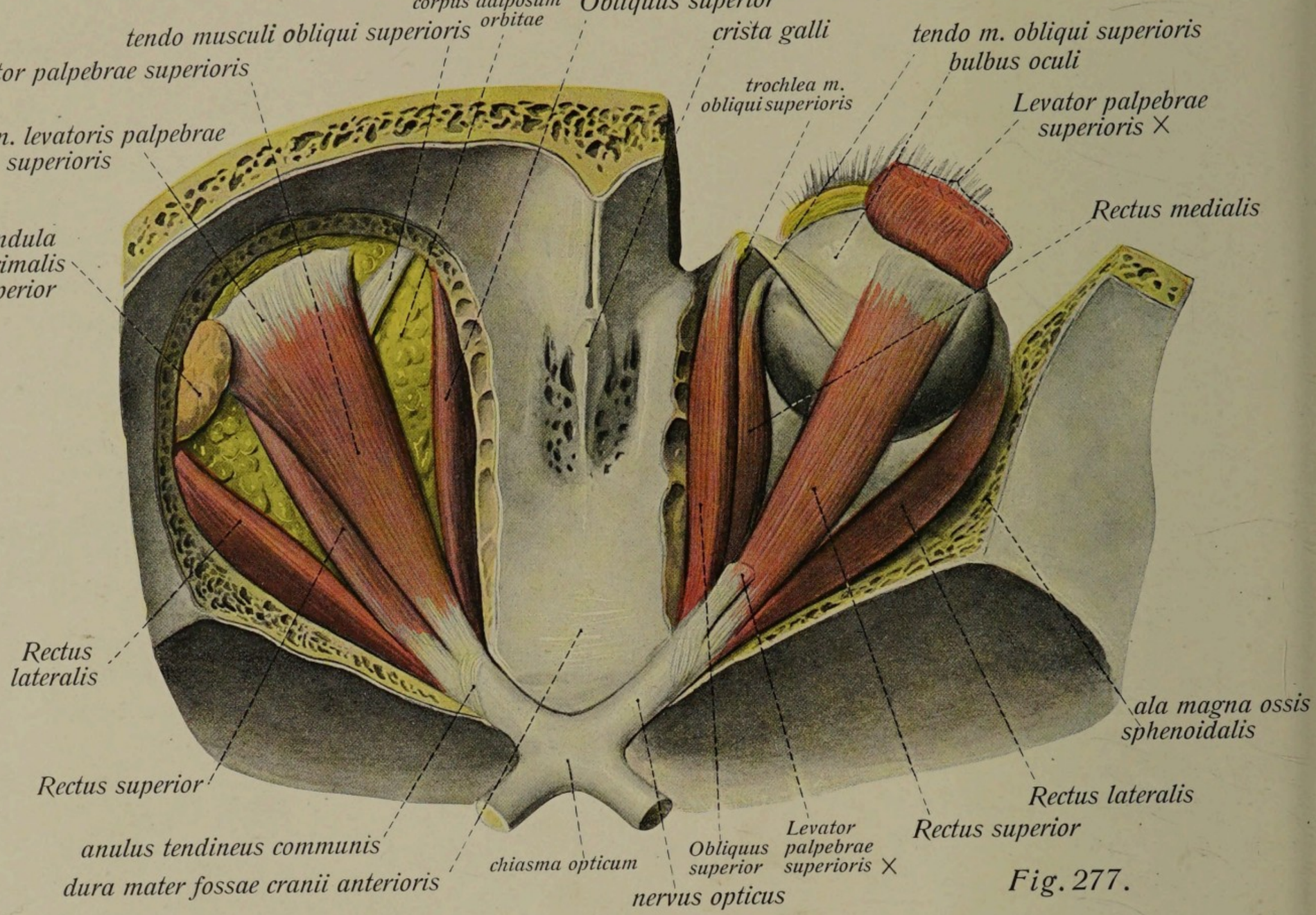

Fig. 277.

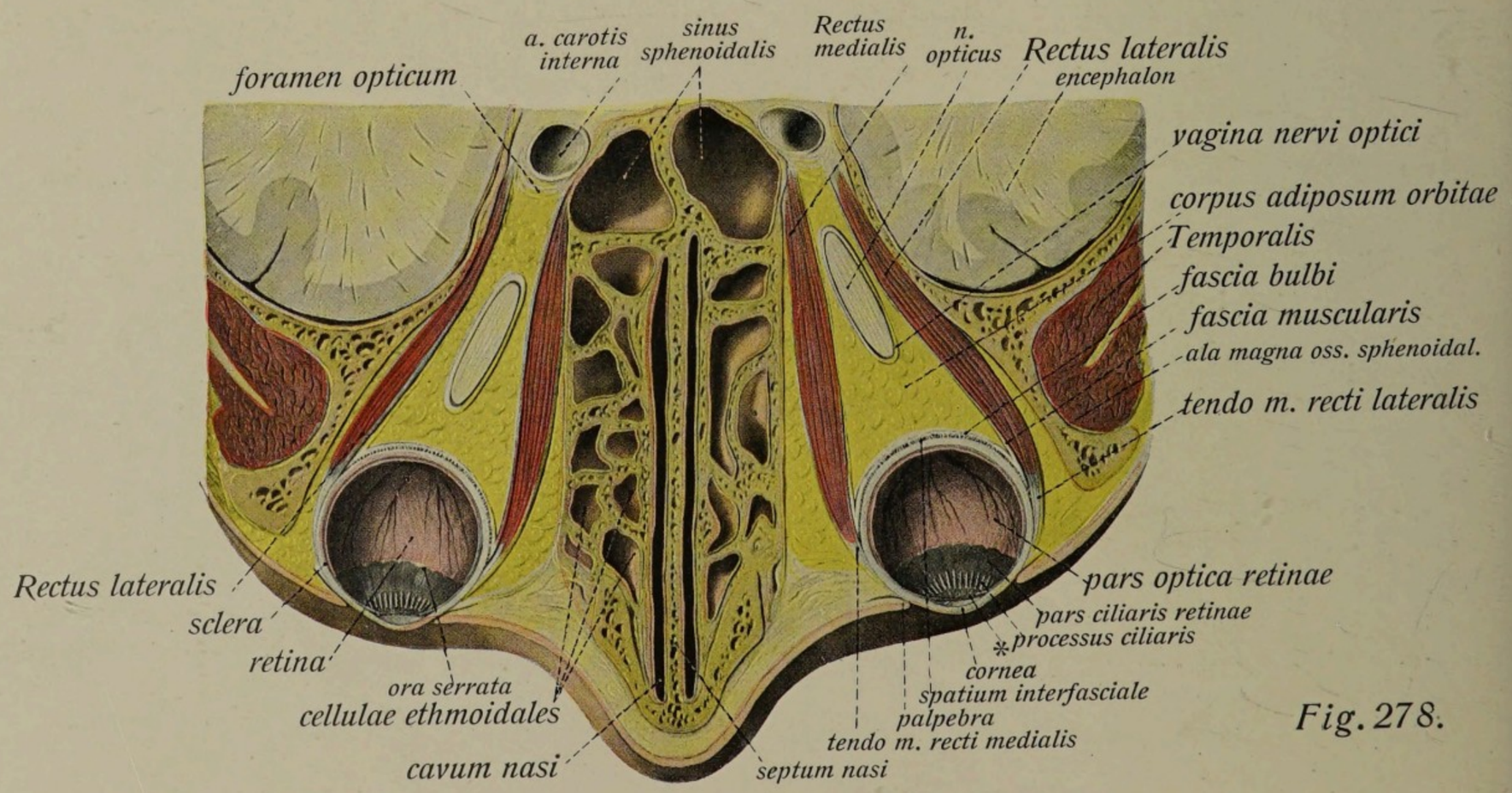

Fig. 278.

The Eye. The Muscles of the Eye. (Cont.)

Fig. 277. The muscles of the orbit from above. (1/1) On the left the superficial layer; only the roof of the orbit and the periorbita have been removed. On the right the deep layer; the Levator palpebrae superioris is largely removed and the orbital fat entirely so.

Fig. 278. Horizontal section through both orbits. (2/3) * = iris.

The *Rectus inferior* lies on the under surface of the eyeball, not exactly opposite the Rectus superior, but inclining nasalwards to the same extent as the latter does temporalwards. The same is true for the moderately long, rather small tendon, which is inserted obliquely as is that of the superior, but in the inverse direction (the lateral border more posteriorly) and somewhat nearer the corneal margin. The length of its fleshy portion is less than that of any of the other recti; nevertheless it is a stronger muscle than the Rectus superior.

For the distances of the rectus tendons from the corneal border see the schema, Fig. 272, page 268.

The *Obliquus superior* arises with the recti from the optic foramen (medial circumference) and from the dural sheath of the optic nerve, and runs forward as a moderately flat muscle in the upper half of the nasal side of the orbit, close under the periorbita and separated from the eyeball by the fatty tissue of the orbit. At first, therefore, it is not in contact with the eyeball, but behind the region of the trochlear spine or fovea of the frontal bone it passes into a round tendon, which passes through a fibro-cartilaginous pulley (trochlea), from which it is separated by a small mucous bursa *(trochlear bursa)*. From the trochlea the tendon, gradually broadening and becoming thinner, runs backwards and laterally, passes under the Rectus superior, and, much broadened, inserts into the eyeball behind its equator. The insertion is a good half centimeter behind that of the Rectus superior and is along an oblique line, mostly on the temporal side and running almost parallel with the axis of the optic nerve.

The *Obliquus inferior* is the only one of the six muscles that takes its origin from the anterior portion of the orbit. It arises by a small and short tendon from the posterior part of the infraorbital border of the maxilla, below the fossa for the lacrimal sac. It runs, becoming somewhat broader, obliquely beneath the lower part of the eyeball, crosses under the Rectus inferior (lying between it and the Rectus lateralis) and passes, like the Obliquus superior, to the temporal side of the posterior hemisphere of the eyeball. Here it inserts opposite the tendon of the Obliquus superior, but by a smaller and shorter insertion, in a line which crosses the axis of the eyeball at an acute angle. It is by far the shortest of all the eye muscles; its tendon is usually very short.

Fig. 279. Frontal section through the right orbit at the level of the posterior third of the eyeball, from in front (enlarged about 1/3).

Fig. 280. Frontal section through the orbit behind the eyeball, from in front (enlarged about 1/3).

The remaining Muscles and the Fasciae of the Orbit.

The eye muscles are provided with a fascial investment in the anterior part of their length, but in the cases of the Recti and the Obliquus superior this sheath becomes gradually thinner posteriorly, so that the posterior portion of these muscles lies practically naked in the fat tissue of the orbit. The stronger anterior part of the sheaths of the Recti is only apparently a direct continuation of Tenon's capsule (see p. 275). Only the Obliquus inferior has a uniformly thick fascia throughout its entire length, as has also the praetrochlear portion of the tendon of the Obliquus superior, whose sheath is a direct tubular prolongation of Tenon's capsule.

In addition to the six muscles that move the eyeball there is in the orbit another transversely striated, voluntary muscle, the *Levator palpebrae superioris*. It is a long muscle, broader in front than behind, which almost covers the Rectus superior (only its lateral border remains free) and lies closely imposed upon that muscle in the posterior part of the orbit. It arises with the Rectus superior by a small, short tendon from the tendinous ring (see p. 267), it consists of striated muscle tissue and is covered by fascia in its anterior portion. Between its tendon and the palpebral conjunctiva there are the smooth muscle fibres of Muller's muscle, *m. palpebralis*. The aponeurosis forks before its insertion in such a way that the posterior part inserts into the upper border and the whole anterior surface of the tarsus of the upper lid, while the anterior part passes between the tarsus and the skin of the eyelid and inserts into this skin.

The term *m. orbitalis* is applied to smooth muscle fibres of the orbit which occur in variable amount around the eyeball and also form a strong layer closing the inferior orbital fissure.

The *periorbita* is the periosteal lining of the orbit and is continuous with the periosteal layer of the dura mater at the optic foramen and superior orbital fissure, and with the periosteum of the bones of the face at the inferior orbital fissure. The superior orbital fissure is closed by a thickening of the periorbita, except for the openings for the passage of blood vessels and nerves.

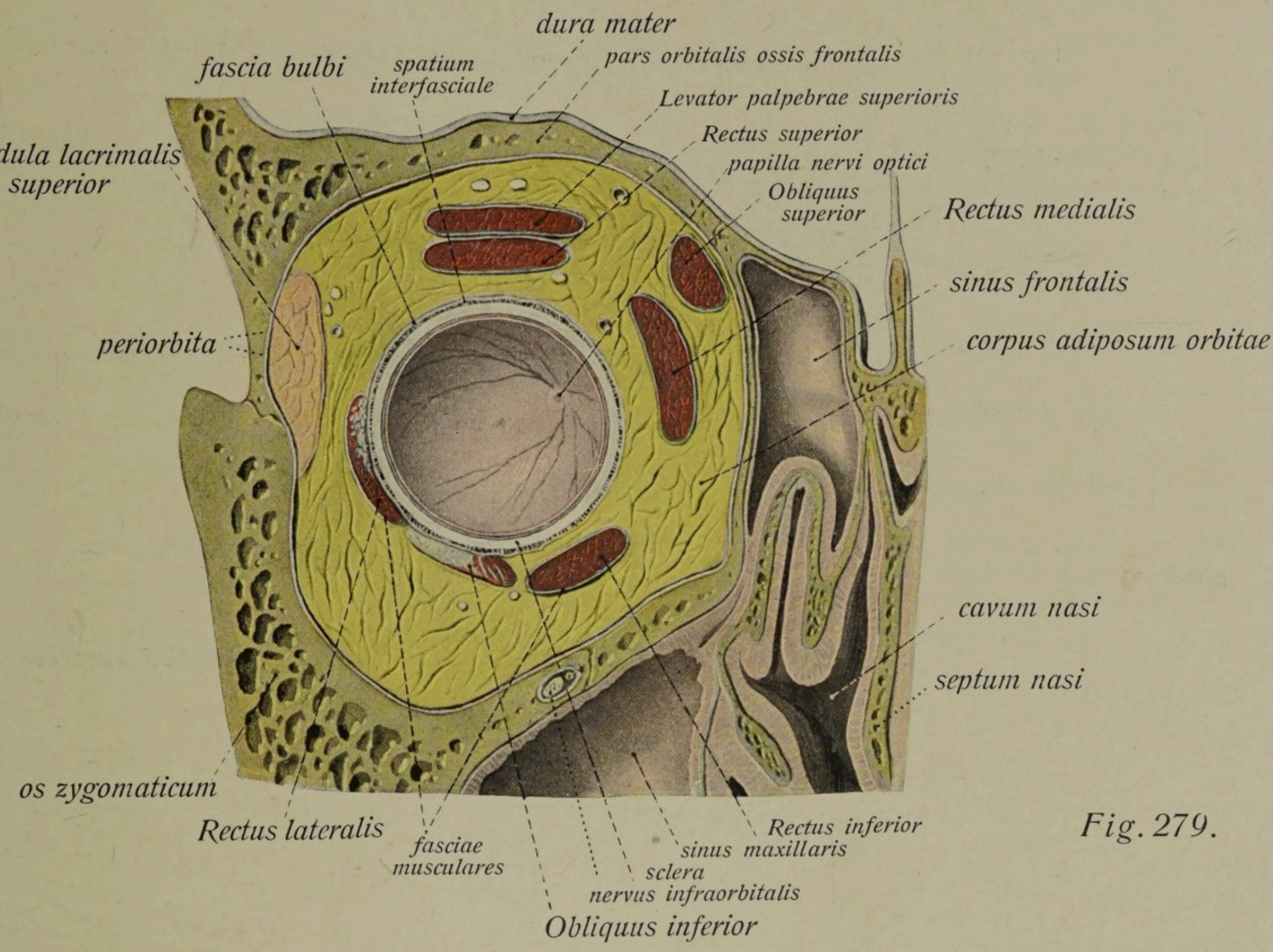

Fig. 279.

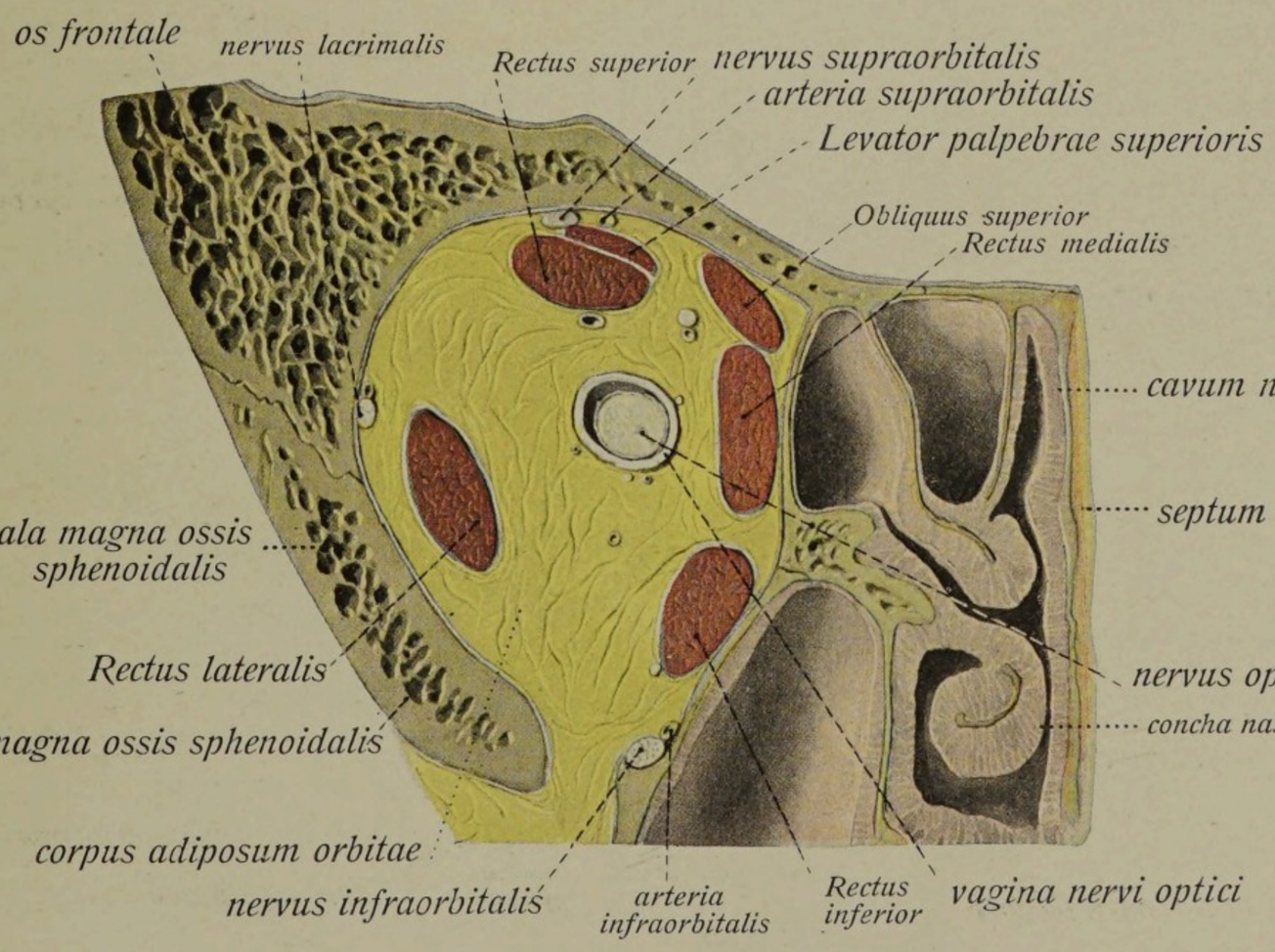

Fig. 280.

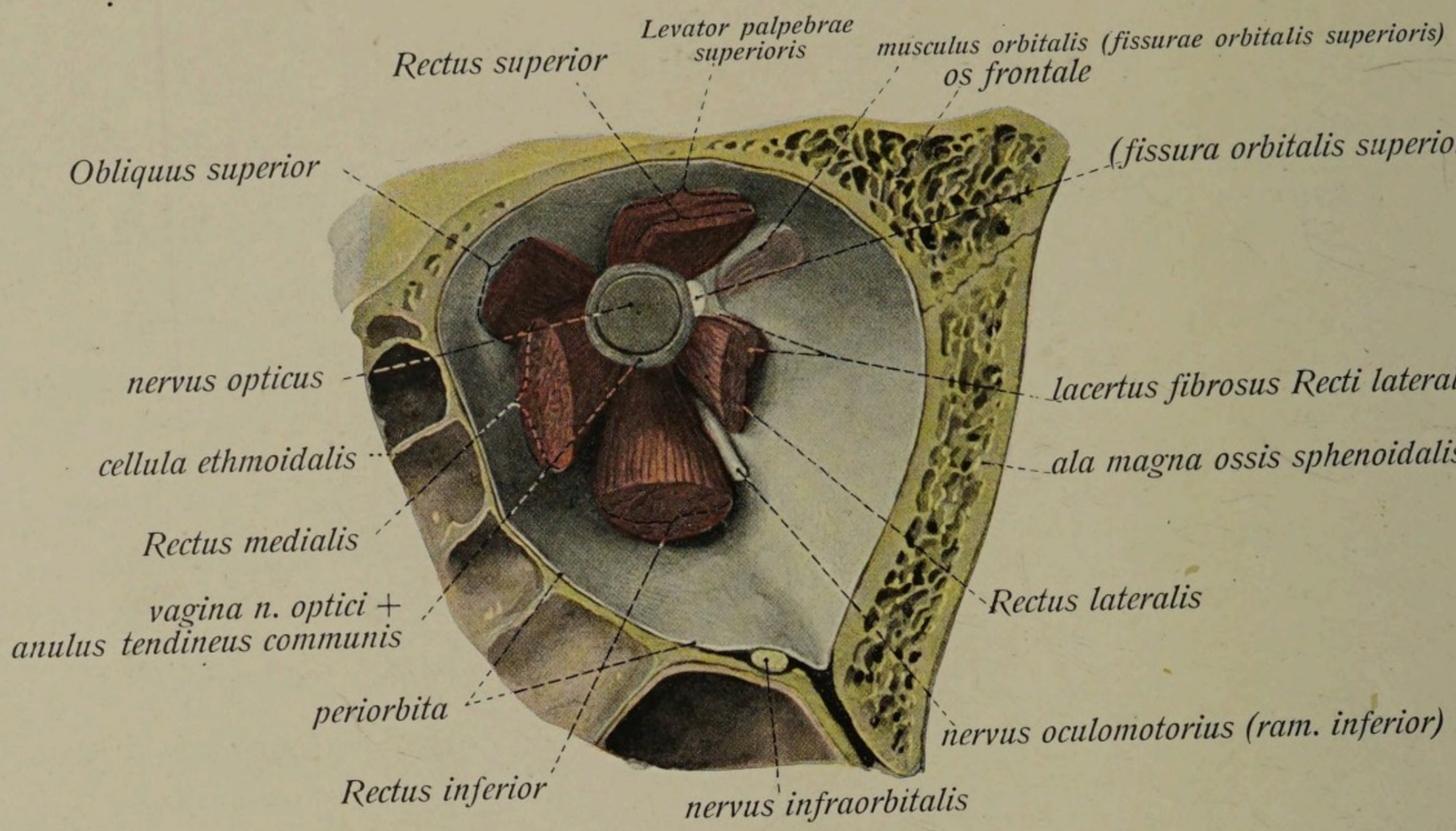

Fig. 281.

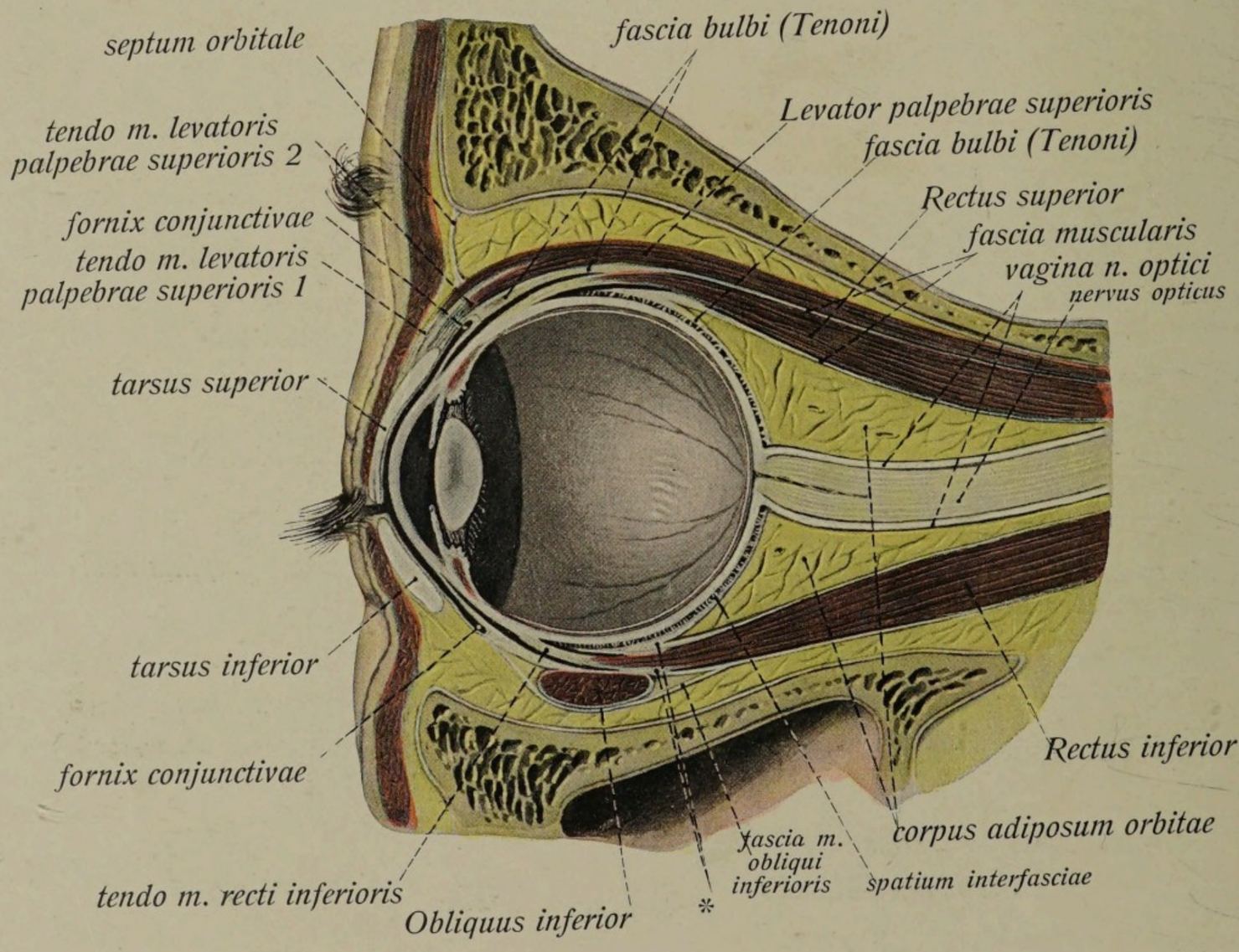

Fig. 282.

The Eye. Fasciae of the Orbit. (Cont.)

Fig. 281. The origins at the optic foramen of the muscles of the left orbit.
The orbit is divided in the frontal plane, and one looks from in front on the posterior surface of the section. The optic nerve is cut close to the optic foramen, and the stumps of the muscles which surrounded the optic nerve are retained. Of the other nerves only the lower branch of the oculomotor is retained. (Enlarged about $^1/_3$)

Fig. 282. Sagittal section through the orbit and eyeball, somewhat schematized as to Tenon's capsule (after H. Virchow). (Enlarged about $^1/_3$)
* = point of fusion of the capsule with the muscle.

The Fasciae of the Orbit. (Cont.)

The *orbital septum* is a fascia-like, connective tissue structure at the opening of the orbit, like a diaphragm perforated at its centre. It covers the posterior surfaces of the eyelids, follows their form and is therefore convex anteriorly, and separates them from the actual contents of the orbit. At the same time it is the posterior fascia of the Orbicularis oculi. Since it extends into the bases of the eyelids it belongs to a certain extent also to these and, in the upper lid, it is connected with the aponeurosis of the Levator palpebrae superioris. The nerves and blood vessels passing out from the opening of the orbit (the frontal, supraorbital, supratrochlear, infratrochlear and lacrimal nerves; the frontal and supraorbital arteries and the naso-frontal vein) pierce the upper (orbital) part of the septum. At the medial and lateral angles of the eye it is connected with the medial palpebral ligament and the lateral palpebral raphe. It shuts in the fat tissue *(corpus adiposum)* of the orbit anteriorly and is made convex anteriorly by it.

The Capsule of Tenon, *fascia bulbi.*

Tenon's capsule is a hollow spherical structure, formed of lamellae of connective tissue, in which the posterior hemisphere of the eyeball rests and moves. It separates the eyeball from the fat tissue of the orbit. The anterior thickened end of the capsule lies at the fornix of the conjunctiva and splits there into a conjunctival and a palpebral portion. Posteriorly the capsule gradually becomes thinner. It is pierced in the first place by the optic nerve, and, secondly, by the tendons of the six muscles of the eyeball. The optic nerve passes through an irregularly round opening in the posterior thinner portion of the capsule and with it pass the accompanying nerves and vessels (ciliary nerves and vessels), so that the capsule becomes gradually inseparably united with the sclerotic. The muscle tendons pierce the capsule (here markedly thicker) obliquely through slit-like openings and, from the openings for the obliqui, the capsule extends backwards over the tendons of these muscles as a strong fascia (see p. 272).

The capsule is not in immediate contact with the eyeball, but throughout its entire extent is separated from it by a narrow space *(interfascial space)*, traversed by strands of connective tissue. Anteriorly this space extends to behind the bulbar conjunctiva.

The Eye. Capsule of Tenon.

Fig. 283. Tenon's capsule, fascia bulbi, of the right eye with its openings, after removal of the eyeball. (Somewhat enlarged.)
Both eyelids are divided to the base by a sagittal incision and reflected. * = inner lip of the muscle opening.

Fig. 284. The tarsi of the eyelids of the right eye with the palpebral ligament and raphe and the lacrimal sac. (1/1)
The skin and musculature of the eyelids have been removed; the tendon of the Levator palpebrae superioris is cut.

For explanation see p. 272 and 275.

The Ear.

The auditory apparatus, which is mostly contained within the temporal bone of the skull, may be divided into three principal portions:

I. The *internal ear*, formed by the so-called *labyrinth*, which consists of the *membranous labyrinth*, containing the terminal apparatus of the acoustic (and equilibrium) nerves, and is therefore an actual part of the auditory apparatus; and of the *bony labyrinth* which is merely its osseous investment. The entire internal ear lies in the petrous portion of the temporal bone.

II. The *middle ear*, which consists principally of an air-containing cavity of the temporal bone, the *tympanic cavity*. It contains, as important structures, the actual sound conducting apparatus in the form of the *auditory ossicles*, and, furthermore, possesses a communication with the cavity of the naso-pharynx through the *tuba auditiva (Eustachian tube)*. It is separated from the external ear by the *tympanic membrane*.

III. The *external ear* is the portion of the ear that receives the sound waves and consists of the *external auditory (acoustic) meatus* and the *auricle*.

The Internal Ear.

The Membranous Labyrinth.

The membranous labyrinth is a branched, exceedingly thin-walled system of canals, filled by a watery fluid, the *endolymph*. The following parts may be distinguished in the endolymphatic canal system: the two vestibular sacs, the *sacculus* and *utriculus*, which are only indirectly connected with one another by the *utriculosaccular duct*, this arising from the *endolymphatic duct*, which, again, is a slender, blindly ending process from the sacculus. From the larger of the two sacs, the utriculus, three arched *semicircular canals (ducts)* take origin, while a spiral canal, the *cochlear duct*, is connected with the sacculus by a short, narrow canal, the *ductus reuniens*.

The endolymphatic ducts lie in corresponding cavities of the bony labyrinth, without, however, completely filling them. Between the membranous and bony labyrinths there is a *perilymphatic space*, also filled with fluid, the *perilymph*.

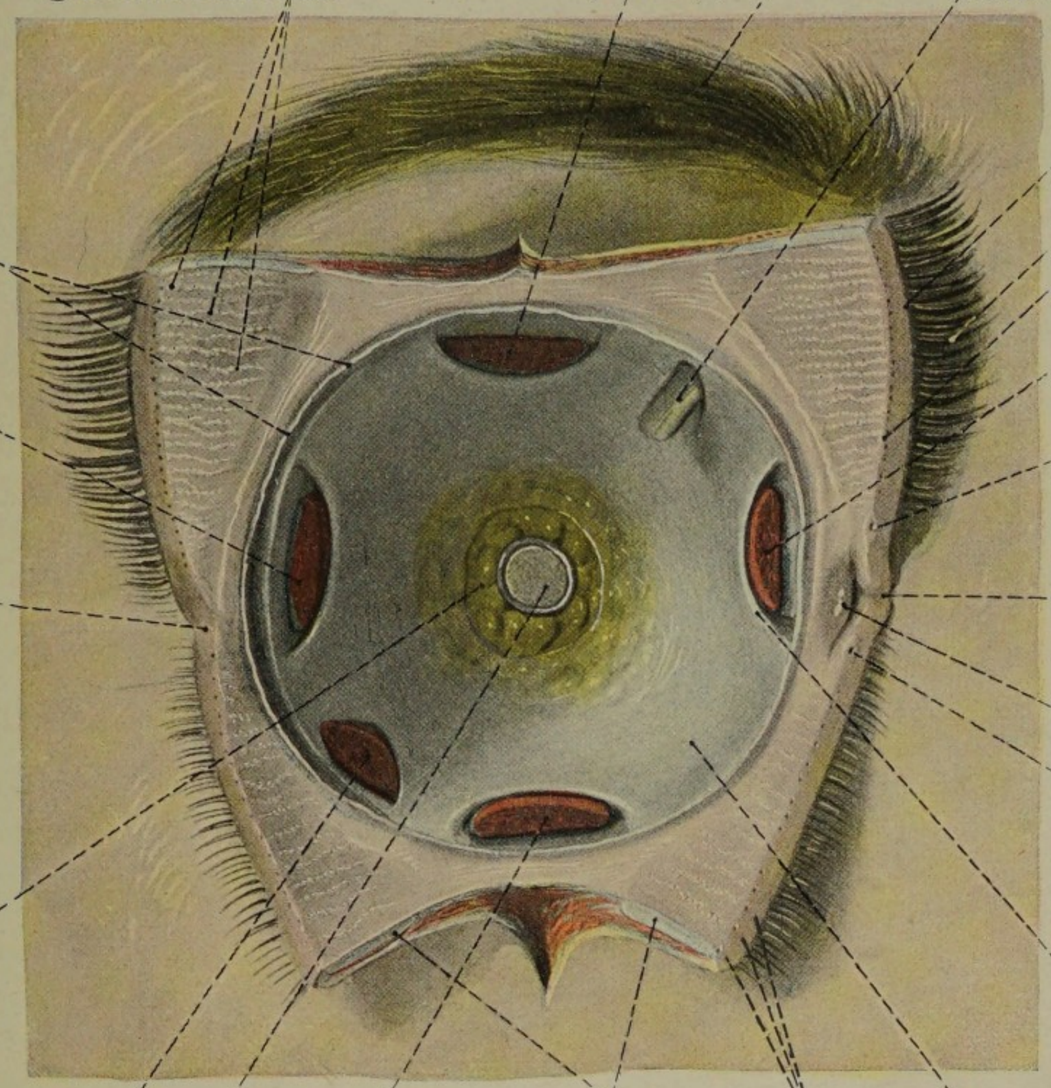

Fig. 283.

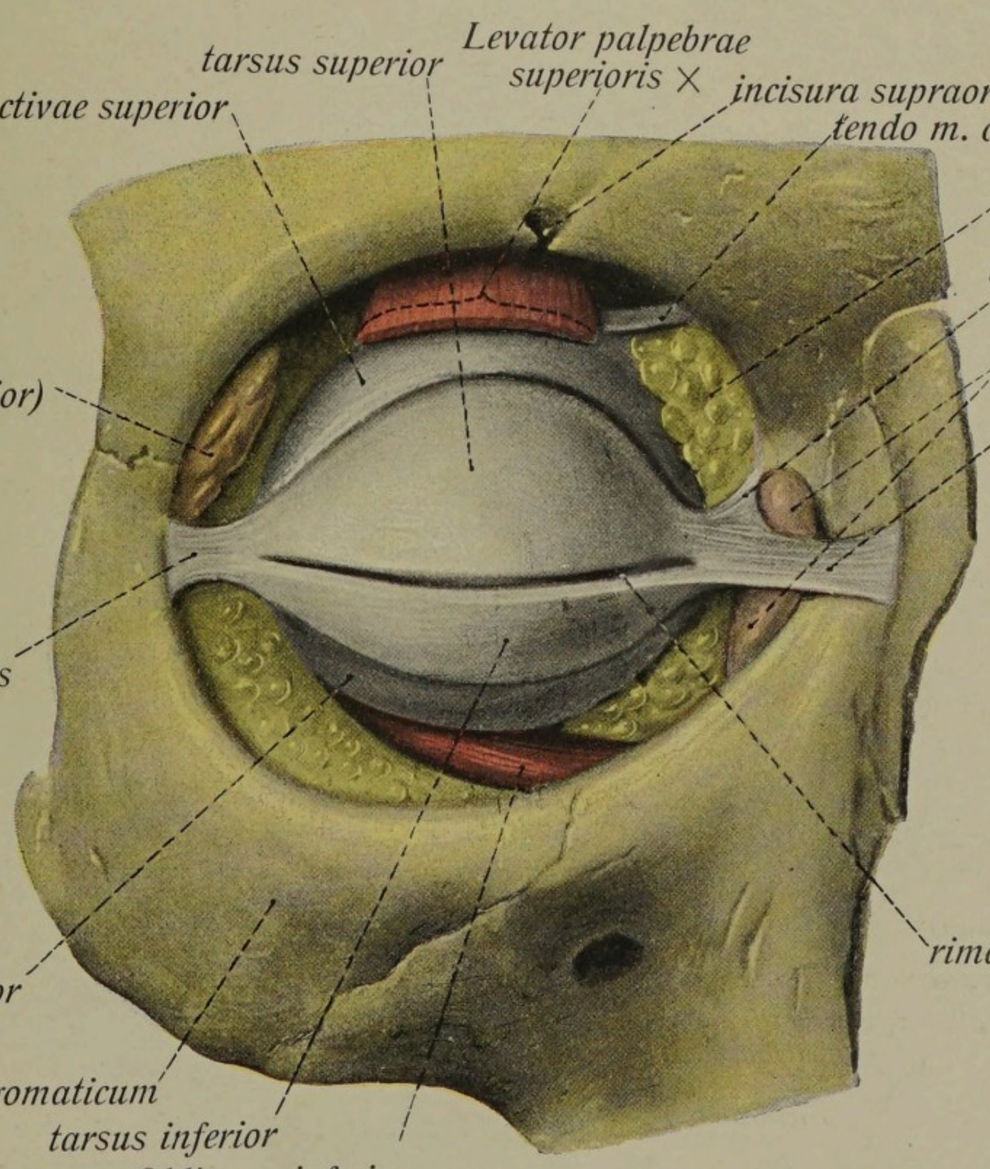

Fig. 284.

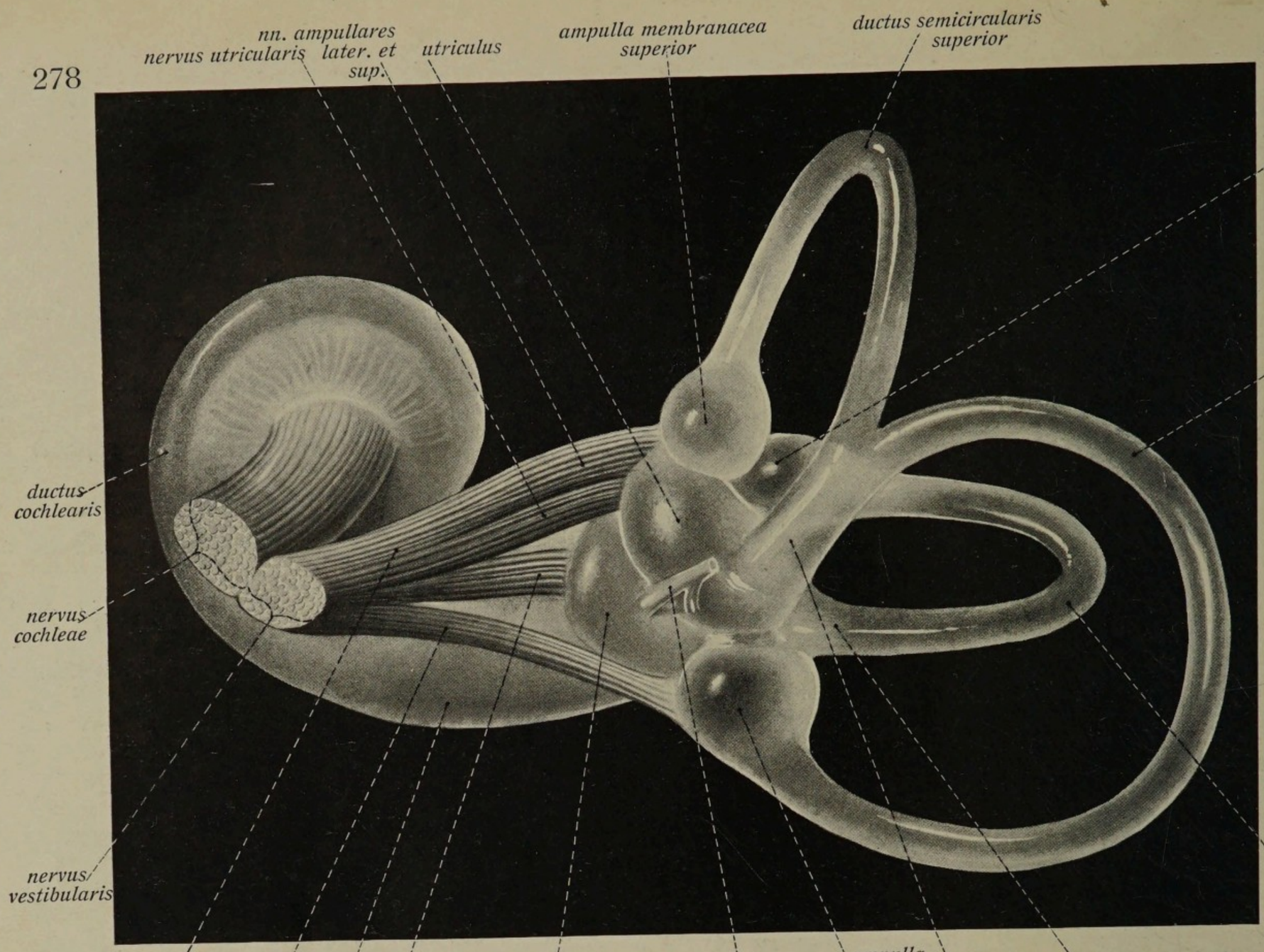

Fig. 285.

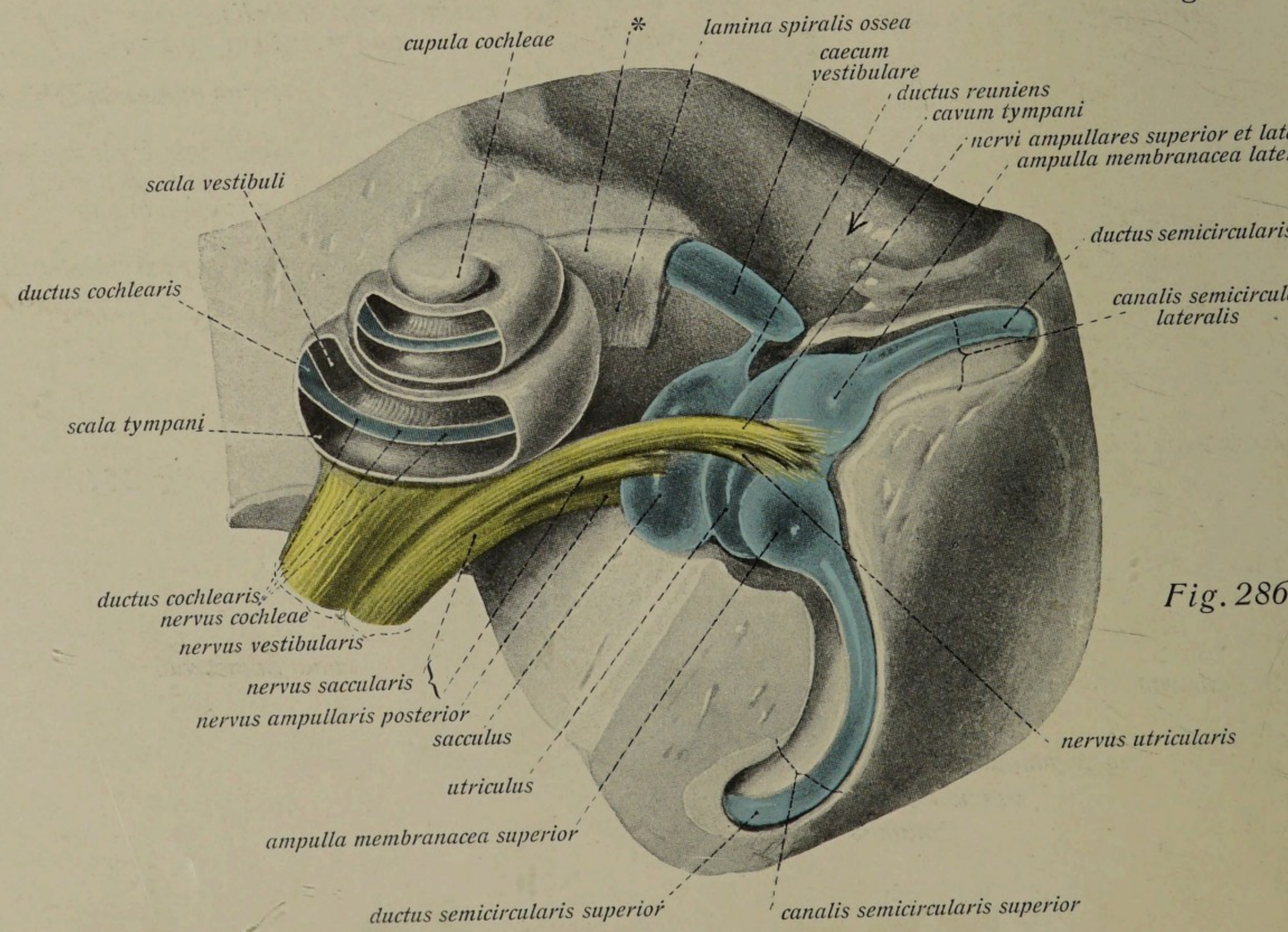

Fig. 286.

The Ear. The Labyrinth.

Fig. 285. The right membranous labyrinth isolated, with the branches of the acoustic nerve that pass to it. (Somewhat schematic.) (7/1)

Fig. 286. The right membranous labyrinth with the nerves that pass to it, partly exposed by chiselling away the bone. The cochlea is opened laterally. (Somewhat schematic.) (7/1) The membranous labyrinth (endolymph) blue. * = beginning of the basal coil.

Fig. 287. Schema of the membranous labyrinth. The endolymphatic spaces black, the bone shaded.

The Ear. The Labyrinth. (Cont.)

Fig. 289. The right bony labyrinth, from the medial side and behind. (6/1)

Fig. 290. The right bony labyrinth, from the lateral side and in front. (6/1)
* = apical. ** = middle. *** = basal coil of the cochlea.

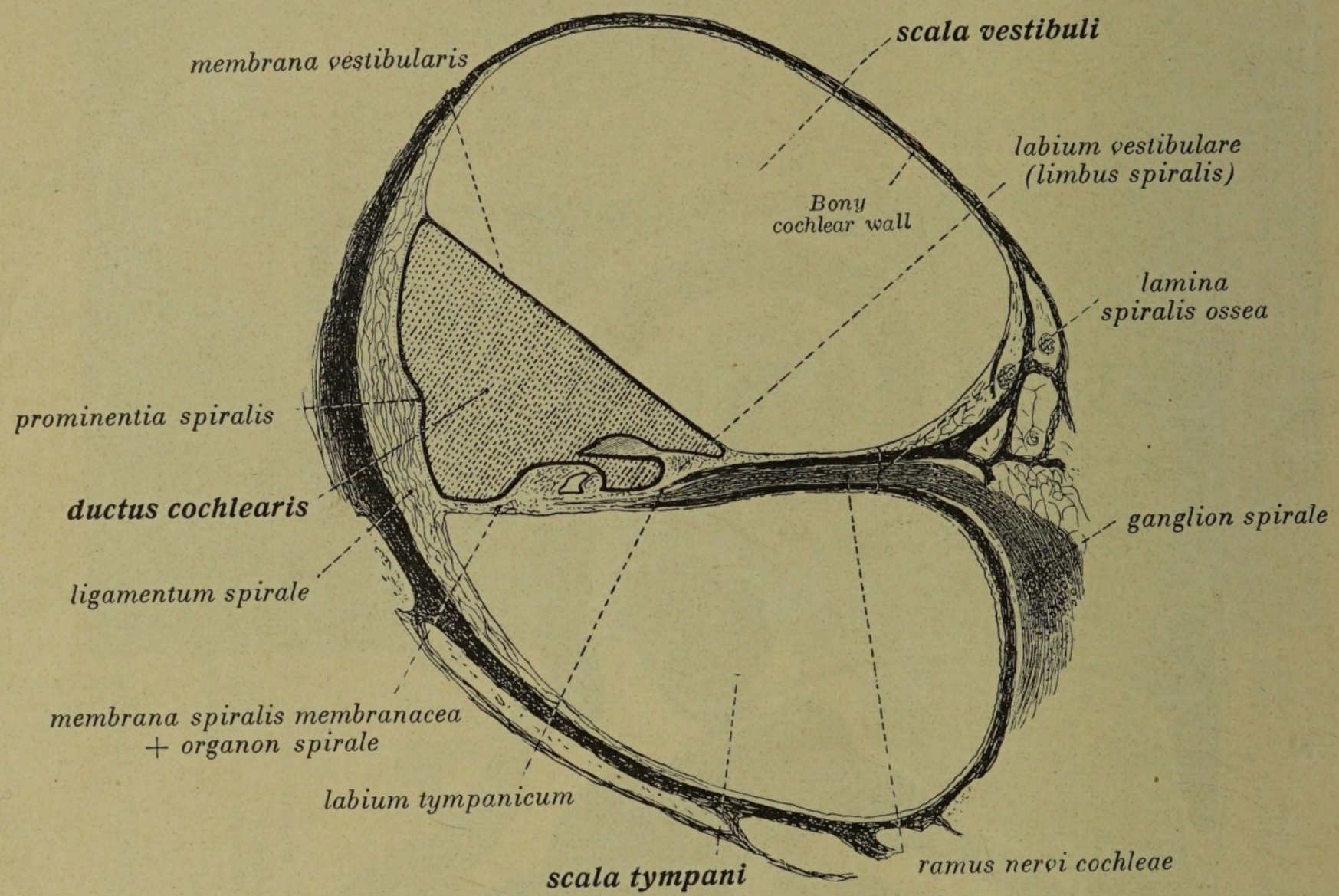

Fig. 288. Transverse section of a coil of the cochlea (schematic). The cavity of the cochlear duct is stippled.

The Membranous Labyrinth. (Cont. from p. 276.)

The *utriculus* is an oval, slightly flattened sac, which lies in the hemielliptic recess of the bony labyrinth. The *semicircular canals (ducts)*, which arise from it, are very thin-walled endolymphatic canals, oval in section, which lie excentrically in similar bony canals. One canal is *superior* (anterior), another *lateral* (horizontal) and the third *posterior*, and each has a hemispherical enlargement, an *ampulla*, at one of the ends attached to the utriculus, the ampulla of the superior canal being at its anterior end, that of the posterior canal at its lower end and that of the lateral canal at its anterior end. The membranous ampullae fill the bony ampullae almost completely. Corresponding to the relations of the bony canals, only the lateral canal has two separate openings into the utriculus, the superior and posterior canals, in addition to their openings through the ampullae, open at their other end by a very narrow common limb.

The *sacculus* is the smaller of the two vestibular sacs, and lies in the hemispherical recess of the bony vestibule. It has the form of a flattened sphere. From its lower slightly smaller end arises the very narrow *ductus reuniens* by which it communicates with the cochlea.

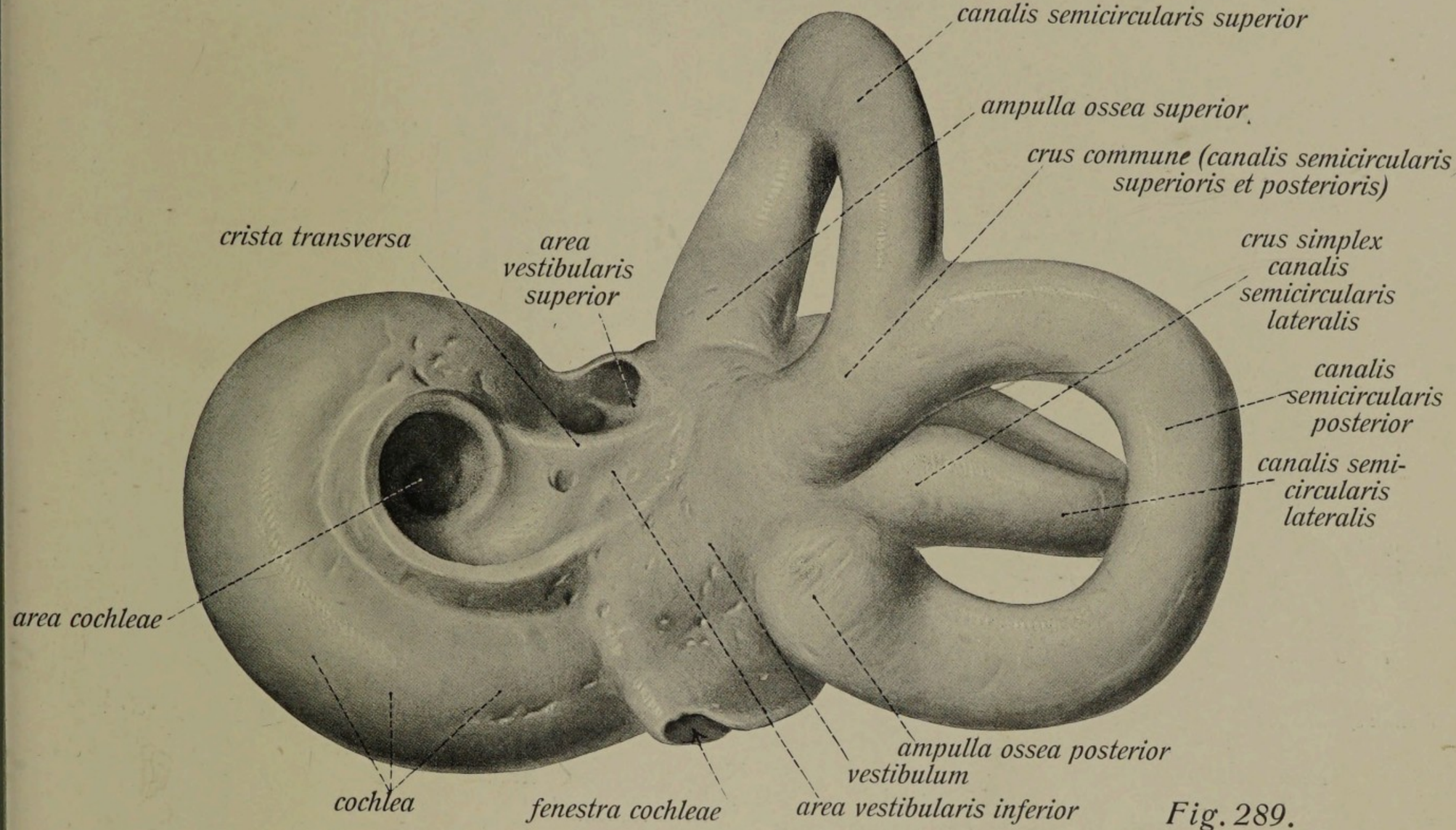

Fig. 289.

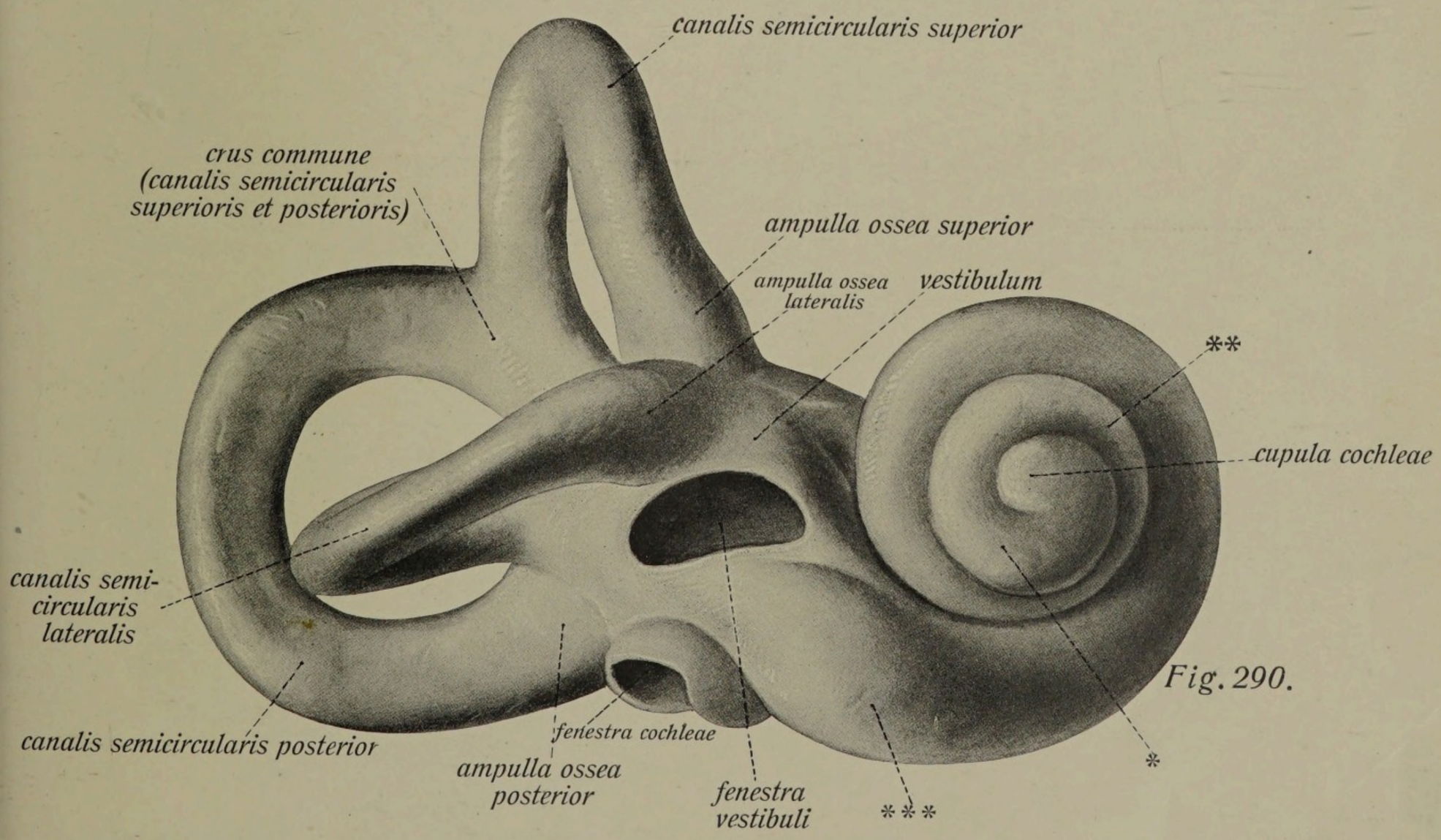

Fig. 290.

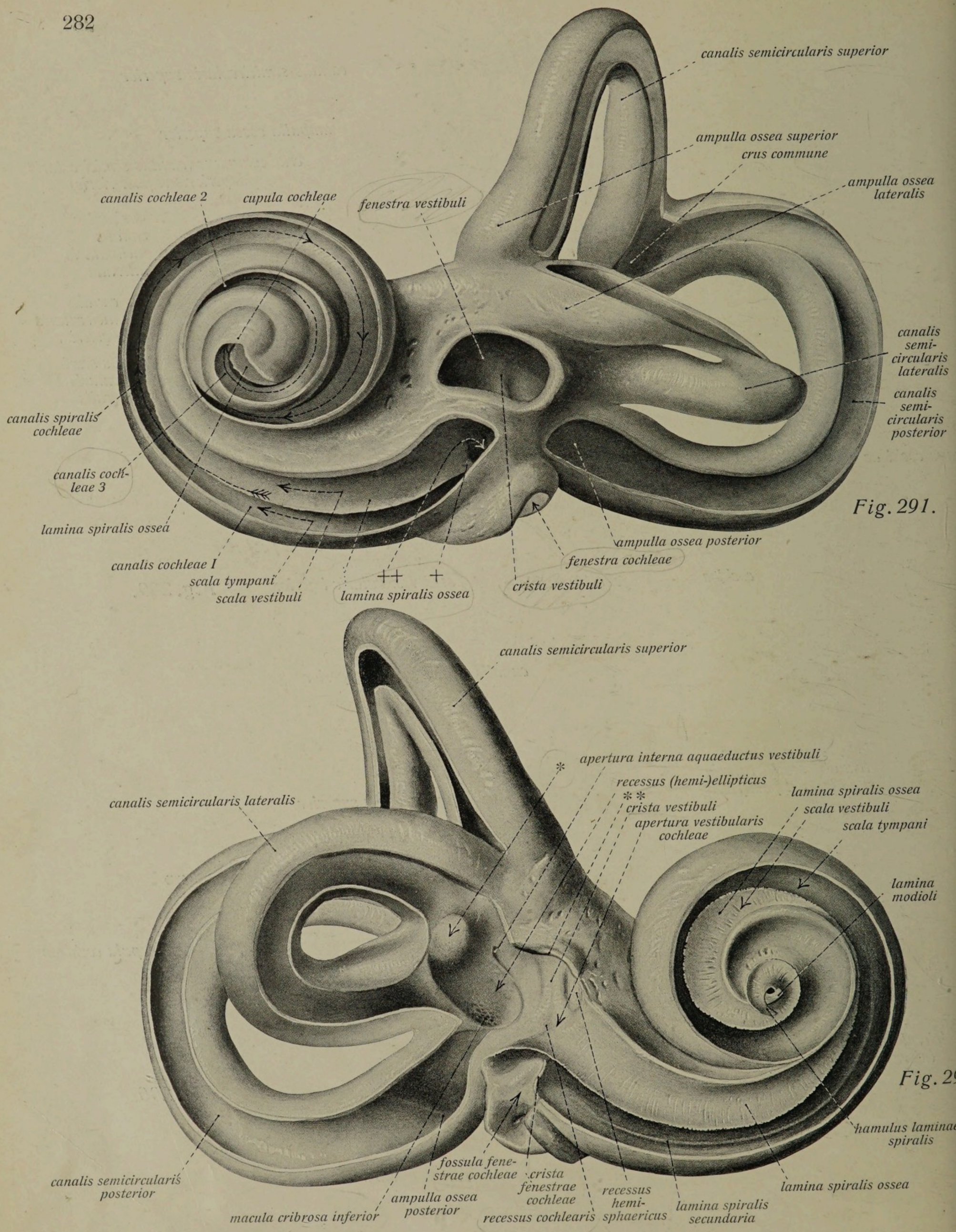

Fig. 291.

Fig. 292.

Fig. 291. The right bony labyrinth from in front. (7/1) The semicircular canals and the greater portion of the spiral canal of the cochlea are opened. + = beginning of the spiral lamina. ++ = vestibular opening of the cochlear canal.

Fig. 292. The left bony labyrinth. (7/1) Preparation as in Fig. 291, but the vestibule is opened and the cochlea up to its cupula. * = opening of the common limb of the posterior and superior semicircular canals. ** = margin of the vestibular fenestra.

The Membranous Labyrinth. (Cont.)

The *cochlear duct* is a narrow, spirally coiled canal, triangular in section, and runs in the spiral canal of the cochlea, making two and a half turns about the cochlear axis. It begins while still in the region of the vestibule by a blind sac, the *vestibular caecum*, and ends at the apex of the cochlea in the *cupular caecum*. One of its walls is attached to the free edge of the bony spiral lamina and extends to the opposite wall of the cochlea, where it unites with a periosteal thickening, the so-called *spiral ligament*; this wall is the *membranous spiral lamina* and it separates completely the scalae of the cochlea (see p. 287), which, without it would pass into one another at the free edge of the bony spiral lamina. A second wall is continuous with that just described over a thickening of connective tissue, the *limbus spiralis*, near the free edge of the bony spiral lamina, and extends thence as the very thin *vestibular (Reissner's) membrane* to the opposite wall of the cochlea, separating the cochlear duct from the perilymphatic scala vestibuli. The third wall is adherent to the lateral wall of the bony cochlea, completing the triangular cochlear duct (see Fig. 288).

The *endolymphatic duct* and *sac* are very rudimentary in man. The former arises from the lateral part of the sacculus and extends as an exceedingly fine canal through the whole length of the aquaeductus vestibuli, emerging under the dura mater to end blindly in the *endolymphatic sac*. Soon after leaving the sacculus the duct is joined at an acute angle by the *utriculosaccular duct*.

The Bony Labyrinth.

The Internal Auditory Meatus.

The internal auditory (acoustic) meatus begins at the internal auditory (acoustic) pore on the pyramid of the temporal bone and passes laterally in the substance of the bone, to end in the *fundus*. At this floor of the meatus the two nerve trunks, the facial and acoustic, which it contains, separate. On the fundus there is an almost horizontal *transverse crest*, which separates an upper smaller area from a lower larger one. The anterior part of the upper area is the *area of the facial nerve* and on it the *facial canal* begins at a rather large, round foramen. The posterior part of the upper area, the *superior vestibular area*, shows a number of small foramina which lead to the superior macula cribrosa of the vestibule (see p. 291) and contain the utricular and superior and lateral ampullary branches of the acoustic nerve. Below the transverse crest anteriorly is the *cochlear area*, which has a number of foramina arranged spirally, lying in the hollow base of the axis of the cochlea. Posteriorly is the *inferior vestibular area*, also with small foramina which lead to the middle macula cribrosa of the vestibule the saccular branch of the acoustic nerve. Finally there is an isolated round *foramen singulare* towards the posterior wall, that leads to the inferior macula cribrosa and transmits the posterior ampullary branch of the acoustic nerve.

The Ear. The Labyrinth. (Cont.)

Fig. 294. A cast of the right bony labyrinth, seen from the lateral side and in front. (7/1)
* = the beginning of the basal coil of the cochlea.

Fig. 295. A cast of the right bony labyrinth, from the medial side and behind. (7/1)
* (after cochlea) = basal coil, ** = middle coil.

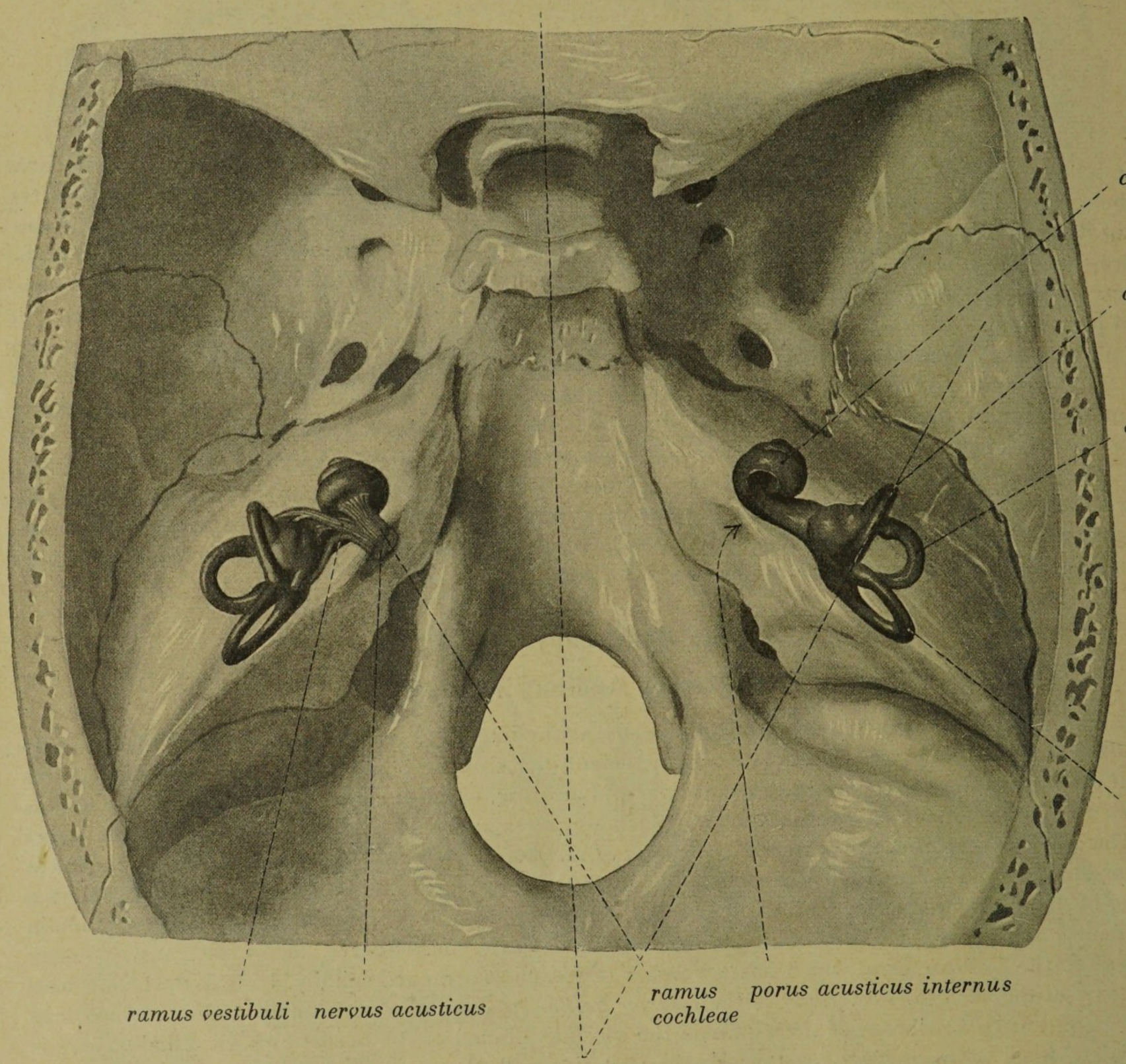

Fig. 293. The two bony labyrinths in their natural relative positions. On the left the nerves that pass to them are shown. (Schematic.)

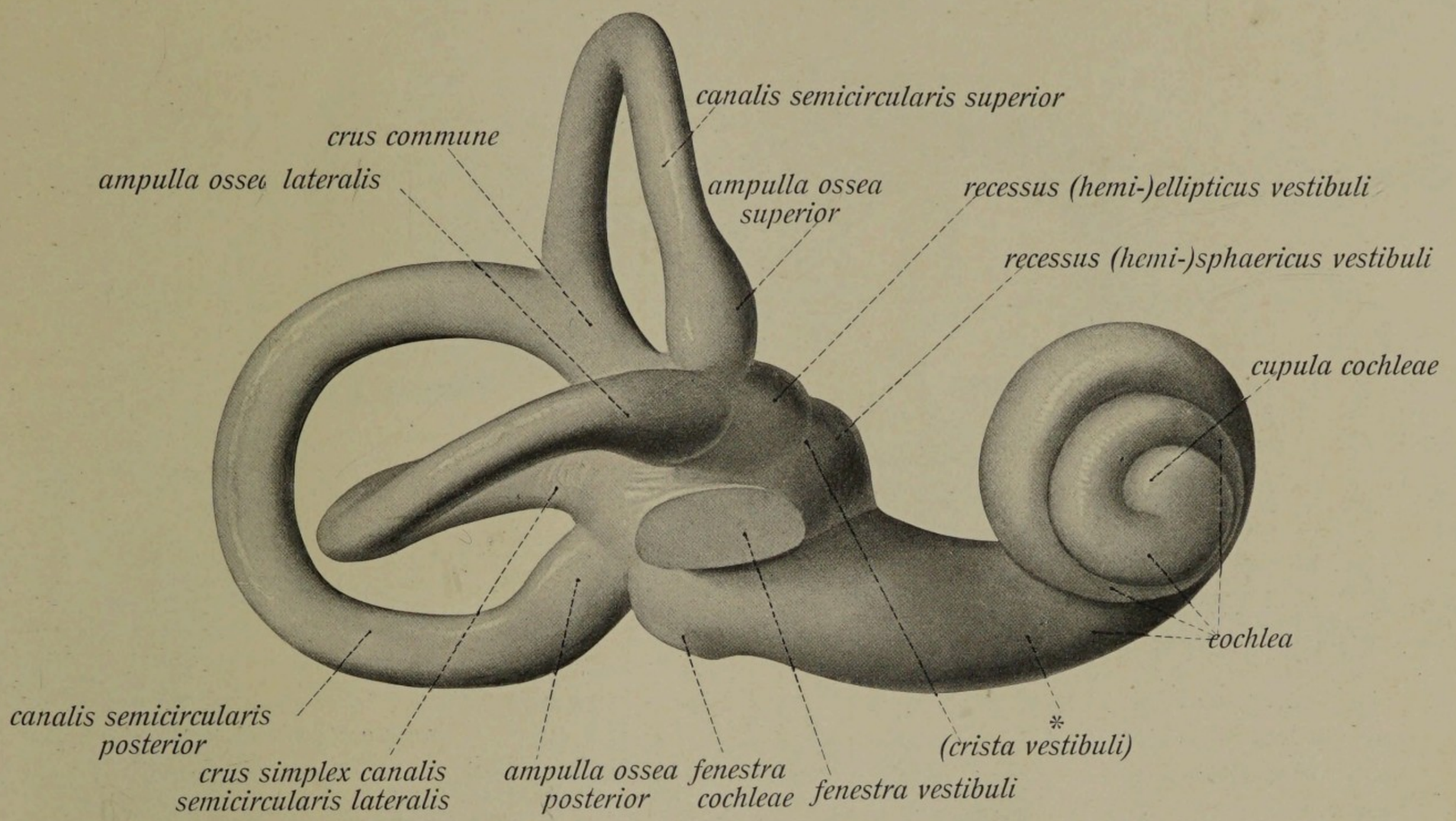

Fig. 294.

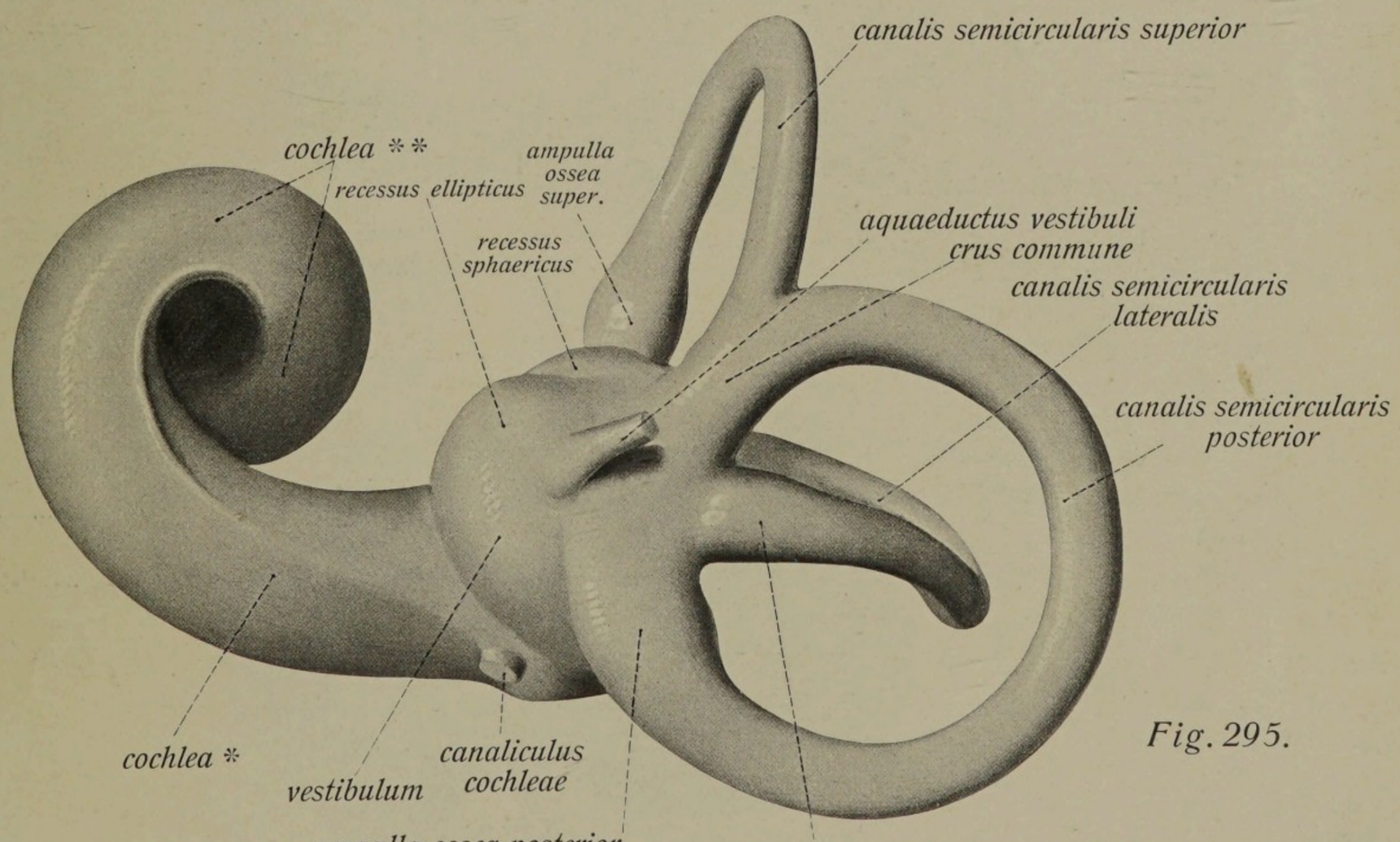

Fig. 295.

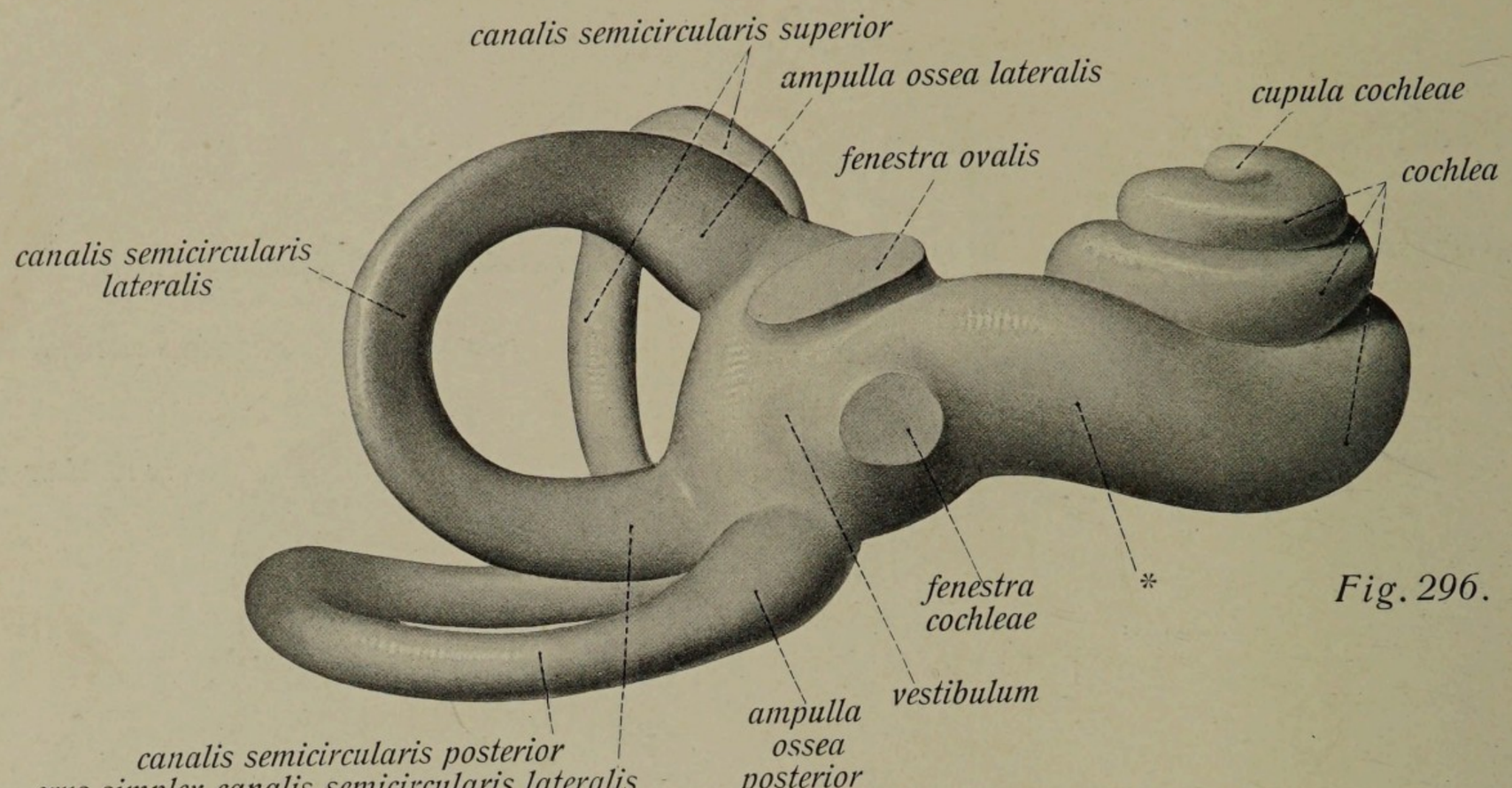

Fig. 296.

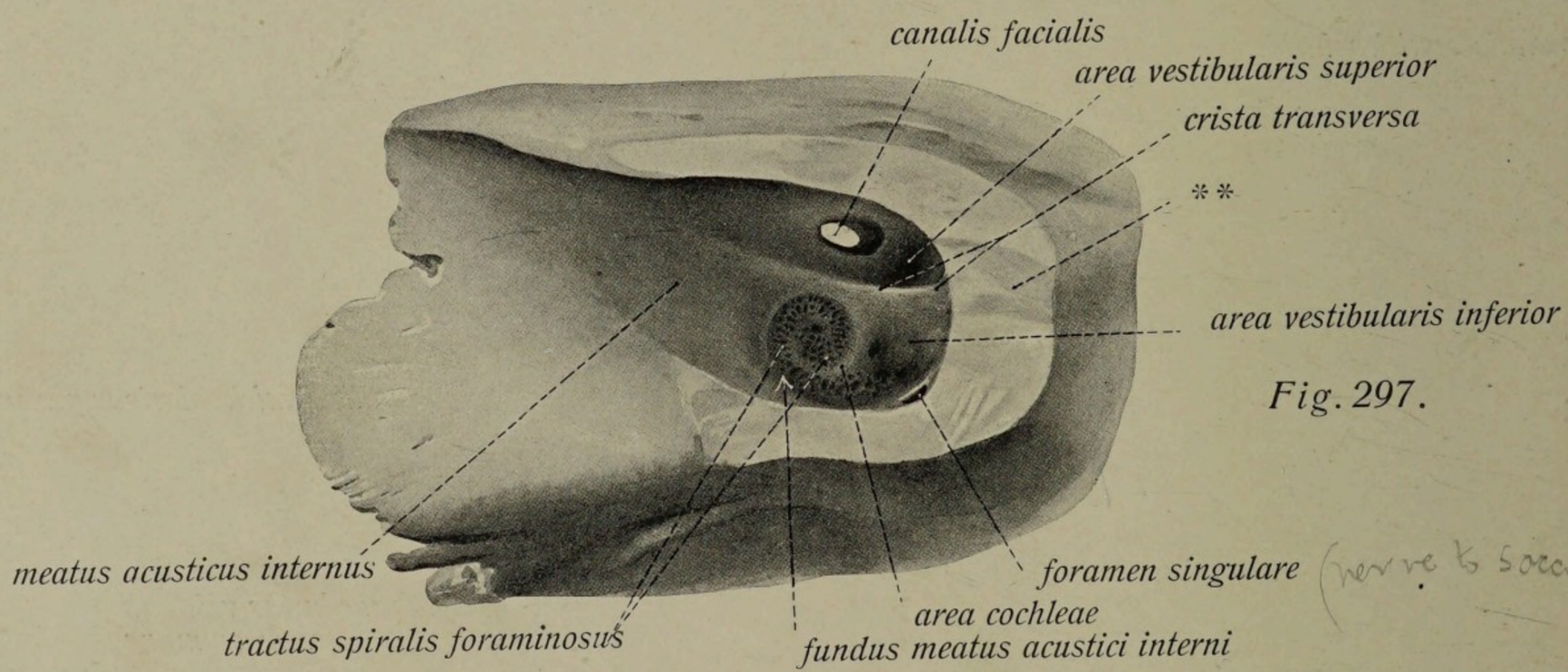

Fig. 297.

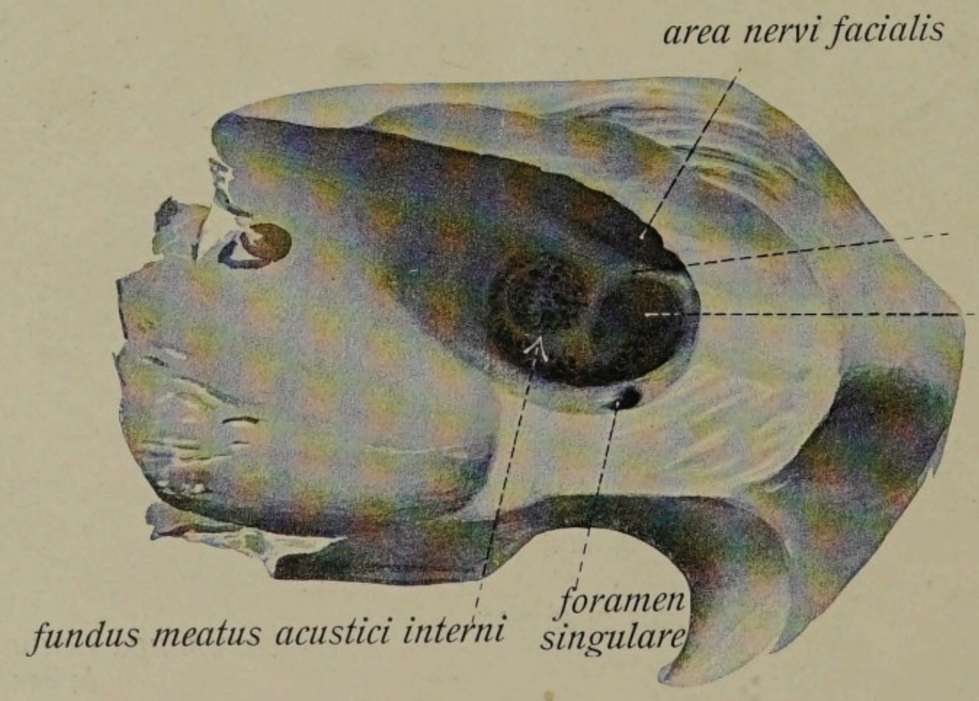

Fig. 298.

The Ear. The Bony Labyrinth.

Fig. 296. A cast of the right bony labyrinth, from below. ($^{7}/_{1}$)
* = beginning of the basal coil of the cochlea.

Fig. 297. The right internal auditory meatus after chiselling away a part of its posterior wall, from the medial side. (About $^{5}/_{1}$)
** = chiselled wall of the meatus.

Fig. 298. The same preparation more extensively chiselled, from the medial side and above.

The Cochlea.

The cochlea has the form of a *spiral canal* with two and a half turns. Its coils pass for the most part around an axis, the *modiolus*, which is formed of spongy bone and has the form of a low hollow cone. The broader part of the cochlea is its *base* and the apex, the *cupula*. The latter is directed towards the tympanic cavity, close to the medial wall of the tuba auditiva; the base looks towards the internal auditory pore. Consequently the axis of the cochlea lies obliquely, almost perpendicular to the posterior surface of the pyramid (see Fig. 293). The bony cochlear canal begins in the vestibule and near its beginning communicates with the tympanic cavity through the cochlear fenestra, and makes an elevation, the promontory, upon the lateral wall of that cavity. It runs free for a short distance (Fig. 296*) before it begins to coil about the modiolus. Towards the cupula it becomes gradually narrower; the middle coil is seated on the basal one and lies at a higher level; the apical coil, on the other hand, is surrounded by the middle coil.

The *base of the modiolus* is formed by the cochlear area at the fundus of the internal auditory meatus and contains the *spiral tract* of foramina for the entrance of nerve fibres. The axis of the modiolus coincides with that of the cochlea, but is much shorter. The basal coil of the spiral canal bends around the hollow base of the modiolus; in the region of the middle coil the modiolus consists of spongy bone, traversed by narrow longitudinal canals that end blindly; at the end of the second coil the modiolus proper ends and is continued by the *lamina modioli*. Around the modiolus winds the bony *spiral lamina*, which is an incomplete partition of the spiral canal. Where the modiolus ends the bony spiral lamina becomes free and curves as a thin sickleshaped plate, the *hamulus*, around the lamina modioli. There is thus formed between the lamina modioli and the hamulus a semilunar *helicotrema*, through which the two scalae, separated by the cochlear duct, communicate. The lower *scala tympani* begins at the cochlear fenestra and lies below the spiral lamina, while the upper *scala vestibuli* begins at the cochlear recess of the vestibule and runs above the vestibular membrane. At the beginning of the basal coil there appears on the lateral wall opposite the spiral lamina a *secondary spiral lamina*, which does not, however, extend beyond the basal coil. Since the half of the apical coil does not project above the level of the middle coil, the position of the bony wall between the coils changes. Between the basal and middle coils the thick intervening wall formed by the base of the modiolus is perpendicular to the axis of the modiolus; already in the middle coil it becomes oblique to it, and in the apical coil it comes to lie in the plane of the axis of the cochlea forming a plate, the *lamina modioli*, which is concave towards the apical coil, convex towards the middle coil. (Fig. 300.)

The Ear. The Labyrinth.

Fig. 299. The right bony labyrinth from in front and from the medial side. The cochlea is opened from the side. (About $^{7}/_{1}$)

Fig. 300. The left cochlea bisected. (About $^{6}/_{1}$)
* = basal coil. ** = middle coil. *** = apical coil.

Fig. 301. The lateral wall of the right vestibule. ($^{2}/_{1}$) The temporal bone is divided by a cut parallel to the axis of the pyramid.
* = basal coil of the cochlea.

The Bony Semicircular Canals.

The bony semicircular canals contain the membranous ones and, as in the case of these, two are vertical and one horizontal. Each describes about two-thirds of the circumference of a circle and their lumina are flattened in their planes of curvature. Each canal communicates with the vestibule by two openings, a wider ampullated and a narrower simple one, but the two vertical canals are united for a certain distance to form a common, non-ampullary limb, so that there are really only five openings into the vestibule. The *superior* (anterior vertical) *canal* is perpendicular to the axis of the pyramid of the temporal bone and, accordingly, parallel to its transverse diameter. It is also higher than the others, the highest point of its curve lying immediately beneath the arcuate eminence of the anterior surface of the pyramid. It begins at its anterior end with an ampullary limb, dilated to form the *superior ampulla* and at its posterior end forms with the posterior canal the *common limb*. It is narrower and longer than the lateral canal but somewhat broader and shorter than the posterior.

The second vertical canal, the *posterior*, is almost parallel to the posterior surface of the pyramid of the temporal bone and is at right angles to the superior canal. Its strongest curvature looks backwards and downwards. It begins at the vestibule by an ampullary limb, its ampulla opening on the lower wall of the vestibule at some distance from the other two ampullae. Its upper end unites with the posterior end of the superior canal to form the common limb. The posterior canal lies more deeply than the superior; it is the most strongly curved of all the semicircular canals and is consequently the longest, but also the narrowest.

The horizontal *lateral canal* lies horizontally in the angle formed by the two vertical canals. It is by far the shortest of the three, but also the broadest. Furthermore, it has two separate openings into the vestibule; the ampullary limb is the anterior one and begins in the lateral ampulla, close beside the superior ampulla and forming the prominence of the lateral canal; the posterior limb opens into the vestibule below the common limb. The apex of the curvature of the canal looks laterally and somewhat backwards.

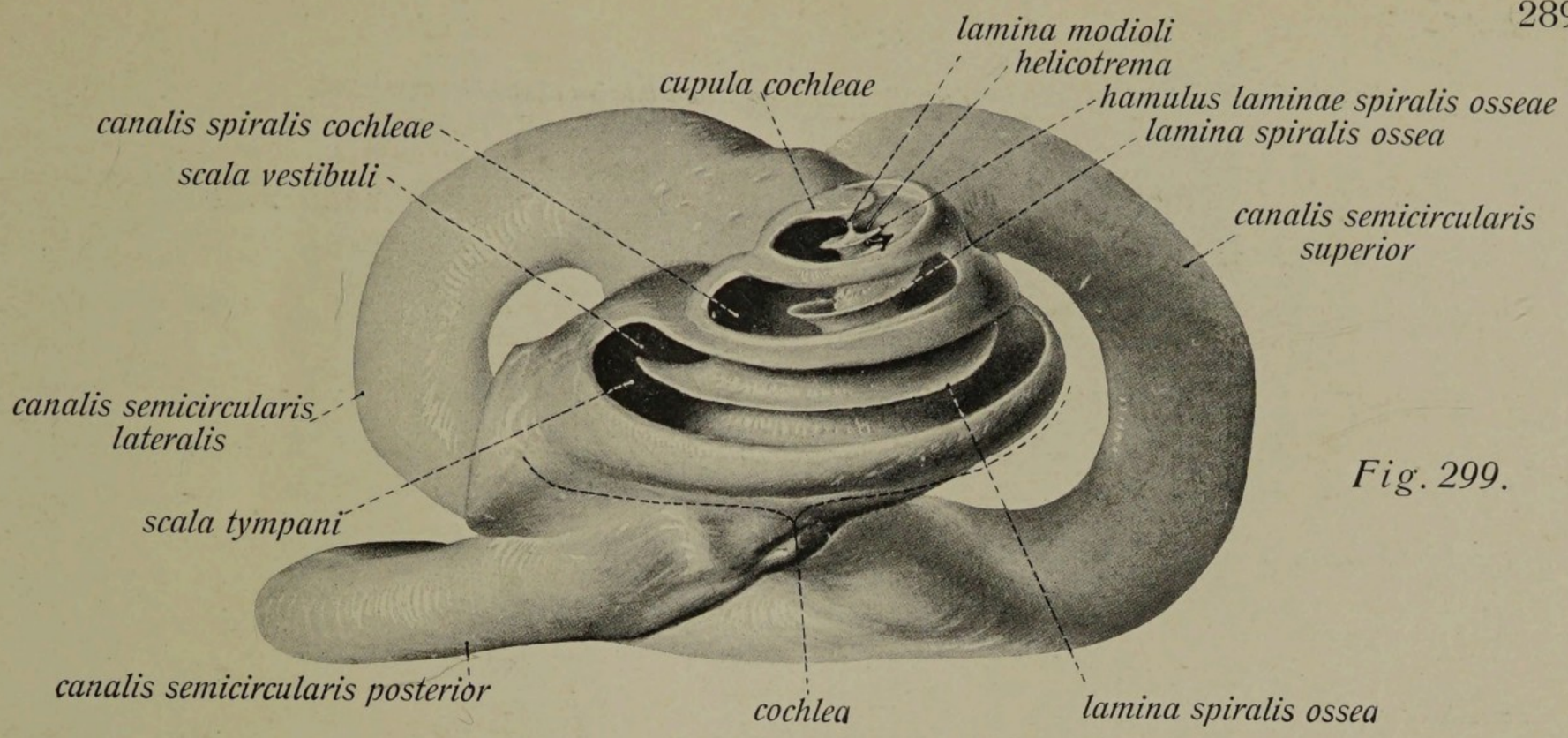

Fig. 299.

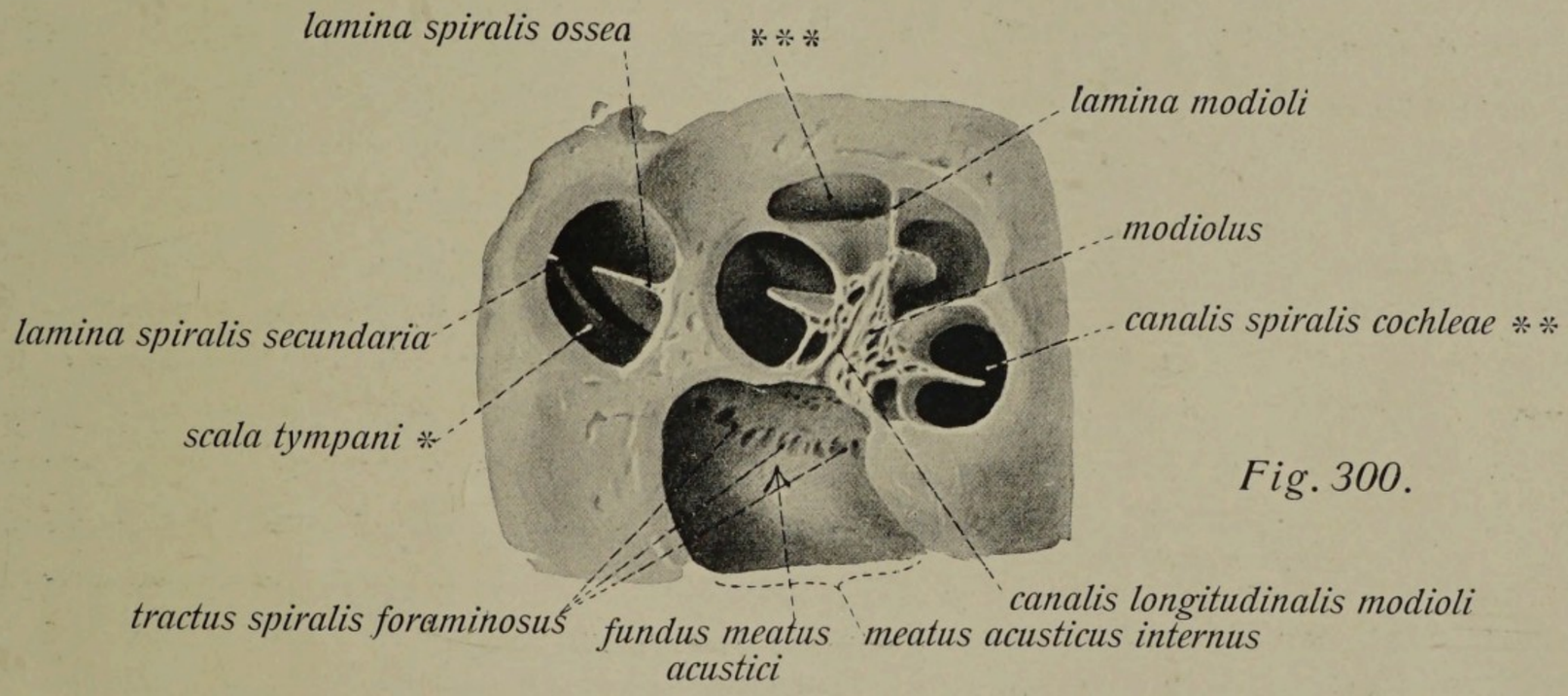

Fig. 300.

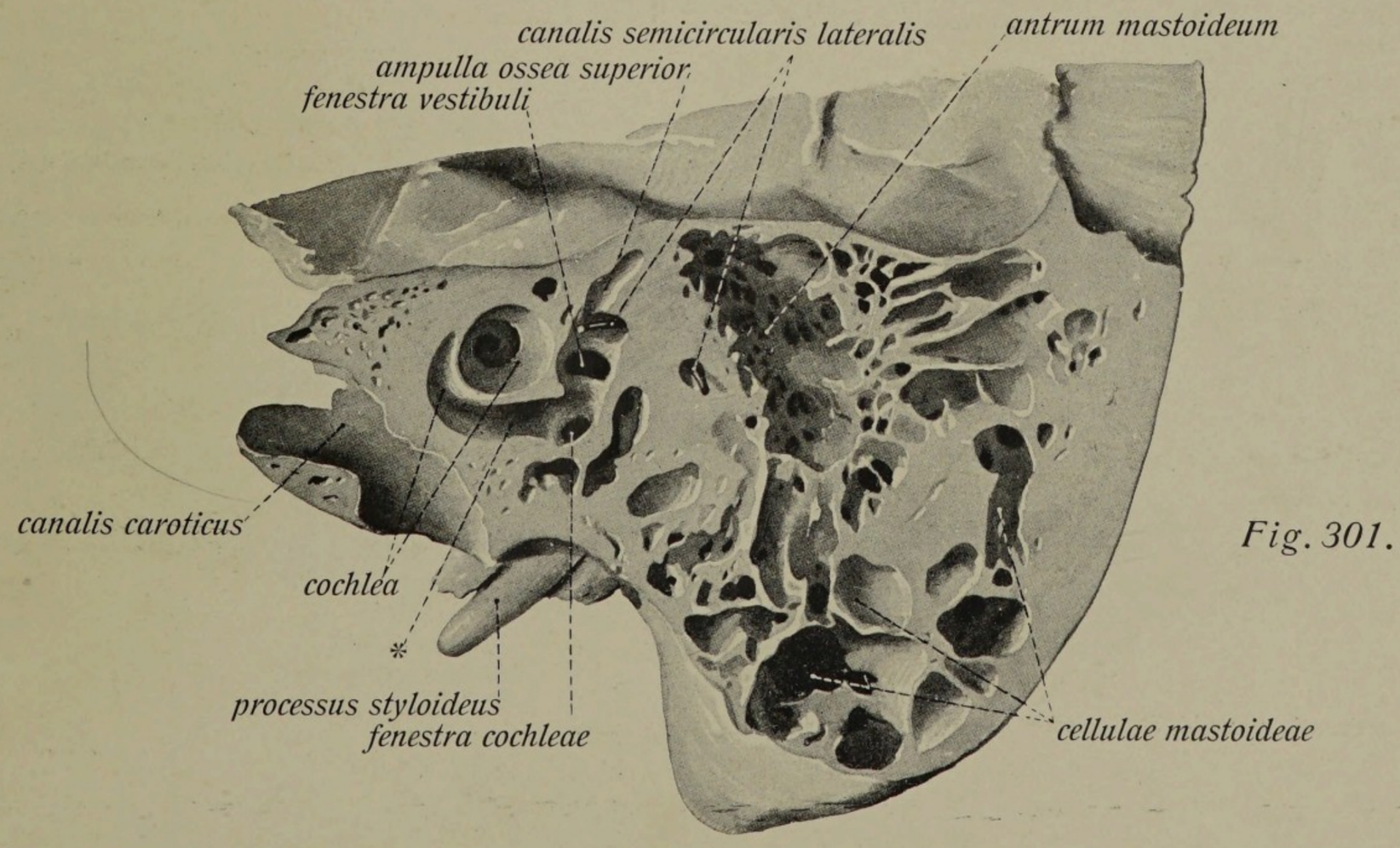

Fig. 301.

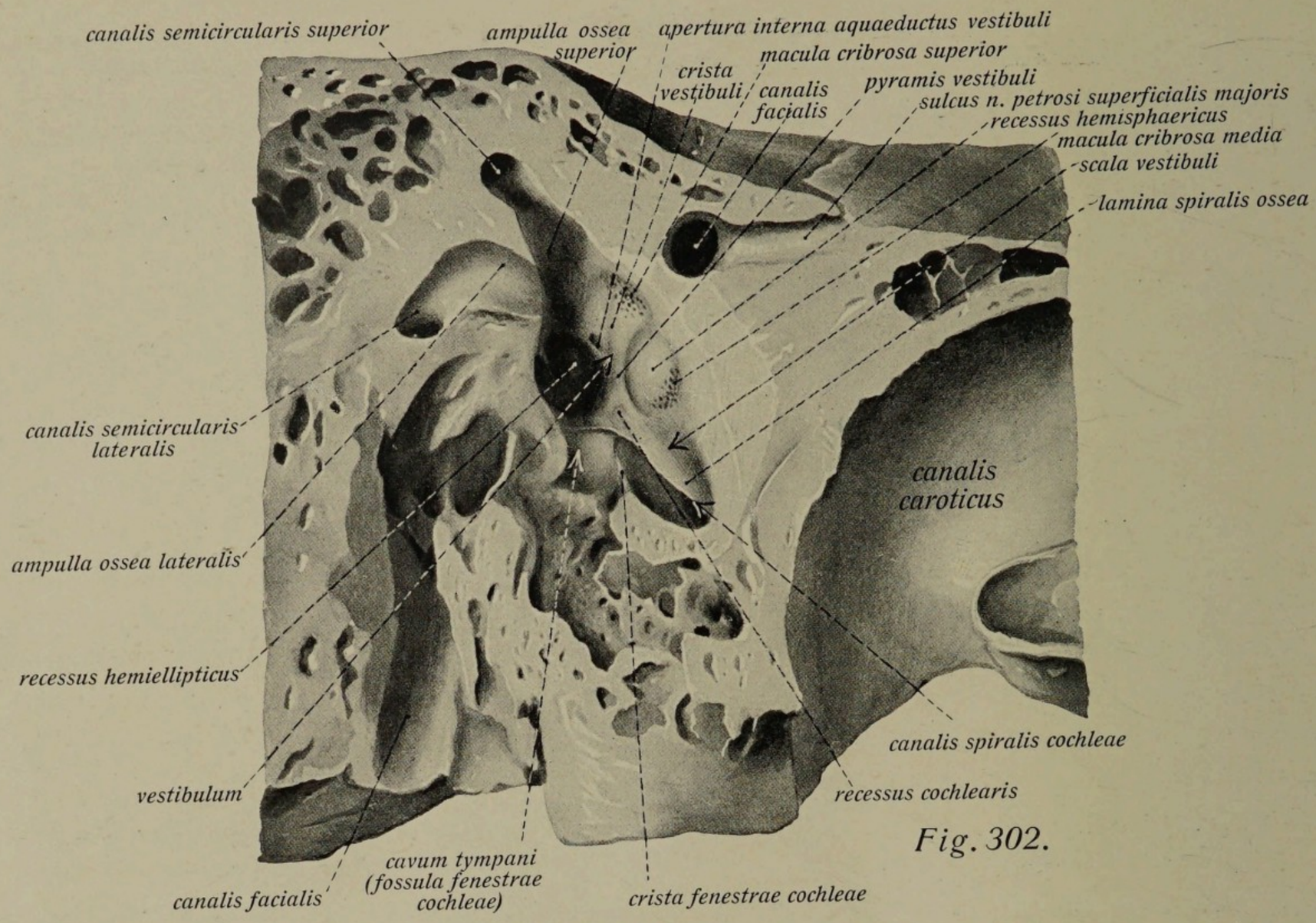

Fig. 302.

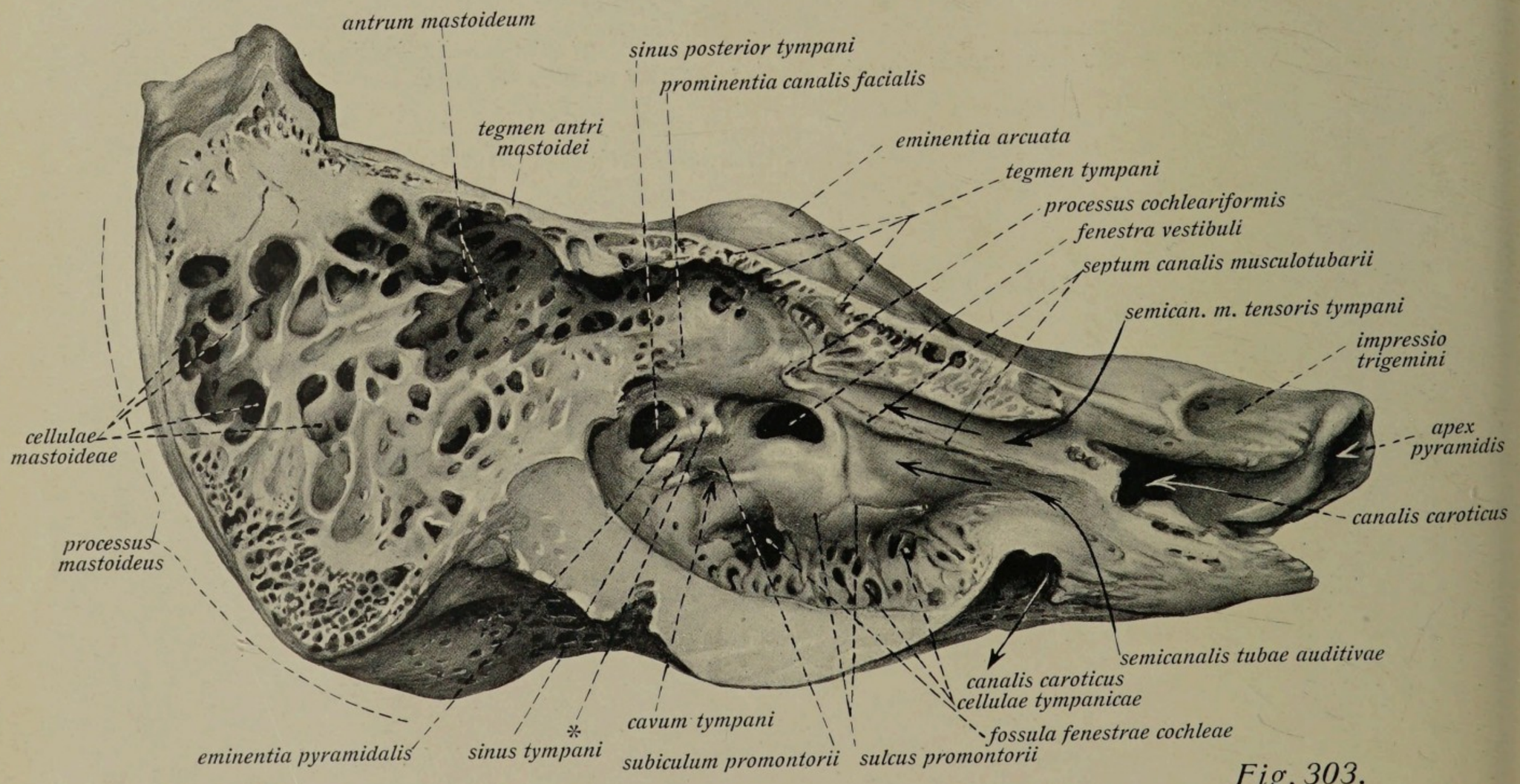

Fig. 303.

The Ear. The Labyrinth and Tympanic Cavity.

Fig. 302. The right vestibule exposed by removal of its lateral wall. ($^3/_1$)

Fig. 303. The right tympanic cavity and mastoid antrum as shown by a section almost parallel with the axis of the pyramid of the temporal bone. ($^2/_1$)
* = opening of the pyramidal eminence for the tendon of the Stapedius.

The Vestibule.

The vestibule is the middle portion of the bony labyrinth, situated between the semicircular canals and the cochlea. Its medial wall borders upon the internal auditory meatus and its lateral wall on the tympanic cavity, an opening on this wall, the *fenestra vestibuli (ovalis)*, placing this cavity in communication with the vestibule (see also p. 292).

On the anterior wall is an almost vertical, low ridge, the *vestibular crest*, which separates a small, round, anterior (and inferior) depression, the *hemispherical recess*, from a larger elongated, posterior (and superior) one, the *hemielliptic recess*. The former lodges the sacculus, the latter the utriculus. The vestibular crest terminates above in a sharp projection, the *pyramid*, and below in two limbs that bound a flat depression. This depression, the *cochlear recess*, is really in the lower wall of the vestibule, close to the beginning of the spiral lamina (see p. 287); it lodges the vestibular caecum of the cochlear duct (see p. 284).

In addition to the kidney-shaped *fenestra vestibuli (ovalis)* and the round *fenestra cochleae (rotunda)*, there are other openings in the wall of the vestibule for the passage of branches of the acoustic nerve. In the lateral wall, in the region of the hemispherical recess, there is a number of small foramina, forming the *middle macula cribrosa*, through which pass nerve twigs for the macula acustica of the sacculus. A similar area, the *superior macula cribrosa*, lies at the upper end of the vestibular crest for the utriculo-ampullary nerve, while the smallest, the *inferior macula cribrosa*, which corresponds to the foramen singulare, is situated beside the ampulla of the posterior semicircular canal, on the lower surface of the vestibule. The five openings of the semicircular canals open into the posterior portion of the vestibule, three being ampullary openings and two non-ampullary (see p. 288). The latter lie in the medial wall of the vestibule, that of the lateral canal below that of the common limb. The ampulla of the posterior canal is on the lower wall; the other two ampullae are close together at the boundary between the posterior and lateral walls.

Furthermore the spiral canal of the cochlea opens on the anterior wall and the vestibular aquaeduct on the medial wall by an elongated fine slit.

The Ear. The Tympanic Cavity.

Fig. 304. The right tympanic cavity, opened by the removal of the lateral wall and adjacent parts of the anterior and upper walls. From the lateral side and in front. (About $^2/_3$ enlarged)

Fig. 305. The right tympanic cavity after further removal of the bone. (Enlarged about $^2/_3$) The carotid, facial and musculo-tubar canals are opened, the external auditory meatus is completely removed and the mastoid cells are opened. * = opening on the pyramidal eminence. ** = cavity of the pyramidal eminence for the Stapedius.

The Tympanic Cavity.

The **medial** *(labyrinthic)* **wall** of the tympanic cavity presents its most important structures. At about its middle is the *fenestra vestibuli (ovalis)*, which is kidney-shaped, convex above and concave below, and lies in a niche-like depression, the *fossula* of the fenestra vestibuli. Immediately beneath the fenestra is a rounded eminence, the *promontory*, formed by the basal coil of the cochlea, and over its surface a groove runs from above downwards. Below and behind the promontory and almost concealed by it is a second, roundish opening, *the fenestra cochleae (rotunda)*, in a rather deep depression, the *fossula* of the fenestra cochleae, its sharp border being termed the *crest* of the fenestra rotunda. The fossula is bounded posteriorly by a ridge-like swelling that has its origin at the fenestra vestibuli (ovalis), the *subiculum* of the promontory. Above it is a small depression, the *tympanic sinus*, and near the anterior end of the fenestra vestibuli (ovalis) there is a curved, spoon-like projection, the *cochleariform process*, which is the free end of the septum of the musculo-tubar canal.

The **posterior** *(mastoid)* **wall** of the cavity is mostly occupied by the openings of the mastoid cells, the largest of these cavities, opening directly into the tympanic cavity, being termed the *mastoid antrum*. In addition there is on the posterior wall, above the fenestra vestibuli (ovalis) a distinct, elongated projection, the *prominence of the facial canal*. Above this is a stronger eminence, the *prominence of the lateral semicircular canal*, corresponding to the ampulla of that canal. Behind the fenestra vestibuli (ovalis) and in front of the lower portion of the prominence of the facial canal is a small, conical, hollow elevation, the *pyramidal eminence*. Above this is a small but deep depression, the *posterior sinus*, and above this again a shallow depression, the *fossa incudis*, for the short limb of the incus. In addition, on this wall is the opening for the passage of the chorda tympani into the tympanic cavity.

The **anterior** *(carotid)* **wall** possesses the opening of the musculo-tubar canal and also the small openings of the carotico-tympanic canaliculi from the carotid canal. The **lateral** *(membranaceous)* **wall** is essentially a round opening closed by the tympanic membrane and above this by a small plate of bone, behind which is the head of the malleus and a part of the body of the incus. The **upper** *(tegmental)* **wall** has a shallow depression, the *epitympanic recess*, which deepens dome-like towards the lateral wall to form the *pars cupularis*. The **lower** *(jugular)* **wall** frequently shows opposite the point of attachment of the styloid process a low tubercle, the *styloid prominence*. On all the walls of the tympanic cavity, except on the promontory and the epitympanic recess, there are groovelike depressions, the *tympanic cellules*, which extend as the *tubar cellules* into the beginning of the tuba auditiva.

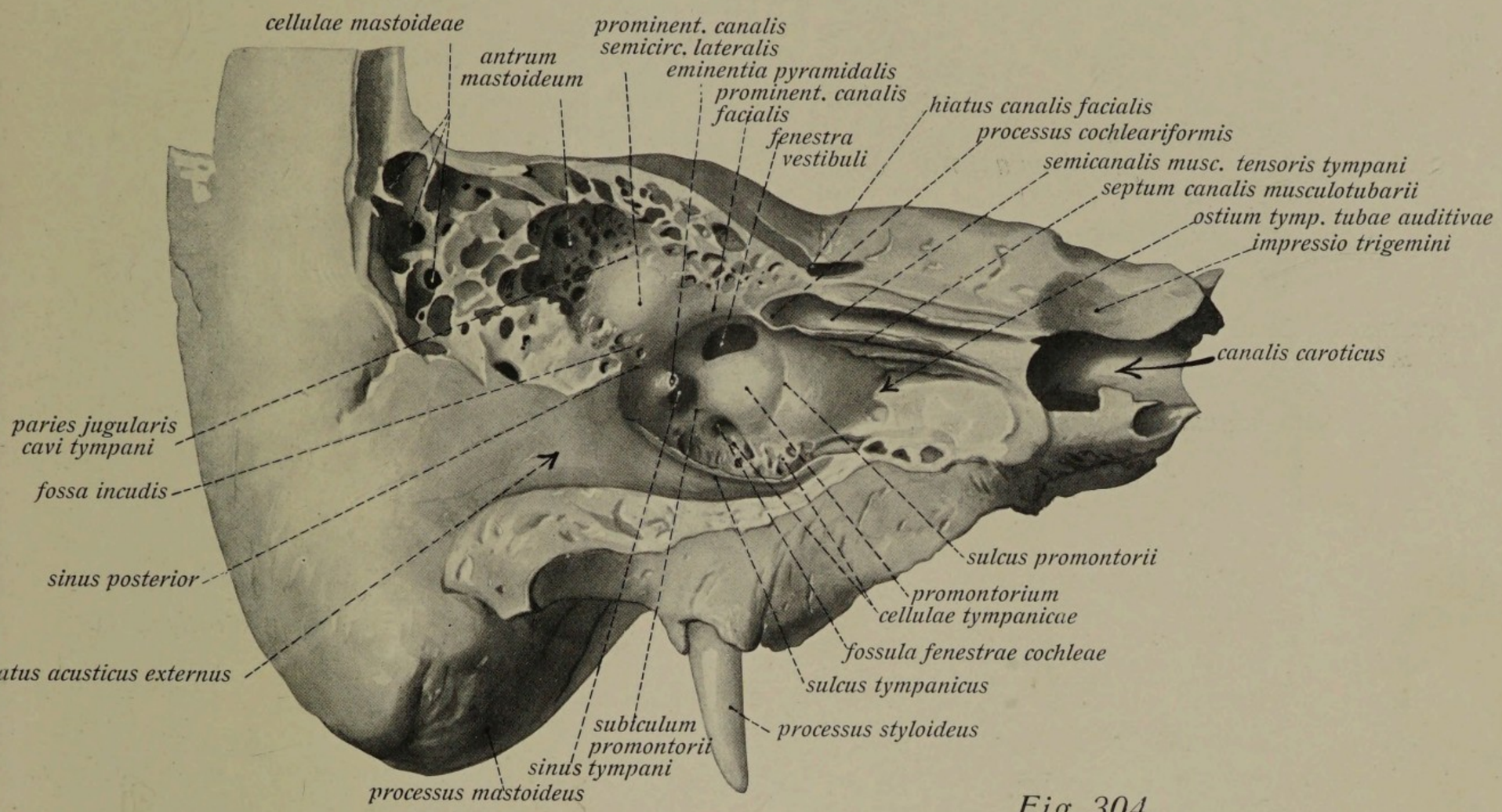

Fig. 304.

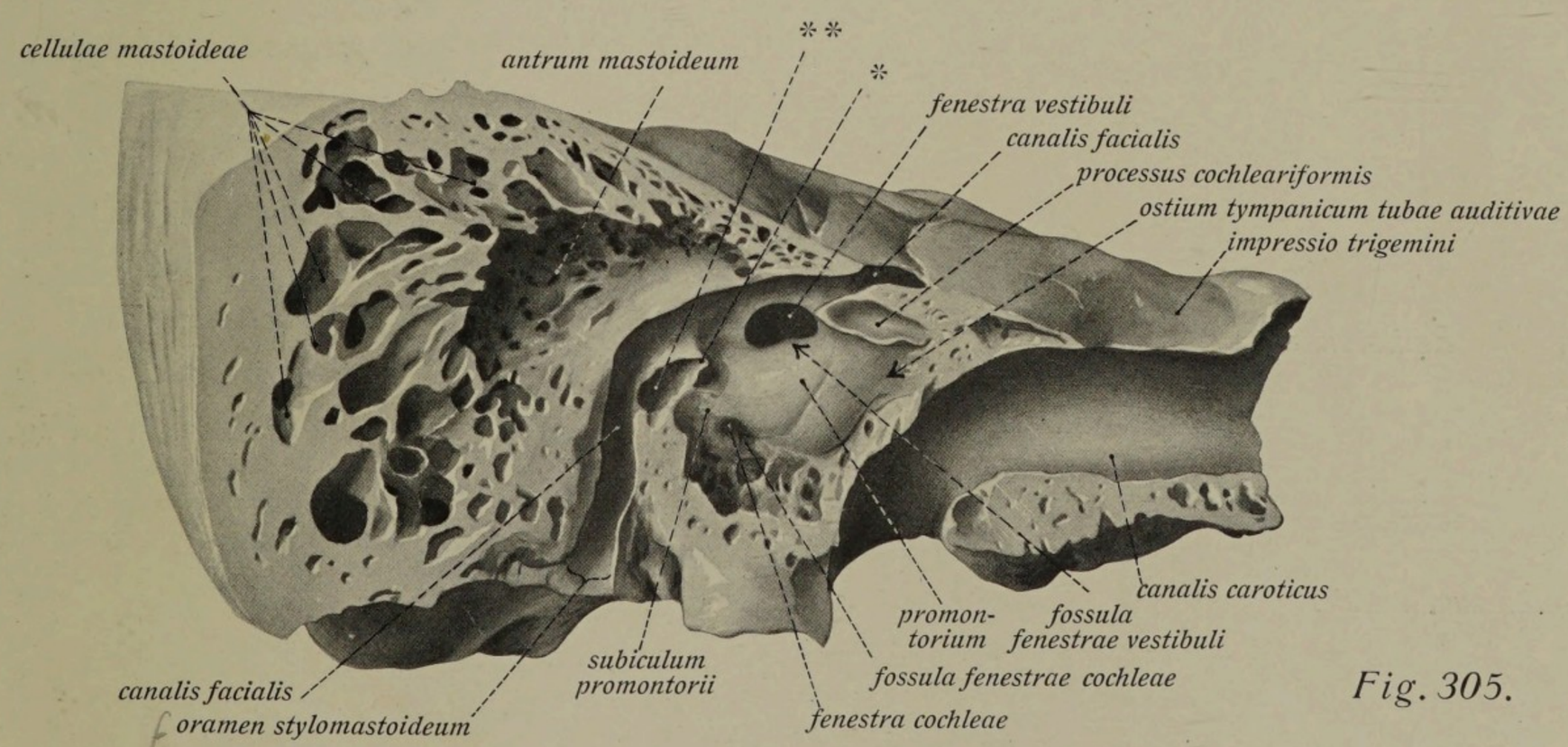

Fig. 305.

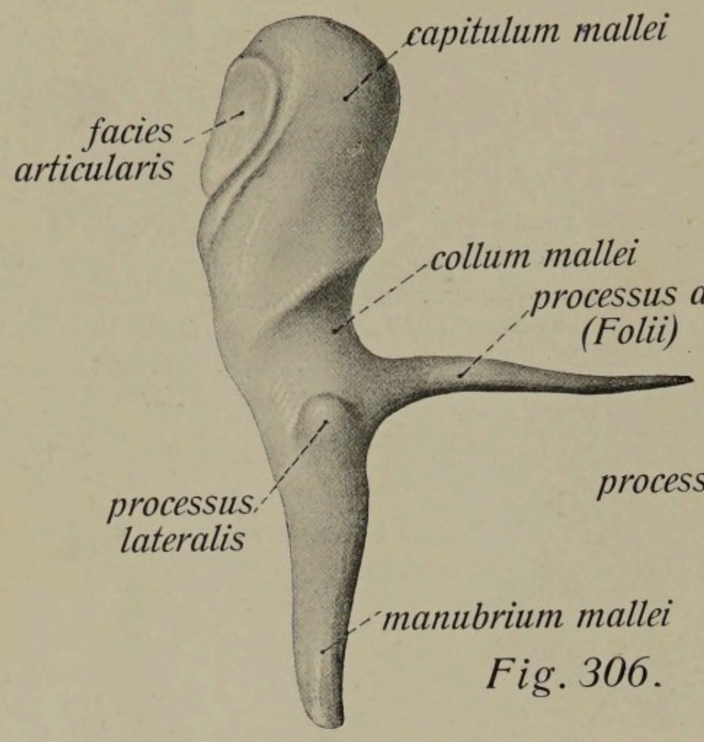

Fig. 306.

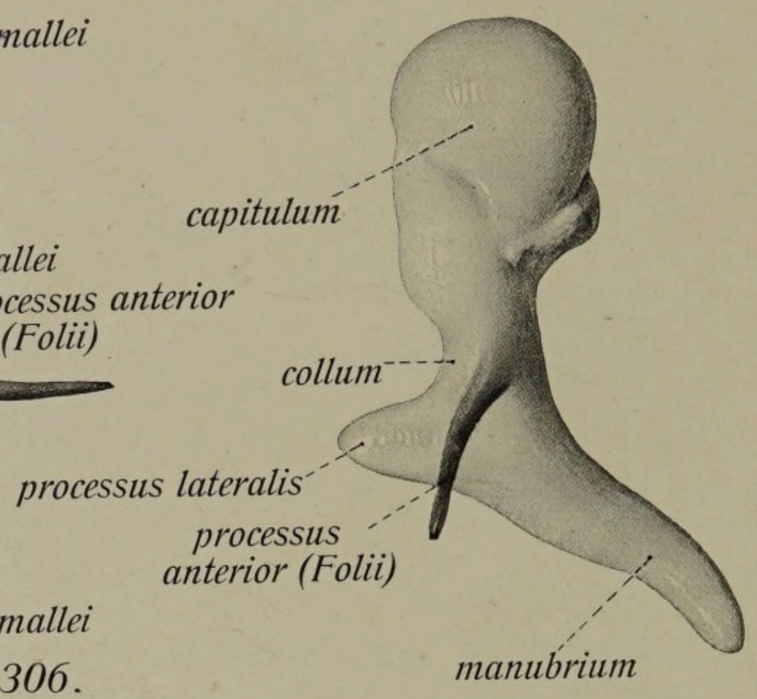

Fig. 307.

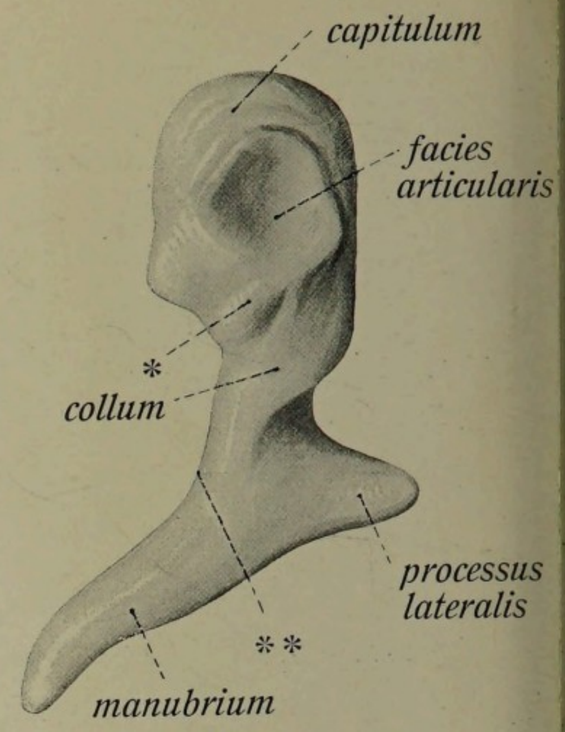

Fig. 308.

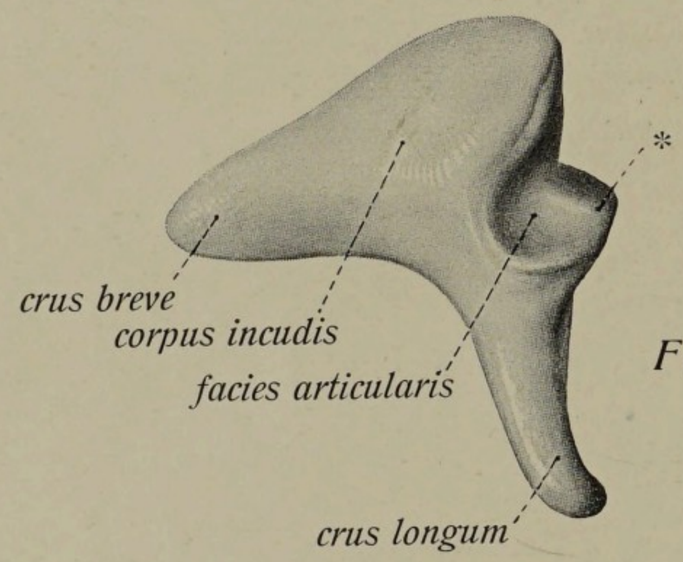

Fig. 309.

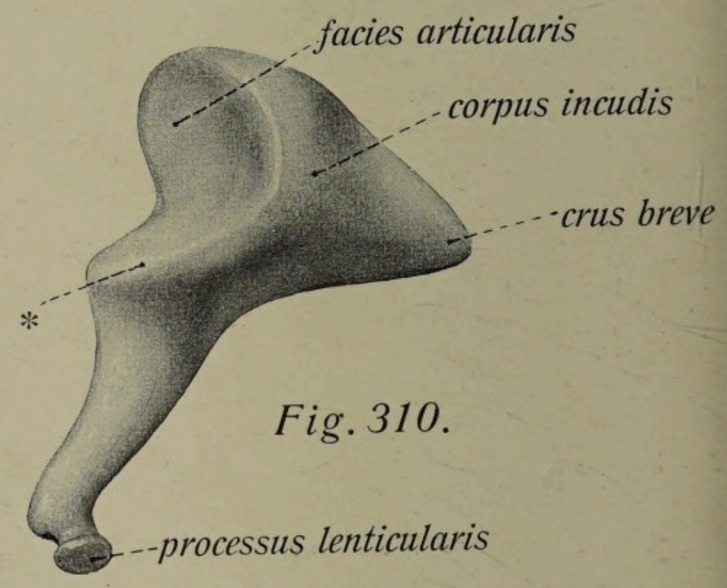

Fig. 310.

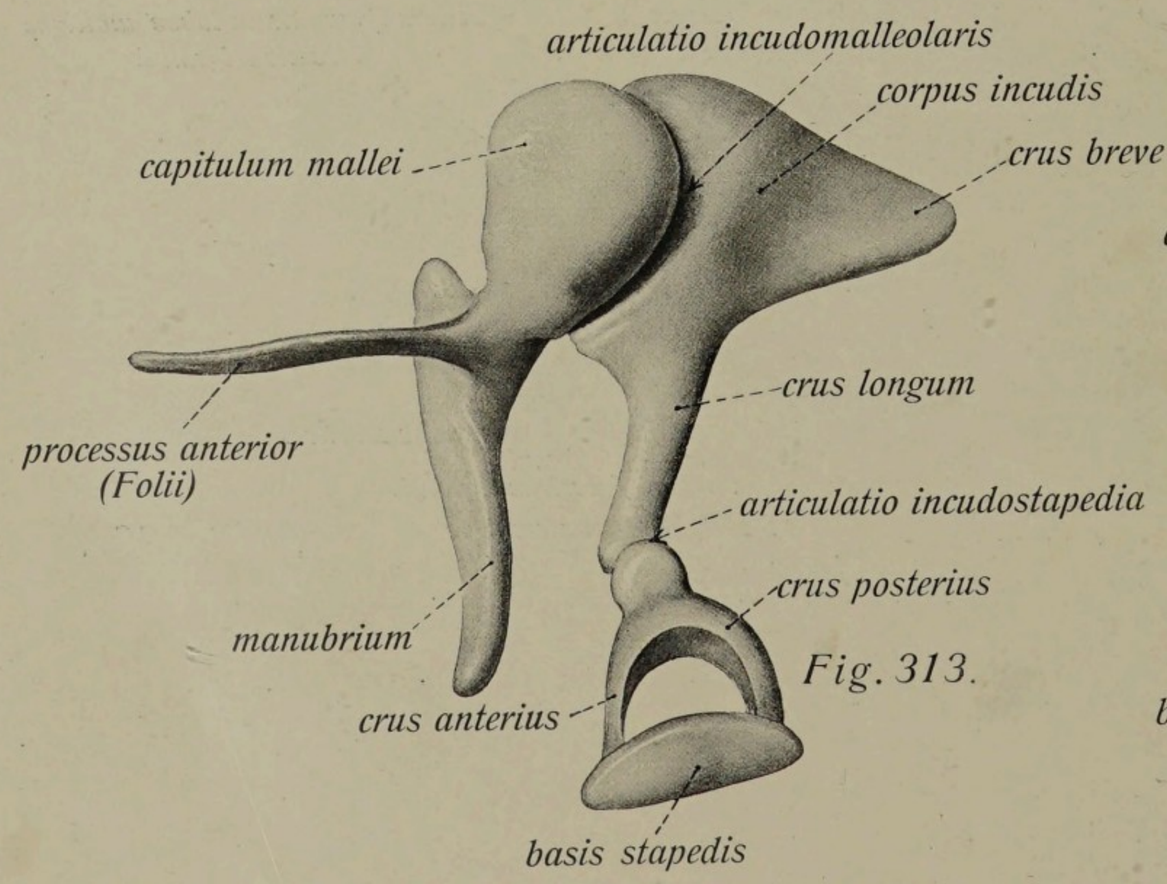

Fig. 313.

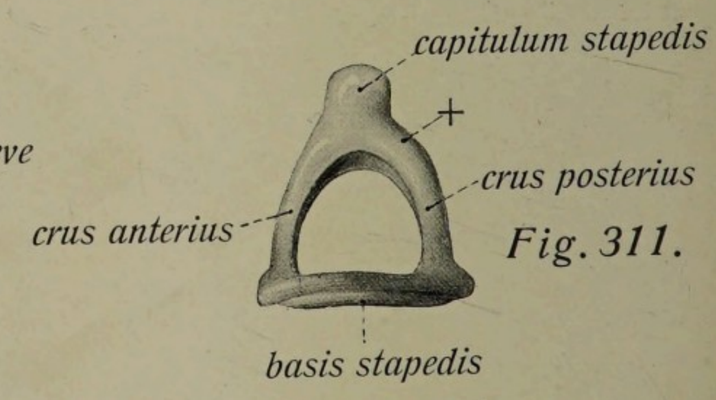

Fig. 311.

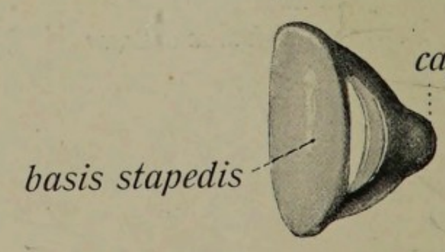

Fig. 312.

The Ear. The Auditory Ossicles.

Fig. 306. The right malleus from the lateral side. (7/1)
Fig. 307. The right malleus from in front. (7/1)
Fig. 308. The right malleus from behind. (7/1)
Fig. 309. The right incus from the lateral side. (7/1)
Fig. 310. The right incus from the medial side. (7/1)
Fig. 311. The right stapes from above. (7/1)
Fig. 312. The right stapes from the medial side and below. (7/1)
Fig. 313. The right auditory ossicles of a child. (7/1)
* = the spur of the malleus. ** = attachment of Tensor tympani. + = attachment of Stapedius.

The Auditory Ossicles.

The *malleus* has the form of a mallet. It has a rounded head *(capitulum)*, a constriction below this, the neck *(collum)*, and a handle *(manubrium)*, as well as two processes. The head is rounded at its upper end and on its posterior surface has an articular facet for the incus. The neck is below this facet. The manubrium lies approximately in the line of prolongation of the head and is a long cylindrical rod of bone which is attached throughout its entire length to the tympanic membrane, its end corresponding to the umbo of the membrane. It is not actually a direct prolongation of the head and neck, but forms with this an angle of 125—150°. Of the two processes of the malleus the *lateral process* lies at the base of the manubrium, where it forms a short thick process, which produces the malleolar prominence of the tympanic membrane. The *anterior (Folian) process* is a long, thin, spicule of bone, usually much longer in the new-born child than in the adult, where it is occasionally quite rudimentary. It arises from the anterior surface of the neck and extends towards the petro-tympanic fissure, imbedded in the anterior ligament of the malleus (see p. 296).

The *incus* has almost the shape of a molar tooth, with two roots of unequal length. It has a body *(corpus)* and two limbs *(crura)* that taper towards their ends. The body looks forward and has on its surface a saddle-shaped depression for the reception of the malleus. The *long crus* lies almost parallel and medial to the manubrium of the malleus, but behind it. It is shorter than the manubrium and bears at its end a disk-shaped enlargement, the *lenticular process*. The *short crus* looks towards the tympanic antrum and is almost horizontal. Its blunt end rests in the fossa incudis of the tympanic cavity.

The *stapes* corresponds in shape very perfectly to its name (stirrup). It consists of a flat, oval foot-plate *(basis)*, which fits into the fenestra vestibuli (ovalis), and two limbs *(crura)*, which pass almost horizontally from the two ends of the foot-plate, a somewhat shorter, less curved *anterior crus* and the more strongly curved, *posterior crus*. These meet at the head *(capitulum)* of the stapes. The bone has a small articulating surface for the lenticular process of the incus.

Fig. 314. The right tympanic cavity opened from above. (5/1) The tegmen tympani, the upper wall of the musculo-tubar canal and the roof of the mastoid antrum have been removed; a small portion of the facial nerve in the vicinity of the geniculum has been exposed * = folds of the mucous membrane of the antrum.

Fig. 315. General view of the right middle and internal ear (from Schultze-Lubosch, Topogr. Anatomie). The temporal bone is divided after having been decalcified; the tendon of the Tensor tympani is divided and also the joint between the stapes and incus. The two halves of the preparation are separated in the region of the tympanic cavity. The course of the facial and acoustic nerves and the relation of the labyrinth to the tympanic cavity and its walls are shown.

The Joints and Ligaments of the Auditory Ossicles.

The three auditory ossicles are united by two articulations. The articulation of the malleus with the incus is a saddle-shaped joint. The head of the malleus has a markedly convex articular surface, covered by cartilage, and the surface of the body of the incus is correspondingly concave; a delicate articular capsule encloses the two surfaces. Each of the two surfaces possesses, in addition, a spur-like process below it. The joint between the incus and stapes is between the lenticular process of the incus and the capitulum of the stapes. It is an ellipsoid joint, approximating a ball and socket. The stapes lies with the plane uniting its two crura almost at right angles to the long axis of the long crus of the incus.

In addition to these articulations there is the so-called *tympano-stapedial syndesmosis*, the union of the base of the stapes with the fenestra vestibuli (ovalis). The fenestra is closed by the periosteum of the tympanic cavity and the small space between its bony margin and the base of the stapes is filled by ligament.

For the fixation of the malleus there are three ligaments. The *superior* (Fig. 315, 317, 318) fastens the head of the malleus in the epitympanic recess to the under surface of the tegmen tympani. The *lateral* (Fig. 314) passes from the margin of the tympanic membrane to the malleus, where it inserts at the base of the two processes of the bone. The *anterior* surrounds the anterior (Folian) process of the malleus and seems to be a continuation of this; it passes to the petro-tympanic fissure and through this to the angular spine of the sphenoid bone. In addition, the manubrium is attached to the tympanic membrane.

The incus is held in position by the following ligaments. The *superior* (Fig. 317, 318) extends from the body of the incus to the roof of the tympanic cavity; the *posterior* (Fig. 314—318) is a short dense ligament fastening the short crus of the incus in the fossa incudis of the tympanic cavity.

A thin membrane stretched between the two limbs of the stapes is termed the *obturator membrane* (Fig. 319).

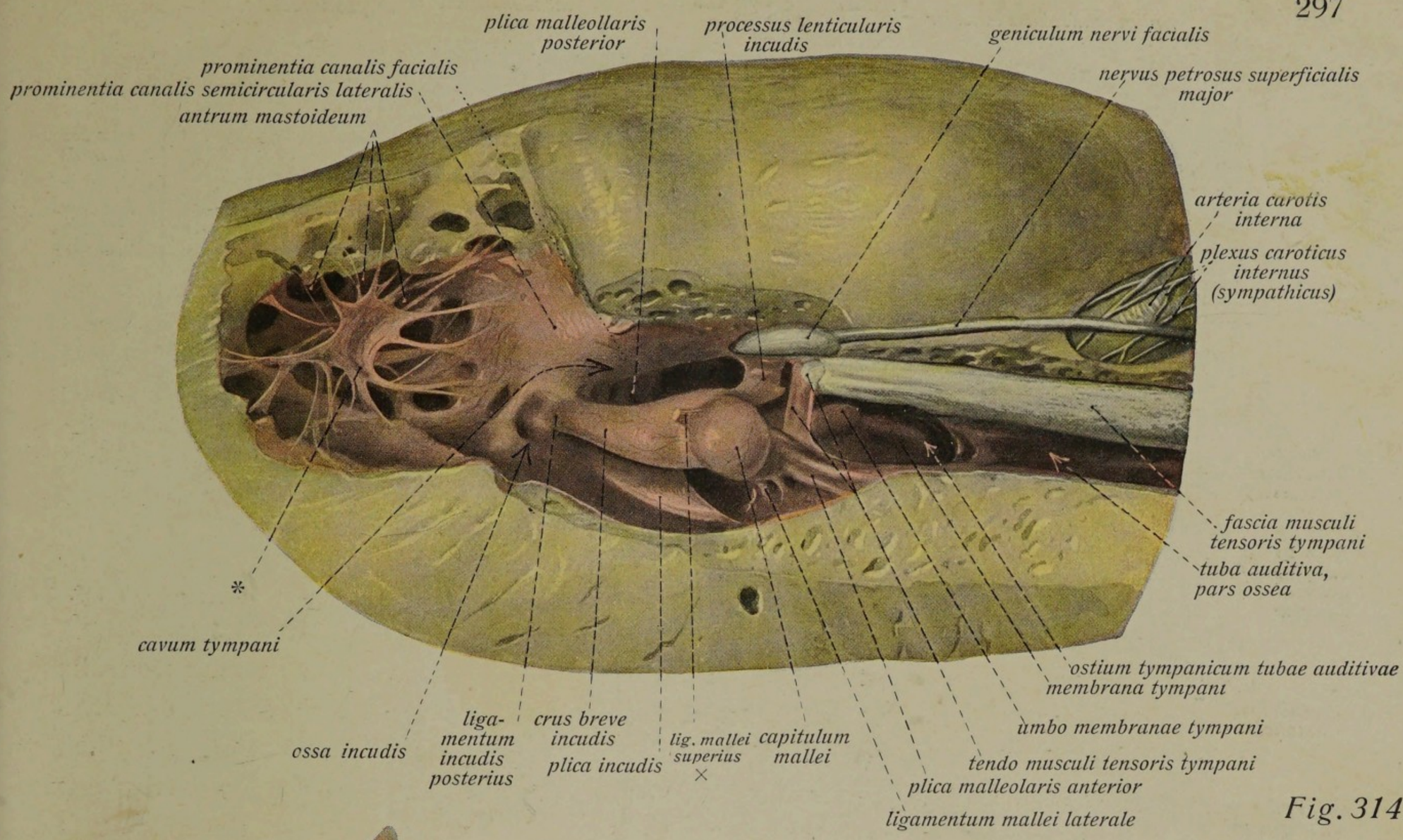

Fig. 314.

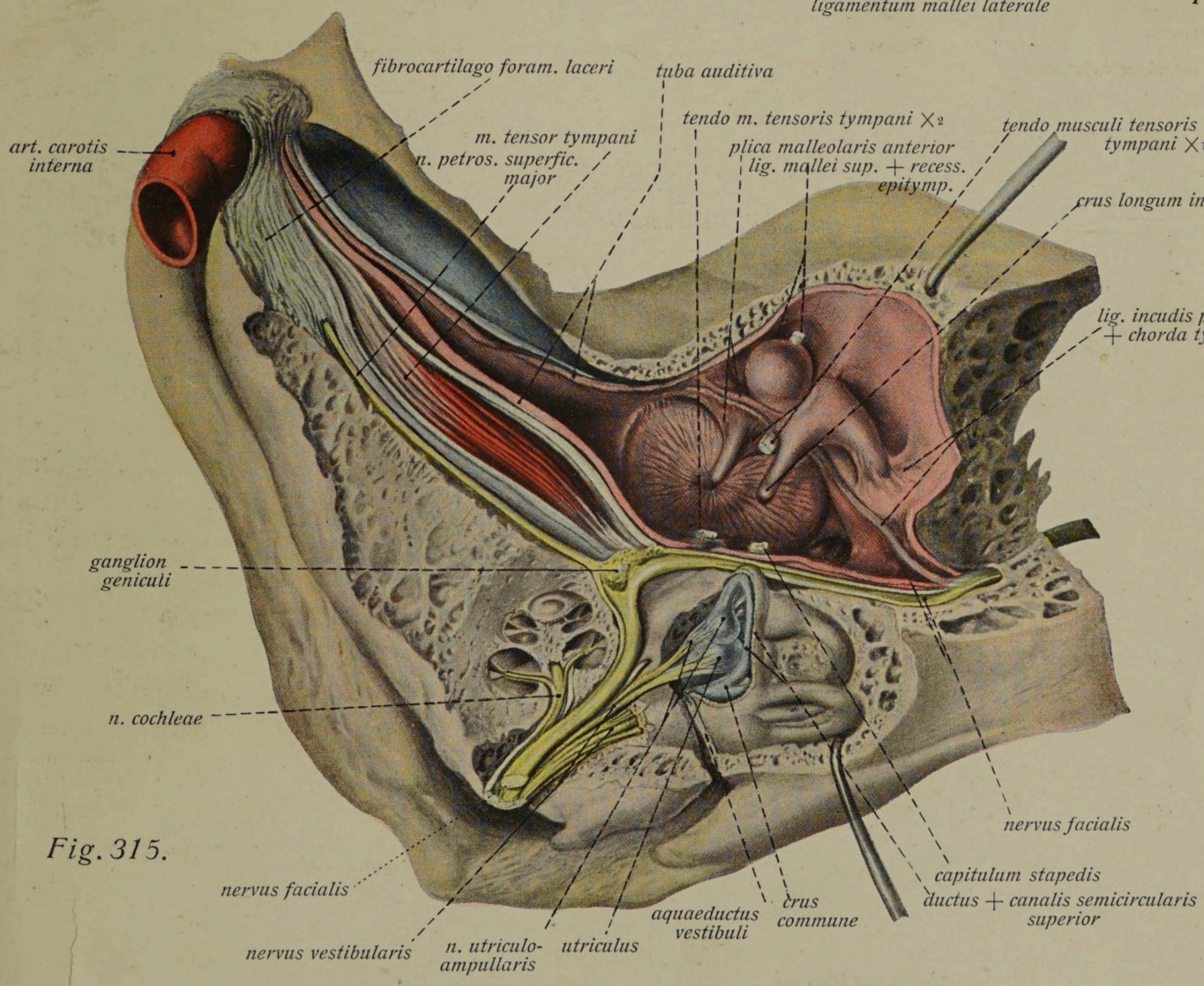

Fig. 315.

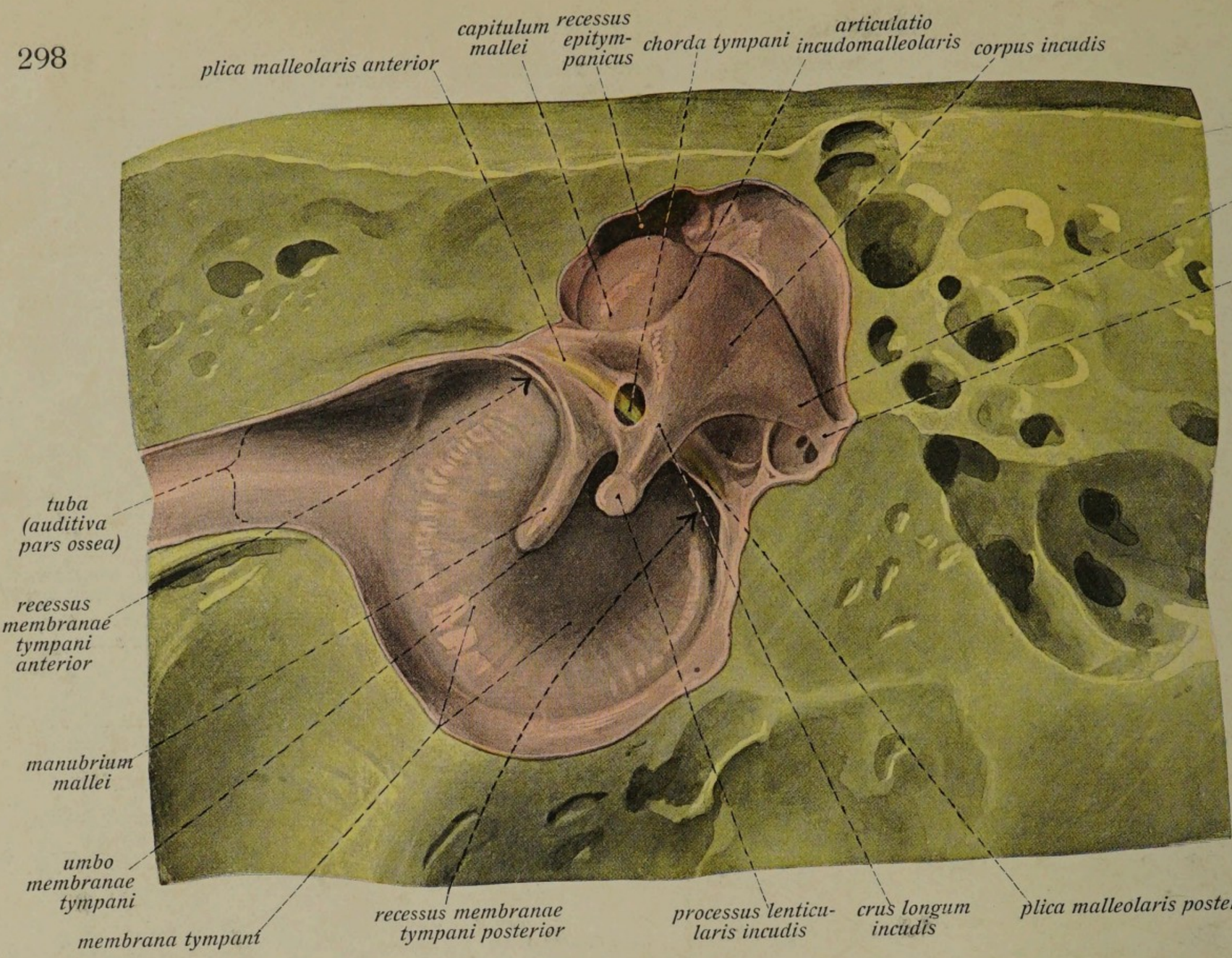

Fig. 316.

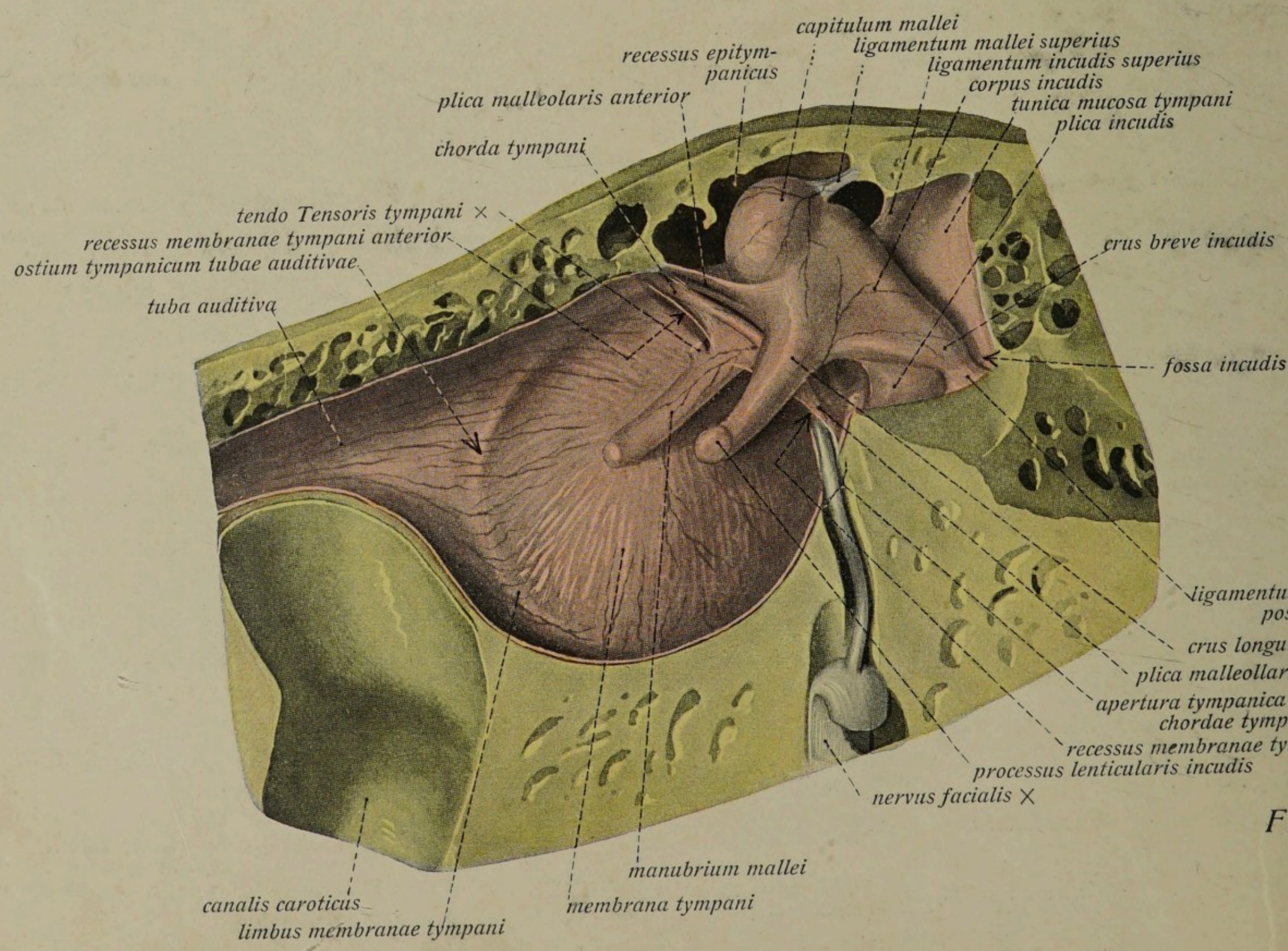

Fig. 317.

The Ear. The Middle Ear. (Cont.)

Fig. 316. The lateral wall of the right tympanic cavity from the medial side. (5/1)

The malleus, incus, tympanic membrane and tuba auditiva (Eustachian tube) are shown in position, the medial wall of the tympanic cavity being removed by a section almost parallel to the tympanic membrane; the canal for the Tensor tympani and the muscle have also been cut away, as well as the insertion of the tendon into the malleus.

Fig. 317. The lateral wall of the right tympanic cavity from the medial side. (5/1)

Preparation in general as in Fig. 316, but the bone is cut so as to expose the chorda tympani and the foramen by which it enters the tympanic cavity. The tendon of the tensor tympani is cut close to the malleus.

The Muscles of the Auditory Ossicles.

The **Tensor tympani** is an elongated muscle which lies in a canal forming the upper part of the musculo-tubar canal. It arises from the walls of its canal, and also from the cartilage of the tuba auditiva (Eustachian tube) and the neighborhood of the spheno-petrous fissure. As it runs through its canal it is enclosed by a strong layer of periosteum (Fig. 323) until it almost reaches the tympanic cavity. At the root of the cochleariform process it becomes converted into a round tendon, which, running through the spoon-like concavity of the process, bends almost at a right angle and passes almost transversely through the tympanic cavity to be inserted on the medial side of the base of the manubrium of the malleus, opposite the lateral process. The muscle draws the tympanic membrane inwards towards the tympanic cavity and by doing so tenses it (Fig. 318—321, 323, 324).

The **Stapedius** (Fig. 320) is smaller than the Tensor tympani; indeed it is the smallest skeletal muscle in the body, hardly over 1 cm. in length. It has an elongated conical form and lies completely enclosed within the cavity of the pyramidal eminence, from whose walls it arises. It passes into a short, thin tendon, which passes through the small opening at the apex of the pyramid and is attached to the posterior crus of the stapes close to the capitulum. As it passes out of the cavity of the pyramid the tendon is bent downward somewhat. Its function is uncertain.

Fig. 318. Lateral wall of the right tympanic cavity from the medial side. (5/1)
The preparation differs from that of Fig. 316, 317 in that a much greater amount of the roof of the tympanic cavity is retained. In this way a greater length of the Tensor tympani is retained and is exposed as far as the cochleariform process by cutting away the greater portion of the septum of the musculo-tubar canal. The insertion of the muscle into the manubrium is thus rendered evident. The layer of periosteum ** (compare Fig. 323) is largely removed.

Fig. 319. The medial wall of the right tympanic cavity from the lateral side. (5/1)
In addition to the lateral, the upper wall is also removed, as well the greater part of the external auditory meatus. The tympanic membrane is removed except for a small fragment. The malleus and incus are removed and the chorda tympani cut where it enters the tympanic cavity. The septum of the musculo-tubar canal is partly cut away so as to show the Tensor tympani, whose tendon is cut near the cochleariform process. The facial nerve is exposed for a short distance near the geniculate ganglion.

The Mucous Membrane of the Tympanic Cavity.

The tympanic cavity (Fig. 314–322, 324) is lined throughout its entire extent by a very thin and delicate mucous membrane, which extends also into the mastoid antrum and into the mastoid cells, and becomes continuous with the pharyngeal mucous membrane through the tuba auditiva (Eustachian tube). In general it lies close upon the bony walls of the tympanic cavity and upon the auditory ossicles, and follows the outlines of these parts. But it also forms some folds projecting into the cavity. Many of these are variable, but in the vicinity of the tympanic membrane and malleus there are two strong, constant, semilunar folds. There is an *anterior malleolar fold* (Fig. 316), that contains the chorda tympani, the anterior ligament and process of the malleus; it arises from the greater tympanic spine (see p. 307) and is attached to the neck of the malleus. The *posterior malleolar fold* (Fig. 316—318) contains the chorda tympani after it has entered the tympanic cavity, and extends from the lesser tympanic spine to the neck of the malleus. It lies close to the tympanic membrane and is continuous in part with its mucous layer.

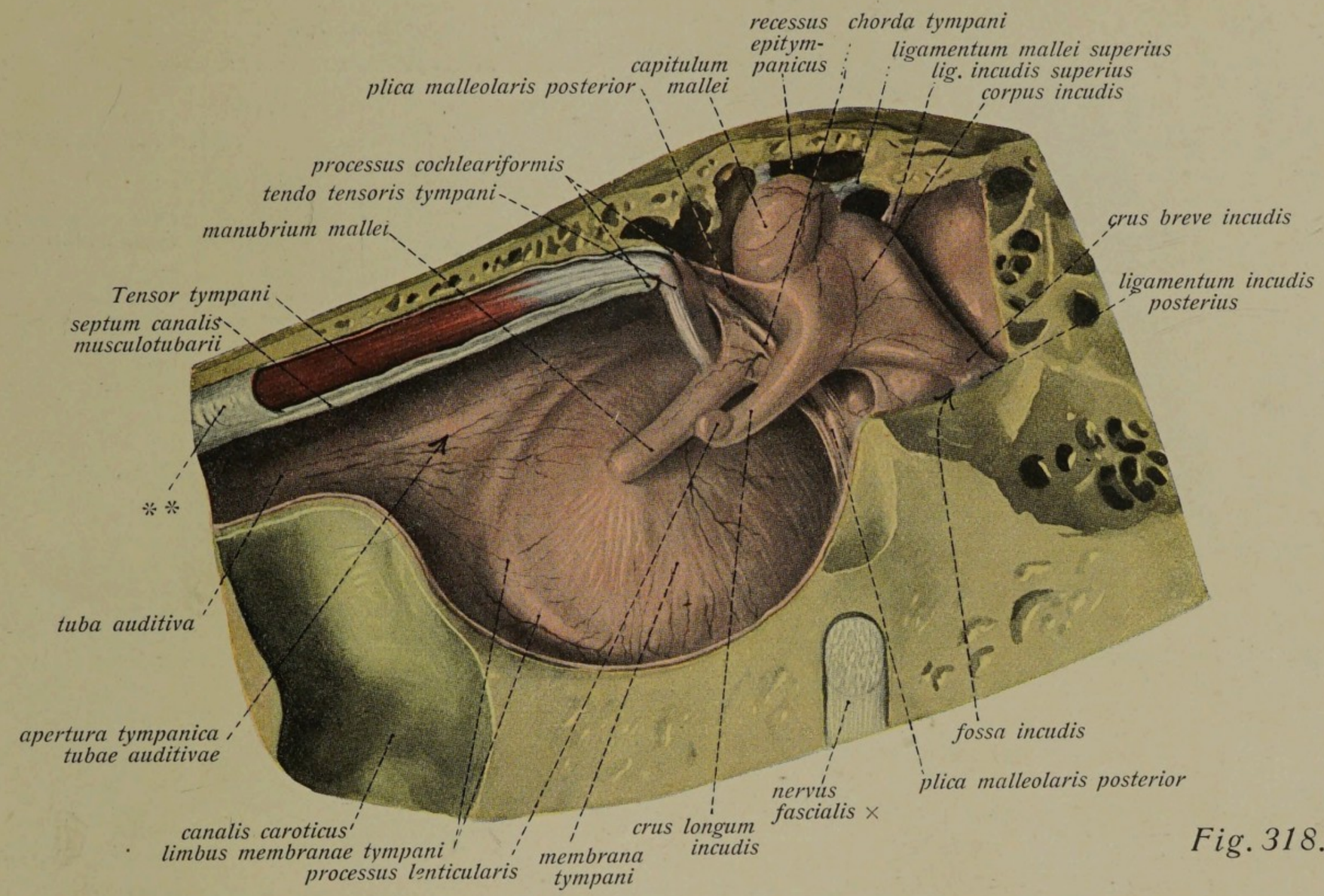

Fig. 318.

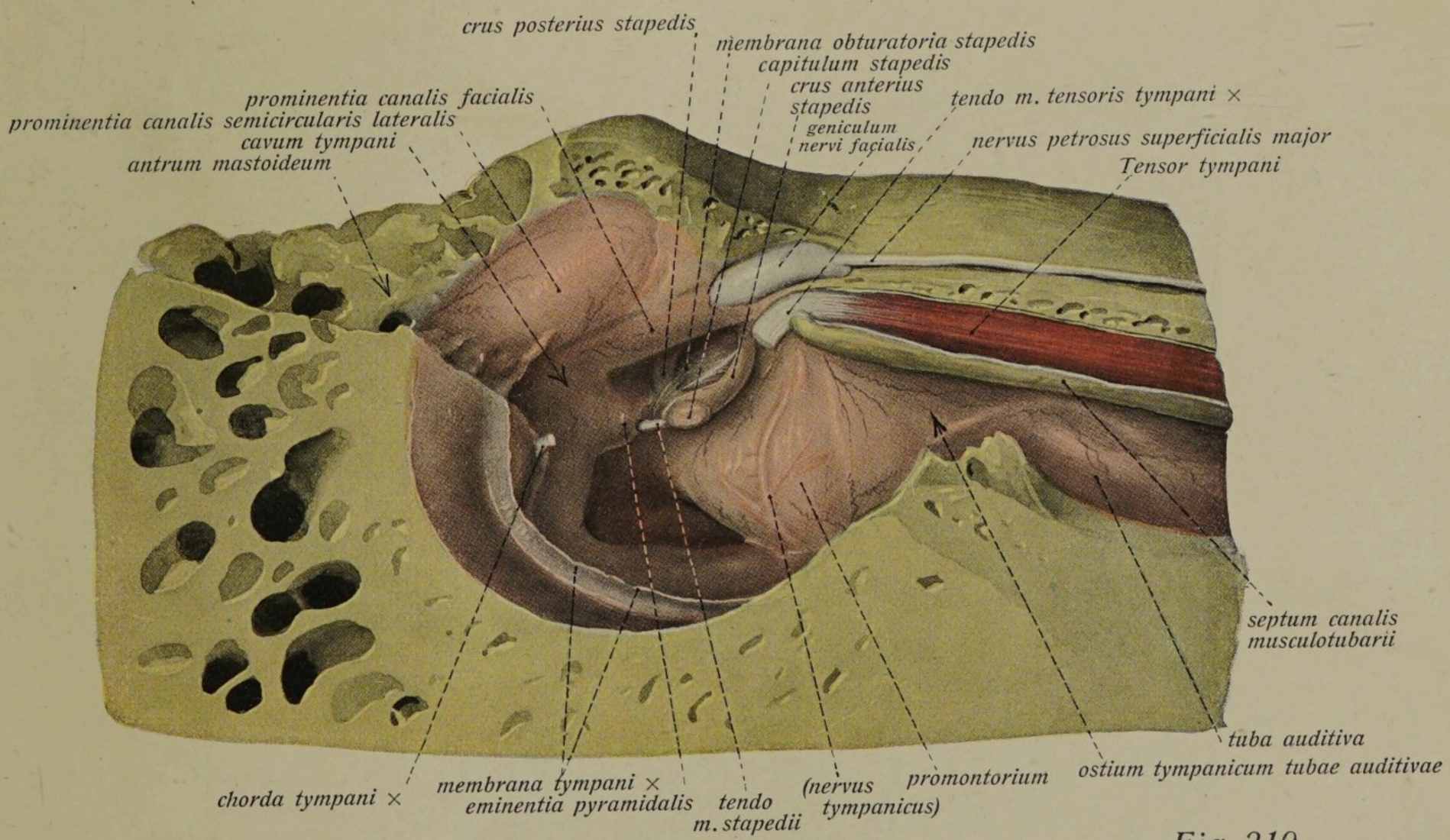

Fig. 319.

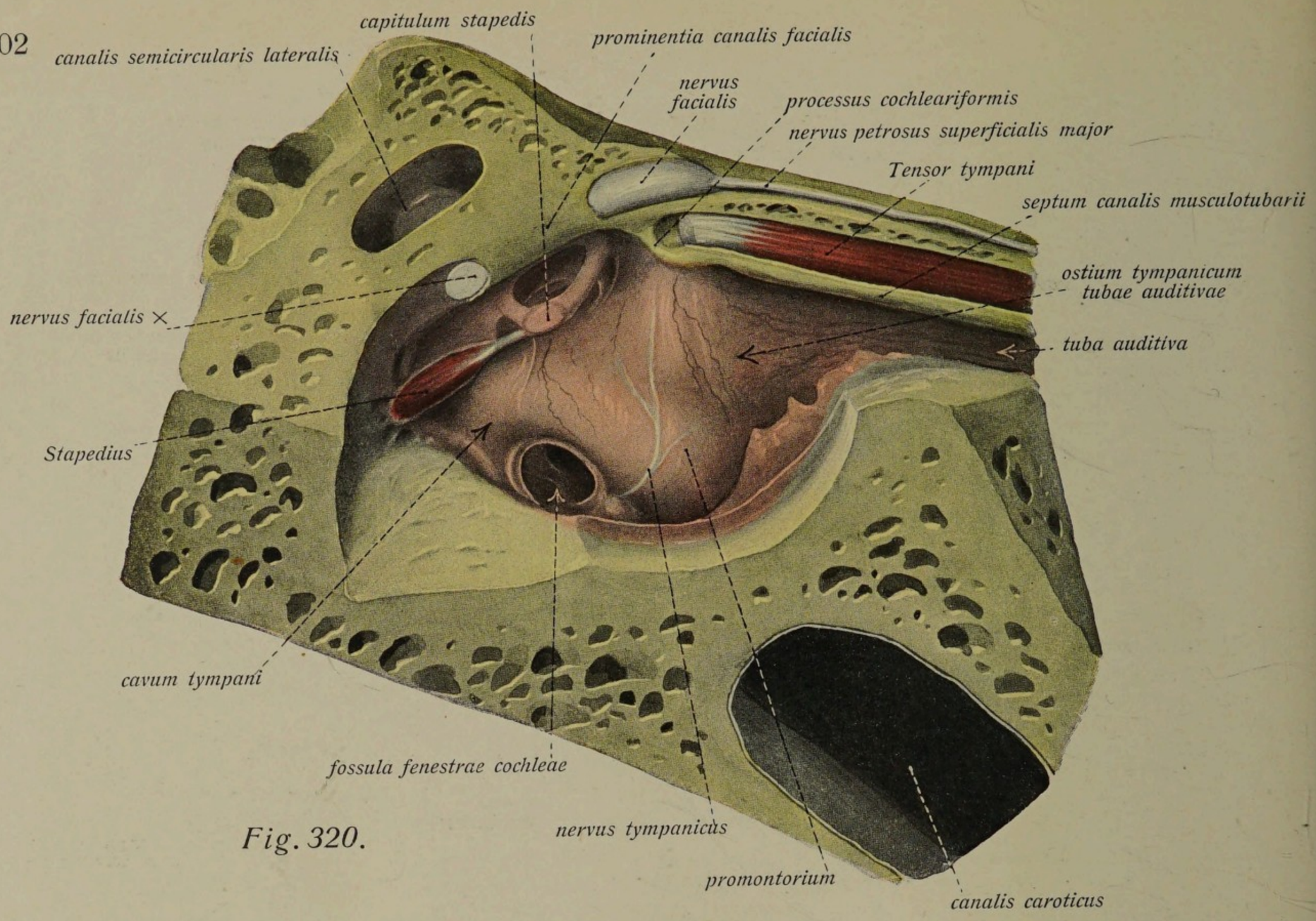

Fig. 320.

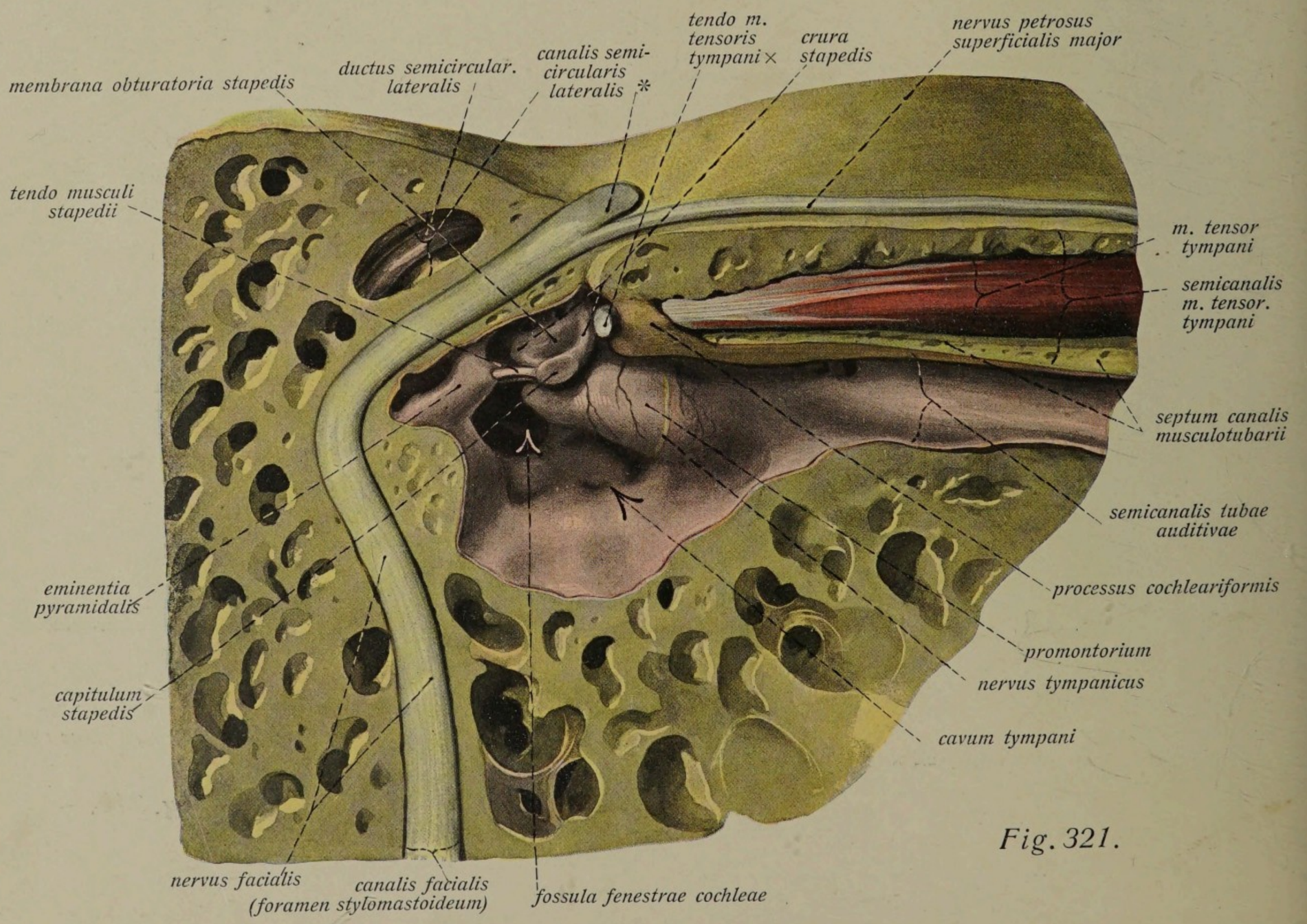

Fig. 321.

The Ear. The Middle Ear. (Cont.)

Fig. 320. The medial wall of the right tympanic cavity, from the lateral side. ($^5/_1$) Preparation similar to Fig. 319, but the posterior wall of the tympanic cavity is partly cut away, the Stapedius exposed by cutting away the wall of the pyramidal eminence and the lower part of the facial canal opened, as is also the lateral semicircular canal; the carotid canal is also opened for a short distance.

Fig. 321. The medial wall of the tympanic cavity, with the stapes and the portion of the facial nerve adjacent to the middle ear. ($^5/_1$) The tympanic cavity has been opened by a section almost parallel to the axis of the pyramid of the temporal bone; the lateral wall with the tympanic membrane, malleus and incus has been removed; the tendon of the Tensor tympani is cut, the musculo-tubar canal is opened and the septum cut away as far as the cochleariform process, to expose the muscle. The facial canal is opened from the hiatus to the stylo-mastoid foramen, as is also the lateral semicircular canal. * = geniculum of the facial nerve.

The Mucous Membrane of the Tympanic Cavity. (Cont.)

The *plica incudis* passes from the long crus of the incus to the posterior wall of the tympanic cavity; the *stapedial fold* covers the tendon of the Stapedius, the stapes and its obturator membrane. Small folds cover the *secondary tympanic membrane* that closes the fenestra cochleae (rotunda). The tendon of the Tensor tympani also runs in a fold.

Partly as a consequence of these folds and partly on account of the conformation of the bones forming the walls of the tympanic cavity, there is formed a series of blind pouches. The cleft-like pouches opening downwards that the malleolar folds make with the tympanic membrane are termed the *anterior* and *posterior recesses* of the membrane. A *superior recess* (Prussak's space) is a narrow space lying between the pars flaccida of the membrane and the neck of the malleus. It is closed below by the lateral process of the malleus and its upper boundary is the lateral ligament of the same bone; it communicates with the posterior recess. The space in which the head of the malleus and body of the incus are situated above the tympanic membrane is termed the *epitympanic recess* (Fig. 326). It is bounded by a bony plate of the lateral wall of the tympanic cavity and by the cupula of the tegmen tympani, and is at least partly separated from the recesses of the tympanic membrane by the lateral ligament of the malleus.

The Ear. The Middle Ear. (Cont.)

The Tuba Auditiva, *Eustachian Tube.*

(Fig. 314—321, 323, 330, 331.)

The *tuba auditiva (Eustachian tube)* is about $3^1/_2$ cm. in length and places the tympanic cavity in communication with the naso-pharyngeal cavity. It has two portions, the one, the *bony portion*, lying in the substance of the petrous portion of the temporal, the other, the *cartilaginous portion*, lying in the roof and wall of the pharynx.

The inner surface, throughout both portions, is lined by mucous membrane. The narrowest part of the tube lies at the transition from the bony to the cartilaginous portions and is termed the *isthmus* of the tube.

The Bony Portion of the Tuba Auditiva (Eustachian tube).

The bony portion of the tube begins in the anterior wall of the tympanic cavity and follows the course and form of the bony canal, which is separated by the septum of the musculotubar canal from the Tensor tympani (see p. 299). Its transition into the cartilaginous portion takes place in the region of the spheno-petrosal fissure.

While the cartilaginous portion has a narrow cleft-like lumen, that of the bony portion, corresponding with the caliber of the bony canal in which it lies, is relatively wide and rounded triangular.

The bony portion lacks glandular structures in its very thin mucous membrane; on the other hand, like the bony canal for the Tensor tympani (see p. 292), it possesses numerous small blind pockets, the *tubar cells*.

Fig. 322. The fenestra vestibuli (ovalis) and fenestra cochleae (rotunda) seen from the tympanic cavity. ($^6/_1$)
The pyramidal eminence is opened, the Stapedius removed, also the stapes. The bone is chiselled away so as to expose the fenestra cochleae (rotunda), with the secondary tympanic membrane and the neighbouring folds of the mucous membrane.

Fig. 323. A transverse section of the musculo-tubar canal, with the bony part of the tuba auditiva (Eustachian tube) and the Tensor tympani. ($^{20}/_1$)

Fig. 324. A frontal section of the right external auditory meatus, the tympanic membrane and cavity. ($^4/_1$)
The Tensor tympani is cut across almost transversely at its transition into its tendon. * = apex of the tympanic cavity. ** = posterior wall of the tympanic cavity.

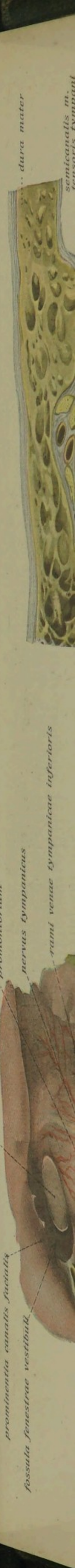

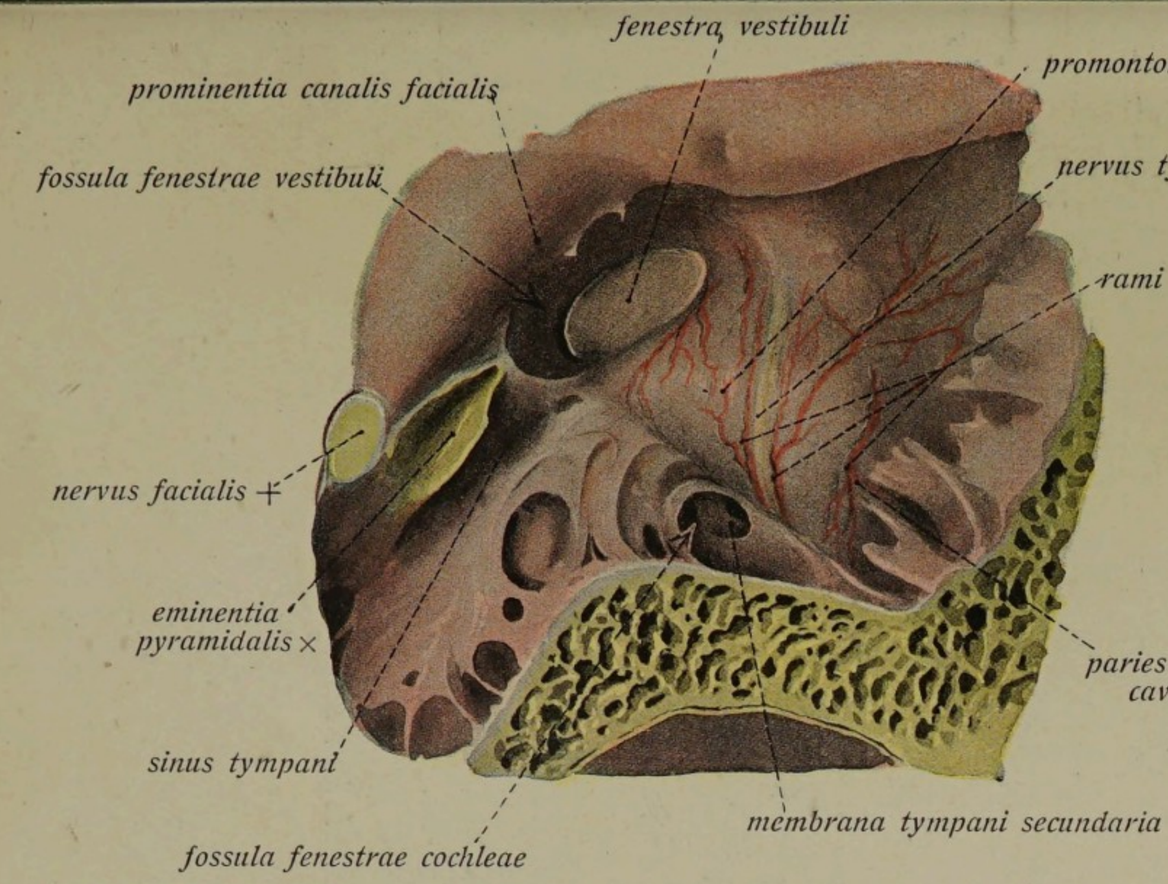

Fig. 322.

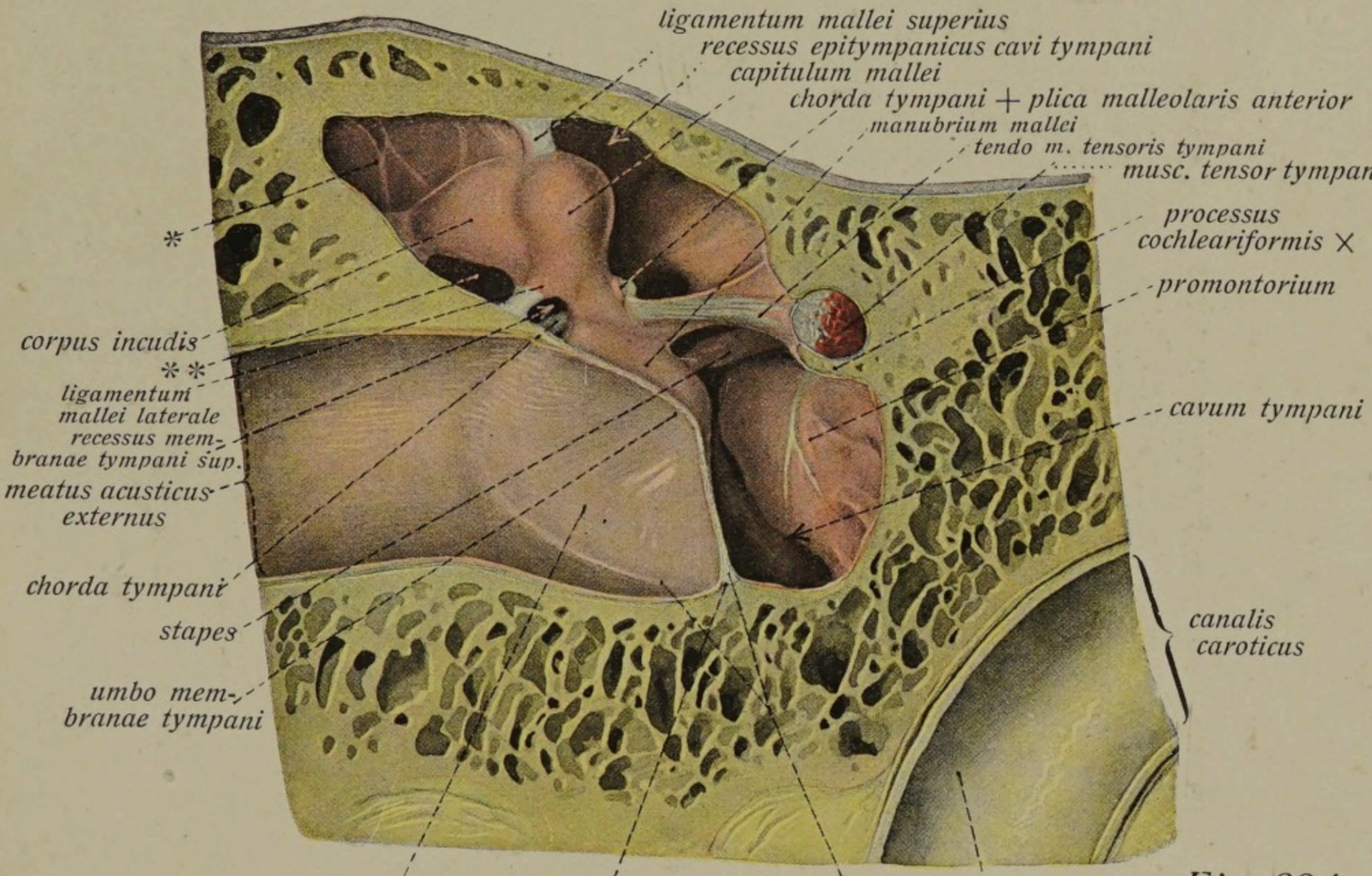

Fig. 324.

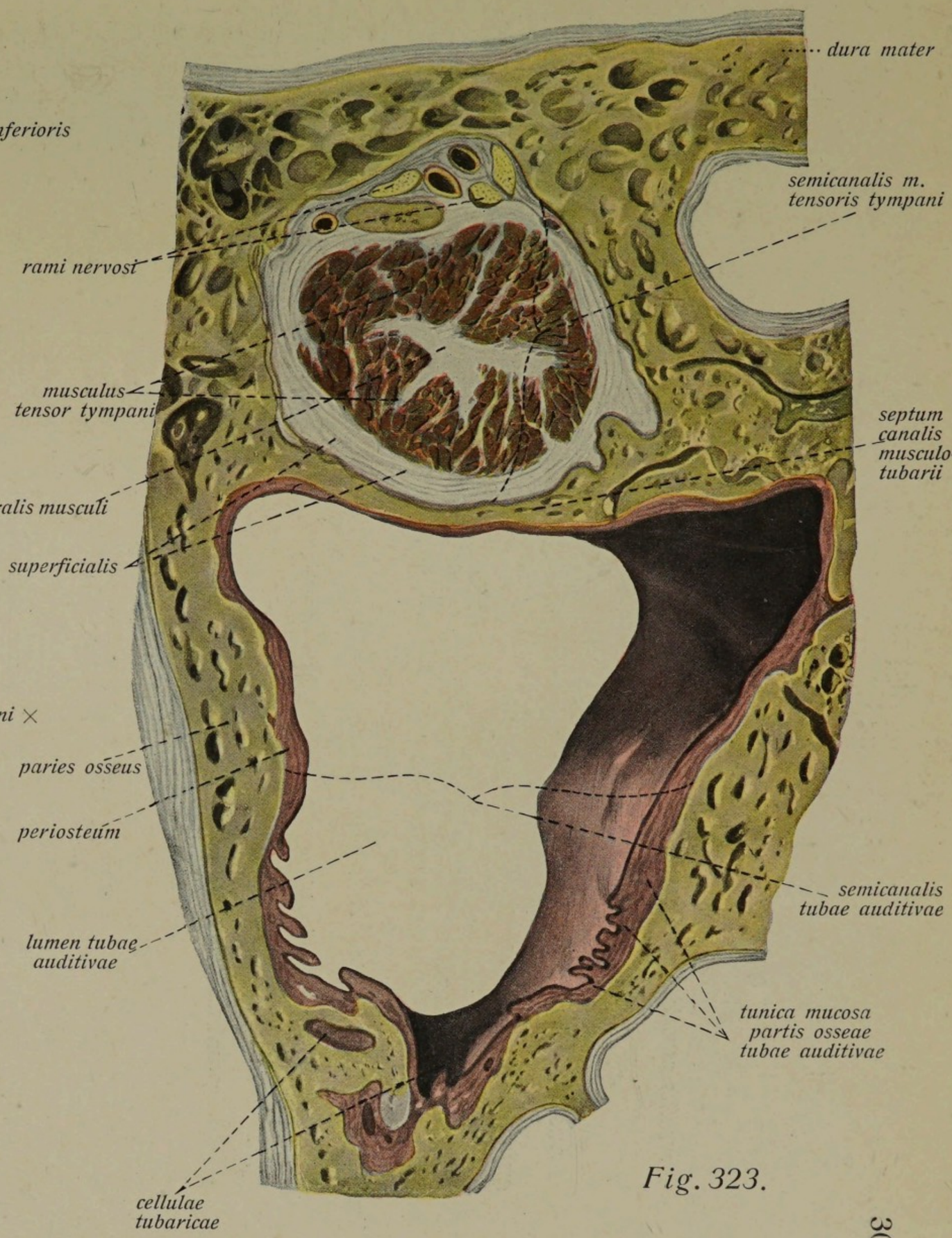

Fig. 323.

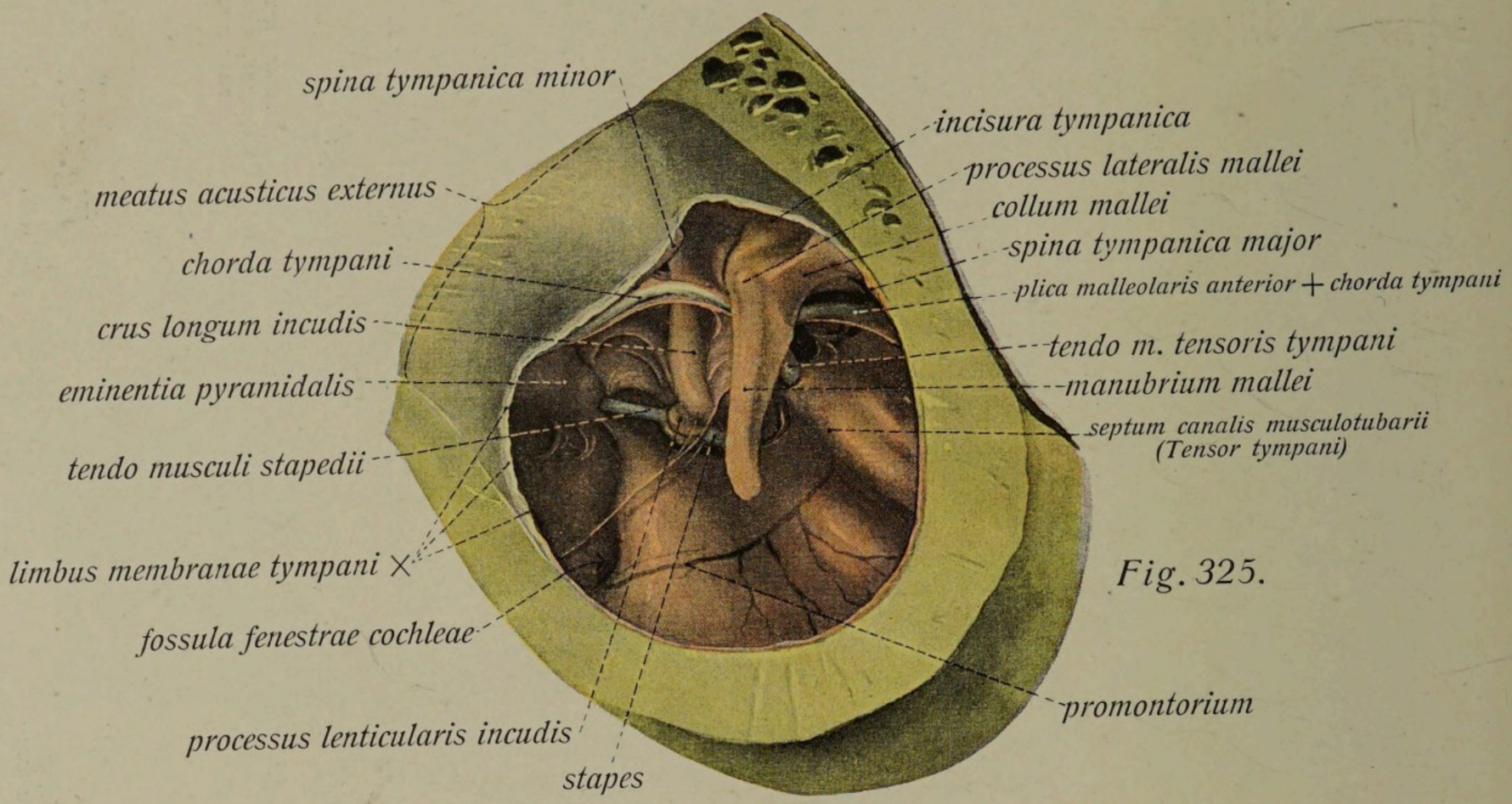

Fig. 325.

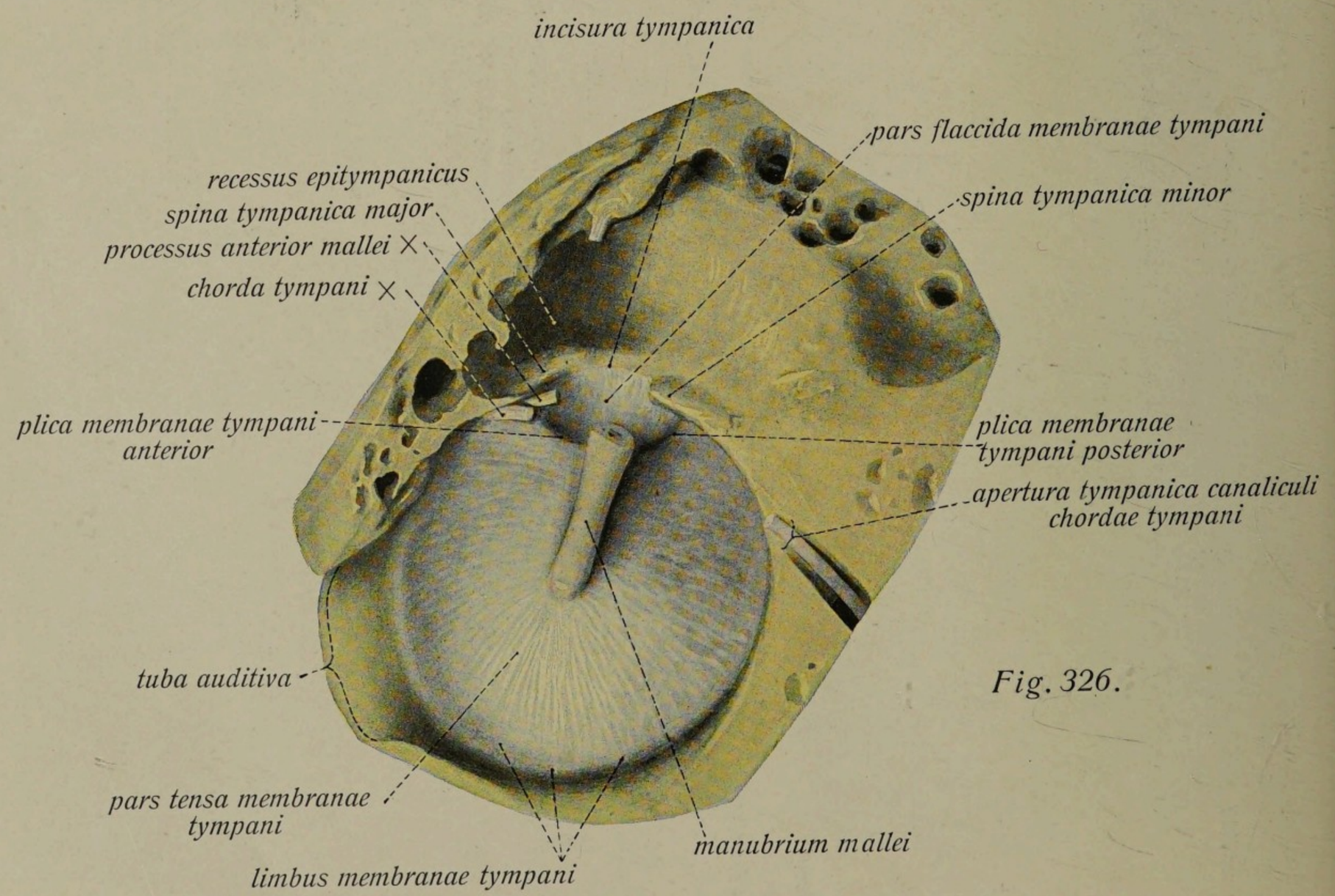

Fig. 326.

The Ear. The Middle Ear. (Cont.)

Fig. 325. A view from the external auditory meatus into the tympanic cavity, after removal of the tympanic membrane. ($^5/_1$) The wall of the external meatus is chiselled away up to the tympanic membrane and this is practically all removed. One sees the chain of auditory ossicles, which in this view partly overlap each other, further, the tendons of the Tensor tympani and the Stapedius, the malleolar folds, the promontory, the fossula of the fenestra cochleae (rotunda) and the end of the septum of the musculo-tubar canal covered by mucous membrane.

Fig. 326. The lateral wall of the tympanic cavity and the tympanic surface of the tympanic membrane, from the medial side, i. e. from the tympanic cavity. ($^5/_1$) The bone has been divided by a section almost parallel with the axis of the pyramid of the temporal bone. The contents of the tympanic cavity together with its mucous membrane have been removed; only the manubrium of the malleus on the tympanic membrane has been retained.

The Cartilaginous Portion of the Tuba Auditiva (Eustachian tube).

The cartilaginous portion extends from the isthmus to the opening into the pharynx. Its cartilage is low and small at the transition into the bony part and surrounds the lumen completely. Towards the opening into the pharynx the cartilage becomes thicker and higher, but it serves as a support for the tube in this part of its course only on its upper and medial wall, having now assumed the form of a curved plate that forms a narrow groove. The plate consists of a *lateral* and *medial lamina* (Fig. 329—331), but these are continuous above over the groove which opens downwards. The medial lamina, towards the opening into the pharynx becomes higher and noticeably thicker than the lateral one, which extends as a hook-like bent plate only into the upper part of the lateral wall of the tube, the lower part of this wall and the lower wall being formed by the *membranous lamina* (Fig. 331). The lumen of the cartilaginous part of the tube is merely a vertical cleft (Fig. 330, 331). The medial lamina is especially thickened at the opening into the pharynx and forms there the projecting *torus tubarius*.

The Tympanic Membrane.

The *tympanic membrane* (Fig. 318) is a very thin, but dense and tense membrane, almost circular or elliptical, which closes the tympanic cavity laterally and consequently forms the boundary between the middle and external ear. In the adult there is a groove, the tympanic sulcus, in the tympanic portion of the temporal bone where the membrane is attached, but the upper quarter of its attachment is to the squamous portion of the temporal, in the *tympanic notch*, which is bounded on either side by the *tympanic spines* (greater and lesser) (Fig. 326). In the tympanic sulcus the membrane is fastened by a circular thickening, the *fibrocartilaginous ring*, which is really the margin of the membrane. (Continued on p. 308.)

The Ear. The Tympanic Membrane.

Fig. 327. The right tympanic membrane from the lateral side. (5/1) The wall of the external auditory meatus is largely removed.

Fig. 328. A frontal section of the external auditory meatus, the tympanic cavity and the labyrinth. (2/1) + = the apical recess of the tympanic cavity. ++ = oblique section of the wall of the external meatus.

(Continued from p. 307.)

The surface of the tympanic membrane that is turned towards the lumen of the external auditory meatus is covered by the external skin, greatly diminished in thickness, while the surface turned towards the tympanic cavity is covered by mucous membrane.

The tympanic membrane shows two distinctly different portions, a greater tense portion and a smaller flaccid portion, the latter corresponding to the attachment in the tympanic notch. The tense portion is drawn inwards funnel-like towards the tympanic cavity by the attachment of the manubrium of the malleus to it, and the depression which thus results on the outer surface of the membrane is termed the *umbo* (Fig. 327). This surface when seen through the external meatus is shining and the entire length of the manubrium of the malleus shows through as a white streak, the *malleolar stria*. Since the top of the manubrium reaches to below the centre of the tympanic membrane, the umbo is slightly excentric. At the upper end of the malleolar stria is a slight projection, the *malleolar prominence*, produced by the lateral process of the malleus, and above this the flaccid portion of the membrane begins (Fig. 327). The manubrium of the malleus is so fastened to the medial surface of the membrane, that the mucous membrane of the tympanic cavity passes over both, and from the malleolar prominence curved folds which separate the tense and flaccid portions of the membrane extend, the anterior, shorter one *(plica anterior)* to the lesser tympanic spine and the posterior longer one *(plica posterior)* to the greater spine (Fig. 327).

The tympanic membrane is placed obliquely with reference to the axis of the external auditory meatus, indeed, it is oblique in two directions. In the first place the anterior border of the membrane is more medial than the posterior, whereby the anterior wall of the meatus is distinctly longer than the posterior wall. Furthermore, the upper border of the membrane lies further forward than the lower border. Consequently, the membrane is oblique both in the vertical and in the horizontal plane and, in addition, it has the funnel-like form produced by the *umbo*. The upper and lower segments of the funnel form different angles with the wall of the meatus, the upper one an obtuse angle and the lower an acute.



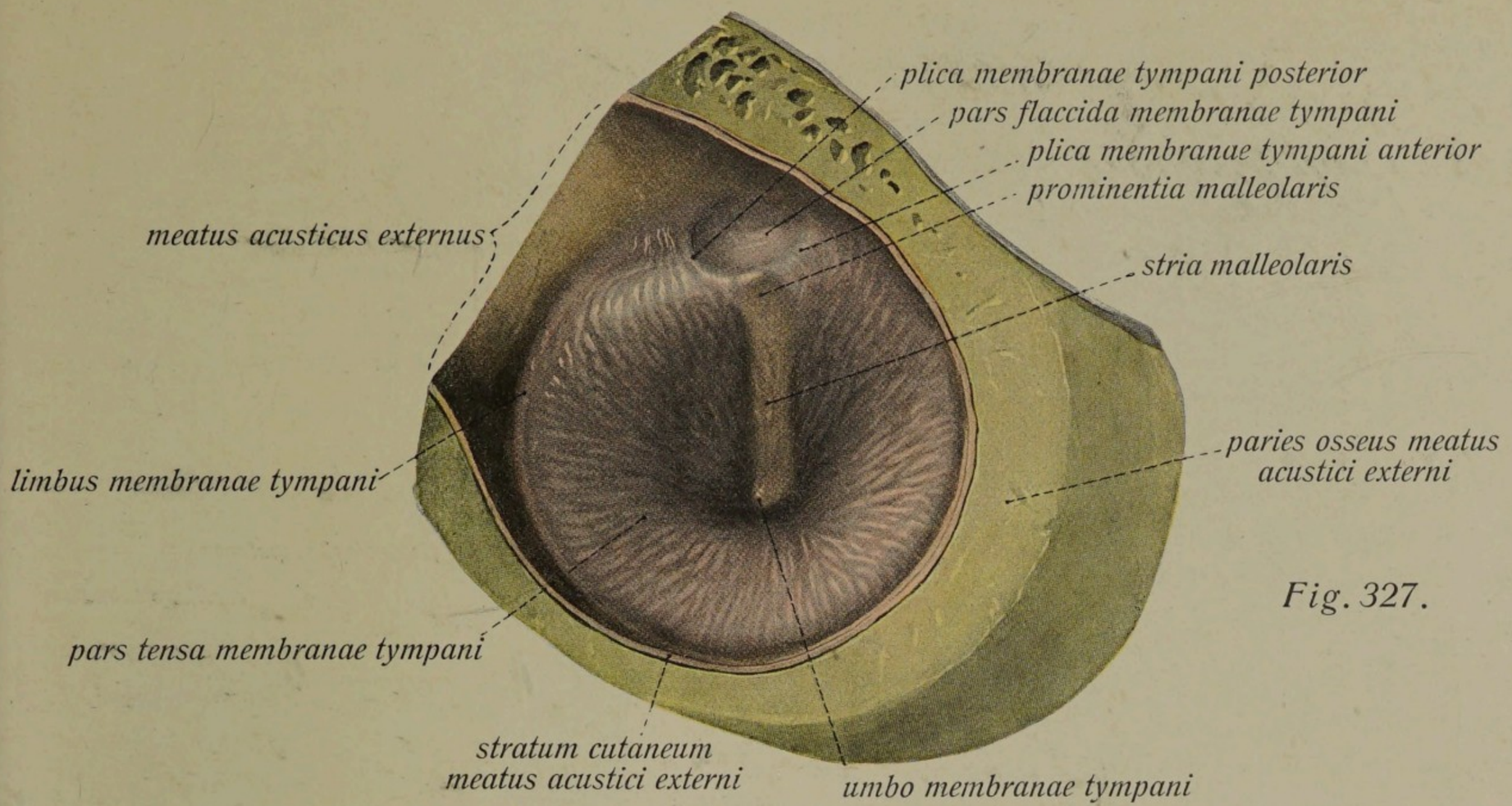

Fig. 327.

Fig. 328.

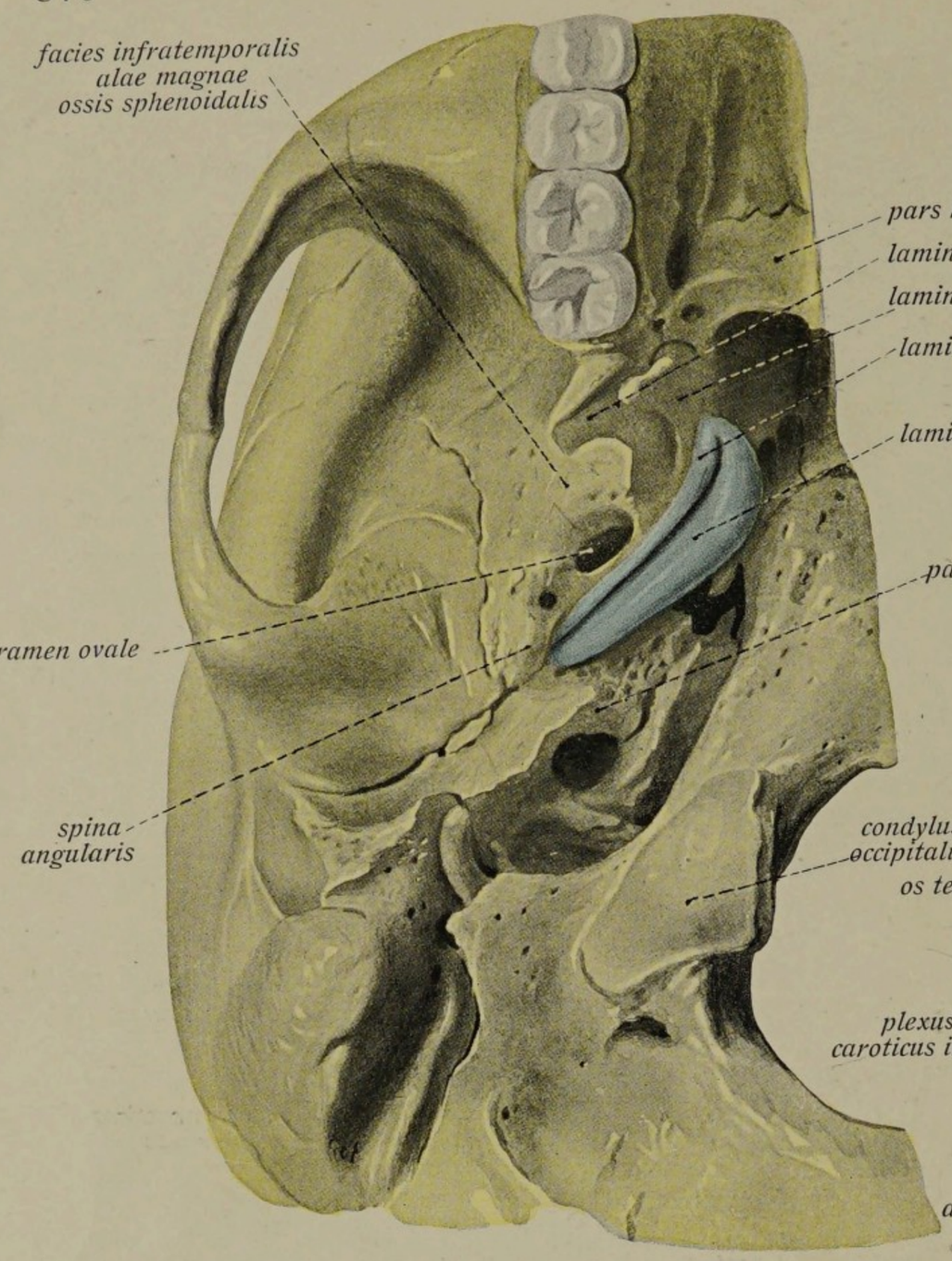

Fig. 329.

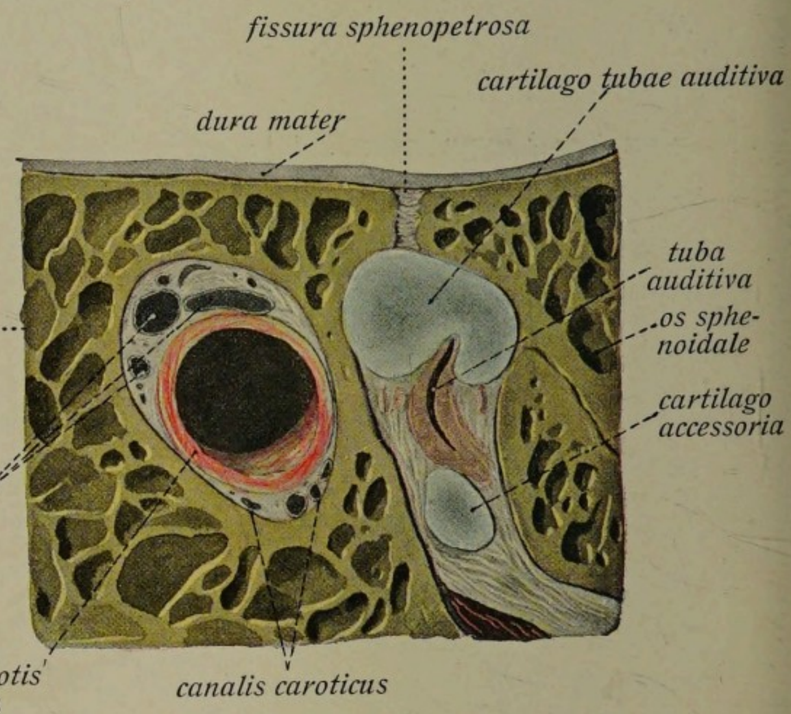

Fig. 330.

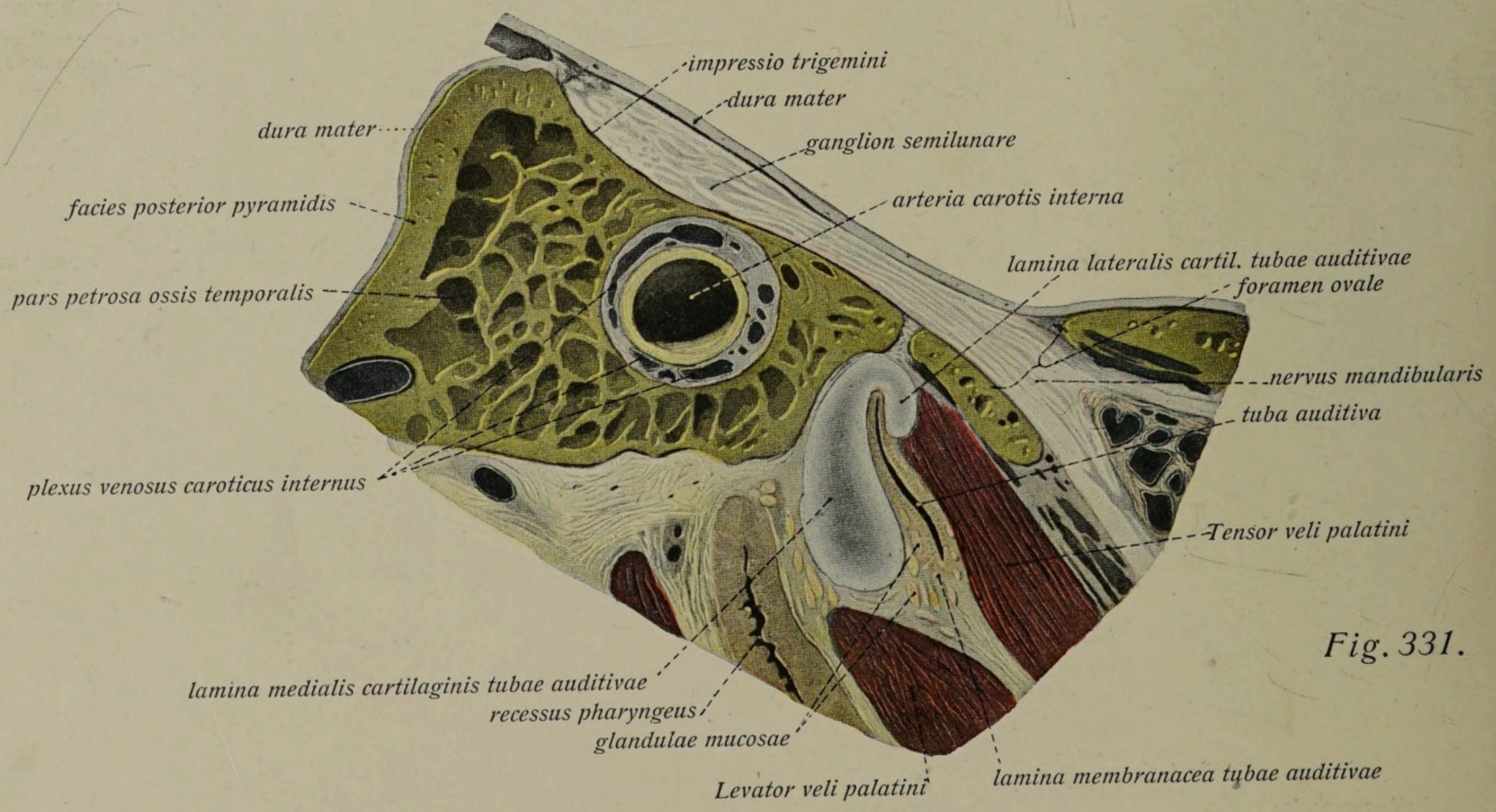

Fig. 331.

The Ear. The Tuba Auditiva *(Eustachian tube)*.

Fig. 329. The cartilage of the left tuba auditiva (Eustachian tube) in position at the base of the skull. (1/1)

Fig. 330. A transverse section of the cartilaginous portion of the left tuba auditiva (Eustachian tube), near its attachment to the bony portion. (2/1)

Fig. 331. A transverse section through the cartilaginous portion of the left tuba auditiva (Eustachian tube), near its opening into the pharynx. (2/1)

The External Auditory (Acoustic) Meatus.

The *external auditory (acoustic) meatus* consists of two portions, a medial *bony portion* and a lateral *cartilaginous portion*, which pass the one into the other, without interruption. The bony portion extends from the external auditory (acoustic) pore to the groove for the tympanic membrane in the tympanic portion of the temporal bone and, since the tympanic membrane is placed obliquely to the axis of the meatus, the upper wall of the meatus is shorter than the lower one and the posterior wall shorter than the anterior. The cartilaginous portion of the meatus is a part of the cartilaginous framework of the auricle.

The meatus lies almost in the frontal plane and horizontally, and runs almost directly medially between the auricle and the tympanic membrane; its departure from the horizontal direction is but small, that from the frontal direction somewhat greater. Furthermore the course of the meatus is by no means straight, but shows individual and variable bendings, that are mainly in the cartilaginous portion. One bend lies close behind the entrance and looks upwards and forwards and a second bend is near the boundary between the bony and cartilaginous portions and looks backwards and downwards, but is less marked than the first bend. The bony part then carries the direction somewhat forward again.

In its length the meatus shows individual differences; on the average it is 35 mm., the bony part forming 1/3 and the cartilaginous part 2/3. In transverse section it is in general irregularly elliptical. The lumen becomes narrower from the entrance to the end of the cartilaginous portion, but widens again in the bony portion. The lower wall forms with the tympanic membrane an acute angled depression.

The lumen of the meatus is lined by a prolongation of the external skin of the auricle, this also, greatly diminished in thickness, covering the outer surface of the tympanic membrane, forming its cutaneous layer. In the region of the bony portion the invaginated integument is thin and firmly united with the periosteum, but in the cartilaginous portion it is thicker and, in addition to fine hairs and the sebaceous glands associated with these, has *ceruminous glands*, secreting a waxy substance.

The Ear. The External Ear.

Fig. 332. The right auricle from the lateral side. (1/1)
Fig. 333. The cartilage of the right auricle from in front. (1/1)
The cartilage is shown in its natural relation to the temporal bone. The anterior part of the squamous portion of the temporal is cut away.
Fig. 334. The cartilage of the right auricle from the lateral side. (1/1)
Fig. 335. The cartilage of the right auricle from the medial side. (1/1)

The Auricle, *Pinna*.

(Fig. 332—338)

The foundation of the auricle is a frame-work of elastic cartilage, the majority of whose parts may be made out from the exterior. The sharp curved border that forms the posterior, upper and upper part of the anterior circumference of the auricle is termed the *helix*. The almost transverse terminal part of the anterior part of the helix is termed its *crus*, and an anteriorly projecting nodule is termed the *spina helicis*. Posteriorly and below, the helix passes into a free, flattened *cauda helicis*. Parallel to the helix is the *anthelix*, which begins above by two *crura*, below the highest point of the helix, the depression between the crura being termed the *fossa triangularis*. The elongated deep groove between the helix and anthelix is the *scapha*.

The deep depression between the anthelix, the anterior portion of the helix, and the tragus, the actual bottom of the auricular cartilage, is termed the *concha*. From it the crus of the helix takes its origin and divides the concha into the *cymba*, between the crus of the helix and the anthelix, and the actual vestibule of the external auditory meatus, the *cavum conchae*, which is bounded anteriorly by the tragus. The lower, anterior portion of the cartilage is formed by the *lamina tragi* and the cartilage of the external meatus. The former, together with the integument covering it, forms the *tragus* and is continued medially into the cartilage of the meatus without any sharp boundary. Opposite the lamina tragi the auricular cartilage is folded so as to produce an elevation, the *anti-tragus*, which is separated from the cauda helicis by the *fissura antitrago-helicina* and from the lamina tragi by the *incisura intertragica*. This incisure produces the narrow isthmus that joins the cartilage of the external meatus and the lamina tragi on the one side with the main portion of the auricular cartilage on the other, these two portions of the cartilage being separated medially by the *incisura terminalis*. The depressions of the lateral surface of the auricular cartilage produce corresponding elevations on the medial surface, the eminences of the fossa triangularis, concha and scapha. The first two are separated by the *transverse sulcus of the anthelix*, a groove that corresponds to the lower crus of the anthelix and passes into the *fossa anthelicis*, which corresponds to the anthelix. Further, the medial surface has a *sulcus of the crus helicis*, corresponding to the projection of that name on the lateral surface.

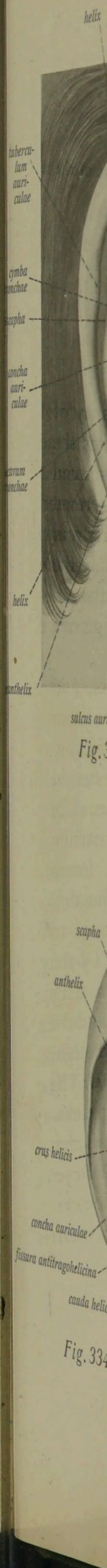

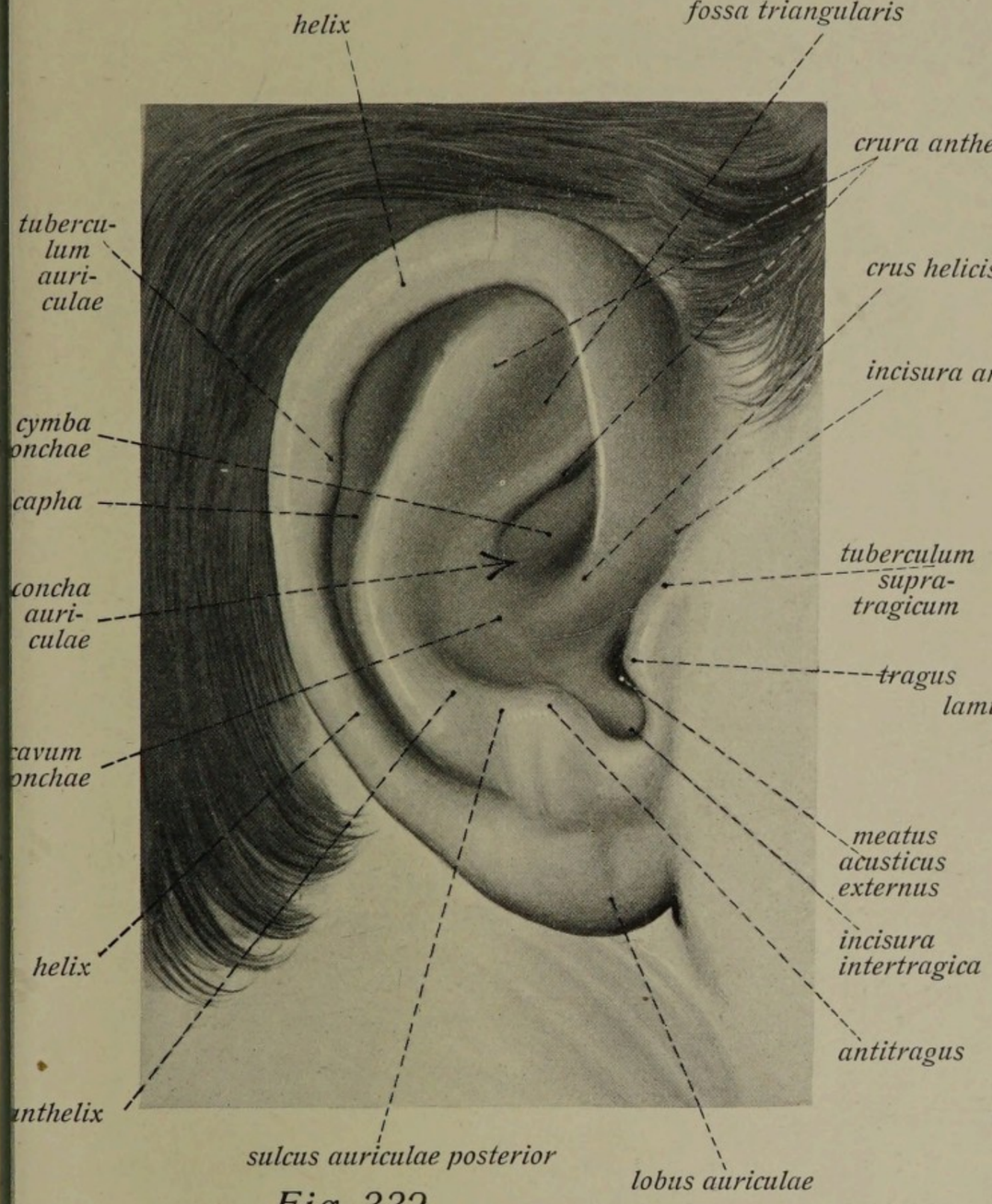

Fig. 332.

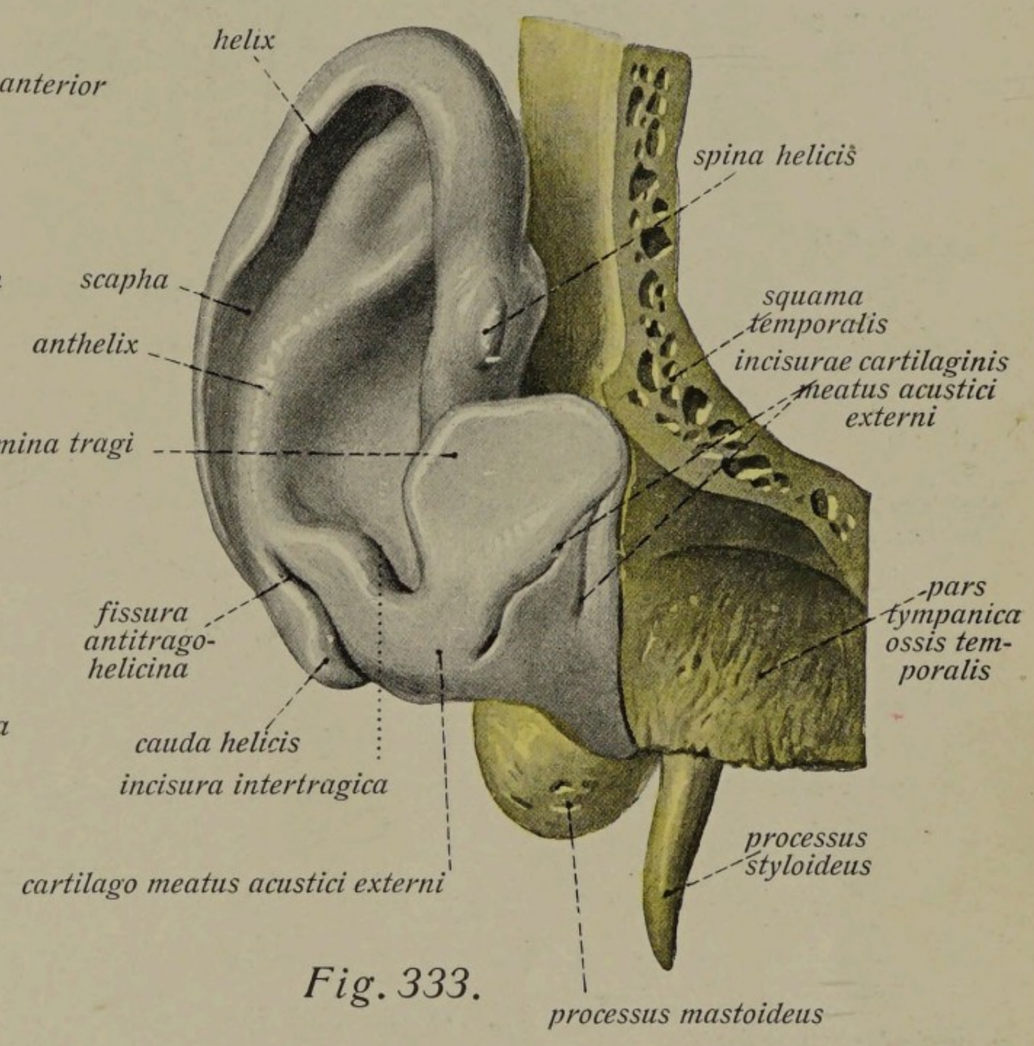

Fig. 333.

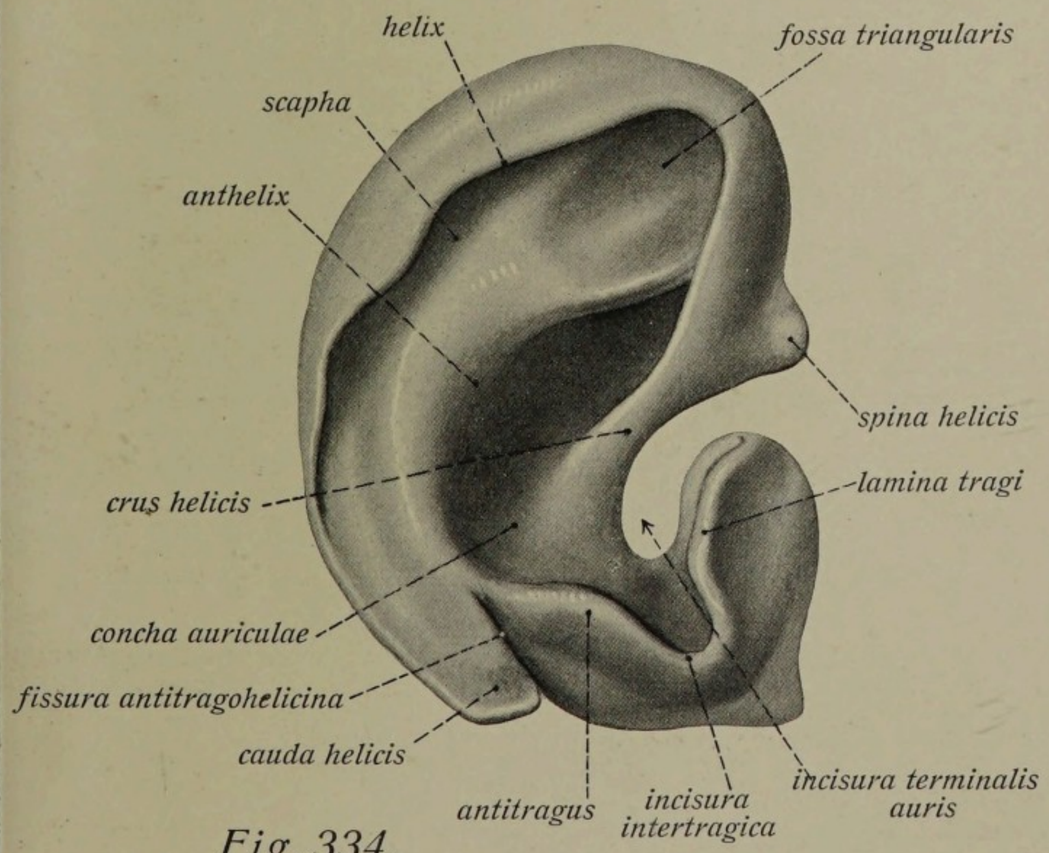

Fig. 334.

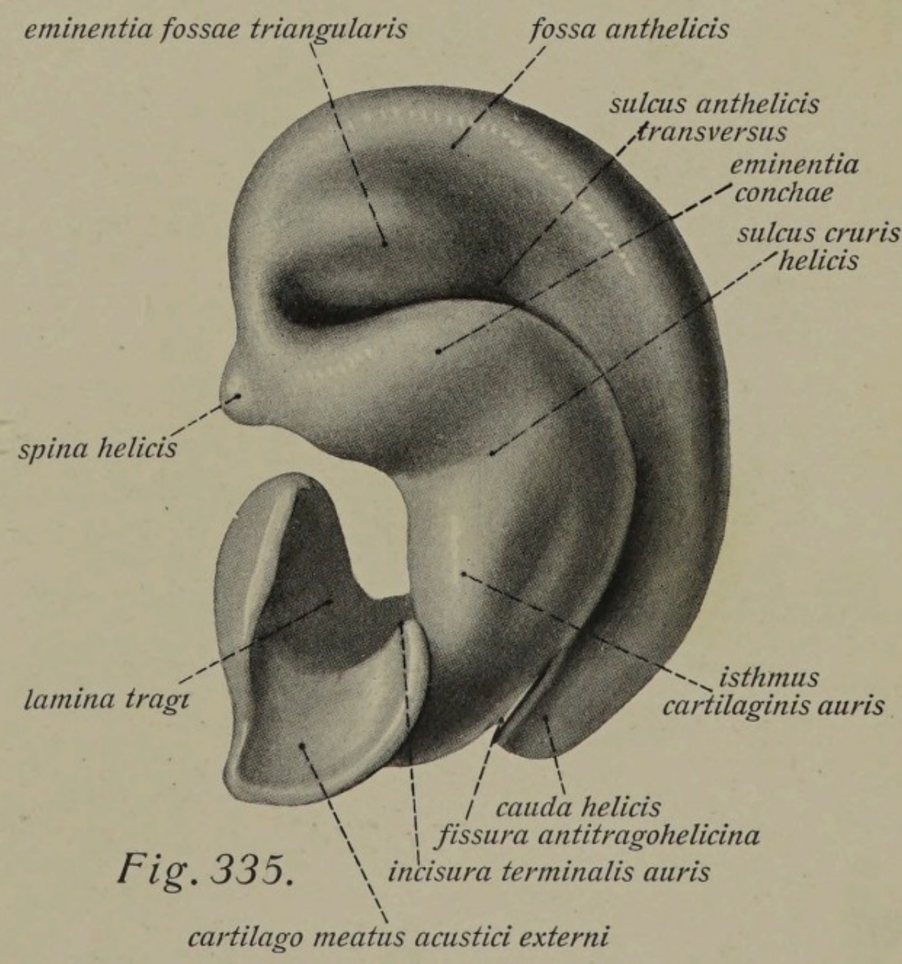

Fig. 335.

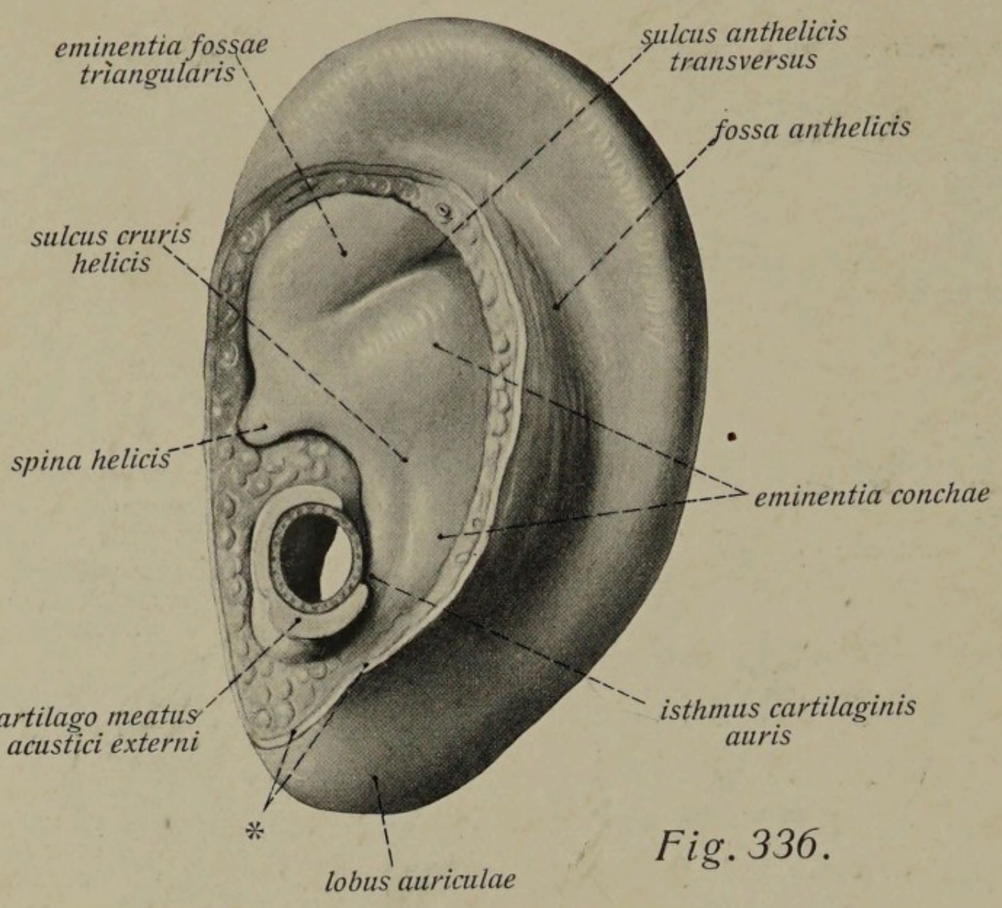

Fig. 336.

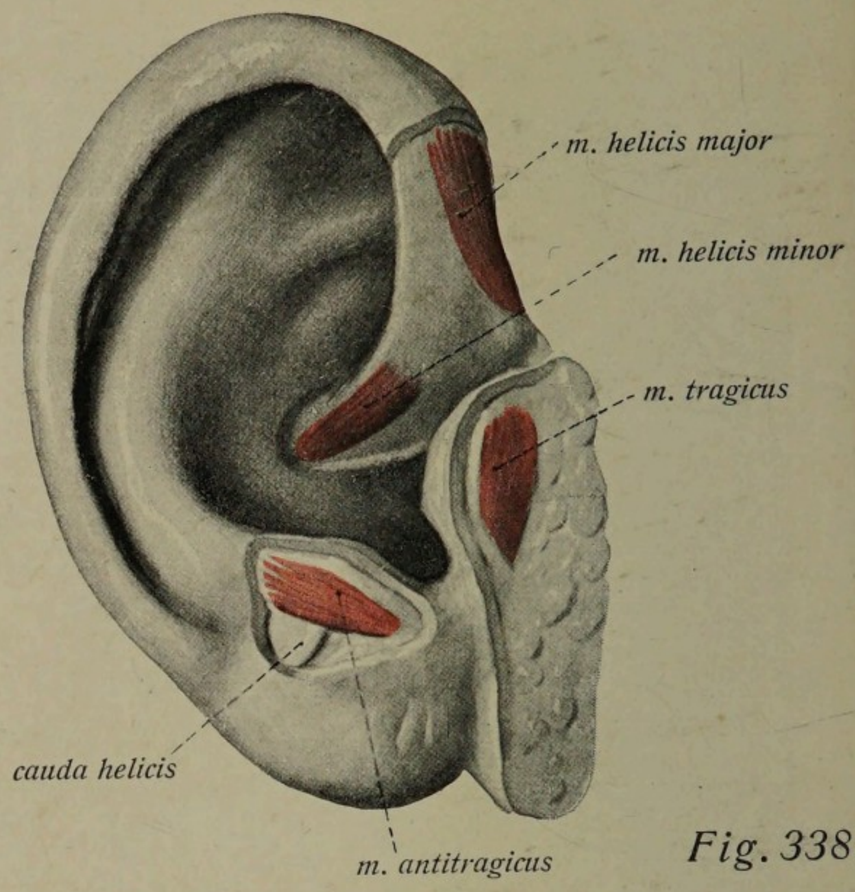

Fig. 338.

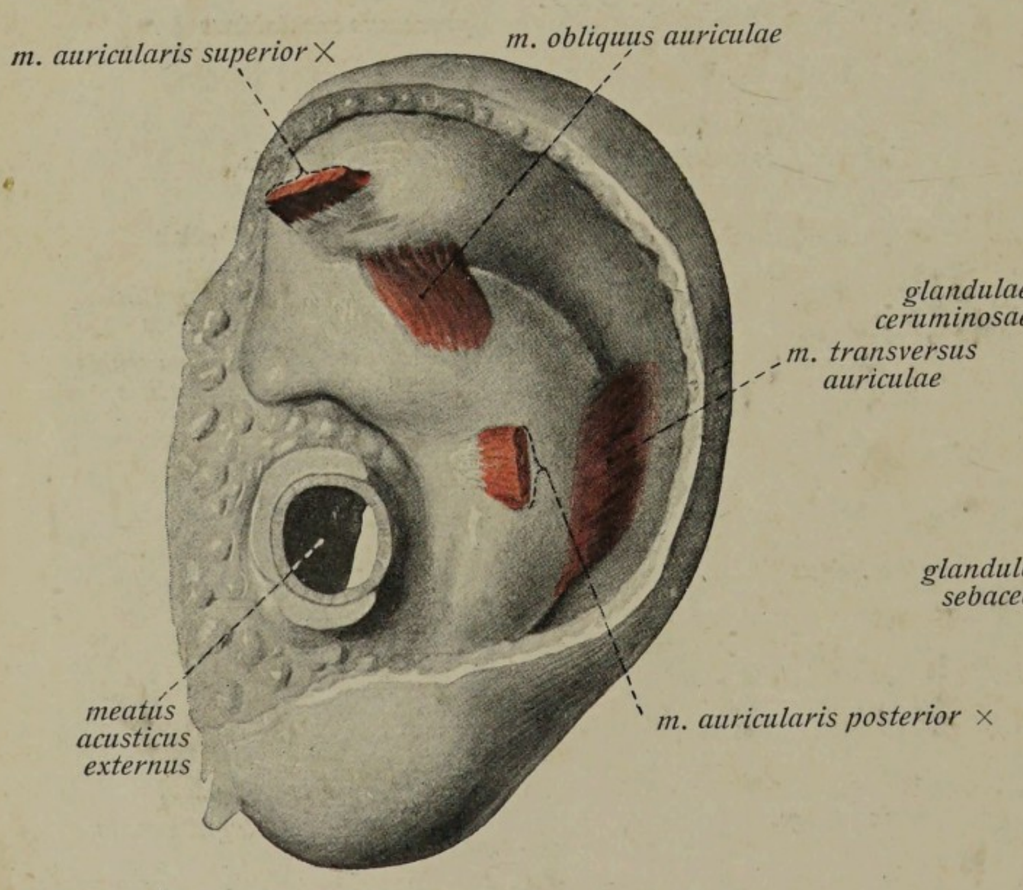

Fig. 337.

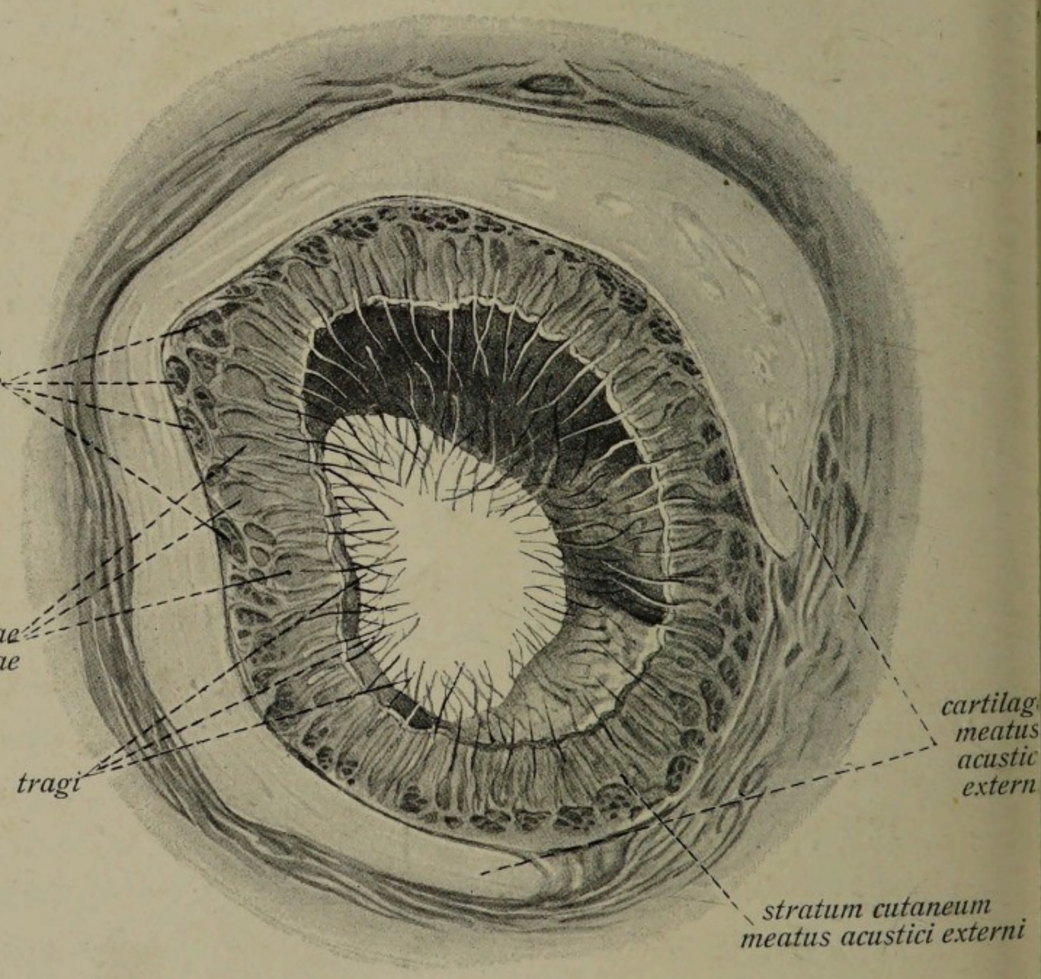

Fig. 339.

The Ear. The External Ear. (Cont.)

Fig. 336. The right auricle separated from the head, from the medial surface. ($^1/_1$)
* = the cut edge of the external skin.
Fig. 337. The muscles of the medial surface of the auricular cartilage. ($^1/_1$)
Fig. 338. The muscles of the lateral surface of the auricular cartilage. ($^1/_1$)
Fig. 339. A transverse section through the external auditory meatus, cartilaginous portion. ($^8/_1$)

The cartilage of the external auditory meatus begins at its lateral end in the lamina tragi and is a trough-like semicanal whose posterior and upper portion is bridged over by connective tissue. Its continuity is interrupted by, usually, two vertical incisures, the *incisures of Santorini*, which, also, are bridged over by connective tissue.

The external skin of the ear covers the auricular cartilage so that almost all the irregularities of its surface are clearly to be made out. This depends on the fact that the skin of the auricle is destitute of fat and is consequently closely moulded to the surface of the cartilage. Departures from these conditions are found only at the following places; firstly in the lobe of the ear; this contains no cartilage, but is a duplicature of the integument filled with fat tissue; secondly, the antitrago-helicine fissure and the portion of the terminal incisure between the crus of the helix and the lamina of the tragus are bridged over by the external skin. Over the antitrago-helicine fissure there is a shallow groove, the *posterior auricular sulcus*, and at the terminal incisure there is a simple groove, the *anterior incisure*, along which the skin of the auricle passes into that of the cheek. While the lateral surface of the auricle is completely covered with skin, this is the case with only the upper and posterior parts of the medial surface, the skin being reflected from these into the skin of the temporal region (Fig. 336).

In addition to the three parts of the Auricular muscle (see Vol. I) that serve for the movement of the auricle, there are some very small muscles on the auricle itself (Fig. 337, 338). The *m. helicis major* is an elongated flat muscle, which extends from the spine of the helix to where the anterior portion of the helix passes into its upper portion. The *m. helicis minor* lies on the crus of the helix; it is shorter than the preceding and runs upwards and forwards. The *m. tragicus* is broadly rectangular; it arises from the lamina of the tragus and runs thence upwards. The *m. antitragicus* lies on the antitragus behind the incisura anthelicis and unites the antitragus and anthelix. The *m. transversus auriculae* consists of short fibres, often separated by intervals into distinct bundles, that lie on the medial surface of the auricular cartilage where it unites the eminence of the concha and scapha. The *m. obliquus auriculae* is a small, weak bundle that unites the eminence of the triangular fossa and that of the concha.

The Integument.

The Mammary Gland.

Fig. 340. The right breast of a pregnant woman, from in front. (1/2)

Fig. 341. The right mammary gland of a pregnant woman, from in front. (1/2) The skin is removed up to the nipple.

The Integument.

A distinction may be made between the skin itself and the structures formed from it. The skin consists of three layers, which, named from without inwards, are the cellular layer, the *epidermis*, the fibrous layer, the *corium* (dermis or cutis), and the fatty or fascial layer, the *tela subcutanea*.

The *epidermis* is the epithelial portion of the skin and is the layer from which all the accessory glandular structures are formed. It varies greatly in thickness in the different regions of the body, its greatest thickness being found on the palm of the hand and the sole of the foot, while it is very thin over the eyelids, the prepuce, the scrotum, etc. Just as the corium passes into the mucous membrane at the body openings, so too the epidermis passes into the epithelium of the membranes.

The *corium* (dermis or cutis) has numerous furrows, the *sulci cutis*, upon its outer surface, these being sometimes faint, sometimes deeper. In many regions of the body, such as the palmar surface of the hand or the sole of the foot, where they are especially well developed and regularly arranged, the sulci are separated by distinct ridges, the *cristae cutis*, which form characteristic patterns whose form and arrangement differ in each individual (Fig. 344). Also the thickness of the cutis which is formed by the felt-like interweaving of bundles of connective tissue fibres, varies in different parts of the body, usually in correspondence with the thickness of the epidermis. Numerous elastic fibres in the corium give the skin a high degree of elasticity. Smooth muscle fibres also occur in the skin, forming in some places, such as the tunica dartos of the scrotum and the nipple area of the breast (see p. 319), continuous sheets.

The *tela subcutanea* passes gradually into the corium, from which strong bundles of connective tissue fibres, the *retinacula* cutis, project into it. It is separated from the underlying tissues by a thin membrane, the *superficial fascia*. In most of the regions of the body the tela subcutanea contains more or less fat, this constituting what is termed the *panniculus adiposus*. Only at definite individual regions is the skin destitute of fat tissue (the eyelids, the scrotum, the prepuce, labia minora, the auricle, etc.).

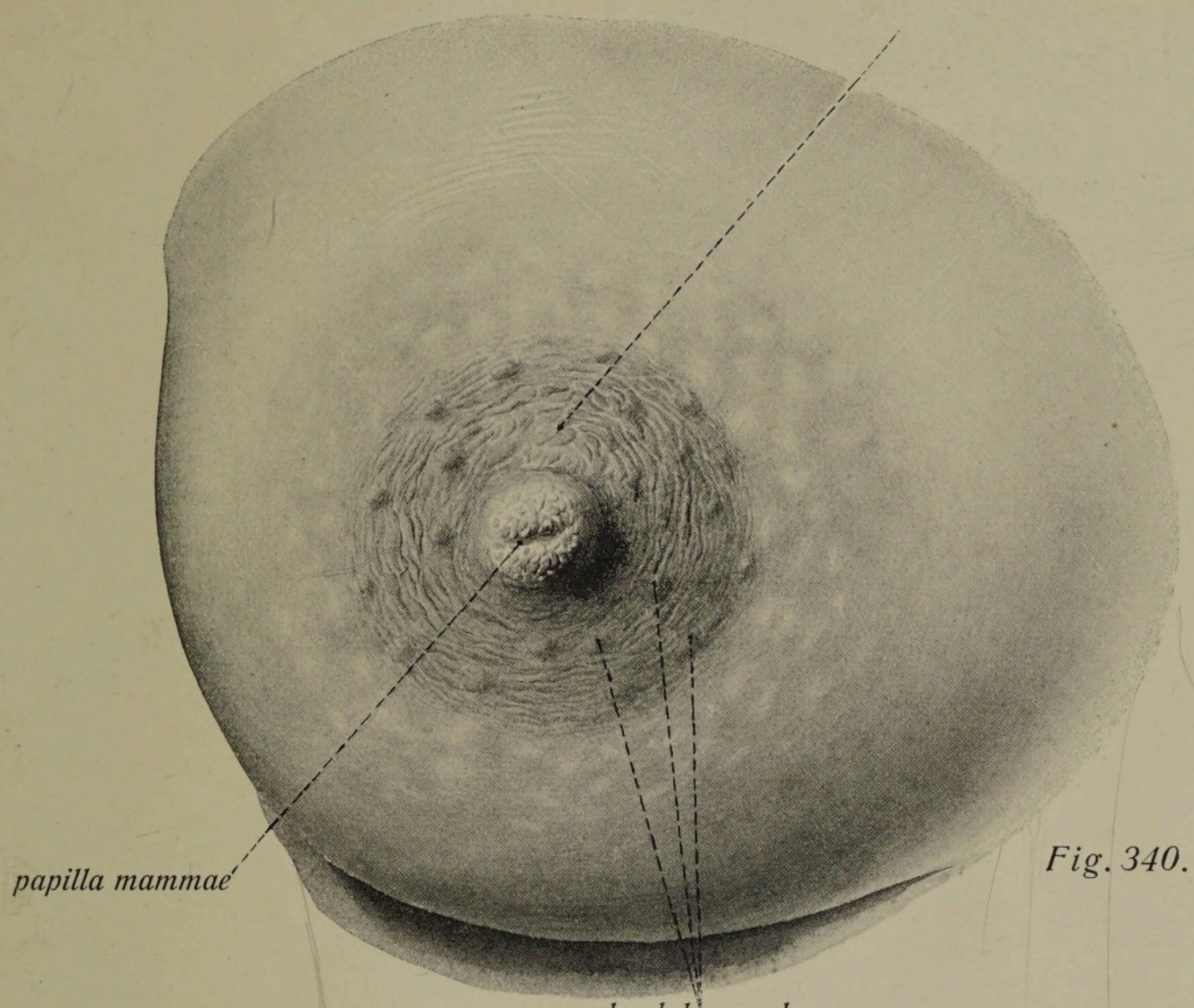

Fig. 340.

Fig. 341.

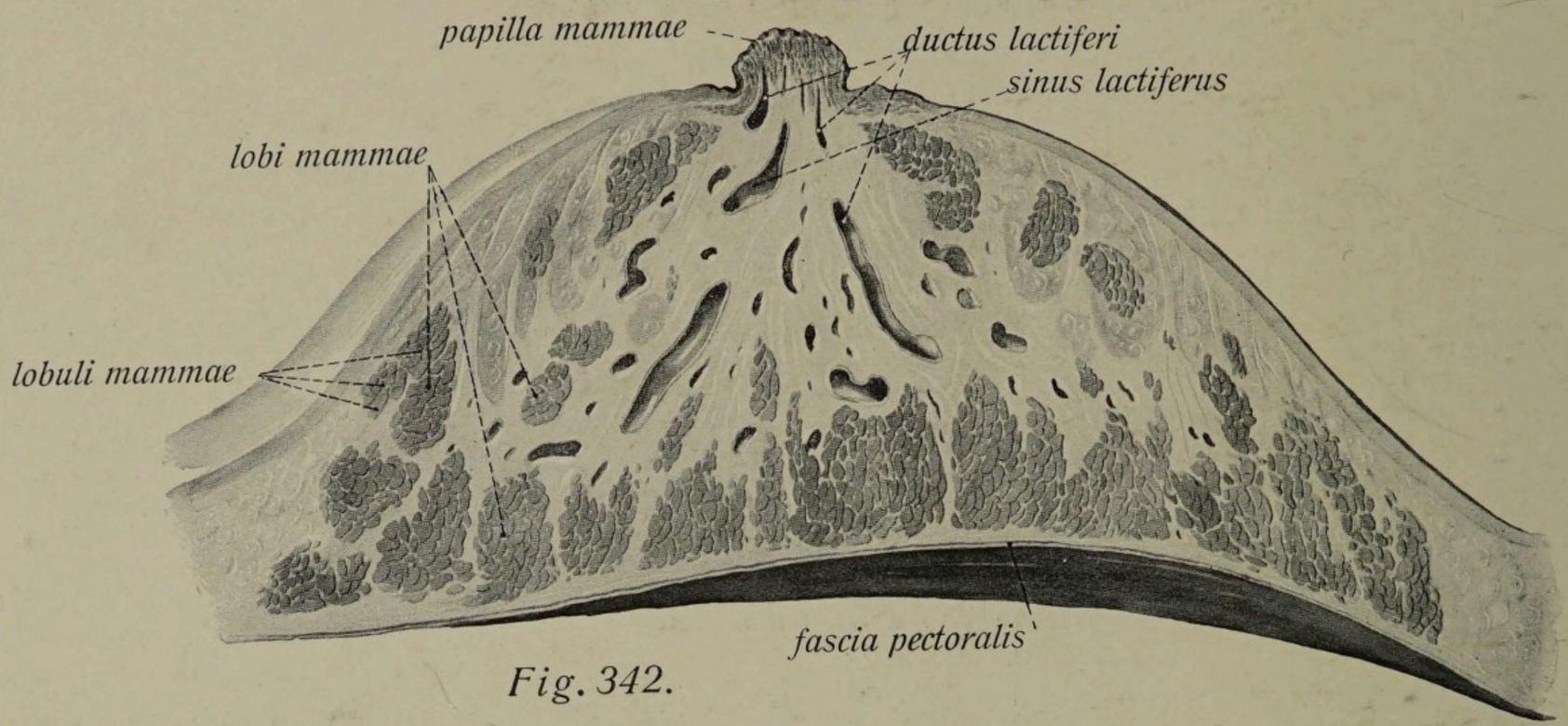

Fig. 342.

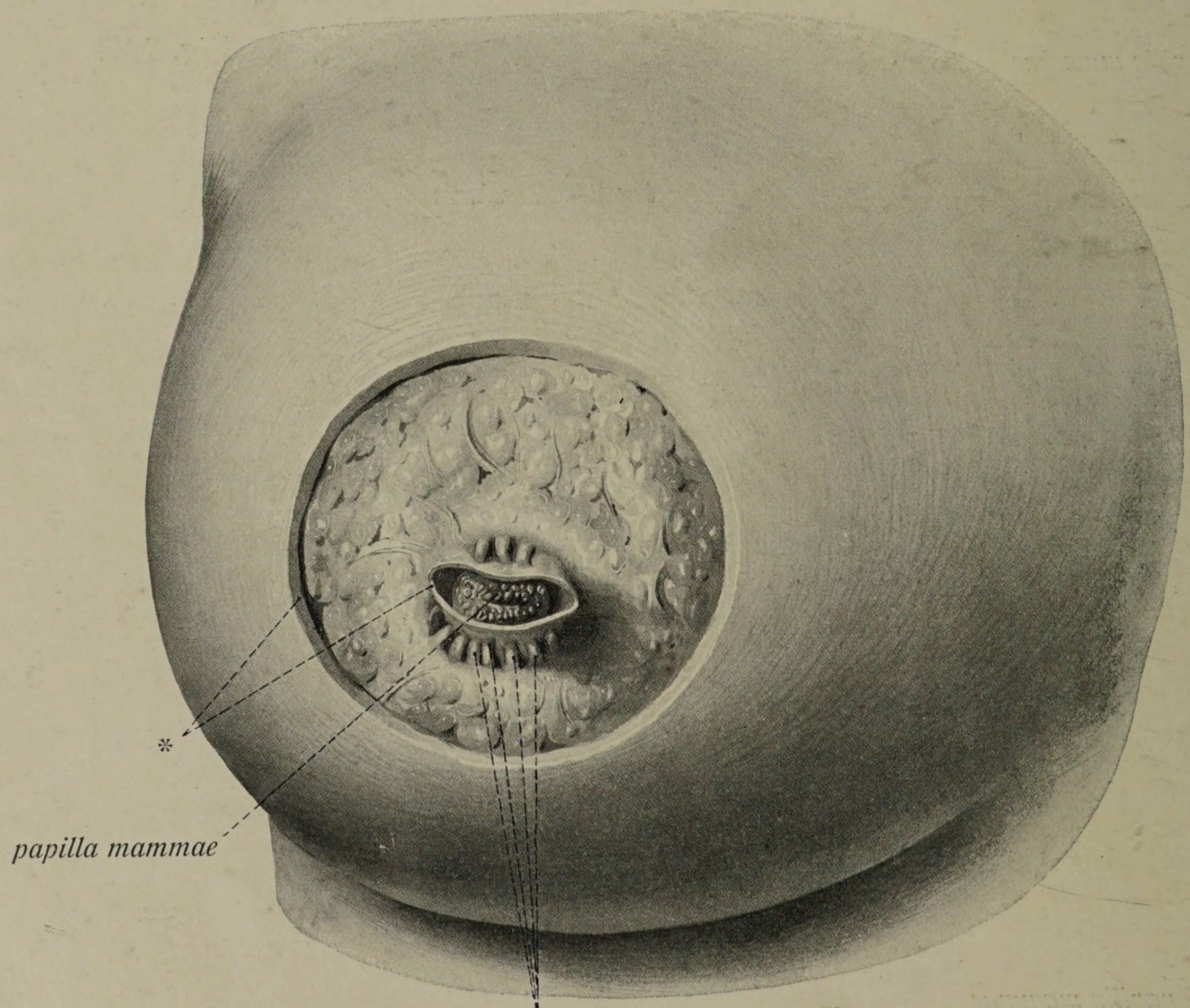

Fig. 343.

Fig. 342. The right mammary gland of a pregnant woman divided by a sagittal section. ($^1/_2$)

Fig. 343. The right mammary gland of a pregnant woman. ($^1/_2$) A circular area of skin around the nipple has been cut and the skin immediately around the nipple has been reflected over it to show the lactiferous ducts. * = cut edge of skin.

The Appendages of the Skin.

The Integumentary Glands.

The Mammary Glands.

The *mammary glands* (Fig. 340—343), which are developments of the integument, are peculiarly modified sudoriferous glands, which, in the completely developed and functioning condition, secrete milk. They are paired and lie in the fat tissue of the skin of the anterior thoracic wall. The glandular tissue proper and the subcutaneous fat form together the breast, *mamma*, varying greatly in its prominence in different individuals. The glandular substance of each gland has a flattened, hemispherical form, and consists of 15—24 irregularly shaped *lobes*, more or less deeply separated by fat tissue. Each lobe again is composed of small *lobules* and has a special excretory duct, the *ductus lactiferus*, which opens upon the nipple.

The nipple *(papilla mammae)* (Fig. 340) lies in the centre of a circular darkly pigmented area of skin, the *areola mammae*, which is characterized by the absence of fat and by the presence over its surface of large sebaceous glands, the *areolar (Montgomery's) glands*, each of which forms a small wart-like elevation. The nipple is conical and varies greatly in height and size in different individuals; it is covered by a delicate, much wrinkled skin and is especially rich in smooth muscle fibres. On its summit the *lactiferous ducts* (Fig. 343) from the lobes of the gland open by small pores; each duct, shortly before its opening, undergoing a spindle-shaped enlargement, the *sinus lactiferus*.

The mammary glands are situated at the level of the third to the sixth or seventh rib, in the mammary region. The level of the nipple varies greatly; usually it corresponds to the fourth intercostal space. The glandular substance has no sharp delimitation at its periphery and, frequently, prolongations of it extend towards the axillary cavity. It is separated from the Pectoralis major by the fascia of that muscle.

In the male the actual mammary gland is rudimentary; only the nipple is developed.

The Nails, *ungues*.

Fig. 344. The furrows and ridges of the volar surface of a finger tip. (2/1)
Fig. 345. Imprints of the furrows and ridges of two fingers. (1/1)
Fig. 346. The nail plate separated from the nail bed, dorsal surface. (1/1)
Fig. 347. A finger nail in its natural position, dorsal surface. (1/1)
Fig. 348. A finger nail from the dorsal surface. (1/1) The nail is divided longitudinally and on the left the nail bed is exposed.
Fig. 349. The nail bed of the great toe after removal of the nail. (2/1)
Fig. 350. The nail bed of the great toe with the wall of the nail removed. (2/1)

The **nails** (Fig. 346—350) are thin, translucent, horny plates, situated on the dorsal surface of the terminal phalanges of the fingers and toes. Their number is, accordingly, 20. Each is strongly curved in the direction transverse to the axis of the phalanx, so that the dorsal surface is convex. The greater part of this surface of the nail is uncovered, and the nail projects as a *free border* over the distal extremity of the phalanx. The proximal thinner portion, the *root (radix)*, lies in a fold of skin and ends in a sharp, usually convex *margo occultus*, while the lateral borders are also imbedded in folds of skin. At the transition of the root into the body of the nail there is a whitish, semilunar area, the *lunula*, which is the portion of the formative area of the nail that projects beyond the nail wall. The upper convex surface of the nail is smooth, but the under surface is finely striated longitudinally, and on this surface the horny nail substance passes without delimitation into the uncornified germinal layer of the epidermis.

The surface of the phalanx upon which the concave under surface of the nail rests is termed the nail bed *(matrix unguis)*, and is a portion of the skin destitute of glands and fastened by strong bundles of connective tissue to the ungicular tuberosity of the terminal phalanx. On the surface turned toward the nail it shows longitudinal ridges *(cristae matricis)*. The groove of the skin in which the root and posterior part of the lateral borders of the nail are lodged is termed the *sulcus of the matrix*, and the fold of skin which partly covers these parts is termed the nail wall *(vallum unguis)*. Throughout the greatest part of its length the nail is firmly adherent to the nail bed, only its distal portion being free on both surfaces.

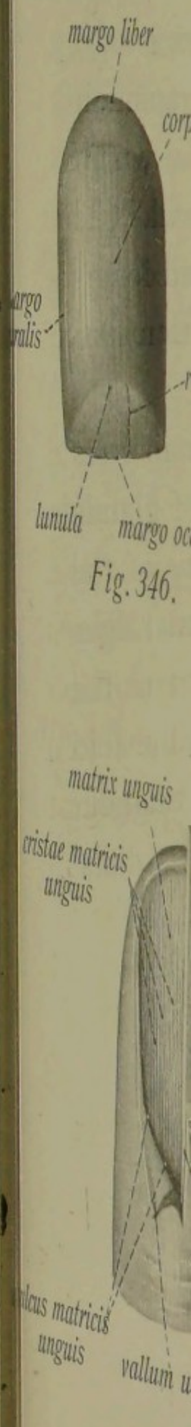

Fig. 346.

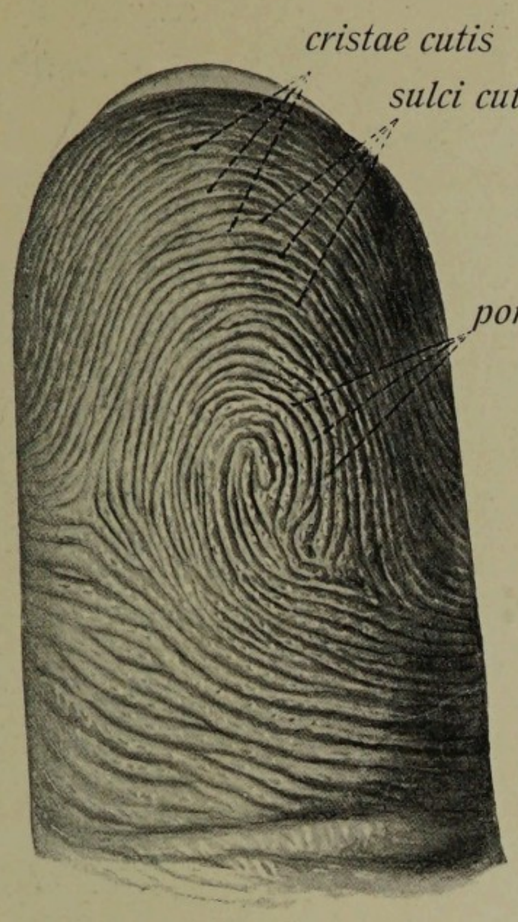

Fig. 344.

Fig. 345.

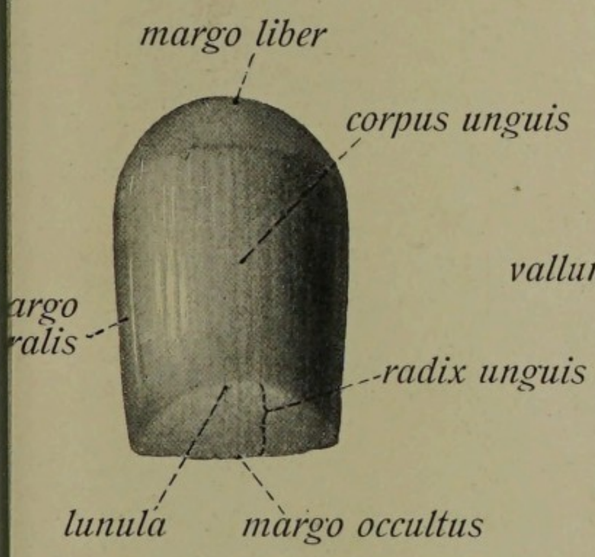

Fig. 346.

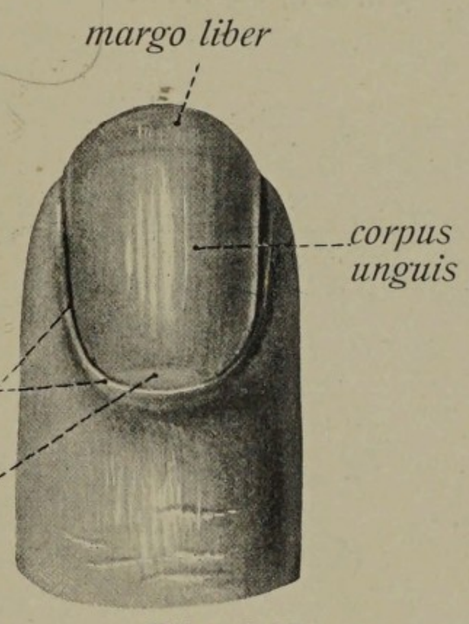

Fig. 347.

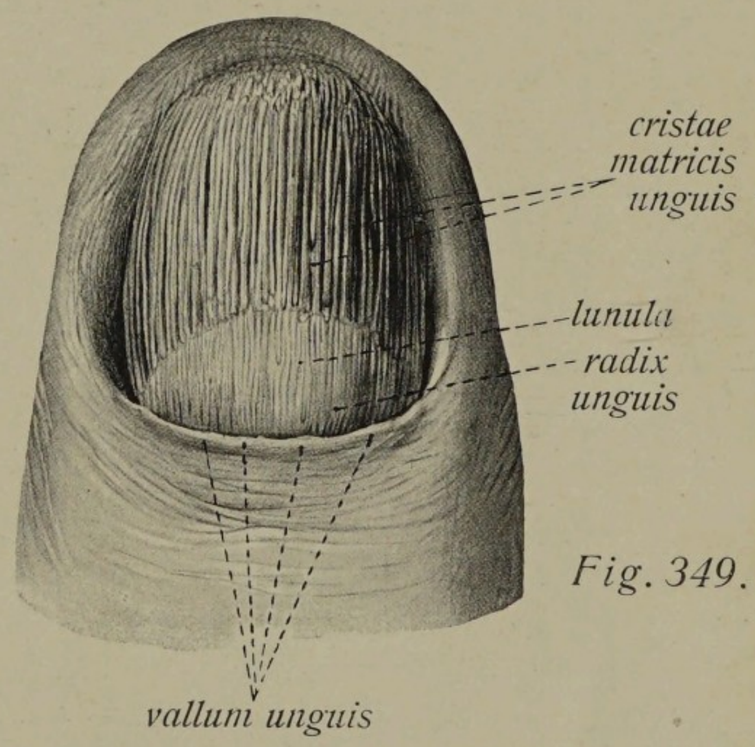

Fig. 349.

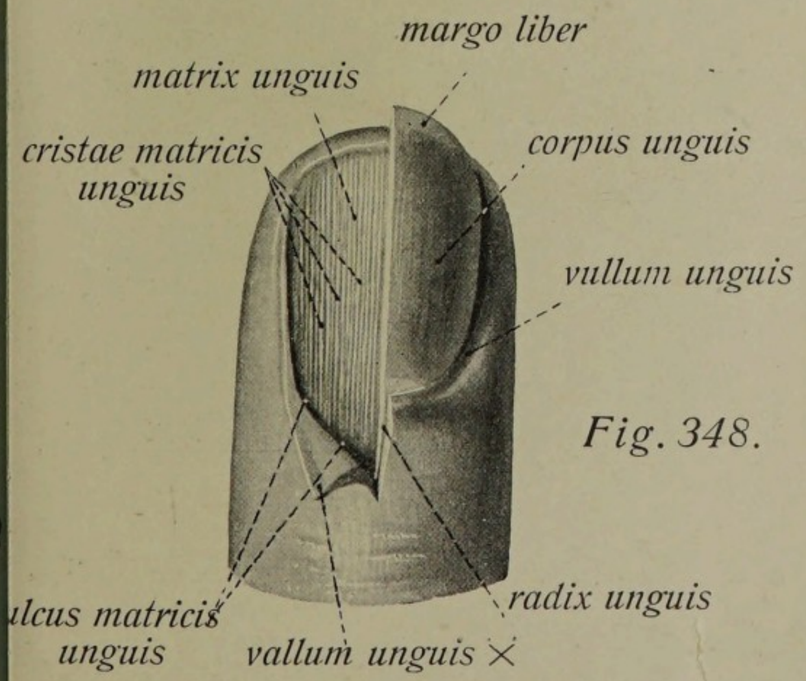

Fig. 348.

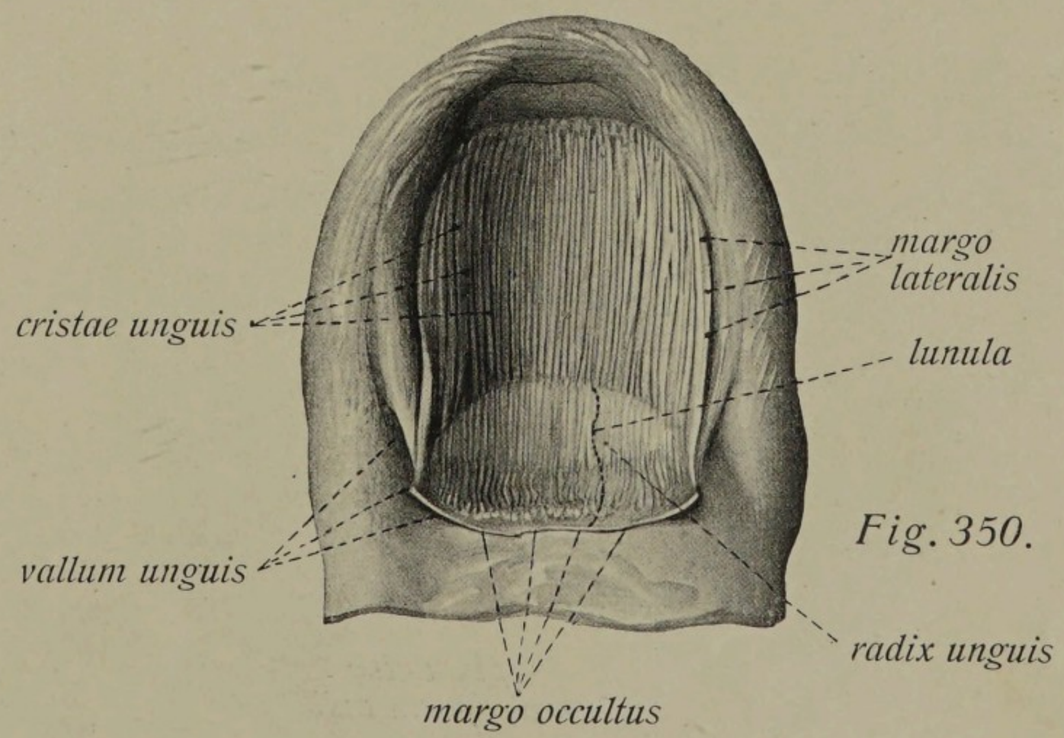

Fig. 350.

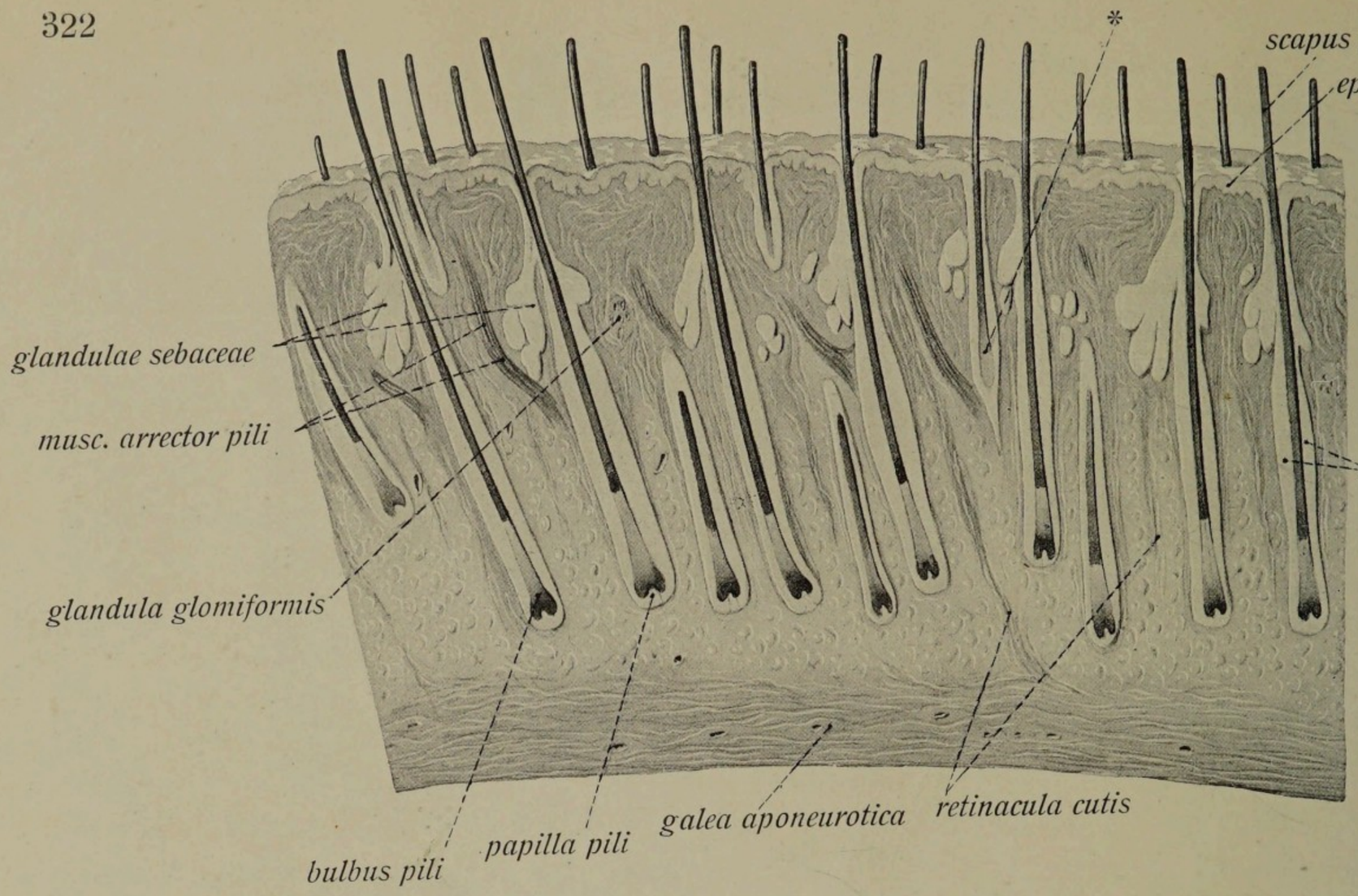

Fig. 351.

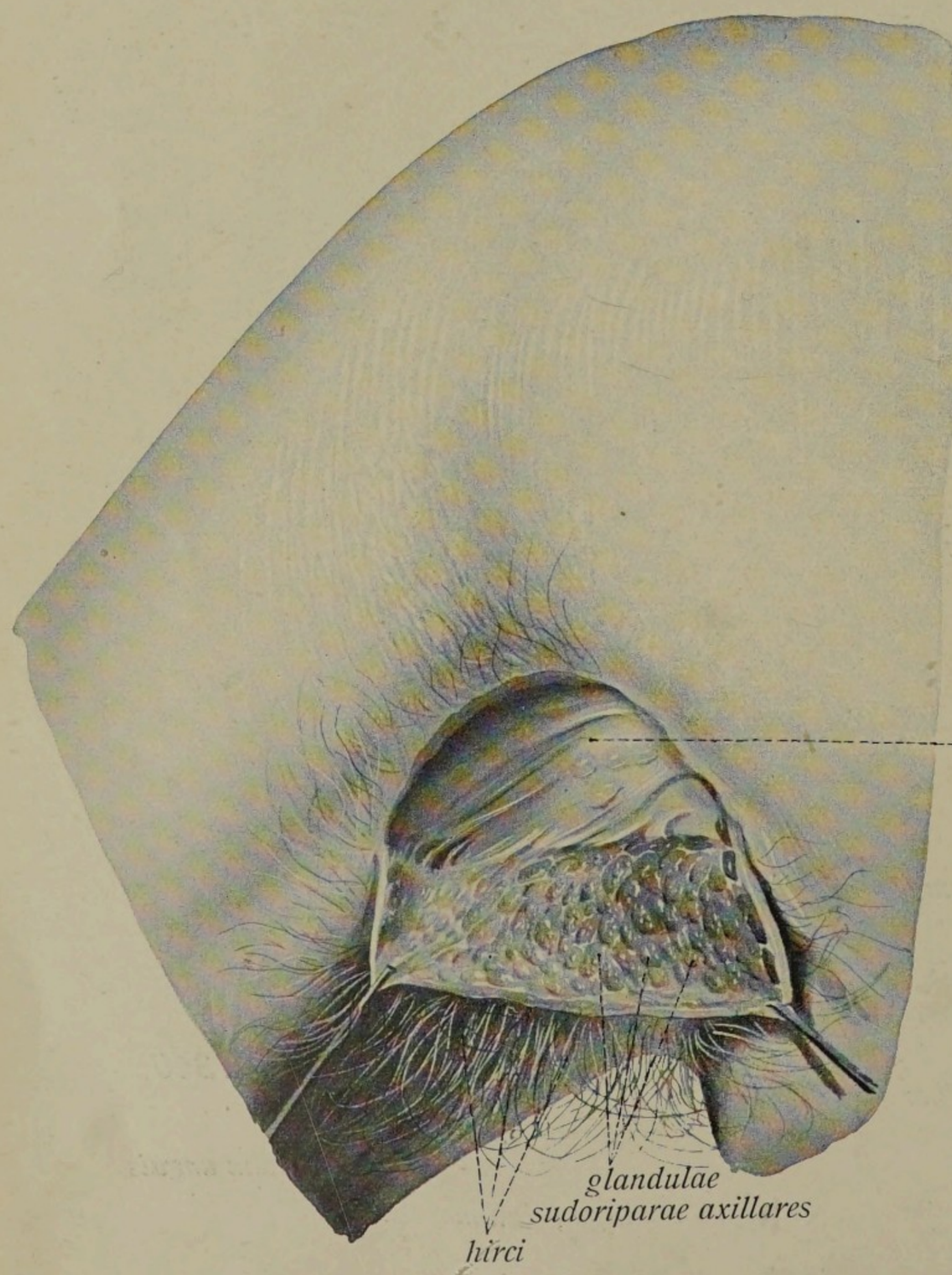

Fig. 352.

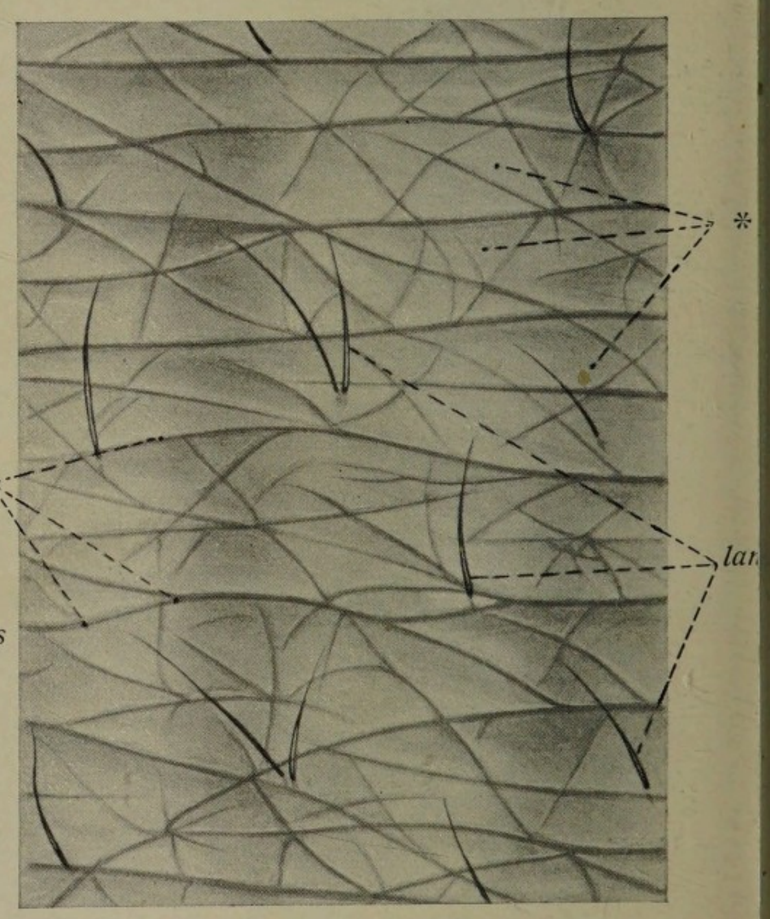

Fig. 353.

The Integument. (Cont.)

Fig. 351. A vertical section through the scalp. ($^{12}/_{1}$) * = club shaped hair.
Fig. 352. Sudoriferous glands of the axilla. ($^{1}/_{1}$)
Fig. 353. The lanugo hairs of the human skin. ($^{5}/_{1}$)
* = fields of scurfy scale. + = borders of these fields.

The Hairs, *pili*.

The hairs (Fig. 351, 353) are fine, but long, thread-like, cornified structures of the integument, of which a portion, the *scapus*, projects freely from the surface of the skin, while the root *(radix)* is imbedded in the skin, enclosed by a hair *follicle*. At the bottom of the follicle the hair is attached to a *papilla*.

Two varieties of hair are found on the skin, the *lanugo* (Fig. 353) and the stronger body hairs. The lanugo hairs are either very fine or if somewhat coarser they are always quite short; they occur on almost all regions of the skin, but are never closely set. Absolutely destitute of hairs are only the skin of the volar surface of the hand, the plantar surface of the foot, the corresponding surfaces of the fingers and toes and, in addition, the dorsal surface of the terminal phalanges of the fingers and toes, the glans penis, the inner surface of the prepuce and the labia majora, the labia minora and the red portion of the lips.

The stronger body hairs are distinguished by their greater thickness, especially by being more closely set and, usually, by their greater length. They include the eyebrows, *supercilia*; the eyelashes, *cilia*; the hairs of the nostrils, *vibrissae*; the hairs of the auricle, *tragi*; somewhat longer are the hairs of the scalp, *capilli*; the beard, *barba*; the hairs of the pubic region, *pubes*; and the hairs of the axilla, *hirci*. The stronger body hairs usually are arranged in groups, as is the case with the hairs of the head. On the bodies of embryos the hairs are arranged in distinct curved lines, termed *hair streams (flumina pilorum)*, which occasionally, as at the crown of the head, become *vortices*.

The Smaller Glands of the Skin.

Sudoriferous glands (Fig. 352) occur in almost all regions of the skin. Those of the axilla are especially large, as are also the *ciliary glands* (Glands of Moll) of the eyelids, the *circumanal glands* and the *ceruminous glands* of the external auditory meatus.

Sebaceous glands occur in connection with the hair follicles; they are imbedded in the corium and secrete an oily substance, the *cutaneous sebum*, into the follicles. They are absent from those regions where hairs are lacking, such as the palm of the hand and the sole of the foot.

Fig. 354. The lymph nodes of the right side of the neck and head of a child. (2/3)
Portions of the Sterno-mastoideus, Omohyoideus, Pectoralis major and minor are cut away to show the deep nodes. The Platysma is removed.

The Lymph Nodes and Plexuses of the Neck and Head.

1. *Posterior auricular nodes*, very small nodes on the origin of the Sternomastoideus, behind the ear.

2. *Occipital nodes*, inconstant, on the attachment of the Trapezius.

3. *Anterior auricular nodes*, small (3—4). They lie superficially on the parotid gland, in front of the ear, and receive lymphatic vessels from the temporal region, their efferents passing to the superficial cervical nodes.

4. *Parotid nodes*, small nodes in the substance of the parotid gland.

5. *Deep facial nodes*, lie on the Bucinator and the lateral wall of the pharynx, and receive afferents from the deep parts of the face.

6. *Submaxillary nodes*, 8 or more, some of them rather large, in the triangle between the base of the mandible and the Digastricus; some, termed the *submental nodes*, lie under the Mylohyoideus. They receive afferents from the anterior part of the face and the region of the chin, and their efferents pass to the superficial and deep cervical nodes.

7. *Superficial cervical nodes*, lie on the lateral surface of the neck, partly covered by the Platysma. They lie on the lateral surface of the Sternomastoid, in the region of its posterior border and along the lower border of the parotid gland.

8. *Superior deep cervical nodes*, 10—15 partly of large size, lie in the carotid fossa, in the neighborhood of the internal jugular vein and the bifurcation of the common carotid artery. Their afferents drain the interior of the skull, the pharynx, tympanic cavity, tuba auditiva, etc. and their efferents pass directly into the succeeding group.

9. The *inferior deep cervical nodes* extend along the lower part of the internal jugular vein into the supraclavicular fossa. Since they receive the efferents from the superior cervical nodes and, in addition, independent vessels from the lower part of the thyreoid gland and larynx, from the trachea and oesophagus, these glands are in the pathway of all lymph channels of the head and neck, and form, with the other cervical nodes, the *jugular plexus*.

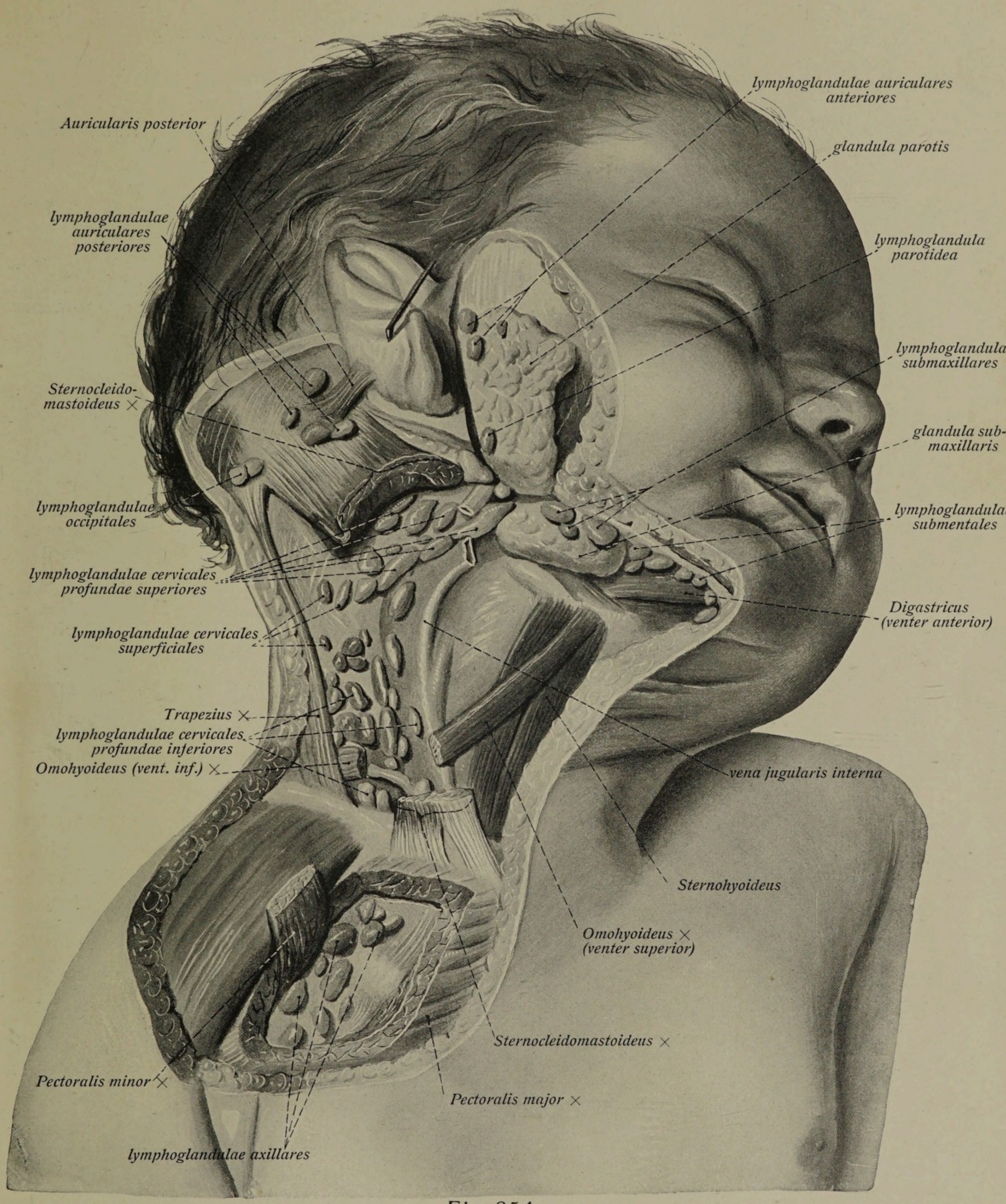
Auricularis posterior
lymphoglandulae auriculares posteriores
Sternocleido-mastoideus ×
lymphoglandulae occipitales
lymphoglandulae cervicales profundae superiores
lymphoglandulae cervicales superficiales
Trapezius ×
lymphoglandulae cervicales profundae inferiores
Omohyoideus (vent. inf.) ×
Pectoralis minor ×
lymphoglandulae axillares
lymphoglandulae auriculares anteriores
glandula parotis
lymphoglandula parotidea
lymphoglandulae submaxillares
glandula sub-maxillaris
lymphoglandulae submentales
Digastricus (venter anterior)
vena jugularis interna
Sternohyoideus
Omohyoideus × (venter superior)
Sternocleidomastoideus ×
Pectoralis major ×

Fig. 354.

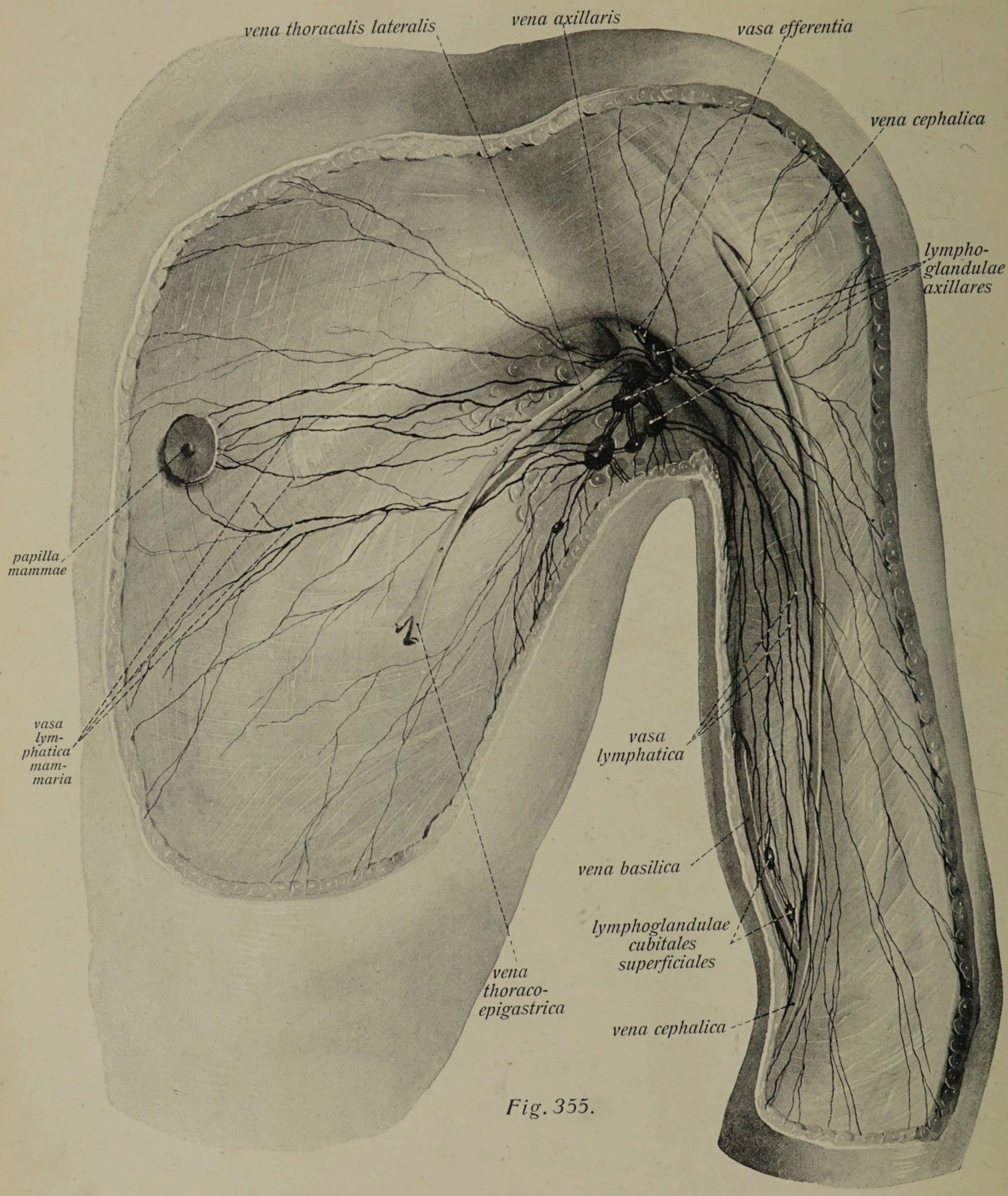
vena thoracalis lateralis
vena axillaris
vasa efferentia
vena cephalica
lympho-
glandulae
axillares
papilla
mammae
vasa
lym-
phatica
mam-
maria
vasa
lymphatica
vena basilica
lymphoglandulae
cubitales
superficiales
vena
thoraco-
epigastrica
vena cephalica

Fig. 355.

The Lymphatic System. (Cont.)

Fig. 355. The superficial lymph vessels and nodes of the arm, the anterior thoracic wall and the axilla. ($^1/_2$) The lymph vessels have been injected with india ink.

The Lymph Nodes and Vessels of the Upper Extremity.

1. *Superficial cubital nodes*, 1—2 small nodes, beside the basilic vein in the region of the cubital fossa.

2. *Deep cubital nodes*, deep in the cubital fossa beside the brachial artery and vein.

3. *Axillary nodes* (Fig. 355), numerous and in part moderately large. The majority are imbedded in the fat tissue of the axillary cavity in the vicinity of the axillary artery and vein, some superficially, others more deeply seated. They receive the drainage of the entire upper extremity, including the shoulder region, the lower part of the back of the neck, the posterior and anterior walls of the thorax, and the mammary gland. They form the *axillary plexus* and communicate with the thoracic duct by the subclavian trunk on the left side and by the right lymphatic trunk on the right.

The axillary lymph nodes may be arranged in the following groups, which are, however, not sharply defined:

a) *Subscapular nodes* in the region of the subscapular vessels. They receive the lymph from the arm, especially from the radial side.

b) *Brachial nodes* which form the most distal group. They are four to six in number, situated at the beginning of the axillary vein and receive the lymph from the free extremity, especially that from the ulnar side which has already passed the cubital nodes.

c) *Intermediate (central) nodes*, three to six usually large nodes, imbedded in the axillary fat and receiving the efferent ducts of the two preceding groups.

d) *Infraclavicular nodes*, small but numerous (10—11) nodes situated along the upper border of the Pectoralis minor.

4. Outside the axillary region are the *pectoral (subpectoral) nodes*, one to three, of moderate size, situated along the lower border of the Pectoralis major and along the lateral thoracic vessels. They receive the lymph from the thoracic and upper part of the abdominal walls.

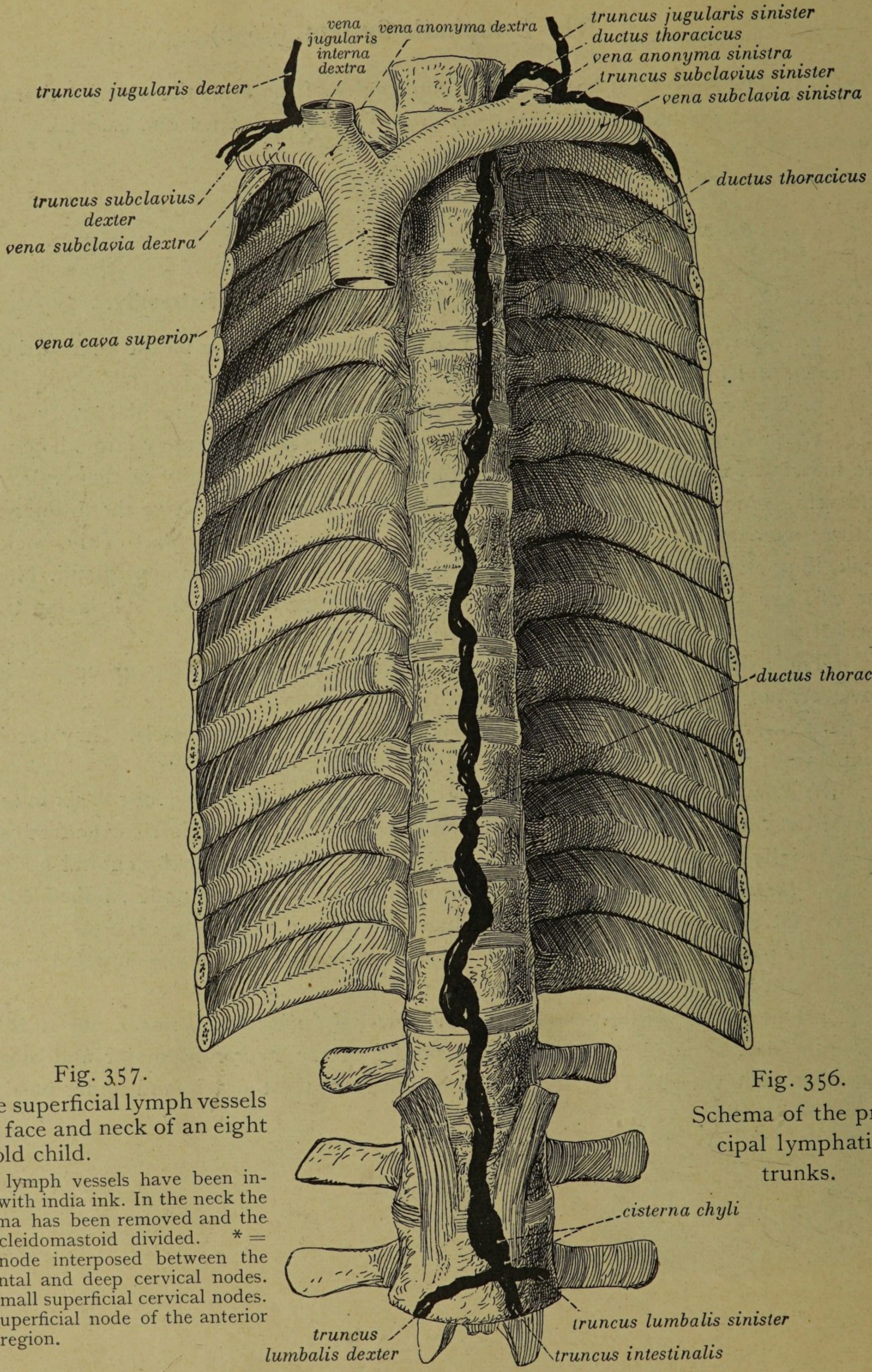

Fig. 357.

The superficial lymph vessels of the face and neck of an eight year old child.

The lymph vessels have been injected with india ink. In the neck the Platysma has been removed and the Sternocleidomastoid divided. * = small node interposed between the submental and deep cervical nodes. ** = small superficial cervical nodes. + = superficial node of the anterior cheek region.

Fig. 356.

Schema of the principal lymphatic trunks.

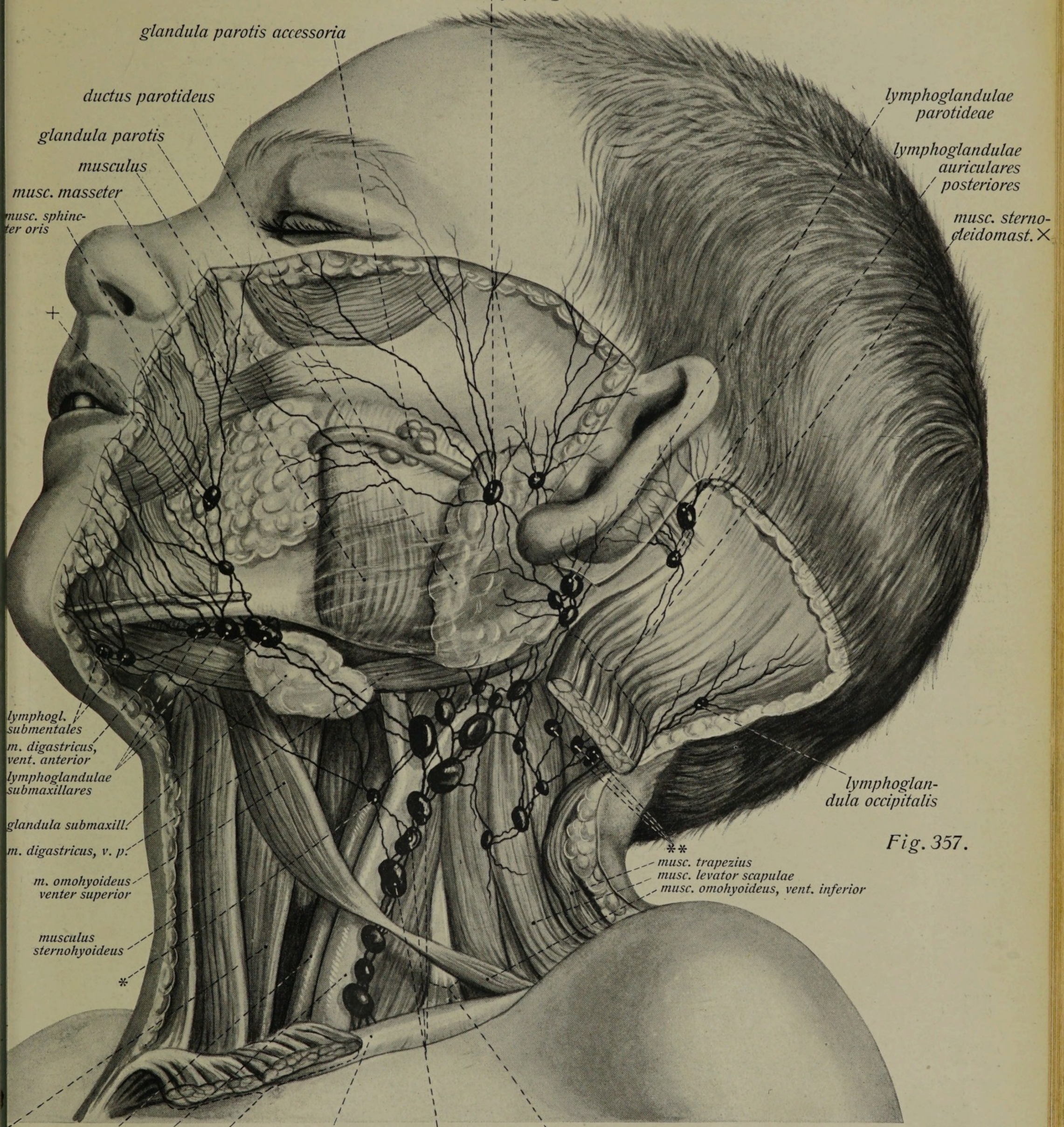
lymphoglandulae auriculares anteriores
glandula parotis accessoria
ductus parotideus
glandula parotis
musculus
musc. masseter
musc. sphinc-ter oris
lymphoglandulae parotideae
lymphoglandulae auriculares posteriores
musc. sterno-cleidomast. ×
lymphogl. submentales
m. digastricus, vent. anterior
lymphoglandulae submaxillares
glandula submaxill.
m. digastricus, v. p.
m. omohyoideus venter superior
musculus sternohyoideus
lymphoglan-dula occipitalis
**
musc. trapezius
musc. levator scapulae
musc. omohyoideus, vent. inferior
usc. sterno-hyreoideus
rt. carotis ommunis
vena jugularis interna
musc. sternocleidomastoideus ×
clavicula
lymphoglandulae cervicales profundae superiores
plexus brachialis

Fig. 357.

Fig. 358.

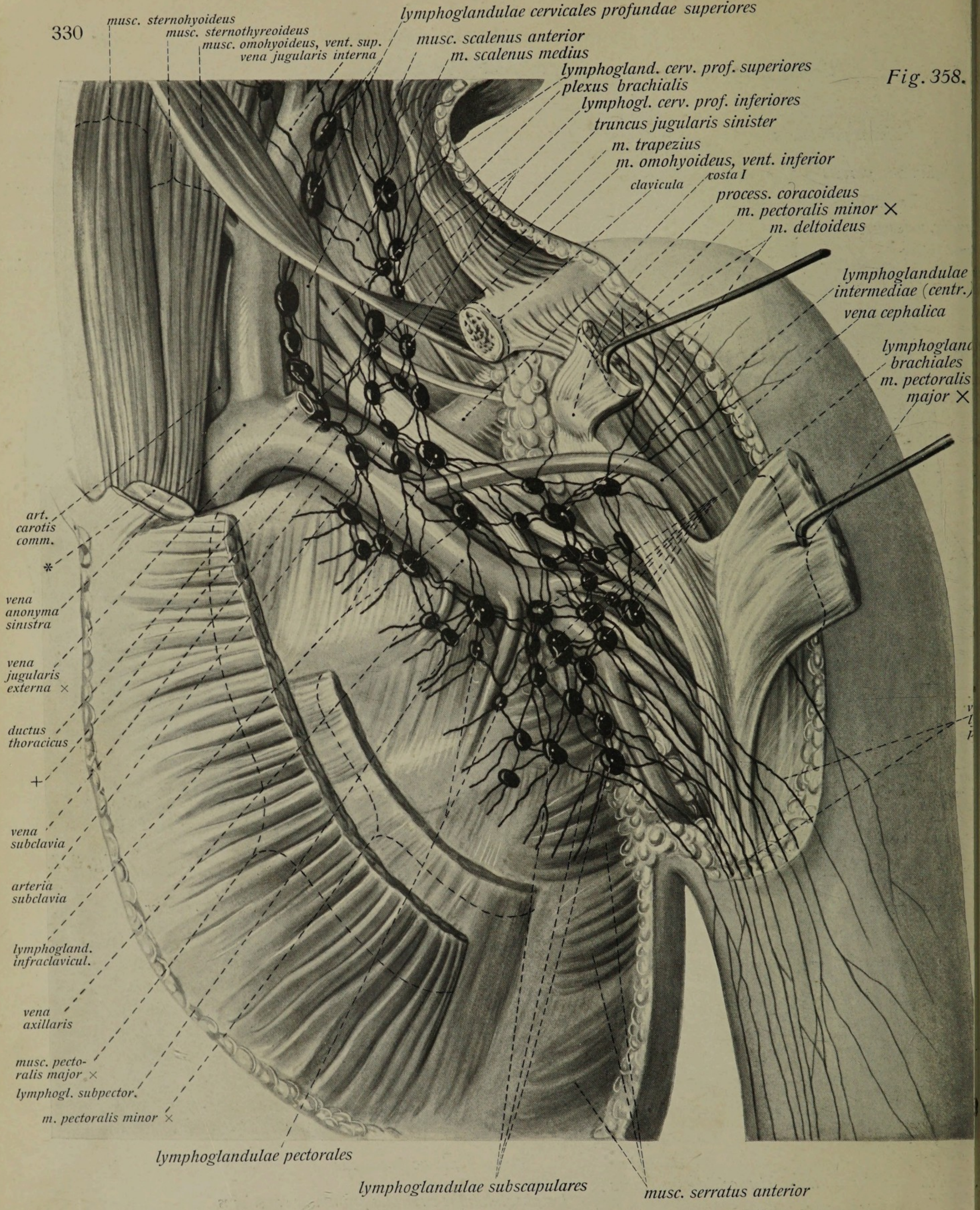
musc. sternohyoideus
musc. sternothyreoideus
musc. omohyoideus, vent. sup.
vena jugularis interna
lymphoglandulae cervicales profundae superiores
musc. scalenus anterior
m. scalenus medius
lymphogland. cerv. prof. superiores
plexus brachialis
lymphogl. cerv. prof. inferiores
truncus jugularis sinister
m. trapezius
m. omohyoideus, vent. inferior
clavicula
costa I
process. coracoideus
m. pectoralis minor ×
m. deltoideus
lymphoglandulae intermediae (centr.)
vena cephalica
lymphoglandulae brachiales
m. pectoralis major ×
art. carotis comm.
*
vena anonyma sinistra
vena jugularis externa ×
ductus thoracicus
+
vena subclavia
arteria subclavia
lymphogland. infraclavicul.
vena axillaris
musc. pectoralis major ×
lymphogl. subpector.
m. pectoralis minor ×
lymphoglandulae pectorales
lymphoglandulae subscapulares
musc. serratus anterior

The Lymphatic System. (Cont.)

Fig. 358. The deep lymphatics of the left lower cervical region and the left axilla of an eight year old child. (1/1)
The lymphatics have been injected with india ink. In the neck the Sternocleidomastoid and the clavicle have been removed; in the thoracic region the Pectorales major and minor have been divided. * = sternoclavicular articulation. + = left subclavian artery.

The Large Lymphatic Trunks.

I. The *thoracic duct* (see also Fig. 18 and 116) begins at the level of the second lumbar vertebra by the union of the lumbar and intestinal trunks. In its first part it is enlarged to a spindle-shaped structure the *cisterna chyli*, above which it runs as a thin-walled, plexus-like trunk through the aortic opening of the diaphragm, behind and to the right of the aorta. It then continues vertically upwards over the anterior surface of the thoracic vertebrae, between the thoracic aorta and the vena azygos, as far as the fourth cervical vertebra, where it inclines towards the left, passing behind the oesophagus, and passes through the superior aperture of the thorax to open into the angle formed by the left internal jugular and the left subclavian vein or into one or the other of these venous trunks. Its roots are:

1. The *right* and *left lumbar trunks*, two plexus-like stems which convey the lymph from the lower limb and the pelvis.

2. The *intestinal trunk*, an unpaired stem, which conveys the lymph from the abdominal portion of the digestive tract.

In addition, the thoracic duct receives lymph vessels from the wall of the thorax, the *left jugular trunk* that conveys the lymph from the left side of the head and neck, and the *left subclavian trunk* which carries that from the left upper extremity. Furthermore, it receives lymph from the thoracic viscera of the left side as well as from the left thoracic wall.

II. The *right lymphatic duct* opens at the angle formed by the right internal jugular and the right subclavian vein, or into the right innominate vein. It has the following roots:

1. The *right jugular trunk* drains the deep cervical nodes of the right side and carries the lymph from the right side of the head and neck.

2. The *right subclavian trunk* which drains the right axillary nodes and carries the lymph from the right upper extremity.

3. The *right broncho-mediastinal trunk* which is formed by the efferent vessels of the bronchial and mediastinal nodes and carries the lymph from the right thoracic wall, the right lung, the heart, etc.

The Lymphatic System. (Cont.)

Fig. 359. The lymphatic plexuses and nodes of the false and true pelves and their connections with the lymph vessels of the lower extremity and the viscera. (1/2)
The lymph vessels have been injected with india ink.

The Lymphatic Nodes of the Pelvis.

1. *Hypogastric nodes* lie on the side walls of the pelvis, beside the internal iliac (hypogastric) blood vessels, and form the *hypogastric plexus*. They receive some vessels from the thigh and, in addition, the deep lymphatics from the gluteal region, the perineum and the posterior part of the external genitalia, together with those from the pelvic viscera. The efferents pass to the lumbar plexus.

2. *Sacral nodes* situated partly behind the rectum, partly in the mesorectum in front of and below the promontory. They collect principally the lymph of the rectum and form the *middle sacral plexus*. Their efferents pass to the lumbar nodes.

The Lymph Nodes and Plexuses of the False Pelvis.

1. *Iliac nodes*, large nodes situated along the iliac blood vessels and connected by afferents and efferents with the deep inguinal nodes.

2. *Lumbar nodes* about 12 in number lying in the lumbar plexus along the common iliac vessels and at the bifurcation of the aorta. They receive the efferent vessels from the iliac, hypogastric and sacral nodes and in addition vessels from the testis and epididymis and in the female from the ovary, uterine tubes and part of the uterus. Their strong efferent vessels form the lumbar trunk.

The Lymph Nodes and Plexuses of the Thorax.

1. *Bronchial nodes*, divisible into the *pulmonary nodes* in the substance of the lung tissue; the *bronchial nodes* in the narrower sense, 20—30 in number, larger and situated in the hilus of the lung and along the bronchi as far as the bifurcation of the trachea, and the *tracheal nodes*, which are small and scattered sparingly along the trachea. These nodes in the adult are usually blackish, in some cases deep black (coal dust). Their efferent vessels are the principal constituents of the broncho-mediastinal trunk.

2. *Intercostal nodes*, very small nodes, situated in the neighborhood of the heads of the ribs.

3. *Sternal nodes*, very small nodes along the internal mammary vessels. They form the *mammary plexus*.

4. *Anterior mediastinal nodes* closely associated with the preceding, but lying behind them. Their efferents unite with those of the bronchial nodes to form the broncho-mediastinal trunk.

5. *Posterior mediastinal nodes*, small nodes situated along the thoracic aorta.

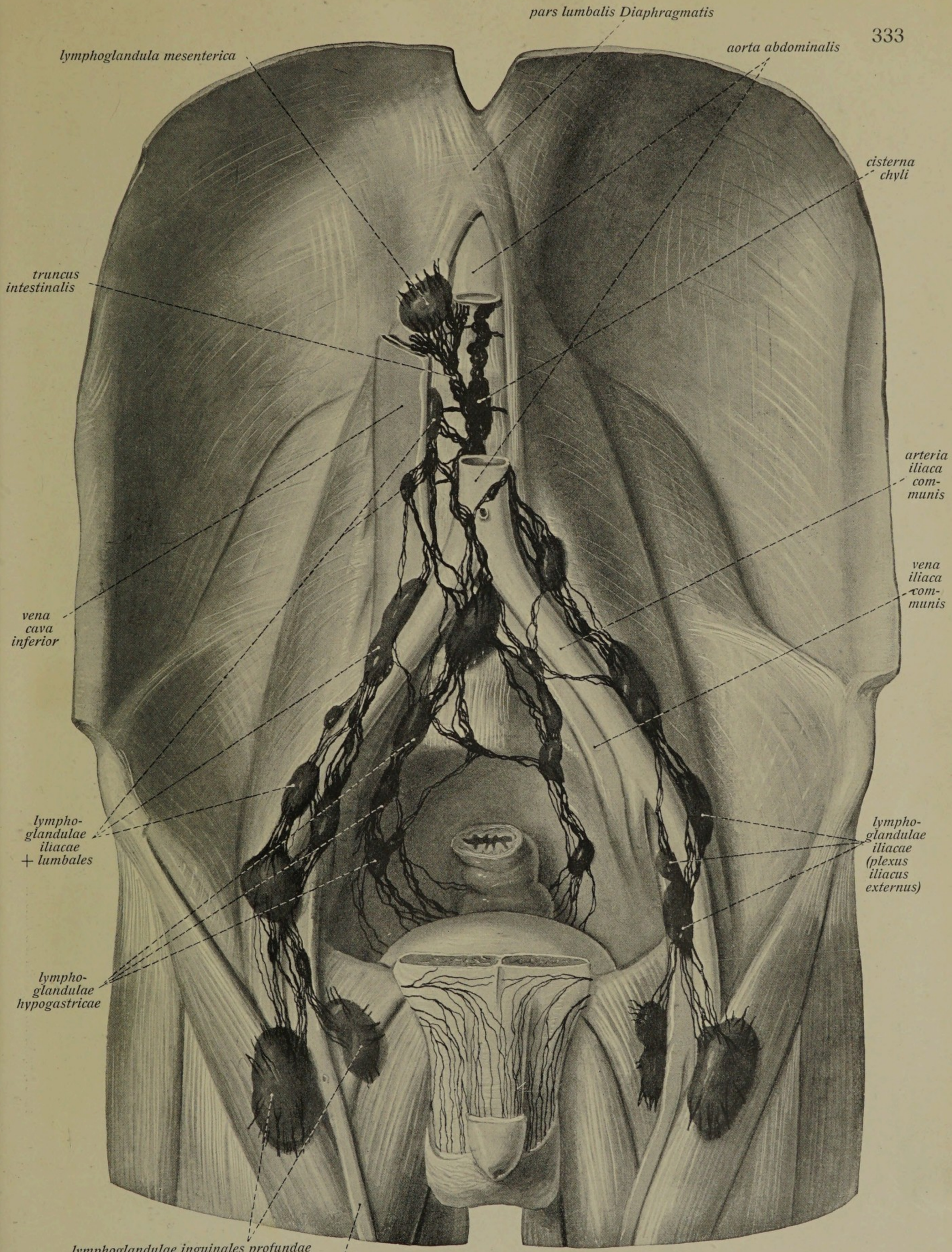
pars lumbalis Diaphragmatis
lymphoglandula mesenterica
aorta abdominalis
cisterna chyli
truncus intestinalis
arteria iliaca communis
vena iliaca communis
vena cava inferior
lympho-glandulae iliacae + lumbales
lympho-glandulae iliacae (plexus iliacus externus)
lympho-glandulae hypogastricae
lymphoglandulae inguinales profundae
vena saphena magna

Fig. 359.

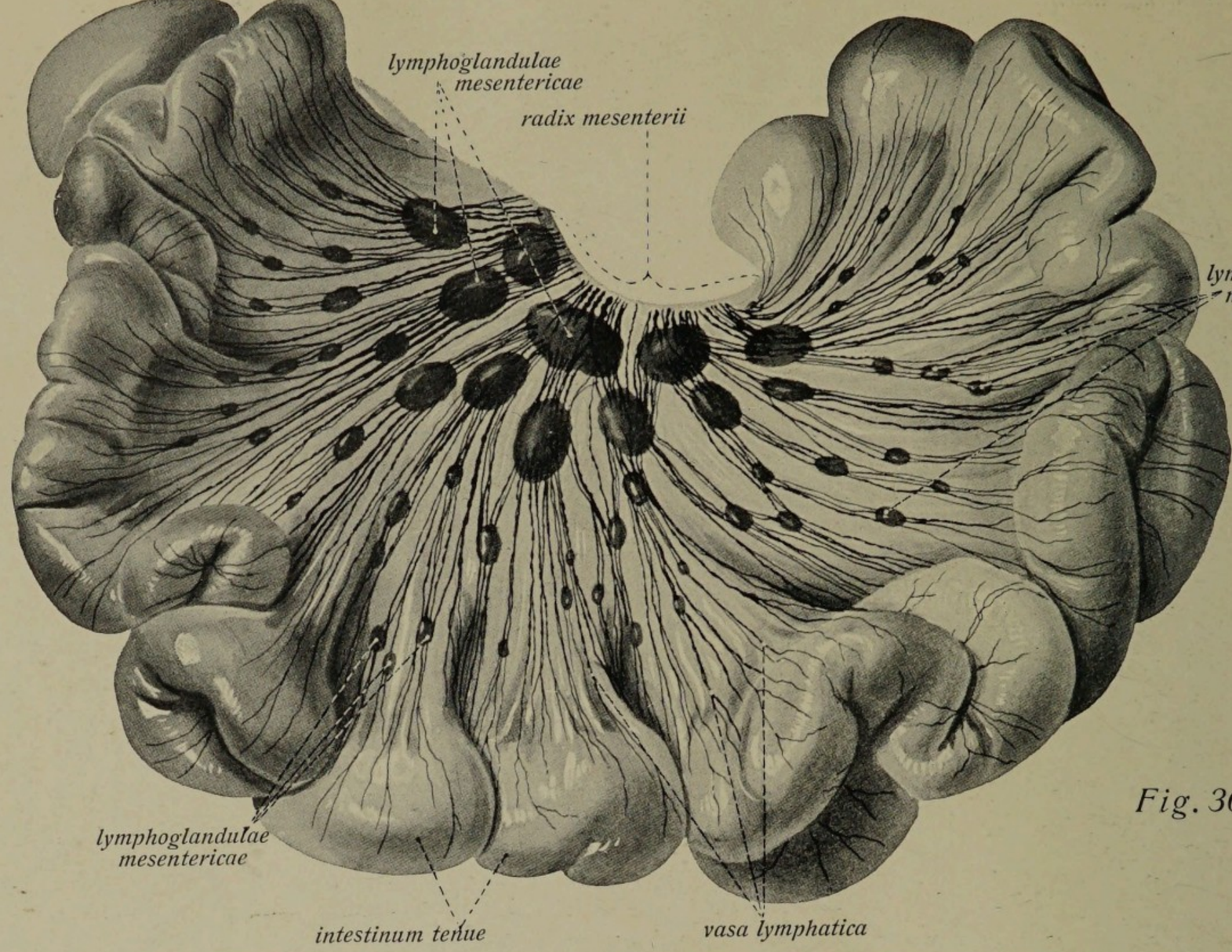

Fig. 360.

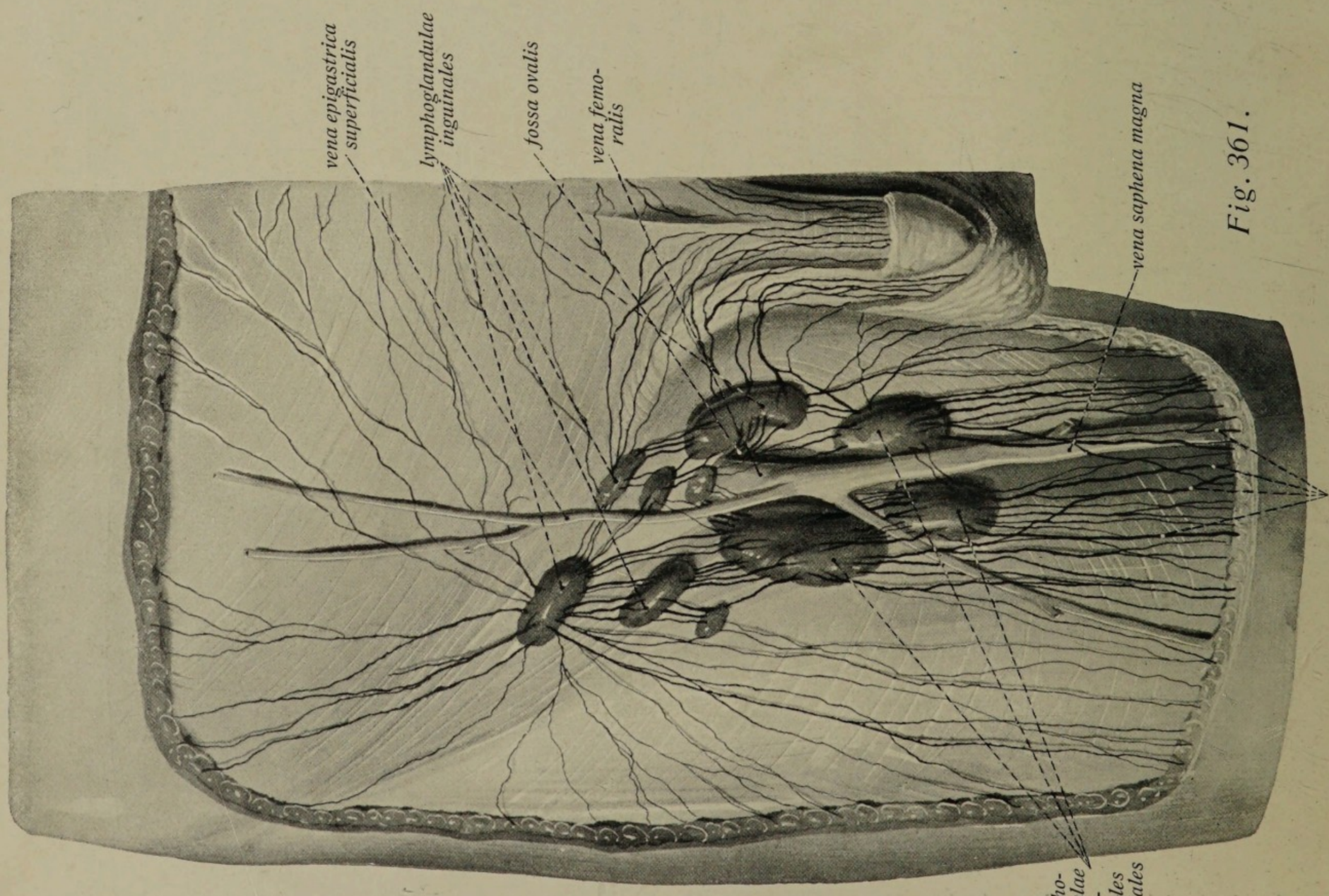

Fig. 361.

The Lymphatic System. (Cont.)

Fig. 360. The lymph vessels and nodes of the mesentery. (1/2) Injection with india ink.
Fig. 361. The lymph vessels and nodes of the thigh, the inguinal region and the external genitalia. (1/2) Injection with india ink.

The Lymph Nodes and Plexuses of the Abdomen.

1. The *mesenteric nodes* constitute the largest group of lymph nodes in the body, being about 100 in number. They lie in the mesentery, arranged in several rows, those nearest the intestine being the smallest. The afferents of these nodes lie in the wall of the intestine and are known as the chyle vessels.

2. The *mesocolic nodes*, smaller and less numerous than the preceding, receive the lymph vessels from the large intestine and their efferents open into the intestinal trunk.

3. The *coeliac nodes*, lie behind the stomach, pancreas and duodenum, in close proximity to the largest mesenteric nodes. They receive the lymph from the organs in the upper part of the abdominal cavity and, with the upper mesenteric nodes, form the *coeliac plexus*. Their efferents unite with those of the mesenteric nodes to form the intestinal trunk.

4. The *superior gastric nodes*, small, along the lesser curvature of the stomach; the *inferior gastric nodes*, also small, along the greater curvature of the stomach; the *pancreatico-lienal (pancreatico-splenic)* nodes in the hilus of the spleen; and the *hepatic nodes* in the portal fissure of the liver and the hepato-duodenal ligament.

The Lymph Nodes and Plexuses of the Pelvis, and Lower Extremity.

All the lymph vessels of the pelvis and of the lower extremity drain on either side into the lumbar trunk, which takes origin from the *lumbar plexus*. This is formed by the union of vessels from the *hypogastric plexus* of the pelvis with vessels from the lower extremity, which form the *external iliac plexus*.

The Lymph Nodes of the Lower Extremity.

1. *Inguinal nodes*, 3—5 lie under the skin along the inguinal (Poupart's) ligament, with their long axis parallel with it.

2. *Superficial subinguinal nodes*, 7—12, partly very large, lie parallel with the long axis of the thigh in the region of the fossa ovalis. They are superficial, under the skin of the thigh.

3. *Deep subinguinal nodes*, forming the direct continuation of the preceding. They lie deeply in the ileo-pectineal fossa beside the femoral artery and vein.

These three groups of nodes in the inguinal region form the *inguinal plexus*. In a somewhat variable manner they receive the superficial and deep lymphatics of the lower extremity, the superficial vessels of the gluteal region, those of the lower part of the anterior abdominal wall, of the penis (clitoris), the lateral and anterior surfaces of the scrotum (labia majora and mons pubis). Their efferent vessels pass to the iliac nodes.

The figures ref
index is to ena
In general the
designation is
the part

The **number**

aequator lentis
ala cinerea 20
— — lobuli c
alveus 190
ampulla ductu
— ae membra
— osseae 289-
anguli oculi (l
angulus iridis
ansa (nervi) hy
— lenticularis
— pedunculari
— subclavia (
117
anthelix 332—
antitragus 332
antrum mastoi
anulus ciliaris
— fibrocartilag
— iridis major
— — minor 2
— tendineus co
aorta abdomina
— ascendens 4
— thoracalis de
apertura lateral
— mediana (m
— tympanica c
— vestibularis
apex columnae
apparatus lacri
aquaeductus ce
arachnoidea en
— spinalis 124

INDEX

of the parts shown in the illustrations.

The figures refer to the numbers of the **illustrations** of the volume, not to the numbers of the pages. The index is to enable the reader to find the part in question in the various illustrations in the shortest time. In general the name is given wherever it occurs as designation of a figure except in places where such designation is merely incidental. Wherever a number is enclosed in brackets, it signifies that, although the part in question is plainly visible in the picture, it is not specially designated thereon.

The **numbers** in **bold type** indicate the figures which best represent the objects named in the index.

A.

aequator lentis 250, 251
ala cinerea 206, 207, 222
— — lobuli centralis 232
alveus 190
ampulla ductus lacrimalis 267, 268
— ae membranaceae 285, 287
— osseae 289—292, 294—296
anguli oculi (lateralis et medialis) 259—261
angulus iridis 240, 242
ansa (nervi) hypoglossi 9, 10
— lenticularis 205
— peduncularis 205
— subclavia (Vieussenii) (trunci sympathici) 115, 117
anthelix 332—334
antitragus 332—334
antrum mastoideum 303—305
anulus ciliaris 241—243, 255
— fibrocartilagineus membranae tympani 326
— iridis major 243
— — minor 243
— tendineus communis (Zinnii) 269, 277, 281
aorta abdominalis 69, 76, **80**, 82, (84), 85, 118
— ascendens 4, 5, **15**, **18**, 117
— thoracalis descendens **18**, 116, 117
apertura lateralis ventriculi quarti 174, (180)
— mediana (medialis) ventriculi quarti 180
— tympanica canaliculi chordae tympani 317
— vestibularis cochleae 292
apex columnae posterioris medullae spinalis 131
apparatus lacrimalis 267, 268
aquaeductus cerebri **149**, 177, **178**, 212, 213
arachnoidea encephali 140, 141, 143, **144**, **145**
— spinalis 124, **127**
arcus aortae 15, 18, (117)
— raninus 75
— tarsei (superior et inferior) 51, 52, (53—56, 58, 59)
— venosi digitales (dorsales) 45
— venosus dorsalis pedis 108
— — juguli 14
— plantaris 113
— volaris profundus 50
— — superficialis 49
area acustica 297, 298
— cochleae 289, 297, 298
— nervi facialis 297, 298
— parolfactoria (Brocae) 149, 178, 195
— vestibularis inferior 289, 297, 298
— — superior 289, 297, 298
areola mammae 340
arteria[1]) alveolaris inferior 55—58
— — superior posterior 57, 58, (59)
— angularis 51—59
— anonyma II 226, III 15, 18, 20, 115, (117)
— auditiva interna 135, 146
— auricularis posterior 6, (7, 8), 9, **51—59**
— — profunda 59
— arcuata 110
— axillaris 10, 11, **13**, 17, 26, 33, 34
— basilaris 144, 146, 147
— brachialis 33—39, 41
— bucinatoria 55—59
— bulbi urethrae 89
— — — vestibuli 90
— carotis communis 8, **9**, **10**, 11, 15, 20, 59, 114
— — externa 8—10, 55—59, 114
— — interna 55—57, 60—63, 66, 67, 69, 71, 72, 114, 135, **138**, 139, **146**, 147

[1]) See also arteriae.

arteria canalis pterygoidei 66, (114)
— centralis retinae (178), 236, 237, (243), 248, 249
— cerebelli inferior anterior 146
— — — posterior 146
— — superior 146, 147
— cerebri anterior 146, 147
— — media 146
— — posterior 146, 147
— cervicalis ascendens 9—11, **13**
— — profunda 11, 25
— — superficialis (7), 8—11, **13**
— chorioidea (146), 163, 166, 167
— circumflexa femoris lateralis 96, 97
— — — medialis 96, 97, (100, 101)
— — humeri anterior 26, 33
— — — posterior 16, 26, 27, 33, 34
— — — ilium superficialis 91
— — — profunda 80, 84
— — scapulae 16, 26, 27
— clitoridis 90
— coeliaca **76**, **77**, 80, 118
— colica dextra 78
— — media 78
— — sinistra 79
— collateralis media 36
— — radialis 35—43
— — ulnaris inferior 33—37, 39, 40, 43
— — — superior 33, 34, 37
— communicans anterior 146
— — posterior 146, 147
— coronaria cordis dextra 4, 5
— — — sinistra 4, 5
— cystica 76 (77)
— deferentialis 84
— dorsalis clitoridis 90
— — nasi 53—56
— — pedis 106, 110
— — penis 84, 86
— epigastrica inferior 21, 80
— — superior 21
— — superficialis 91
— ethmoidalis anterior 60, 62, 63
— — posterior 62, 63
— femoralis 91, 95—97
— frontalis 51—55, 60—62
— gastrica dextra 76, 77
— — sinistra 76, 77
— gastroduodenalis 76, 77
— gastroepiploica dextra 76, 77
— — sinistra 76, 77
— genus inferior lateralis 106, 107
— — — medialis 104, 105, 107
arteria genus media 107
— — superior lateralis 102, 106, 107
— — inferior medialis 103, 104, 107
— — suprema 95—97, 107
— glutea inferior **88**, 100, 101
— — superior **88**, 100, 101
— haemorrhoidalis inferior 89, 90
— — media 84, 85, 88
— — superior 79, 84, 85
— hepatica 76, 77
— — propria 76
— hypogastrica 80, 84, 85
— ileocolica 78
— iliaca communis 80, 82, 84, (85), **88**
— — externa 80, 82, 84, 95
— iliolumbalis 80, 88
— infraorbitalis 53—57, (58, 59), 63
— intercostalis suprema 11, **18**, (22)
— interossea communis 38, 39
— — dorsalis 38
— — recurrens 42, 43
— — volaris 38, 41—43, 48
— labialis inferior 51—54, 57
— — superior 51—54, 57, (58, 59)
— lacrimalis 60—62
— laryngea inferior 74
— — superior 8—10, 74, 75
— lienalis 76, 77
— ligamenti teretis 85
— lingualis 9, 64, 75
— lumbalis (lumbales) 80
— — ima 80
— malleolaris anterior lateralis 106, 110
— — — medialis 106, 110
— — posterior lateralis 105
— — — medialis 105
— mammaria interna 104
— masseterica 55, (56)
— maxillaris interna 56—59
— — externa 10, 13—15, 51—58
— meningea anterior 60, 62, 63, 135
— — media 57—60, 135, 136
— — posterior 72
— mentalis 53—58
— mesenterica inferior 79, 80
— — superior 77, 78, 80
— metacarpea dorsalis prima (47, 48)
— metatarsea dorsalis prima 110
— musculophrenica 21
— nasalis anterior lateralis 65, 66
— — — septi 64
— — posterior septi 64

arteria obturatoria 84, 88, 96, 97
— occipitalis 6—8 (9), **10**, **13**, 51, 52, 55, 57—59
— ophthalmica 60—62, 114, 138
— ovarica 85, 87
— palatina ascendens 57, 72, (74)
— — descendens 65, 66
— palpebralis medialis 51—54
— pancreaticoduodenalis inferior 77
— — superior 77
— penis (84), 86
— perforans prima 97, 100
— — secunda 97, 100
— — tertia 100, 107
— pericardiacophrenica 20, 21
— perinei 89, 90
— peronaea 104, 105
— pharyngea ascendens 72
— phrenica inferior 80
— plantaris lateralis 112, 113
— — medialis 112, 113
— poplitea 99, 100, 102, 104, 105, **107**
— princeps pollicis 50
— profunda brachii 33—36
— — femoris 96, 97
— — linguae 64, 75
— pudenda interna 84, 85, 88—90
— pulmonalis 4, 5
— radialis 37—41, 47, 48
— recurrens radialis 37—39, 41
— — tibialis anterior 105, 106, 110
— — ulnaris 38—40, 42
— renalis 80
— sacralis lateralis 88
— — media 80, 88
— spermatica externa 86
— — interna 80
— sphenopalatina 57—59, 65
— spinalis anterior 146, 147
— — posterior 147
— sternocleidomastoidea 9, 59
— subclavia 8—11, 13, **15**, **17**, 20
— sublingualis 64, 75
— submentalis 9, 10, 13, 57—59
— subscapularis 16, 17, 26
— supraorbitalis 51—55, 60—62
— suprarenalis media 80
— tarsea lateralis 110
— — medialis 110
— temporalis media 55—59
— — profunda anterior 57—59
— — — posterior 57—59
— — superficialis 51—59
arteria thoracalis lateralis 16, 17
— thoracoacromialis 8—10, 13—15, 17
— thoracodorsalis 16, 17, 26
— thyreoidea inferior 10, 11, 13, 29, 31
— — superior 8—10, 13, 15, 75
— tibialis anterior 105, **106**, 107, 110
— — posterior 104, 105, 107, 111—113
— transversa colli 8—11, 13—**15**, 17, 23
— — faciei 51—55, (56), 57, 58
— — scapulae 8, 11, 13, 26, 27
— tympanica anterior 57—59
— — inferior 72
— — superior 135
— ulnaris 37—40, 44, 45
— umbilicalis 2, 84, 85, 88
— uterina 85, 87
— vaginalis 85, 87
— vertebralis 10, **11**, 13, 25, 146, 147
— vesicalis inferior 84, 85, 88
— zygomaticoorbitalis 51—55
arteriae alveolares superiores posteriores 57, 58
— bronchiales 18
— ciliares anteriores 248, 249
— — posteriores 248, 249
— — — breves 248, 249
— — — longae 248, 249
— digitales dorsales 46—48
— — — (pedis) 109, 110
— — plantares 111—113
— — volares communes 44, 46, 49
— — — propriae 44, 46, 49
— epiploicae 76
— gastricae breves 76
— jejunales 78
— ileae 78
— intercostales 18, 22, 116
— intestinales 78
— labiales pudendi posteriores 90
— lumbales 80
— metacarpeae dorsales 47, 48
— — volares 50
— metatarseae dorsales 110
— nasales posteriores laterales (65), 66
— palatinae minores (65), 66
— pudendae externae 91
— scrotales anteriores 86
— — posteriores 89
— sigmoideae 79
— surales 102, 103, 107
— tarseae mediales 110
arteriola macularis inferior 243
— — superior 243

arteriola nasalis retinae inferior 243
— — superior 243
— retinae medialis 243
— temporalis retinae inferior 243
— — — superior 243
articulatio incudomalleolaris 314—318, (324)
— incudostapedia 314, 315, (324)
auricula 332
axis lentis 251
— oculi 242

B.

basis encephali 148, 174
— pedunculi 177, 212
— stapedis 311—313
brachium conjunctivum 180, 206, 207, 214
— pontis 180, 206, 207
— quadrigeminum inferius 180, 206, 207
— — superius 180, 206, 207
bulbus cornu posterioris 166, 168
— oculi 242—255
— olfactorius 149, 161, 174
— venae jugularis (internae) inferior 9, 15
— — — — superior 72, 328

C.

caecum cupulare 287
— vestibulare 287
calamus scriptorius 206
calcar avis 165, 166, 168, 169
camera oculi anterior 240, 242
— — posterior 240, 242
canales semicirculares (ossei) 289—296, 299
canalis centralis medullae oblongatae 223, 228, (229)
— — — spinalis 131, (132—134)
capitulum mallei **306—308**, 315—318, 324
capsula externa 184, 188, 190, 195, 197, 205
— interna 184, 188, 190, 195, 197, 205
— lentis 252
— nuclei dentati 235
caput columnae posterioris (medullae spinalis) 131
— nuclei caudati 163—166, 167, (173), 180, 188, 205
cartilago auriculae 332—336
— meatus auditorii 328, 335, 339
— tubae auditivae 329—331
caruncula lacrimalis 259—261, 267, 268
cauda equina 119, 121, 130
— helicis 333, 334
— nuclei caudati 180, 184, **190**
cavum conchae 283
— septi pellucidi 164, 166, 167, 173, 195
— subarachnoideale 124, 143, 190
— tympani 302, 303, (304, 305), 314, 315, (316), 319—321, 324
cellulae mastoideae 301, 303—305, 315, 328
— tubariae 323
— tympanicae 303, 304
centrum semiovale (Vieussenii) 162, (163)
cerebellum 148, (149), 173, 174, 178, 183, **230—235**
cervix columnae posterioris (medullae spinalis) 131
chiasma opticum 148, 149, 174, 177, 178, 183, 196
chorda tympani 59, 66, 67, 69, 71, 114, 309, 317—319, 325, 328
chordae oesophageae n. vagi 116, 117
chorioidea 240—246
cilia 260, 262, 283
circulus arteriosus (Willisii) (146)
— — iridis major 249
— — — minor 249
cisterna (subarachn.) ven. cerebri magnae 166
— — cerebellomedullaris 144
— — interpeduncularis 144
— — fossae cerebri lateralis 144
— — chiasmatis 144
cisternae subarachnoideales 144
claustrum 184, 188, 190, 195—197, 205
clava 206, 207
cochlea 285—296, 299—301, 328
colliculus facialis 206, 215
collum mallei 306—308
columna anterior medullae spinalis 113, 129, 131, (132—134)
— fornicis 149, **161**, 165, 167, 178, 180, 184, 188, 197
— lateralis medullae spinalis 131
— posterior medullae spinalis 129, 131, (132—134)
commissura alba anterior medullae spinalis 131
— cerebri anterior 149, 158, 161, 178, 180, **183**
— — posterior 149, 165, 173, 178
— grisea anterior medullae spinalis 131
— hippocampi 163, 167
— posterior medullae spinalis 131
concha auriculae 332
confluens sinuum 136
conus medullaris medullae spinalis 122
cornea 240, 242, 247, 248
corona ciliaris 244, 245, 247
corpora (corpus) mamillaria **148**, 149, 157, **161**, 174, 177, 178, 184, **189**

corpora quadrigemina 149, 165, 173, 178, **180**, **188**, **206**, 207
corpus adiposum orbitae 277—280, 283, **284**
— callosum 148, 149, 158, 161, **162**, 163, 164—167, 178, 189, 195—197, 205
— ciliare 242, 244, 247
— geniculatum laterale 177, 180, 206, 207
— — mediale 177, 180, 206, 207
— incudis 309, 310, 313, 316—318, 324
— medullare hemisphaerii cerebelli 234, 235
— — vermis 178
— pineale 149, **165**, 173, 178, 180, 188
— restiforme 206, 207, 220, 221
— striatum 166, 167, 173, 180
— trapezoideum 215
— unguis 346—348
crista fenestrae cochleae 292
— transversa (meatus acustici interni) 289, 297, 298
— vestibuli 292, 302
cristae cutis 344
— matricis unguis 348, 349
— unguis 350
crura anthelicis 332
— stapedis 311, 313, 321
crus anterius stapedis 311, 313
— breve incudis 309, 310, 314, 317, 318
— commune canal. semicircularis 289, 290, 294, 295
— fornicis 161, 163, 164, 166, 167
— helicis 332, 334
— longum incudis 309, 310, 314, 317
— posterius stapedis 311, 313
— simplex canal. semicircul. lateralis 289, 294, 296
cuneus 149, 158, 161
cupula cochleae 286, 287, 290, 291, 294, 295
cutis 351
cymba conchae 332

D.

decussatio brachii conjunctivi 178, 213
— lemniscorum 223
— nervorum trochlearium 208, 209
— pyramidum 122, 174, 184, 228, 229
diaphragma sellae 135
diencephalon 150, 151
digitationes hippocampi 165, 168—170
ductus arteriosus (Botalli) 2
— cochlearis 285—288
— endolymphaticus 285, 287
— lacrimalis 267, 268
ductus lactiferus 342, 343
— nasolacrimalis 266—269
— semicirculares 285—287, 315
— thoracicus 18, 22, 356, (359)
— utriculosaccularis 287
— venosus (Arantii) 1, 2
dura mater encephali 135, 136, 139, 140, 143
— — spinalis 121, 122, 124, 127, 130

E.

eminentia arcuata (ossis temporalis) 303
— (trigonum) collateralis 170
— conchae 335, 336
— medialis fossae rhomboideae 206
— pyramidalis 303—305, 321
— scaphae 335, 336
— fossae triangularis 335, 336
ependyma ventriculi lateralis 189
epidermis 351

F.

facies anterior corneae 242
— — iridis 242
— — lentis 242
— posterior corneae 242
— — iridis 242
— — lentis 242
falx cerebelli 136
— cerebri 135, 136, 140, 141, 143
fascia bulbi 278, 279, 282, **283**
— dentata hippocampi 161, 168, 170—172, 190
fasciculus anterior proprius 125, 126
— anterolateralis superficialis 125, 126
— cerebellospinalis 125, 126
— cerebrospinalis 125, 126
— — lateralis 125, 126
— cuneatus 125, 126, 206, 207, 229
— gracilis 125, 126, 206, 207, 229
— longitudinalis inferior 176
— — superior 175
— — pontis 178, 184, 214, 215
— — medialis 213—215, 220, 221
— obliquus pontis 174
— thalamomamillaris 161
— uncinatus 175
fasciola cinerea 158, 172
fastigium 178
fenestra cochleae 289—292, 294, 296, 301, 305
— vestibuli 290, 291, 294, 303—305
fibrae arcuatae (cerebri) 176
— — externae 220—222
— — internae 222

fibrae cerebelloolivares 221
— (circulares et meridionales) m. ciliaris 242
— pontis profundae 214, 215
— — superficiales 214, 215
— zonulares 247
fila lateralia pontis 207
— radicularia nervorum spinalium 127—129
filum terminale durae matris spinalis 122
— — (medullae spinalis) 120, 122
fimbria hippocampi (fornicis) 161, 165, 169—172, 190
fissura antitragohelicina 334
— calcarina 149, 157, **158**, 161, 163, 164, 168
— cerebri lateralis **153**, 181, 184, 188, 196, 197, 205
— collateralis 157—159, 170
— hippocampi 170
— longitudinalis cerebri 154, 157, 162, 163—167, 174, 183, 184, **196**, **197**, **205**
— mediana anterior medullae oblongatae 122, 220, 223
— — — — spinalis 121, 122, 127—129
— — (posterior) fossae rhomboideae 222
— parietooccipitalis **149**, 153, 154, 157, 158, 161
— transversa cerebri 164, 166, (167)
— — cerebelli 232
flocculus cerebelli 138, 174, 231, 232, 233
folium vermis 178, 230, 231
foramen caecum medullae oblongatae 174
— interventriculare (Monroi) 149, **164—167**, 178, 180, 197
— singulare 297, 298
formatio reticularis medullae oblongatae 223
fornix (cerebri) 149, 158, **161**, 163, 164, 166, 178, 189, 197, 205
— conjunctivae 261, 262
— sacci lacrimalis 267
fossa anthelicis 335, 336
— cerebri lateralis 157
— incudis 304, 314
— rhomboidea 120, 140, 161, 178, 180, **206**, 207, (220, 221), 222
fossula fenestrae cochleae 302, 304, 305
— — vestibuli 305
fovea centralis retinae 240, 242, 243
— inferior fossae rhomboideae 206
fundus folliculi pili 331
— meatus acustici interni 297, 298, 300
funiculus anterior medullae spinalis 131
— lateralis medullae oblongatae 174
— — spinalis 131
— posterior medullae spinalis 131
frenulum veli medullaris anterioris 180, 206

G.

ganglia coeliaca 118
— lumbalia trunci sympathici 80, 118
— sacralia trunci sympathici 88, 118
— thoracalia trunci sympathici 18, 22, 115—117
ganglion cervicale inferius trunci sympathici 13. 72, 115, 117
— — medium trunci sympathici 13, 72, 115, 117
— — superius trunci sympathici 13, 67, 72, 114
— ciliare 61, 62, 114
— coccygeum trunci sympathici 118
— geniculi nervi facialis 68—70, 314, 315, 319
— jugulare nervi vagi 68—70
— mesentericum superius 118
— nodosum nervi vagi 67, 72, 114
— oticum 67, 68, 114
— petrosum nervi glossopharyngei 73, 114
— semilunare nervi trigemini 60—63, 67—70, 114, 135
— spinale 119, 120, 124, 128, 129
— sphenopalatinum 66—68, 114
— submaxillare 59, 68, 114
— superius nervi glossopharyngei 72
geniculum nervi facialis 321 (s. a. ganglion geniculi)
genu capsulae internae (188)
— corporis callosi 149, 158, 161—164, 173, 178
— internum nervi (radicis) facialis 215
glandula lacrimalis inferior 264
— — superior 60—62, 70, 114, **264**, 266, 273, 277, 279, 284
glandulae areolares 340
— ciliares 262
— glomiformes 351
— lacrimales accessoriae 262
— sebaceae 351
— tarsales 262, 265, 283
globus pallidus (nuclei lentiformis) 184, 188, 194, 197, 205
glomus chorioideum 163, 164, 166
granulationes arachnoideales 137, 143, 145
gyri breves insulae 160, 162
— occipitales laterales 153
— — superiores 154
— orbitales 148, 157
gyrus angularis 153
— centralis anterior 152—155
— — posterior 152—155
— cinguli 149, 158, (161)
— fornicatus 158, (161)
— frontalis inferior 152, 153
— — medius 152—155

gyrus frontalis superior 152—155
— fusiformis 157, 158
— hippocampi 157, 158, 165, 168, 169, (170), 171, 172, (190), 205
— lingualis 157, 158
— longus insulae 160, 162
— rectus 157
— subcallosus 149, 178
— supramarginalis 153
— temporalis inferior 153, 157, 158
— — medius 153
— — superior 153
— — transversus 162

H.

habenula 165—174, 177—180
hamulus laminae spiralis 292, 299
helicotrema 299
helix 332—335
hilus nuclei dentati (cerebelli) 235
— — olivaris 220—222
hippocampus 163, 165, **168—171**, 174, 184, 205
hirci 352
hypophysis 148, 149, 178, 179
hypothalamus 151, (178), **189**

I.

incisura cerebelli anterior 230, 231
— — posterior 230, 233
— intertragica 332, 333
— tentorii 136
— terminalis auris 335
— tympanica 326
incisurae cartilaginis meatus acustici externi 333
incus 309, 310, 313, (314—318)
infundibulum (cerebri) 149, 174, 178, 179, 196, 197
insula 160, 162, (184, 188), 196, (197)
intumescentia cervicalis medullae spinalis 122
— lumbalis medullae spinalis 119, 122
iris 240—243, 247, 254
isthmus cartilaginis auris 335
— gyri fornicati 158
— rhombencephali 150, 151

L.

labyrinthus membranaceus 285—287, 315
— osseus 289—296
lacertus fibrosus m. recti oculi lateralis 281
lacunae laterales (durae matris) 137, 143
lacus lacrimalis 261, 267
lamina affixa thalami 163, 164, 166, 173, 180, 189
— (= membrana) choriocapillaris 248
lamina cribrosa sclerae 240, 242
— fusca — 241
— modioli 292, 299, 300
— quadrigemina 149, 165, 173, 178, **180**, (188) (206), 212
— septi pellucidi 149, 164, **166**, 167, 173, 180, **195**, (196), **197**
— rostralis (corporis callosi) 161, 178
— spiralis membranacea 288
— — ossea 288, 291, 292, 299, 300
— — secundaria 300
— terminalis 149, 178
— tragi 339
lanugo 353
lemniscus (medialis et lateralis) 214, 215
lens crystallina 240, 242, 244, 246, **250—253**
ligamentum incudis superius 317, 318
— — posterius 314—318
— mallei anterius 314
— — laterale 324
— — superius 314—318
— palpebrale mediale 267, 284
limbus membranae tympani 317
— palpebralis anterior 262
— — posterior 262
— spiralis 288
limen insulae 174
lingula vermis (cerebelli) 178, 180, 232, 234, 235
lobulus paracentralis 149, 158
— parietalis inferior 152, 153
— — superior 152, 153
— quadrangularis (cerebelli) 230
— semilunaris inferior (cerebelli) 230, 231
— — superior (cerebelli) 230
lobus anterior hypophyseos 149, 179
— biventer (cerebelli) 231, 233
— posterior hypophyseos 149, 179
locus caeruleus 206
lunula unguis 346—350
lymphoglandulae auriculares anteriores 354
— — posteriores 354, 357
— axillares 355, 358
— brachiales 358
— cervicales profundae inferiores 354, 358
— — — superiores 354, 358
— — superficiales 354
— faciales profundae 354
— hypogastricae 359
— iliacae 359
— infraclaviculares 357
— inguinales 359, 361
— lumbales 359

lymphoglandulae mesentericae 359, 360
— occipitales 354, 357
— parotideae 354, 357
— subinguinales profundae 359
— — superficiales 359, 361
— submaxillares 354, 357
— submentales 354, 357
— subpectorales 358

M.

macula cribrosa inferior 292
— — media 302
— — superior 302
— lutea 245
malleus 306—309, 313, 314—318
mamma 340—343
manubrium mallei 306—309, 313
margo occultus unguis 346, 350
— pupillaris iridis 242, 243
massa intermedia thalami 149, 165, 173, 178, 188, **189**, 205
matrix unguis 348, 349
meatus acusticus externus 304, 324, 325, 327, 328
— — internus 297, 298
medulla oblongata 148, 149, 174, 178, 183, 184, 203, 204, **206**, **207**, 220—229
— spinalis 120—130
membrana obturatoria stapedis 319
— tympani 315—318, 324, 326—328
— — secundaria 320
— vestibularis (Reissneri) 288
mesencephalon 150, 151
metencephalon 150, 151
modiolus 300
monticulus 178, 230
musculus antitragicus 338
— auricularis posterior 337
— — superior 337
— ciliaris 242, 243
— helicis major 338
— — minor 338
— levator palpebrae superioris 60—63, **269**, **270**, 273, 277—282, 284
— obliquus auriculae 337
— — oculi inferior 63, **269**, **270**, **273—276**, 279, 282—284
— — — superior 60—63, **270**, **273—277**, 279—281, 283, 284
— orbicularis oculi 9, 10, 267, 268
— rectus oculi inferior 63, **269**, **270**, 274—276, 279—282
musculus rectus oculi lateralis 60—63, **269**, 270, 273—276, 277—281, 283
— — — medialis 62, 63, **270**, 274—276, 277—281, 283
— — — superior 60—62, **269**, **270**, 273—277, 279—282, 283
— sphincter pupillae 242
— stapedius 320
— tensor tympani 318—321, 323, 324
— tragicus 338
— transversus auriculae 337
myelencephalon 150, 151

N.

nervi alveolares superiores 58, 59, 68, 69, 114
— anococcygei 89, 90
— caroticotympanici 69, (114)
— ciliares breves 62
— — longi 62
— cluneum inferiores (laterales) 89, 90, **93**, 98
— — medii 93
— — superiores 93, 98
— cutanei cruris mediales 94
— digitales dorsales 45, 46
— — — pedis 108, 109, 110
— — plantares communes 111—113
— — — proprii 111—113
— digitales volares communes 44, 46, 49
— — — proprii 44, 46, 49, 50
— haemorrhoidales inferiores 89, 90
— — medii 88
— intercostales 18, 22, 115—117
— intercostobrachiales 16
— labiales pudendi posteriores 90
— meatus auditorii externi 58, 59
— nasales anteriores laterales 65, 67
— — — mediales 64
— scrotales anteriores 86
— — posteriores 89
— sphenopalatini 66, 67
— supraclaviculares 6, 7, 29, 31
— temporales profundi 58, 59, 68
— thoracales anteriores 13, (17)
nervus abducens **60—63**, 135, 139, 146, 148, 161
— accessorius **7—10**, 13, 23, 25, 72, 135, 146, 148, 174, 228, 229
— acusticus 148, 174, 207, 220, 285, 286, 315
— alveolaris superior medius 68, 69
— — inferior 56, 58, 59, 114
— ampullaris lateralis 285, 286, (315)
— — posterior 285, 286, (315)
— — superior 285, 286, (315)

nervus auricularis magnus 6—8, 51
— — posterior 52
— auriculotemporalis 51—56, 58, 59
— axillaris 16, 26, 27, (33), 34
— bucinatorius 54—56, 58, 59
— canalis pterygoidei 66, 67, 68, 114
— cardiacus inferior 115
— — medius 72, 115
— — superior 72, 115
— caroticus internus 69, 72, 114
— cluneum inferior medialis 89, 90
— coccygeus 88
— cochleae 285, 286, (315)
— cutaneus antebrachii dorsalis 32, 35
— — — lateralis 29, 32, 33
— — — medialis 29, 32, 33
— — brachii lateralis 27, 29
— — — medialis 26, 32, 33
— — — posterior 31, 35
— — colli 6, 7
— — dorsalis pedis intermedius 108
— — — — lateralis 103, 106
— — — — medialis 108
— — femoris lateralis 80, 91, 93
— — — posterior 93, 94, 96, 99
— — surae lateralis 94, 99, 100, 102
— — — medialis 94, 100
— dorsalis penis 86
— — scapulae 23, 25
— ethmoidalis anterior 60, 62—66
— — posterior 62, 63
— facialis **46—56**, 58, 59, 68, 69, 71, 73, 114, 135, 146, 174, 215, 314, 315, 317, 319—**321**
— femoralis 80, 95—97
— (ramus) frontalis 51—56, 58—61
— genitofemoralis 80
— glossopharyngeus 64, 65, 68, 69, **72**, 74, **114**, 135, 146, 148, 174, (222, 223)
— glutaeus inferior 100, 101
— — superior 101
— hypoglossus 9, 10, 13—**15**, **59**, 64, 72, **75**, 114, 135, 146, 148, 174, 207, 222
— iliohypogastricus 80, 91, 93
— ilioinguinalis 80, 91, 93
— infraorbitalis 53—56, 58, 59, 68, 69, 114
— infratrochlearis 53—56, 58, 59, 63
— intermedius 69, 71, 135, 148, 174
— interosseus (antebrachii) volaris 39
— ischiadicus 98, 100—102
— jugularis 67, 72
— lacrimalis 60—62, 70, 114, 264
— laryngeus inferior 15, 74
nervus laryngeus superior 10, (13), 72, 74, 114
— lingualis 15, 56, 58, **59**, 68, 75
— lumboinguinalis 80, 91
— mandibularis 56, 58, 59, 67, 68, 114
— massetericus 55, 56, 58
— masticatorius 59
— maxillaris 67—69, 70, 114, 148
— medianus 26, 33, 34, 37—40, 49
— meningeus medius 60, 135
— mentalis 53—56, 68, 114
— musculocutaneus 26, 33, 34
— myohyoideus 9, 10, 13, 58, **59**, 68
— nasociliaris 60—63, 114
— nasopalatinus (Scarpae) 64
— obturatorius 80, 88, 96, 97
— occipitalis major 8—10, 13, 23, **25**, 51—55
— — minor 6—10, **13**, 23, 51—55
— oculomotorius **60—63**, 114, 135, 139, 146—148, (174), 178, 212
— olfactorius 64, 65, 135
— ophthalmicus **60—63**, 67—69, 70, 148
— opticus **62**, **63**, 135, 138, 139, 144, 146—149, 157, 161, **177**, 183, 240, 241, 269, 270, 274—278, 280—283
— palatinus anterior 65—68
— — medius 65—68
— — posterior 65—68
— perinei 89, 90
— peronaeus communis 99, 100, 102—104, 106
— — profundus 106, 110
— — superficialis 106, 108
— petrosus superficialis major 66—69, 73, 114, 135
— — — minor 67—69, 73, 114, 135
— — profundus 67—69, 114
— phrenicus 9, 10, **13**, 15, 20, 115
— plantaris lateralis 112, 113
— — medialis 112, 113
— pterygoideus externus 59
— — internus 67
— pudendus 88—90
— radialis 26, 33—43
— recurrens 13, 15, 18, 74, **115**, 117
— saccularis 285, 286, (315)
— saphenus 92, 94, 96, 97, 108
— spermaticus externus 80, 88, 91
— spinalis 24, 120, 129
— spinosus 60, 135
— splanchnicus major 115—118
— — minor 116—118
— sublingualis 68, 75
— suboccipitalis 25
— supraorbitalis 51—56, 58—61, 263

nervus suprascapularis 26, 27
— suralis 94, 108
— temporalis profundus anterior 58, 59
— — — posterior 58, 59
— tensoris tympani 67
— — veli palatini 67
— tentorii 60
— thoracodorsalis 6, 7, 14, 15
— thoracalis longus 13, 16, 17
— tibialis 100, 102—105
— trigeminus **60—69**, 71, 114, 135, 138, 144, **148**, 174, 207
— trochlearis **60—62**, (63), 135, 148, 174, 206, 207
— tympanicus 68, 69, 73, 104
— ulnaris 26, 33, 34, 37—40, 49, 50
— utricularis 285, 286
— vagus 9, 10, **13**, 15, 17, 67, 69, **72**, 73, **114—117**, 148, 174, 220, 221
— vestibuli 285, 286
— zygomaticus 63, 68—70, 114
nidus avis (cerebelli) 233
nodulus vermis 178, 201, 202, 231—233
nuclei arcuati medullae oblongatae 220, 221
— corporis mamillaris 184, 189, 205
— pontis 215
— thalami 184, 188, 189
nucleus alae cinereae 222
— ambiguus 220, 221
— amygdalae 196
— caudatus[1]) (163, 164), 165, (166, 173), 180, 184, 188, 189, 195—197, 205
— colliculi inferioris 213
— dentatus cerebelli 234, 235
— dorsalis medullae spinalis 125, 126
— emboliformis 235
— fasciculi cuneati 223, 228
— — gracilis 223, 228
— fastigii 235
— globosus 235
— hypothalamicus 184, 188
— lentiformis 184, 188, 195—197, 205
— lentis 252
— nervi abducentis 215
— — acustici ventralis 220
— — — dorsalis 220
— — facialis 215
— — hypoglossi 221, 222
— — oculomotorii 212
— — trochlearis 213
— — vestibuli dorsalis 200
— nervi vestibuli lateralis 215
nucleus olivaris (inferior) 220—222
— — accessorius dorsalis 221
— — — medialis 221
— radicis descendentis nervi trigemini 214
— ruber tegmenti 177, 188, 212
— spinalis nervi trigemini 220—223, 228, 229

[1]) See also corpus striatum.

O.

obex 206
oliva 148, 174, 207
operculum 153
ora serrata 240, 242, 244, 246
orbiculus ciliaris 240, 242, 246, 254
ostium tympanicum tubae auditivae 304, 305, 314, 315, 319

P.

palpebra 259—263, 265—268
papilla lacrimalis inferior 261, 267
— — superior 261, 267
— mammae 340—343
— nervi optici 236, 237, 242, 245
— pili 351
pars ciliaris retinae 242, 244, 246
— flaccida membranae tympani 326
— inferior fossae rhomboideae 206
— intermedia — — 206
— iridica retinae 242
— libera columnae fornicis 161, 178, 180
— lumbalis medullae spinalis 121
— opercularis gyri frontalis inferioris 153
— optica retinae 240, 242, 244—246
— orbitalis gyri frontalis inferioris 153
— prima radicis nervi facialis 215
— secunda radicis nervi facialis 215
— subfrontalis sulci cinguli 158
— superior fossae rhomboideae 206
— tecta columnae fornicis 161
— tensa membranae tympani 326
— thoracalis medullae spinalis 121
pedunculus cerebri 149, 174, 177, 178, 184, 189, 207, 212, 213
— flocculi 232, 233
pia mater encephali 140, (141), 143, 144, 190
— — spinalis 124, 131
pili 351, 352
placenta 2
plexus chorioideus ventriculi lateralis 163, 164 166, 167, 189, 190, 205
— — — quarti 148, 174, 184, 231
— — — tertii 178, 189, 205
— gangliosus ciliaris 242

plexus (nervosus) brachialis 12, 13, 15—17, 26, 33, 34
— — cervicalis 6—10, 12, (13)
— — dentalis inferior 58
— — — superior 69
— — gastricus anterior (n. vagi) 117
— — — posterior (n. vagi) 117
— — lumbalis 37, 80, 118
— — oesophageus anterior et posterior n. vagi 115—117
— — parotideus nervi facialis 53
— — pharyngeus 72
— — pudendus 88
— — pulmonalis anterior et posterior (n. vagi) 115—117
— — sacralis 88, 118
— — tympanicus 69
— — sympathicus cardiacus 115
— — — caroticus internus 69
— — — coeliacus 118
— — — hypogastricus 118
— — — mesentericus inferior 118
— — — — superior 118
— — — renalis 118
— venosus caroticus internus 330, 331
— — haemorrhoidalis 84, 85
— — pampiniformis 84, 85
— — pharyngeus 72
— — pterygoideus 56
— — pudendalis 84
— — thyreoideus impar 15
— — uterovaginalis 85
— — vesicalis 84, 85
plica malleolaris anterior 316—318
— — posterior 316—318
— membranae tympani anterior 326
— — — posterior 326
— semilunaris conjunctivae 261, 267
polus anterior lentis 242, 251
— — oculi 242
— frontalis hemisphaerii 148, 149, 153
— occipitalis hemisphaerii 148, 149, 153
— posterior lentis 242, 251
— — oculi 242
— temporalis hemisphaerii 148, 149, 153
pons 148, 149, **174**, 178, (184), 206, 207, 214, 215
portio major nervi trigemini 67, 69, 148
— minor nervi trigemini 67, 69, 148
praecuneus 149, 158
processus anterior mallei 306, 307, 313
— ciliares 240, 244, 246, 247, 254, 255
— cochleariformis 303, 305, 320
— lenticularis incudis 310, 316—318
prominentia canalis facialis 303, 304, 314, 319, 320
— — semicircularis lateralis 304, 319, 320
— malleolaris 327
promontorium 303—305, 320—324
pulvinar thalami 173, 180, 207
punctum lacrimale inferius 261, 266, 267
— — superius 261, 266, 267
pupilla 243, 247, 259, 274
putamen (nuclei lentiformis) 184, 188, 196, 197, 205
pyramides medullae oblongatae 148, 174, (184), 207, 220—222, 228
pyramis vermis 178, 231, 233

R.

radiatio corporis callosi 184, 195—197, 205
radii lentis 250—253, 255
radix brevis ganglii ciliaris 61, 62
— descendens nervi trigemini 213, 214
— lateralis tractus optici 177
— longa ganglia ciliaris 61, 62
— medialis tractus optici 177
— pili 351
— sympathica ganglii ciliaris 61, 62
rami articulares art. genus supremae 97
— bronchiales n. vagi 115—117
— buccales n. facialis 51—54
— calcanei laterales art. peroneae 105
— — mediales (nervi tibialis) 111
— cardiaci inferiores n. recurrentis 115, 117
— — superiores nervi vagi 72
— communicantes trunci sympathici 115—118
— cutanei nervorum intercostalium 16, 17
— — anteriores nervi femoralis 91
— dentales inferiores 58
— — superiores 69
— gastrici nervi vagi 117
— intercostales arteriae mammariae internae 21
— laryngopharyngei trunci sympathici 72
— nasales anteriores nervi ethmoidalis anterioris 64—66
— — interni n. ethmoidalis anterioris 66
— — posteriores inferiores 65—67
— nasales posteriores superiores laterales 65—67
— — — mediales 65—67
— perforantes arteriae mammariae internae 14, 17
— perineales n. cutanei femoris posterioris 89, 90
— pharyngei n. glossopharyngei 72
— — n. vagi 72
ramus auricularis n. vagi 51—54, 72, 73
— zygomaticofacialis 51—55
— zygomaticotemporalis 51—55
recessus membranae tympani 316, 317

rhinencephalon 150, 151
rhombencephalon 150, 151
rostrum corporis callosi 149, 158, 161, **178**

S.

sacculus 285—287, 315
saccus endolymphaticus 287
— lacrimalis 266—268, 284
scala tympani 286, 288, 291, 292, 299, 300
— vestibuli 286, 288, 291, 292, 299, 300
scapha 332, 333
scapus pili 351
sclera 240—242, 244—246, 248
septum intermedium posterius medullae spinalis 131
— pellucidum 149, 158, 161, 163—167, 173, **178**, 184, 188, **195—197**
— posterius medullae spinalis 131
sinus cavernosus 135, 136, 139
— circularis 135
— coronarius cordis 5
— intercavernosus anterior 135
— — posterior 135
— occipitalis 136
— petrosus inferior 136
— — superior 135, 136
— posterior cavi tympani 304
— rectus 135, 136, 141
— sagittalis inferior 136
— — superior 135, 136, 137, 140, 141, 143
— sphenoparietalis 135
— transversus 135—137, 140, 141
— tympani 304
— venosus sclerae 240, 242, 248
spatia intervaginalia 242
spatium interfasciale (bulbi) 278, 279, 282
— perichorioideale (bulbi) 242
spina helicis 333—335
— tympanica major 325, 326
— — minor 325, 326
splenium corporis callosi 149, 157, 158, 162, 163, 172, 178
stapes 311—313, 319—321
stratum griseum centrale medullae oblongatae 220—222
— — — mesencephali 204, 208
— — colliculi superioris 223
— pigmenti corporis ciliaris 242
— — iridis 242
— — retinae 242
— zonale thalami 189
stria malleolaris 327
— medullaris thalami 173, 180
stria terminalis 163, 164, 166, 173
striae longitudinales corporis callosi 162, 163, 189
— medullares (acusticae) fossae rhomboideae 206, 207, 220
— olfactoriae 174
subiculum promontorii 303—306
substantia nigra 177, 184, 190
— perforata anterior 148, 157, 174, 177, 196
— — posterior 178, 190
— propria corneae 242
— reticularis alba (Arnoldi) 170, 171, 190
— — — medullae oblongatae 220—222
— — grisea — — 220—222
sulci occipitales laterales 152—155
— — superiores 152—155
sulcus anthelicis transversus 335, 336
— basilaris pontis 174, 215
— centralis (Rolandi) 153—155
— cinguli 149, 158, 161
— circularis (Reili) 160, 162
— corporis callosi 158, 189
— cruris helicis 336
— frontalis inferior 152, 153
— — superior 154, 155
— horizontalis cerebelli 230—233
— hypothalamicus 149, 166
— intermedius posterior medullae spinalis 131
— — — — oblongatae 206
— interparietalis 152—155
— lateralis anterior medullae oblongatae 174
— — — — spinalis 127, 131
— — mesencephali 177, 213
— — posterior medullae spinalis 174
— limitans fossae rhomboideae 206
— matricis unguis 348
— medianus posterior medullae oblongatae 206
— — — — spinalis 121, 127, 129, 131
— nervi oculomotorii 174
— occipitalis transversus 153
— olfactorius 148, 157, 174
— orbitopalpebralis 259, 260
— parolfactorius anterior 149, 158, 178
— — posterior 149, 158, 178
— praecentralis 152—155
— promontorii 303, 304
— subparietalis 149, 158
— temporalis inferior 157, 158
— — medius 152, 153
— — superior 152, 153
— — transversus 162
— tympanicus 304, 324
supercilia 260 (267, 268) 283

T.

taenia fimbriae 190
— chorioidea 173, 180, 189
— thalami 180
— ventriculi quarti 206, 222
tapetum 168
tarsus inferior 262—264, 282
— superior 262—264, 282
tegmen tympani 303
tegmentum 177, 212, 213
tela chorioidea ventriculi quarti 178, 180, 234
— — — tertii 149, 166, 167, 189
telencephalon 150, 151
tentorium (cerebelli) 135, 136, 140, 141
thalamus (opticus) 149—151, 161, 165, **173**, 178, 180, 184, 188, 189, 205—207
tonsilla cerebelli 148, 232, 233
tractus olfactorius 148, 161, 174, 195
— opticus 148, 174, 177, 184, 189, 196, 197
— solitarius 220—222
— spinalis nervi trigemini 220—223
— spiralis foraminosus 297, 298, 300
tragi 339
tragus 332
trigonum (eminentia) collaterale 163, 165, 166, 168—170
— lemnisci 207
— nervi hypoglossi 206
— olfactorium 148, 157, 178
trochlea m. obliqui oculi superioris 63, 277
truncus corporis callosi 149, 158, 161, 162, 167, **178**, 184, 189, 197
— lumbosacralis 80, 88, 118
— lymphaticus intestinalis 356, 357, 359
— — jugularis dexter 356
— — — sinister 356
— — lumbalis dexter 356, 357, 359
— — — sinister 356, 357, 359
— — subclavius dexter 356
— — — sinister 356
— sympathicus 18, 22, 80, 115—118
tuba auditiva (Eustachii) 314—321, 323, 330, 331
tuber cinereum 148, 157, 174, 177, 178
— vermis 178, 232
tuberculum acusticum 206, 220
— anterius thalami 165, 173, 180
— auriculae 332
— cinereum 206
— cuneatum 206
tunica conjunctiva 242, (259, 282)
— — bulbi 242, 259, 261, 284
— — palpebrarum 262

U.

umbo membranae tympani 314—316, 324, 327, 328
uncus (gyri hippocampi) 148, 157, 158, 161, 165, 168, 170
ungues 346—350
utriculus 283—287, 315
uvula vermis 178, 230—232

V.

vallecula cerebelli 232
vallum unguis 347—350
velum medullare anterius 149, **178**, 180, 206, 234
— — posterius 232—234
vena alveolaris inferior 56
— anastomotica facialis 52, 55, 56
— angularis 52
— anonyma (dextra, sinistra) 9, 13, 15, 20, 22
— auricularis posterior 7, 8, 52
— axillaris 26, 27
— azygos 18, 22, 116
— basilica 28—30, 355
— cava inferior 77, 80, 116
— — superior 20, 22, 115
— centralis retinae (240), 243, 245, 248, (256)
— cephalica 8—10, 13, 14, 28—30, 355
— cerebri magna 135, 141, 147, 166, 167
— — interna 167
— cervicalis profunda 25
— — superficialis 14, 15
— chorioidea 167
— circumflexa humeri posterior 16
— — ilium profunda 80
— — — superficialis 91
— colica dextra 78
— — media 78
— — sinistra 78, 79
— comitans nervi hypoglossi 14, 15, 75
— cordis magna 4, 5
— — media 5
— — parva 5
— coronaria ventriculi 76
— cystica 76
— dorsalis penis 84, 86
— epigastrica inferior 80
— — superficialis 91
— facialis communis 8, 9
— — anterior 7—9
— — posterior 7—9
— femoralis 91, 95—97
— femoropoplitea 94
— frontalis 51

vena gastroepiploica dextra 76
— — sinistra 76
— glutaea inferior 101
— — superior 101
— haemorrhoidalis superior 84, 85
— hemiazygos 22
— — accessoria 22
— hypogastrica 80, 84, 85
— ileocolia 78
— iliaca communis 80, 84, 85
— — externa 80, 84, 85
— iliolumbalis 80
— jugularis anterior 7, 14
— — externa 6—8, **14**, **15**, 51—54
— — interna 8—10, 13—15, 20, 22, **72**, 328
— lingualis 14, 15, 75
— lumbalis ascendens 18, 22, 80
— mammaria interna 21
— mediana antebrachii 28—30
— — cubiti 28, 30
— mesenterica inferior 79
— — superior 77—79
— obliqua atrii sinistri (Marshalli) 5
— obturatoria 84, 85
— occipitalis 6—9, 23, 25, 51
— ophthalmica superior 135
— ovarica 85
— poplitea 99, 102—104
— portae 2, 3, 76, 77, (79)
— posterior ventriculi sinistri 5
— pudenda interna 84, 85, 89, 90, 101
— sacralis media 80
— saphena magna 91—93
— — parva 91—93
— septi pellucidi 167
— spermatica interna 80
— subclavia 10, 13, 15, 20, 22
— submentalis 14
— temporalis media 55, 56
— terminalis 167
— testicularis 80, 84, 86
— thoracalis lateralis 16, 17
— thoracoacromialis 14
— thoracoepigastrica 16, 17, 355
— thyreoidea inferior 15
— — ima 14, 15
— — superior 14, 15
— transversa colli 7
vena transversa faciei 51
— umbilicalis 2, 3
— vertebralis 13, 25
venae brachiales 26, 33
— cerebri superiores 136, 137, 140, 145
— ciliares anteriores 248, 249
— — posteriores 248, 249
— costoaxillares 16, 17
— digitales dorsales 108
— diploicae 142, 143
— epigastricae superiores 21
— episclerales 248
— haemorrhoidales inferiores 89, 90
— hepaticae 2
— intercostales 18, 22, 116
— — anteriores 21
— intestinales 78
— labiales (pudendi) posteriores 90
— lumbales 80
— meningeae mediae 136
— metacarpeae dorsales 45
— metatarseae dorsales 108
— pedis dorsales 45
— pharyngeae 72
— pyloricae 76
— renales 80
— scrotales anteriores 86
— — posteriores 89
— sigmoideae 79
— spermaticae internae 80
— temporales superficiales 51
— thymicae 15
— thyreoideae inferiores 14, 15
— — superiores 14, 15
— tibiales posteriores 103
— vorticosae 249
ventriculus lateralis (encephali) 163—166, 188, 189, 195—197, 205
— quartus 149, 178, 180, 214, 215, 234
— tertius 149, 165, 173, 178, 184, 188, 189
venulae maculares 243
vermis cerebelli 149, 178, 232—235
vestibulum (labyrinthi) 285—287, 289, (290—292), (294, 295), 296, (301), 302
vertex corneae 242

Z.

zonula ciliaris 240, 242, 244, 246, 247, 255

WELLCOME INSTITUTE LIBRARY UNIVERSITY COLLEGE LONDON